A manual on Clinical Surgery

Includes :

- SPECIAL INVESTIGATIONS
- DIFFERENTIAL DIAGNOSIS

S. Das

M.B.B.S.(Cal),F.R.C.S.(Eng.& Edin.)

13th EDITION

Author of:

- A CONCISE TEXTBOOK OF SURGERY
- A PRACTICAL GUIDE TO OPERATIVE SURGERY
- A TEXTBOOK ON SURGICAL SHORT CASES
- UNDERGRADUATE FRACTURES & ORTHOPAEDICS

A Manual On CLINICAL SURGERY

INCLUDING SPECIAL INVESTIGATIONS AND
DIFFERENTIAL DIAGNOSIS

Somen Das

M.B.B.S. (Cal.), F.R.C.S. (Eng. & Edin.)

Senior Consultant Surgeon

Author of

A CONCISE TEXTBOOK OF SURGERY,
A PRACTICAL GUIDE TO OPERATIVE SURGERY,
A TEXTBOOK ON SURGICAL SHORT CASES
UNDERGRADUATE FRACTURES & ORTHOPAEDICS
&
MCQs IN FRACTURES & ORTHOPAEDICS.

THIRTEENTH EDITION

KOLKATA
2018

All Rights Reserved

This book or any part thereof must not be reproduced in any form without the written permission of the author, ***DR. S. DAS.***

Copyright © DR. S. DAS.

First Edition.....**March, 1986**

Second Edition.....**March, 1987**

Third Edition.....**May, 1988**

Fourth Edition.....**February, 1996**

Fifth Edition.....**March, 2000**

Sixth Edition.....**June, 2004**

Seventh Edition.....**August, 2008**

Eighth Edition.....**April, 2010**

Ninth Edition.....**August, 2011**
Reprinted.....December, 2011
Reprinted.....June, 2012

Tenth Edition.....**January, 2013**
Reprinted.....June, 2013
Reprinted.....March, 2014
Reprinted.....November, 2014

Eleventh Edition.....**August, 2015**
Reprinted .....May, 2016

Twelfth Edition.....**November, 2016**
Reprinted .....June, 2017

Thirteenth Edition.....**February, 2018**

Rs. 958.00
US$ 22.00

ISBN-978-81-905681-0-4

Published by

Dr. S. Das

13, Old Mayors' Court,
Kolkata - 700 005
INDIA
E-mail - drsdas100@rediffmail.com
salessdas06284@rediffmail.com
Website : http://www.surgerybooksbydrsdas.com

CONTENTS

CHAPTER		PAGE
1.	GENERAL SCHEME OF CASE-TAKING	1
2.	A FEW SPECIAL SYMPTOMS AND SIGNS	11
3.	EXAMINATION OF A LUMP OR A SWELLING	21
4.	EXAMINATION OF AN ULCER	61
5.	EXAMINATION OF A SINUS OR A FISTULA	76
6.	EXAMINATION OF PERIPHERAL VASCULAR DISEASES AND GANGRENE	80
7.	EXAMINATION OF VARICOSE VEINS	100
8.	EXAMINATION OF THE LYMPHATIC SYSTEM	109
9.	EXAMINATION OF PERIPHERAL NERVE LESIONS	122
10.	DISEASES OF MUSCLES, TENDONS AND FASCIAE	142
11.	EXAMINATION OF DISEASES OF BONE	146
12.	EXAMINATION OF BONE AND JOINT INJURIES	167
13.	EXAMINATION OF INJURIES ABOUT INDIVIDUAL JOINTS	177
14.	EXAMINATION OF PATHOLOGICAL JOINTS	213
15.	EXAMINATION OF INDIVIDUAL JOINT PATHOLOGIES	223
16.	EXAMINATION OF HEAD INJURIES	258
17.	INVESTIGATION OF INTRACRANIAL SPACE-OCCUPYING LESIONS	271
18.	EXAMINATION OF SPINAL INJURIES	282
19.	EXAMINATION OF SPINAL ABNORMALITIES	288
20.	EXAMINATION OF THE HAND	310
21.	EXAMINATION OF THE FOOT	320
22.	EXAMINATION OF THE HEAD AND FACE	327
23.	EXAMINATION OF THE JAWS AND TEMPOROMANDIBULAR JOINT	333
24.	EXAMINATION OF THE PALATE, CHEEK, TONGUE AND FLOOR OF THE MOUTH	341
25.	EXAMINATION OF THE SALIVARY GLANDS	354
26.	EXAMINATION OF THE NECK	364
27.	EXAMINATION OF THE THYROID GLAND	374
28.	EXAMINATION OF INJURIES OF THE CHEST	396
29.	EXAMINATION OF DISEASES OF THE CHEST	402
30.	EXAMINATION OF THE BREAST	410
31.	EXAMINATION OF A CASE OF DYSPHAGIA	434
32.	EXAMINATION OF ABDOMINAL INJURIES	442
33.	EXAMINATION OF AN ACUTE ABDOMEN	450
34.	EXAMINATION OF CHRONIC ABDOMINAL CONDITIONS	482
35.	EXAMINATION OF AN ABDOMINAL LUMP	518
36.	EXAMINATION OF A RECTAL CASE	539
37.	EXAMINATION OF A URINARY CASE	555
38.	EXAMINATION OF A CASE OF HERNIA	594
39.	EXAMINATION OF A SWELLING IN THE INGUINOSCROTAL REGION OR GROIN (EXCEPT INGUINAL AND FEMORAL HERNIAS)	611
40.	EXAMINATION OF MALE EXTERNAL GENITALIA	617

Chapter

1 GENERAL SCHEME OF CASE-TAKING

In this chapter it will be narrated in brief, how to follow a patient from his arrival at the hospital or clinic upto his normal condition, i.e. after he has come round. It is a general scheme and applied to all patients whoever come to the surgeon. The student should learn this scheme and make it a reflex, so that he can apply this scheme to all his patients. Ultimately, this will become a habit in his professional career.

This general scheme includes — (1) History taking; (2) Physical examination; (3) Special investigation; (4) Clinical Diagnosis;(5) Treatment — both medical and surgical; (6) Progress during postoperative period; (7) Follow-Up; (8) Termination.

In the clinic, it is a good practice to start examining the patient when he walks into the room rather than to meet him undressed on a coach in a cubicle. It is helpful if the person, who accompanied the patient, remains by the side of the patient in the early part of the history-taking. He can provide valuable information about the type of injury the patient might have sustained, some details of the complaints or about changes in health or behaviour of the patient in the recent past.

HISTORY-TAKING

1. **Particulars of the patient.**— Before interrogating about the complaints of the patient, it is a good practice to know the patient first. That means the following headings should be noted in the history-sheet :

NAME.— It is very important to know the patient by name. The patients like to be asked by name, as for example, 'Mr. Sirkar, how long are you having this problem?' This will not only help to elicit the history properly, but also it will be of psychological benefit to the patient just before the operation and in postoperative period. The patient is assured that you know him by name.

AGE.— Congenital anomalies mostly present since birth, e.g. cystic hygroma, cleft lip, cleft palate, sacro-coccygeal teratoma, phimosis etc. But a few congenital anomalies present later in life, such as persistent urachus, branchial cyst, branchial fistula etc. Certain diseases are peculiar to a particular age. Acute arthritis, acute osteomyelitis, Wilms' tumour of the kidney are found mostly in infants. Sarcomas affect teenagers. Appendicitis is commonly seen in girls between 14 to 25 years of age. Though carcinomas affect mostly those who have passed 40 years of age, yet it must be remembered that *they should not be excluded by age alone.* Osteoarthritis and benign hypertrophy of the prostate are diseases of old age.

SEX.— It goes without saying that the diseases, which affect the sexual organs, will be peculiar to the sex concerned. Besides these, certain other diseases are predominantly seen in a particular sex, such as diseases of the thyroid, visceroptosis, movable kidney, cystitis are

commoner in females, whereas carcinomas of the stomach, lungs, kidneys are *commoner in males.* Haemophilia affects males only, although the disease is transmitted through the females.

RELIGION.— Carcinoma of penis is hardly seen in Jews and Muslims owing to their religious custom of compulsory circumcision in infancy. For the same reason, phimosis, subprepucial infection etc. are not at all seen in them. On the other hand, intussusception is sometimes seen after the month-long fast (Ramjan) in Muslims.

SOCIAL STATUS.— Certain diseases are more often seen in individuals of high social status e.g. acute appendicitis; whereas a few diseases are more often seen in individuals of low social status e.g. tuberculosis due to malnourishment and poor living conditions.

OCCUPATION.— Some diseases have shown their peculiar predilection towards certain occupations. As for example, varicose veins are commonly seen among bus conductors. Workers in aniline dye factories are more prone to urinary bladder neoplasms than others. Carcinoma of the scrotum is more commonly seen among chimney sweepers and in those, who work in tar and shale oil. Injury to the medial semilunar cartilage of the knee is common among footballers and miners. Enlargement of certain bursae may occur from repeated friction of the skin over the bursae, e.g. student's elbow, house-maid's knee etc. Strain to the extensor origin from the lateral epicondyle of the humerus is commonly seen among tennis players and is known as 'tennis elbow' .

RESIDENCE.— A few surgical diseases have got geographical distribution. Filariasis is common in Orissa, whereas leprosy in Bankura district of West Bengal. Gallbladder diseases are commoner in West Bengal and Bangladesh. Peptic ulcer is more commonly seen in northwestern part and southern parts of India as they are habituated to take more spicy foods. Bilharziasis is common in Egypt, sleeping sickness in Africa and hydatid disease in sheep-rearing districts of Australia, Greece, Turkey, Iran, Iraq, U.K. etc. Tropical diseases, such as amoebiasis, are obviously common in tropical countries. 'Kangri' cancer (Fig. 1.1) is peculiar among the Kashmiri on their abdomen due to their habit of carrying the 'Kangri' (an earthenware filled with burning charcoal to keep themselves warm).



Fig.1.1.— A kangri cancer on the abdomen of a Kashmiri.

In this column, the students must not forget to write the full postal address of the patient for future correspondence.

2. **Chief Complaints.**— The complaints of the patient are recorded under this heading in a chronological order of their appearance. The patient is asked, 'What are your complaints?' A few dull patients do not really understand what do you want to know and may start irrelevant talks. In that case, he should be asked, 'What brings you here?'. You should also know the duration of these complaints. For this, ask the patient, "How long have you been suffering from each of these complaints?" These should be recorded in a chronological order. As for example, in case of a sinus in the neck, the complaints may be put down in the following way :

(a) Swelling in the neck — 1 year.
(b) Fever (mostly in the evening) — 10 months.
(c) Slight pain in the swelling — 6 months.
(d) Sinus in the neck — 1 month.

If a few complaints start simultaneously, list them in order of severity.

The students should make it very clear that the patient was free from any complaint before the period mentioned by the patient. For this, the student should ask the patient with sinus in the neck, "Were you perfectly well before the appearance of swelling in the neck?" This is very important, as very often the patients may not mention some of his previous complaints as he considers them insignificant or unrelated to his present trouble. But, on the contrary, this may give a very important clue to arrive at a diagnosis. As for example, a patient with rigidity and tenderness in right hypochondriac region of the abdomen may not have told you of his 'hunger pains' a few months back. But this simple hint at once tells you that this is a case of peptic perforation.

3. **History of Present Illness.**— This history commences from the beginning of the first symptom and extends to the time of examination. This includes (i) **the mode of onset** of the symptoms — whether sudden or gradual, as well as the cause of onset, if at all present; (ii) **the progress** of the disease with evolution of symptoms in the exact order of their occurrence; and lastly (iii) **the treatment** which the patient might have received - the mode of treatment and the doctor, who has treated. To know the mode of onset, the patient is asked, "How did the trouble start?" To know the progress of the disease, the patient is asked, "What is the next thing that happened?" or any such relevant question as the type of case may necessitate. *This should be recorded in the patient's own language* and not in scientific terms. The patient should be allowed to describe his own story of symptoms. They know more about their complaints than the doctors. But if they wander too far from the point, they should be put such questions as to bring them back into the matter. Never ask the question — "What are you suffering from?" The patient will obviously tell you his or another doctor's diagnosis, which you do not want to know. 'Leading questions' should not be put to the patients. By this, it is meant that questions, which yield only one answer, should not be asked. As for example, if the patient is asked like this —"Doesn't the pain move to the inferior angle of the right scapula?" Obviously a well-behaved patient will answer "Yes" to please you. So the question should be such that it leaves the patient with a free choice of answer. As for example, the question should be, "Does the pain ever move?" If the patient says, "Yes", you should ask, "Where does it go?" So the questions should not necessarily be 'leading', but to help the patient to narrate the different aspects of his symptoms to arrive at a definite diagnosis.

Sometimes *negative answers* are more valuable in arriving at a diagnosis and should never be disregarded. As for example, in case of a sinus on the cheek, absence of the history of watery discharge at the time of meals at once excludes the possibility of a parotid fistula.

4. **Associated diseases.**— Patinets may be suffereing from asociated medical diseases apart from the one which he/she is complaining of. Diabetes, high blood pressure, asthma, tropical diseases, bleeding disorders, rheumatic fever or even rarely shyphilis or gonorrhoea. This history is highly important as these may require additional treatment.

5. **Past history.**— *All the diseases* suffered by the patient, previous to the present one, should be noted and recorded in a chronological order. There should be mention of dates of their occurrence and the duration. This may have influence on the present condition. peoptic ulcer, acute pancreatitis, tuberculosis, gall bladder disease, appendicitis etc. are important. Students should not forget to mention any of the *previous operations or accidents* which the patient might have undergone or sustained. The dates and the types of the operations should be mentioned in a chronological order.

6. **Drug history.**— The patient should be asked about all the drugs he was on. Besides the fact that this will help to give a clue to the present illness or in the subsequet treatment, it has tremendous importance from anaesthetic point of view. Special enquiry should be made about steroids, insulin, antihypertensives, diuretics, ergot derivatives, monoamine oxidase inhibitors, hormone replacement therapy, contraceptive pills etc.

7. **History of allergy.**— This is very important and should not be missed under any circumstances, while taking history of a patient. The patient should be asked whether he or she is allergic to any medicine or diet. It should be noted with red type on the cover of the history sheet. The students should make it a practice and they will definitely find that this valuable practice will save many catastrophies.

8. **Personal history**.— Under this heading, the patient's habit *of smoking* (cigarettes, cigar or pipe and the frequency), *drinking of alcohol* (quality and quantity), *diet* (regular or irregular, vegetarian or non-vegetarian, takes spicy food or not etc.) are noted. It is also enquired about the *marital status* of the individual — whether married or single, a widow or a widower.

In women, *the menstrual history* must be recorded perfectly -— whether the patient is having regular menstruation or not, the days of menstruation, whether any pain is associated with menstruation or not and last date of menstruation. The number of pregnancies and miscarriages are noted with their dates, — whether the deliveries were normal or not, whether the patient had Caesarean section or not and if so, for what reason. The patient is also asked whether (there is any white discharge per vaginam or not.

9. **Family history.**— This is also important. Many diseases do recur in families. Haemophilia, tuberculosis, diabetes, essential hypertension, peptic ulcer, majority of the cancers particularly the breast cancer and certain other diseases like fissure-in-ano, piles etc. run in families. So the students must not forget to enquire about other members of the family, such as about the parents if they are still alive. How are they maintaining their healths? Did they suffer from any major ailments? If they arc dead, what were the causes of their deaths? You should also enquire about the brothers, sisters and children of the patient.

10. **History of immunization.**— Children should be asked whether they have been immunised against diphtheria, tetanus, whooping cough, poliomyelitis, small pox, tuberculosis etc.

PHYSICAL EXAMINATION

This includes **General survey, Local examination** and **General examination**.

A. GENERAL SURVEY.— Under this heading comes general assessment of illness, mental state, intelligence, build, state of nutrition, the attitude, the decubitus (position in bed), colour of the skin, skin eruptions if present and pulse, respiration and temperature.

Physical examination starts when the patient enters the clinic. It requires daylight and of course a co-operative patient. In artificial light, one may miss the faint yellow tinge of slight jaundice. For complete examination, the patient should be asked to take off all his clothes and covered by only a dressing gown. For examining a female patient there must be an attendant nurse.

GENERAL ASSESSMENT OF ILLNESS.— This is very important and should be assessed in the first opportunity. In case of severely ill patients, one should cut down the wastage of time to know other less important findings. The doctor should hasten into the treatment after rapidly going through the local examination to come to a probable diagnosis and to find out those signs which may help him to institute proper treatment.

MENTAL STATE and INTELLIGENCE.— In case of chronically ill patients, the doctor should always assess the mental state and intelligence of the individual. An intelligent patient will give a very good history on which the doctor can rely. On the other hand the doctor should not rely wholly on the history from the patient with very low intelligence.

Mental State (Level of consciousness) is of particular importance in a head injury patient. There are 5 stages of level of consciousness — (a) Fully conscious with perfect orientation of time, space and person. (b) Fully conscious with lack of orientation of time and space. (c) Semiconsciousness (drowsy) but can be awakened. (d) Unconscious (stupor), but responding to painful stimuli. (e) Unconscious (coma) and not responding to painful stimuli. In all cases clinician must be well aware of the mental state of his patient.

BUILD and STATE OF NUTRITION.— Besides the fact that a few endocrine abnormalities become obvious from the build of the patient, a hint to clinical diagnosis may be achieved from a look on the build of the patient. As for example, a cachectic patient suffering from an abdominal discomfort with a lump, is probably suffering from carcinoma of some part of the G.I. tract.

ATTITUDE.— This is very important and gives valuable information to arrive at a diagnosis. Patients with pain due to peritonitis lie still, whereas patients with colicky pain become restless and toss on the bed. Meningitis of the neck will show neck retraction and rigidity. An old patient after a fall, when lies helplessly with an everted leg, possibility of fracture of the neck of the femur becomes obvious.

GAIT.— This means the way the patient walks. Abnormal gait occurs due to various reasons — (a) Pain; (b) Bone and joint abnormalities; (c) Muscle and neurological diseases; (d) Structural abnormalities and (e) Psychiatric diseases. 'Waddling gait' is typical in bilateral congenital dislocation of hip and bilateral coxa vara. 'Trendelenburg gait' is typically seen in muscle dystrophies, poliomyelitis, unilateral coxa vara, Perthes' disease and different arthritis of the hip.

FACIES.— The face is the 'mirror of the mind' and the eyes are the 'windows of the mind'. Just looking at the face good clinician can assess the depth of the disease and effect of his treatment. The general diagnostic importance of the facies is enormous. Typical 'Facies hippocratica' in generalized peritonitis, 'Risus Sardonicus' in tetanus, 'Mask face' in Parkinsonism, 'Moon Face' in Cushing's syndrome and 'Adenoid facies' in hypertrophied adenoids are very characteristic and once seen is difficult to forget.

DECUBITUS.— This means the position of the patient in bed. This is sometime informatory, e.g. in cerebral irritation the patient lies curled upon his side away from light.

COLOUR OF THE SKIN.— So far as the colour of the skin is concerned, broadly the students should try to find out the presence of pallor, cyanosis or jaundice.

PALLOR of the skin is seen in massive haemorrhage, shock and intense emotion. Anaemic patients are also pale. One should look at the lower palpebral conjunctiva, mucous membrane of the lips and cheeks, nail beds and palmar creases for pallor.

CYANOSIS i.e. bluish or purplish tinge of the skin or mucous membrane which results from the presence of excessive amount of reduced haemoglobin in the underlying blood vessels. It may be either due to poor perfusion of these vessels (peripheral cyanosis) or due to reduction in the oxygen saturation of arterial blood (central cyanosis). For cyanosis to be observed, there must be a minimum of 5 g/dl of reduced haemoglobin in the blood perfusing the skin. So cyanosis is not detectable in presence with severe anaemia. *Peripheral cyanosis* is due to excessive reduction of oxyhaemoglobin in the capillaries when the blood flow is slowed down. This may happen on exposure to cold (cold-induced vasoconstriction). It is also seen in patients with reduced cardiac output when differential vasoconstriction diverts blood flow from the skin to other more important organs e.g. the brain, the kidney etc. Peripheral cyanosis is looked for in the nail bed, tip of the nose, skin of the palm and toes.

Central cyanosis occurs from inadequate oxygenation of blood in the lungs. This may be due to diseases in the lungs or due to some congenital abnormalities of the heart where venous blood by-passes the lung and is shunted into the systemic circulation. For central cyanosis one should look at the tongue and other places as mentioned above. The tongue remains unaffected in peripheral cyanosis. Very occasionally cyanosis may be due to the presence of abnormal pigments e.g. methaemoglobin or sulphaemoglobin in the blood stream. In these cases arterial oxygen tension is normal. This may occur due to taking of drugs such as phenacetin. Carbon monoxide poisoning produces a generalized cherry-red discolouration.

JAUNDICE is due to icteric tint of the skin, which varies from faint yellow of viral hepatitis to dark olive greenish yellow of obstructive jaundice. This is due to the presence of excess of lipid-soluble yellow pigments (mostly the bile pigments) in the plasma. The places where one should look for jaundice are — (i) sclera of the eyeball — for this the patient is asked to look at his feet when the surgeon keeps the palpebral fissure wide open by pulling up the eyelid, (ii) nail bed, (iii) lobule of the ear, (iv) tip of the nose, (v) under-surface of the tongue etc. When the jaundice is deep and long standing, a distinct greenish colour becomes evident in the sclerae and in the skin due to the development of appreciable quantities of biliverdin. Scratch marks may be prominent in the skin in obstructive jaundice as a result of pruritus which is believed to be due to retention of bile acids.

Jaundice may be confused with hypercarotinaemia in which yellow pigment of carotene is inequally distributed and is particularly seen in the face, palms and soles but *not in the sclerae.* Such hypercarotinaemia may occur occasionally in vegetarians and in those who eat excessive quantities of raw carrot.

SKIN ERUPTION.— Under this heading comes macules, papules, vesicles, pustules, wheals etc.

Macules — are alterations in the colour of the skin, which are seen but not felt. They may be due to capillary naevi or erythemas which disappear on pressure, whereas purpuric macules do not blanch when pressed. *Papules* — are solid projections from the surface of the skin. It may be epidermal papule, e.g. a wart or a dermal papule, which will become less prominent if the skin is stretched, e.g. a granuloma of tuberculosis, reticulosis or sarcoidosis. *Vesicles* — are elevations of horny layer of the epidermis by collection of transparent or milky fluid within them. *Pustules* — are similar elevations of the skin as vesicles, but these contain pus instead of fluid within them. *Wheal* — is a flat oedematous elevation of the skin frequently accompanied by itching. It is the typical lesion of urticaria and may be seen in sensitive persons provoked by irritation of the skin.

PULSE.— This is an important index of severity of illness. Pulse gives a good indication as to the severity of acute appendicitis and thyrotoxicosis. Generally it gives a good indication of the cardio-vascular condition of the patient. Abnormalities of the heart and the vascular system, e.g. hypertension and hypotension are also revealed in pulse. Shock, fever and thyrotoxicosis are a few conditions, which are well reflected in pulse. Following points are particularly noted in pulse :— (a) *Rate* — fast or slow, (b) *Rhythm* — regular or irregular, (c) *Tension* and *force* which indicate diastolic and systolic blood pressure respectively, (d) *Volume* which indicates pulse pressure, (e) *Character* e.g. Water-hammer pulse of aortic regurgitation or thyrotoxicosis, pulsus paradoxus of pericardial effusion etc. and (f) *condition of arterial wall* e.g. atherosclerotic thickening etc.

RESPIRATION.— The students will gradually learn the importance of respiration as a finding not only for diagnosis, but also to assess the condition of the patient under anaesthesia and in

early postoperative days. Tachypnoea (fast breathing) is seen in fever, shock, hypoxia, cerebral disturbances, metabolic acidosis, tetany, hysteria etc. Slow and deep respiration is an ominous sign in cerebral compression. Also note if there is any irregular breathing e.g. Cheyne-Stokes respiration. In Cheyne-Stokes respiration there is gradual deepening of respiration or overventilation alternating with short periods of apnoea.

TEMPERATURE.— This is normally taken in the mouth or in the axilla of the patient. The temperature of the mouth is about 1°F higher than that of the axilla. Fever or high temperature is come across in various conditions, which the students will be more conversant in medical ward. But broadly, the students should know that there are three types of fever — the continued, the remittent and the intermittent. When the fever does not fluctuate for more than 1°C during 24 hours, but at no time touches the normal, it is described as *continued*. When the daily fluctuations exceed 2°C it is *remittent* and when the fever is present only for a few hours during the day, it is called *intermittent*. When a paroxysm of intermittent fever occurs daily, it is called *quotidian*, when on alternate days it is called *tertian* and when two days intervene between the consecutive attacks, it is called *quartan*.

B. **LOCAL EXAMINATION.**— This is the most important part in the physical examination, as a careful local examination will give a definite clue to arrive at a diagnosis. By 'Local examination' we mean examination of the affected region. This should be done by **inspection** (looking at the affected part of the body), **palpation** (feeling of the affected part by the hands of the surgeon), **percussion** (listening to the tapping note with a finger on a finger placed on the affected part), **auscultation** (listening to the sounds produced within the body with the help of a stethoscope), **movements** (of the joints concerned), **measurement** (of the part of the body concerned) and **examination of the lymph nodes** draining the affected area. Detailed description of these examinations are discussed in subsequent chapters.

Inspection of the part should be carried out after complete exposure. *It should be compared with the corresponding normal side*, whenever possible. The importance of proper inspection cannot be overemphasized, as many of the surgical conditions can be diagnosed by looking at it with well-trained eyes. It is said that eyes do not see what mind does not know. So a thorough knowledge of the whole subject is essential before one can train one's eyes for such good inspection.

Palpation will not only corroborate the findings seen in inspection, but also added informations with trained hands may not require any further examination to come to a diagnosis.

Percussion and **Auscultation** are not so important as in the medical side for clinical diagnosis of surgical diseases. These are only important in a few surgical conditions, which will be discussed later in appropriate chapters.

Movements and **Measurements** are important particularly in orthopaedic cases, in fractures and in injuries of different nerves.

Local examination is never complete without the **examination of the draining lymph nodes.** More often than not the students forget to do this valuable examination and fail to diagnose many important cases.

C. **GENERAL EXAMINATION.**— In chronic cases, one should always examine the patient as a whole, after completing the local examination. In acute cases, this examination may be omitted to save the valuable time. But even in acute cases, certain general examinations should be carried out either for anaesthetic sake or for treatment point of view. General examination is required mainly for the following purposes —

1) *For the diagnosis and differential diagnosis.*— For example, in case of retention of urine, one should examine the knee and ankle jerks and pupillary reflexes (Argyll Robertson pupil) to come to a diagnosis of Tabes dorsalis. Similarly examination of the chest or spine should be carried out in an otherwise obscure abdominal pain to find out basal pleurisy or caries spine as the cause of pain. Sometimes the patient complains of pain in the knee when the pathology lies in the hip joint. Cases are on record when teen-aged boy with the complain of pain in the right iliac fossa was referred to the hospital by the general physician as a case of acute appendicitis. Only after examination of the scrotum, the surgeon found torsion of the testis as the cause of pain and not appendicitis.

2) *For selecting the type of anaesthetic.*— The anaesthetist should always examine the patient generally, particularly the heart and lungs to select the proper anaesthetic. Sometimes the operation should be performed under local anaesthesia in old and cardiac patients.

3) *To determine the nature of the operation.*— In case of an inguinal hernia, one should examine the chest to exclude a cause of chronic cough, for enlarged prostate or for stricture of urethra as an organic cause of an obstruction to the outflow of urine and to exclude constipation as cause for increased abdominal pressure to initiate hernia. So patients with these conditions, if operated on, will definitely come back with recurrence of hernia. At the same time, the surgeon should look for the tone of the abdominal muscles to determine whether herniorrhaphy or hernioplasty will give the best result.

4) *To determine the prognosis.*— In a case of gastric cancer, if general examination reveals involvement of the supraclavicular glands, the prognosis is obviously grave. Similarly cancer of the breast, if shows secondary metastases in bones and lungs, is considered to be in the last stage.

A list is given below to remember the points to be examined under the heading of 'general examination' :

Head and **neck**

1) Cranial nerves — particularly the 3rd, 4th, 5th, 6th, 7th, 9th, 11th and 12th cranial nerves should be examined.

2) Eyes.— Tests are done to know the visual field, condition of the conjunctiva and pupils (equality, reaction to light and accommodation reflex), movements of the eye and ophthalmic examination of the fundi.

3) Mouth and pharynx.— Teeth and gum, movement of soft palate, the tongue and its undersurface, tonsils and lips for colour, pigmentation (seen in Peutz-Zegher syndrome) and eruptions.

4) Movements of the neck, neck veins and lymph nodes of the neck, carotid pulses and the thyroid gland.

Upper limbs

I) General examination of the arms and hand with particular reference to their vascular supply and nerve supply (Power, tone, reflexes and sensations). 2) Axillae and lymph nodes. 3) Joints. 4) Finger nails — clubbing or koilonychia.

Thorax

1) Type of chest. 2) Breasts. 3) Presence of any dilated vessels and pulsations. 4) Position of the trachea. 5) Apex beat. 6) Lungs — as a whole, i.e. inspection, palpation, percussion and auscultation. 7) The heart should be examined as a whole, i.e. palpation, percussion and auscultation.

Abdomen

1) Abdominal wall — position of the umbilicus, presence of scars, dilated vessels etc. 2) Abdominal reflexes. 3) Visible peristalsis or pulsation. 4) Generalized palpation, percussion and auscultation. 5) Hernial orifices. 6) Genitalia. 7) Inguinal glands. 8) Rectal examination. 9) Gynaecological examination, if required.

Lower limbs

1) General Examination of legs and feet — with particular reference to the vascular supply and nerve supply (Power, tone, reflexes and sensation). 2) Varicose vein. 3) Oedema. 4) Joints.

Examination of the external genitalia

Sputum, vomit, urine, stool should be examined by naked eye and under microscope, if required.

PROVISIONAL DIAGNOSIS

At this stage the clinician should be able to make a provisional diagnosis. He should also keep in mind the differential diagnosis. He will now require a few investigations to come to the proper clinical diagnosis. The students should know how to diagnose common diseases first and then he should think for possibility of rare diseases. A word of the caution will not be irrelevant here that *'if you diagnose a rare disease, you will be rarely correct'*.

SPECIAL INVESTIGATIONS

Besides the routine examination of the blood, urine and stool, a few special investigations depending upon the provisional diagnosis will be required to arrive at a proper diagnosis. These are discussed in details in appropriate chapters.

CLINICAL DIAGNOSIS

After getting the reports of special investigations, the clinician should be able to give proper clinical diagnosis. By this we mean that not only the ailing organ is identified, but the type of pathological process at work and its extent in different directions is also understood. As for example, in carcinoma of the breast, one should mention under this heading the clinical stage of the disease and the various structures involved in metastasis. Similarly in case of inguinal hernia, the clinician should not only mention that whether it is direct or indirect, reducible or irreducible, but also should mention its content — either the intestine or omentum or a portion of urinary bladder.

TREATMENT

The students should record under this heading the details of medical treatment and the surgical treatment which the patient has received. While writing medical treatment the students should clearly mention the drugs given to the patient, their doses and duration of the treatment. In surgical treatment they should clearly mention the type of anaesthesia given and type of operation performed. In the operation note, the students should describe the operation under following headings :—

(i) Type of anaesthesia and anaesthetics used; (ii) Name of the anaesthetist; (iii) Name of

the surgeons; (iv) Position of the patient on the operation table; (v) The type of incision made; (vi) Technique of operation; (vii) Closure; (viii) Drainage — given or not.

PROGRESS

Daily progress of the patient starting from the time the patient came out of the operation theatre should be clearly noted. Students should also mention if any investigation performed during the postoperative period, the dressings done during the period, condition of the wound etc.

FOLLOW-UP

This resumes when the patient is discharged from the hospital and extends till he starts his normal active life. The students should learn how to make a discharge certificate mentioning in nutshell the diagnosis, special investigations performed, the treatment received and the postoperative advice. He should also mention the date when the patient should report to the outpatient clinic to let the surgeon know his progress and his complaints. Now the students should make a record of the days the patient came for follow-up and the advice given by the surgeon.

TERMINATION

To terminate the history sheet of the patient, the students should mention whether the patient was completely cured when his follow-up period ended or the patient was relieved of his symptoms but not cured or whether the patient died during his stay in hospital or in follow-up period. In case of death, the student should mention the cause of death and also make a note of the result of the postmortem examination, if carried out.

Chapter

2 A FEW SPECIAL SYMPTOMS AND SIGNS

A few symptoms and signs are described in this chapter which I feel deserve special mention and are not thoroughly dealt with elsewhere.

PAIN

This is a very common symptom and all of us must have experienced pain sometime or the other. The word 'pain' is derived from Latin word 'poena' which means penalty or punishment. Pain should not be confused with 'tenderness'. The patient feels 'pain', while the doctor elicits 'tenderness'. Tenderness means pain which occurs in response to a stimulus given by somebody (usually from the doctor). So pain is a symptom and tenderness is a sign. Basically four types of pain are noticed— 1. Superficial, 2. Segmental, 3. Deep or visceral and 4. Psychogenic or central.

1. SUPERFICIAL PAIN.— This occurs due to direct irritation of the peripheral nerve endings in the superficial tissue. Such irritation may be by chemical or mechanical or thermal or electrical. The superficial pain is sharp and can be pointed with a finger tip.

2. SEGMENTAL PAIN.— This occurs due to irritation of a sensory nerve trunk or root. This is located in a particular dermatome of the body supplied by the affected sensory nerve trunk or root.

3. DEEP PAIN.— This pain occurs due to irritation of deep structures of the body e.g. the deep fascia, the muscles, the tendons, the bones, the joints and the viscera. The pain sensation from the affected structure is conveyed to the brain either by somatic nerve or by the autonomic nervous system. The deep pain is vague compared to the superficial pain and may be one of the various types which are described below. The deep pain is vaguely localized in comparison to the superficial pain. The deep pain may be referred to some other area of the body due to common area of representation in the spinal cord (supplied by the same segment). The deep pain may cause involuntary spasm of the skeletal muscles supplied by the same spinal cord segment.

4. PSYCHOGENIC PAIN.— In this condition pain arises from the brain, which may be a functional pain either emotional or hysterical or due to lesions in the thalamus or spinothalamic tract or due to causalgia.

Majority of the surgical patients come to the surgeon with the complaint of pain. A careful history must be taken about pain so that it may help to reach the diagnosis. If careful history is not taken about pain, it may frequently confuse the clinician to make wrong diagnosis. The followings are the various points which must be asked to know the cause of pain.

Original site of pain.— The patient should be asked to locate the site of pain with his finger tip. It must be remembered that when the patient comes to the surgeon the site of pain

may have changed. But it is highly important to know the original site of pain — 'where did the pain start ?' In many cases, particularly in abdominal pain, the patient may not be able to point with a finger tip, instead he uses his whole hand. So exact localization may not be possible particularly in case of deep pain originating in thoracic or abdominal viscus. A patient with acute appendicitis when brought to the surgeon may locate pain at the right iliac fossa. But when he is asked 'where did the pain start ?' His answer is often 'in the umbilical region' and now it is in the right iliac fossa. This simple history is highly important to come to the diagnosis of acute appendicitis and this history only differentiates this condition from many others.

Origin and mode of onset.— It may be possible to know from the patient the time of onset of pain and mode of onset. A long continued pain with insidious onset indicates chronic nature of the disease e.g. chronic pancreatitis, chronic peptic ulcer, subacute appendicitis etc. Whereas recent onset of pain with sudden arrival indicates acute nature of the disease e.g. acute pancreatitis, acute appendicitis, rupture of aneurysm etc.

Enquire into 'how did the pain start ?' When the pain starts after a trauma the cause of the pain must be traumatic e.g. a sprain, or a fracture or dislocation or rupture of kidney or rupture of liver etc.

Severity.— This of course is not so important to come to a diagnosis. Individuals often react differently to pain. A severe pain to one person may be simple dull ache to another. However a few diseases are known to produce severe pain e.g. acute pancreatitis, biliary colic, perforated peptic ulcer, dissecting aneurysm of aorta etc.

Nature of the pain.— It is of great importance to know the character or nature of the pain. It often helps to come to a diagnosis. On the other hand patients may find it very difficult to describe the nature of their pain. The various types of pain are described below :—

(i) VAGUE ACHING PAIN.— This is a mild continuous pain which has no other specific features.

(ii) BURNING PAIN.— It is almost like a burning sensation caused by contact with a hot object. Burning pain is typically experienced in case of peptic ulcer or reflux oesophagitis.

(iii) THROBBING PAIN.— It is a type of throbbing sensation which is typically felt in case of pyogenic abscesses.

(iv) SCALDING PAIN.— It is also a type of burning sensation which is particularly felt during micturition in presence of cystitis, acute pyelonephritis or urethritis.

(v) PINS AND NEEDLES SENSATION — is typically felt in case of injury to the peripheral sensory nerve. As if pins and needles are being pricked in that area of the skin supplied by the affected sensory nerve.

(vi) SHOOTING PAIN — is typically felt in case of sciatica when pain shoots along the course of the sciatic nerve.

(vii) STABBING PAIN — is a sudden, severe, sharp and short-lived pain. This is typically felt in acute perforation of peptic ulcer.

(viii) CONSTRICTING PAIN — means as if something is encircling and compressing from all directions the relevant part. The pain is often expressed as an iron band tightening around the chest. It is typical of angina pectoris.

(ix) DISTENSION.— This type of pain is experienced in diseases of any structure encircled or restricted by a wall e.g. a hollow viscus. When tension increases inside such hollow viscus it causes a pain which is typically described by the patient as a feeling of distension or 'tightness'.

(x) COLIC.— A colicky pain occurs when the muscular wall of a hollow tube is attempting to force certain content of the tube out of it. A colicky pain has two features. Firstly the pain

appears suddenly and it goes off as suddenly as it came. Secondly the pain is of griping nature, may not be very excruciating and it is often associated with vomiting and sweating. Usually four types of colics are seen in surgical practice—ureteric colic, biliary colic, intestinal colic and appendicular colic.

(xi) TWISTING PAIN — is a type of sensation as if something is twisting inside the body. Such sensation is often felt in case of volvulus of intestine, torsion of testis or ovarian cyst.

(xii) 'JUST A PAIN'.— Often a patient may not describe his pain. He often says that 'it is just a pain' and cannot describe the nature of the pain.

Progression of the pain.— Now the patient should be asked 'how is the pain progressing ?' (a) The pain may begin in a weak note and gradually reaches a peak or a plateau and then gradually declines. (b) It may begin at its maximum intensity and remains at this level till it disappears. (c) The severity of pain may fluctuate — its intensity may increase and decrease at intervals. This should be depicted in a graph.

Duration of the pain.— Duration of pain means the period from the time of onset to the time of disappearance. Characteristically the griping pain of intestinal colic is felt for less than a minute. The pain of angina of effort ceases within 5 minutes of resting, whereas that of a myocardial infarct may continue for hours.

Movements of pain.— Pain may move from one place to the other and 3 types of such movements are noticed — (i) radiation, (ii) referred and (iii) shifting or migration of pain.

(i) RADIATION OF PAIN.— This means extension of the pain to another site whilst the original pain persists at its original site. The radiation of pain has almost the same character. The typical example is when a duodenal ulcer penetrates posteriorly. The pain in the epigastrium remains but at the same time the pain spreads or radiates to the back.

(ii) REFERRED PAIN.— When pain is felt at a distance from its source and there is no pain at the site of disease, it is called a referred pain. Irritation or inflammation of the diaphragm causes pain at the tip of the shoulder. Referred pain occurs when the central nervous system fails to differentiate between visceral and somatic sensory impulses from the same segment. In this case diaphragm is supplied by phrenic nerve (C3, 4 and 5) and the cutaneous supply of the shoulder is also C4 and C5. Diseases of the hip joint may be referred to the knee joint as both these joints are supplied by the articulate branches of the femoral nerve, obturator nerve and sciatic nerve.

(iii) SHIFTING OR MIGRATION OF PAIN.— In this condition pain is felt at one site in the beginning and then the pain is shifted to another site and the original pain disappears. This occurs when an abdominal viscus becomes diseased, the original pain is experienced at the site of distribution of the same somatic segment. But when the parietal peritoneum overlying the viscus is involved with the disease, the pain is experienced at the local site of the viscus. In case of acute appendicitis pain is first felt at the umbilical region which is also supplied by the T9 and 10 as the appendix, but later on pain is felt in the right iliac fossa when the parietal peritoneum above the appendix becomes inflamed.

Special times of occurrence.— The patient should be asked if there is any special time of appearance of pain. Often patients with acute appendicitis give history that they feel pain on waking up in the morning, in fact pain awakens the patient. In case of duodenal ulcer pain is often complained at 4 p.m. in the afternoon and in the early morning at about 2 to 3 a.m. This is 'hunger pain' and felt when food has passed out of the stomach and the stomach is empty. Migraine may occur especially in the morning, either every week end or during menstruation. Headache of frontal sinusitis is often at its peak a few hours after rising.

Periodicity of pain.— This is often characteristic in certain diseases. Sometimes an interval of days, weeks, months or even years may elapse between two painful attacks. Particularly in peptic ulcer, a periodicity is noticed and pain recurs in episodes lasting for 1 to several weeks, interspersed with pain free intervals of weeks or months. Trigeminal neuralgia often shows such periodicity and pain free intervals often last for months.

Precipitating or aggravating factors.— This history is of great importance to come to a diagnosis. Alimentary tract pains may be made worse by eating particular types of foods. Musculoskeletal pains are often aggravated by joint movements. But certain typical factors should be given high consideration. Pain of appendicitis often gets worse on jolting, running and moving up the stairs. These movements also aggravate the pain of ureteric or vesical calculus. Pain of reflux oesophagitis often becomes aggravated when the patient stoops. Pain of acute pancreatitis becomes worse when the patient lies down. Pain of peptic ulcer gets worse by ingestion of hot spicy food and drink. Pain of disc prolapse often gets aggravated on lifting weight from stooping position.

Relieving factors.— Many pains subside spontaneously and the patient's statement must be carefully considered. Pain of peptic ulcer is often relieved by alkalies and antacids in 5 to 15 minutes but such relief neither appears immediately nor after 1 hour. Pain of acute pancreatitis is sometimes relieved to certain extent by sitting up in the bed in leaning forward position and the patient prefers to sit up even althroughout the night. Pain of reflux oesophagitis due to sliding hiatus hernia is often relieved in propped up position. Colicky pain of intestinal obstruction often gets relieved on passing flatus. In perforative peritonitis any movement of the abdomen causes aggravation of pain and the patient gets some relief if he lies still.

Associated symptoms.— Severe pain may be associated with pallor, sweating, vomiting and increase in pulse rate. Colicky pain is often associated with sweating, vomiting and clammy extremities. Migraine is often preceded by visual disturbances and accompanied by vomiting. Pain of acute pyelonephritis may be associated with rigor and high fever. Ureteric colic may be accompanied by haematuria. Biliary colic is often associated with presence of jaundice and pale stool. Excessive sweating and cold extremities are very common associated symptoms of leaking abdominal aneurysm, dissecting aneurysm, haemorrhagic pancreatitis etc.

Conclusion.— So it is clear now that pain is a very important symptom in surgical cases and a careful history of the details of the pain may give very valuable clue to come to a diagnosis.

VOMITING

History of vomiting itself is not diagnostic of any condition. Vomiting may occur due to a wide variety of local and systemic disorders. Vomiting may occur from simple gastric irritation. Vomiting may occur in functional and organic disorders of the nervous system e.g. fear, motion sickness, migraine, labyrinthine disorders, meningitis and intracranial tumour. Vomiting may occur from severe pain as in any colic. Amongst systemic conditions pregnancy, renal failure and metabolic disorders e.g. diabetic ketoacidosis or hyperparathyroidism are important. A few drugs may cause vomiting e.g. digoxin, morphine etc.

In surgical practice vomiting may occur in peptic ulceration, pyloric stenosis (gastric outlet obstruction), acute cholecystitis, acute pancreatitis and intestinal obstruction. In some cases of intracranial tumour the vomiting is an important symptom.

Enquiry should be made about the frequency of vomiting, the time of day at which it occurs and also about the taste, colour, quantity and smell of the vomitus.

The vomitus may be of the following types —

1. The vomitus may contain recent ingested material. Such vomitus may be acid in reaction when it is probably due to gastric outlet obstruction. If such vomitus is not acid in reaction the cause may be achalasia of the oesophagus, benign or malignant stricture of the oesophagus.
2. Vomit may contain bile to give yellow colouration of the vomitus.
3. Vomit containing upper small bowel contents may be green in colour.
4. Faeculent vomitus contains lower small bowel contents, brown and of faecal odour. This is characteristic of advanced low small bowel obstruction.
5. Vomit may contain faeces. This may be due to abnormal communication between the stomach and transverse colon (gastrocolic fistula as a complication of gastric ulcer).
6. Vomit containing blood may be of various types. The bleeding may be copious. The vomit may present pure blood or clots. Such bleeding may come from gastric ulcer or oesophageal varices. The blood in the vomit may be altered to blackish or dark brown in colour in contact with gastric juice. This is due to conversion of haemoglobin to haematin. This altered blood gives the vomitus a 'coffee-ground' appearance. Medicine containing iron or red wine may give rise to this type of vomitus. It must be remembered that blood in the vomit may have come from the nose or lungs which have been swallowed.

ITCHING

Itching or pruritus is not a very significant symptom so far as surgical conditions are concerned. The various causes of pruritus are mentioned below —

1. SKIN DISEASES.— Certain skin diseases cause pruritus and the patients should be advised to take physician's advise to cure these. Before any operation is performed such skin conditions must be cured first until and unless the surgical condition deserves immediate operative interference. These skin conditions are urticaria, scabies and eczema.
2. GENERALIZED DISEASES.— Persistent pruritus in the absence of obvious skin disease may be due to certain generalized diseases e.g. thyrotoxicosis, obstructive jaundice, renal failure (uraemia), hepatic failure, lymphoma and other malignancies. However in old people with dry skin pruritus is common and is of no systemic significance. Diabetes mellitus is known to produce pruritus vulvae and pruritus ani.
3. LOCAL IRRITATION.— Certain conditions of the anal canal may cause pruritus of the perianal region. These are discussed in the chapter of 'Examination of Rectum and Anal Canal'. Local irritation by dirty under-clothes may also cause pruritus from local irritation. Fleas and mosquitoes also cause local irritation for itching. Threadworm is particularly known to cause pruritus ani.
4. DRUG INDUCED.— Certain drugs may cause pruritus. Majority of these cases are due to allergic hypersensitivity and vary from person to person.

HICCUP

Hiccup is caused by spasmodic contractions of the diaphragm. Majority of these hiccups are of no significance and have been experienced by almost all of us without the presence of any organic disease. Three groups of hiccups are of some surgical importance and deserve mention. *The first group* occurs in *early postoperative period* and signifies upward pressure on the undersurface of the diaphragm due to increased abdominal pressure. This is often caused by dilated stomach or dilated coils of small intestine due to paralytic ileus or due to some intestinal

obstruction. Obviously such hiccup requires introduction of a nasogastric tube and aspiration through such tube will cause diminution of intra-abdominal pressure and hiccup is relieved. Sometimes injection of pethidine or siquil may be required.

The *second group* is often due to peritonitis involving the diaphragmatic peritoneum. This sometimes causes repeated hiccup.

The *third group* is a common accompaniment of advanced renal failure. So in any case of hiccup the patient should be asked to protrude his tongue and brown dry tongue should indicate renal failure and immediate investigations should be performed in this line.

ABNORMAL SUPERFICIAL VEINS (VISIBLE VEINS)

When venous pressure is within normal limits with the head resting on a pillow, the external jugular vein is either invisible or visible only for a short distance above the clavicle. Only when there is raised venous pressure, *engorgement* of the external jugular vein occurs. Bilateral engorgement of neck veins indicates too much intravenous fluid infusion or myocardial failure. Unilateral engorgement may be due to pressure on the vein by enlarged lymph nodes, a tumour or a subclavian aneurysm. Bilateral or unilateral engorgement may also be due to presence of retrosternal goitre or due to something obstructing the superior vena cava.

Radiating veins from the umbilicus in the abdominal wall indicates obstruction to the portal venous system and this is known as the *caput medusae.*

Sometimes engorged superficial veins may be seen in the flank extending from the axilla to the groin. These are called inguino-axillary veins and engorgement of such vein indicates obstruction of the inferior vena cava. In this case veins of both sides will be prominent. When vein of one side is affected, it indicates blockage of the common iliac or external iliac vein of that side.

For *varicose veins* of the lower limbs see chapter 7.

TONGUE

Examination of the tongue is quite important. Importance is probably much more in case of medical diseases, yet there is quite a big list of surgical cases in which examination of tongue is quite important.

The patient is always asked in 'general survey' to protrude the tongue for examination. *Inability to protrude the tongue* is due to ankyloglossia, tongue-tie (in case of children) or advance carcinoma of the tongue involving the floor of the mouth (in old age). While protruding the tongue the tongue may *deviate to one side.* Such deviation is due to hemiplegia of the tongue due to involvement its motor nerve supply the hypoglossal nerve mostly by carcinomatous lesion.

The tongue may be quite large *(macroglossia).* Such large tongue may be due to acromegaly, cretinism (in children), myxoedema, lymphangioma, cavernous haemangioma and amyloidosis.

Tremor of the tongue after its protrusion is a very characteristic feature of primary thyrotoxicosis though delirium tremens and perkinsonism are other rare causes.

COLOUR of the tongue is highly important. Its particularly reach blood supply with a capillary network close to the surface has made the colour of the tongue dark red. Pale tongue (pallor) is seen in severe anaemia. Discolouration of the tongue may be due to ingestion of colour foods e.g. lozenge, chocolates and certain fruits (black cherries or black berries). For other causes of pathological change of colour see chapter 24.

Moistness is an indication of the state of hydration of the body. Dry tongue means the water content of the body is below standard and the patient is dehydrated. A dry, brown tongue may be found in later stages of severe illness, in acute intestinal obstruction and in advanced uraemia.

Furring on the dorsum of the tongue is of little value as an indication of disease. It is often found in heavy smokers. A brown fur, the 'black hairy tongue' is due to a fungus infection. Furring may also result from local infection of the mouth (stomatitis), local infection of nose or throat (tonsillitis) or from the infection of the lungs (bronchitis or pneumonia).

Examination of papillae of the tongue is quite important. Generalized atrophy of papillae which produces a smooth and bald tongue is characteristic of vitamin B12 deficiency, iron-deficiency anaemia or certain gastrointestinal disorders. In chronic superficial glossitis, whitish opaque areas of thickened epithelium (known as leukoplakia) are seen separated by intervening smooth and scarred areas, with no normal papillae seen on the dorsum of the tongue. In congenital fissuring the papillae are normal but the surface is interrupted by numerous irregular folds which run horizontally. In median rhomboid glossitis a lozenge-shaped area of loss of papillae and fissuring is seen in the midline anterior to the foramen caecum. It feels nodular and must be distinguished from lingual thyroid or carcinoma.

The sides and undersurface of the tongue should always be examined with a spatula to retract the cheeks and lips. Look for ulcers, which are often seen at the margins of the tongues. For details of findings of these examinations see chapter 24.

NAILS

Examination of the nails is important, though more so in medical cases. Well manicured nails are things of beauty and social asset. Injury is the most common cause of changes in the nails and may permanently impair their growths. A transverse groove at a similar level of each of the nails indicates a systemic disturbance and previous illness. Splinter haemorrhages under the nails are manifestations of systemic vasculitis caused by immune complexes which may cause haemorrhages in the skin and retina also. Multiple splinter haemorrhages suggest infective endocarditis. Long standing iron deficiency may make the nails brittle, then flat and ultimately spoon shaped *(koilonychia)*, so this type of nail is seen in advanced cases of anaemia and in Plummer-Vinson syndrome. Nails may be pitted in psoriasis which may also discolour and deform the nails which is often confused with fungal infection. Small isolated white patches are often seen in the nails of normal persons. Whitening of the nail bed *(Terry's nail)* is a manifestation of hypoalbuminaemia. Bitten nails suggest anxiety neurosis. In *clubbing of the fingers*, the tissues at the base of the nail are thickened and the angle between the nail base and the adjacent skin of the finger is obliterated. There is swelling of the terminal phalanges which is due to interstitial oedema and dilatations of the arterioles and capillaries. One can elicit fluctuation of the nail bed. The nail itself loses its longitudinal ridges and becomes convex from above downwards as well as from side-to-side. In advanced degree of clubbing there is swelling of the subcutaneous tissue over the base of the nail which causes the overlying skin to become tense, shiny and red. Gross degree of clubbing

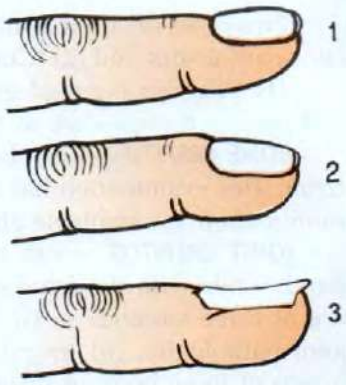

Fig.2.1.— 1.— Normal nail; 2.— Clubbing; 3.— Koilonychia.

is found in association with severe chronic cyanosis, in congenital heart disease and in association with chronic suppuration within the chest e.g. bronchiectasis and empyema. Lesser degree of clubbing may be found in carcinoma of the lung, pulmonary tuberculosis and in certain chronic abdominal conditions e.g. polyposis of the colon, Crohn's disease and ulcerative colitis. Clubbing is also an important sign of subacute bacterial endocarditis when it may be associated with Osler's nodes, which are transient tender swellings in the pulp of the fingers and toes. *Nail bed infarcts* may occur in vasculitis especially in systemic lupus erythematosus and in polyarteritis.

PITTING ON PRESSURE

To confirm a suspicion of a subcutaneous oedema, the cardinal sign is the indentation or *pitting* made on the skin by firm pressure maintained for a few seconds by the examiner's fingers or thumb. The pitting may persist for several minutes until it is obliterated by slow reaccumulation of the displaced fluid. So 'pitting on pressure' is a sign to detect subcutaneous oedema. Oedema may be generalized or local. *Generalized oedema* is often due to disorder of the heart, kidneys, liver, gut or diet. *Local oedema* is more of surgical importance and may be due to venous or lymphatic obstruction, allergy or inflammation. Oedema due to endocrine disorders particularly myxoedema is also local oedema. Pretibial myxoedema may be occasionally seen in thyrotoxicosis patients who are overzealously treated so that the patient is now symptom-free but presents with pretibial myxoedema (myxoedema in the subcutaneous tissue in front of the tibia) and probably persistent exophthalmos. The venous causes of oedema have been well discussed in the chapter of 'Examination of varicose veins'. Localized oedema from lymphatic causes has been described in the chapter of 'Examination of the lymphatic system". Inflammatory causes are of main concern in surgical practice and in fact any inflammation starting from the bone to the skin causes oedema of variable extent.

CREPITUS

Two types of crepitus are seen in surgical cases — (1) **'Grating sensation'** in case of bone and joint pathologies and (2) 'Crackling sensation' due to presence of air in the subcutaneous tissue.

(1) Various types of grating sensation **(crepitus)** which are come across **in different bone and joint pathologies** are as follows :—

BONE CREPITUS — can be heard when two fragments of a fracture are moved against each other. This examination has almost become obsolete as it induces pain and as facilities of X-ray examination are available almost in all rural health centres.

JOINT CREPITUS — can be obtained when the affected joint is passively moved with one hand, while with the other hand placed on the joint is used to feel the crepitus. Joint crepitus are of three varieties — (i) *Fine crepitations* which are present in many subacute and chronic joint pathologies. (ii) *Irregular coarse crepitations* are detected in osteoarthritis. (iii) *'A click'* is a sign of loose body or displaced cartilage in the joint.

CREPITUS OF BURSITIS.— This is occasionally heard when the lining of the bursa is rough or the fluid in the bursa contains small loose fibrinous particles.

CREPITUS OF TENOSYNOVITIS — is detected in a case of tenosynovitis, the typical example of which is De Quervain's disease at the lateral aspect of the wrist joint. The wrist joint is held tight and the patient is asked to open and close his fist, a crepitus is felt at the lateral aspect of the wrist joint just above radial styloid process at a point where the extensor pollicis brevis

and abductor pollicis longus cross the extensor carpi radialis longus and brevis (see Fig. 15.18).

(2) **Crepitus of subcutaneous emphysema.**— In certain conditions a 'crackling sensation' is felt by the examining fingers due to presence of air in the subcutaneous tissue. If a stethoscope is placed over the area this crackling can be heard better. There are various causes which may give rise to subcutaneous emphysema (air bubbles in the subcutaneous tissue). These are as follows :—

(i) *TRAUMATIC.*— Fracture of ribs may injure the lung and air from the lung may extravasate into the subcutaneous tissue to cause subcutaneous emphysema. Fracture of nasal air sinus may cause subcutaneous emphysema of the face. Compressed air may perforate the thin bone at the apex of a tooth root in case of dental treatment allowing air to escape into the soft tissues. Similarly following tracheostomy such subcutaneous emphysema may be noticed.

(ii) *INFECTIVE.*— In gas gangrene subcutaneous crepitus is always detected.

(iii) *OPERATIVE.*— Air may become imprisoned during closure of an operative wound or traumatic wound. Subcutaneous crepitus from such condition may elude the surgeon to wrongly consider it to be due to gas gangrene.

(iv) *MEDIASTINAL EMPHYSEMA* and later on subcutaneous emphysema of the neck, face and chest wall may complicate rupture of oesophagus (see chapter 31).

FAECES

Examination of the faeces is an important investigation, which is often ignored nowadays. In all bowel disturbance cases, the stool should be examined.

Naked eye inspection.— The following points should be noted — 1. THE AMOUNT.— Note whether the stool is copious or scanty and whether it is liquid or semiformed or formed or hard. 2. COLOUR.— *Black stools* are due to presence of haemorrhage in the intestine or due to ingestion of iron or bismuth. In case of haemorrhage high up in the intestine, the stools become dark, tarry-looking and offensive. *Pale-coloured stools* are due to failure of entrance of bile into the intestine e.g. obstructive jaundice or due to rapid passage of stool through the intestine as in diarrhoea or due to abnormally high content of fat as in malabsorption syndrome or chronic pancreatitis. 3. ODOUR.— Stools of jaundice are very offensive. The stools of acute bacillary dysentery are almost odourless, while those of amoebic dysentery have a characteristic odour like that of semen.

4. ABNORMAL STOOLS.— (i) Slimy stools are due to presence of excess of mucus and are often due to disorder of large bowel.

(ii) Purulent stools are found in severe dysentery or ulcerative colitis.

(iii) Blood in stools may be of different types—*(a) Bleeding from stomach and upper G.I. tract.*— When blood comes from high in the intestinal tract e.g. gastric ulcer or duodenal ulcer, the stools are black and tarry (sticky). This is known as *melaena.* The patients taking iron or bismuth also pass this type of stool but not sticky and are usually well formed. (b) Stools with dark red fragmented clots are seen *when there is bleeding in the small intestine* e.g. from Meckel's diverticulum. But in case of massive gastroduodenal haemorrhage this type of stool may be found. (c) *When bleeding is from large intestine* the stools look dark red and jelly-like. (d) *Blood arising from rectum and anal canal.*— In this case faeces contain bright red blood either mixed or coating it.

(iv) Steatorrhoea.— The stools of steatorrhoea are very large, pale, porridge-like and sometime frothy. These are apt to stick to the sides of lavatory pan and are difficult to flush

away. This is also malodourous. Pancreatic insufficiency is the main cause, but there are also other causes which are described in the appropriate chapters.

(v) Pipe-stem stool.— This is seen in carcinomatous stricture of the rectum particularly in the annulus variety at the rectosigmoid junction.

(vi) Tooth-paste stool.— This is occasionally seen in Hirschsprung's disease. The faeces are expressed as tooth-paste from a tube.

(vii) Meconium.— This is scanty, semiliquid, greenish black, odourless, sticky faeces passed by new-born babies during first 3 days of life. After 7 days the stool becomes pale and putty-like in case of bottle-fed baby and thin yellow paste-type in case of breast-fed baby.

Chapter

3 EXAMINATION OF A LUMP OR A SWELLING

A **'Lump'** is a vague mass of body tissue.

A **'Swelling'** is a vague term which denotes any enlargement or protuberance in the body due to any cause. According to cause, a swelling may be *congenital, traumatic, inflammatory, neoplastic* or *miscellaneous.*

A **'Tumour'** or **'Neoplasm'** is a growth of new cells which proliferate independent of the need of the body. While *benign tumour* proliferates slowly with little evidence of mitosis and invasiveness to the surrounding tissues, *malignant tumour* proliferates fast with invasiveness and mitosis.

HISTORY.— It is recorded as described in Chapter 1 with particular reference to the following points :

1. **Duration.**— 'How long is the lump present there?' That means, you should ask the patient, 'When was the lump first noticed?' In case of congenital swellings, e.g. cystic hygroma, meningocele, they are likely to be present since birth. One thing must be remembered that there is heaven and hell difference between 'The lump was first noticed two months ago' and 'The lump first appeared two months ago'. The former is the patient's finding and very often they feel its existence later than it actually appeared. A painless lump may be present for a long time without the patient's knowledge.

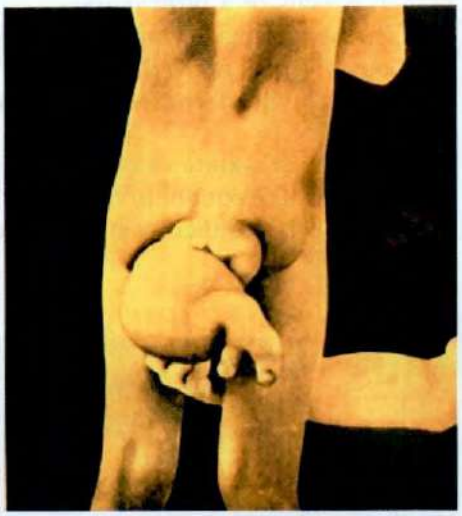

Fig.3.1.— Sacrococcygeal teratoma usually presents since birth. Rudimentary hand is seen in the tumour which develops from the totipotent cells.





Figs.3.2 & 3.3.— Keloids have developed in the scars of vaccination and ear pricks.

Lumps with shorter duration and pain are mostly inflammatory (acute), whereas those with longer duration and without pain are possibly neoplastic (benign). But the swellings with longer duration and with slight pain may be chronic inflammatory swellings whereas swellings with shorter duration may be neoplastic, mostly malignant.

2. **Mode of onset.**— 'How did the swelling start'? It may have appeared just after a trauma (e.g. fractured displacement of the bone, dislocation of the joint or haematoma) or may have developed spontaneously and grown rapidly with severe pain (inflammation) or was noticed casually and the swelling was gradually increasing in size (neoplasm). Sometimes swelling may occur from pre-existing conditions, e.g. keloid may start from a scar of burn or otherwise (Fig.3.2) or even from a pin prick in the ear (Fig. 3.3). Malignant melanoma generally develops from a benign naevus or a birth mark.

The neoplasms are mostly noticed casually and the patient says, 'I felt it during washing'. Or 'Someone else noticed it first and drew my attention.' These swellings are more dangerous and should invite more careful examination than those which are painful and mostly inflammatory or traumatic.

3. **Other symptoms associated with the lump.**— PAIN is by far the most important symptom, which brings the patient to the doctor. Sometimes there may be other symptoms associated with the lump, such as difficulty in respiration, difficulty in swallowing, interfering with any movement, disfiguring etc. The patient will definitely give the history of pain, but he may not give the history of other symptoms. So he must be asked relevant questions to find out if any symptom is associated with the lump.



Fig.3.4.— Keloids have developed from scars of healed boils.

4. **Pain.**— Pain is an important and frequent complaint of traumatic and inflammatory swellings, whereas pain is conspicuously absent in neoplastic swellings particularly in early stage. If the patient complains of pain associated with the lump, the surgeon should know precisely its nature, site and time of onset — whether appeared before the swelling or after it.

Nature of the pain.— Whether the pain is throbbing which suggests inflammation leading to suppuration; or burning; or stabbing i.e. the pain is sudden, sharp, severe and of short duration; or distending; or aching type.

Site.— Sometimes the pain is referred to some other site than the affected one. As for example, in case of affection of the hip joint, the pain may be referred to the corresponding knee joint. But most often the pain is localized to the site of the swelling.

Time of onset.— It is very important to know whether the pain preceded the swelling or the swelling preceded the pain. In the case of inflammation pain always appears before the swelling, but in case of tumours (both benign and malignant) swelling appears long before the

patient will complain of pain. It cannot be impressed too strongly that *most malignant tumours be it in the stomach, kidney, rectum or breast, are painless to start with.* Pain only appears due to involvement of the nerves, deep infiltration, ulceration, fungation or associated inflammation and often indicates inoperability. The only exception is osteosarcoma in which mild pain is usually the first symptom and precedes the appearance of swelling.

5. **Progress of the swelling.**— 'Has the lump changed its size since it was first noticed'? Benign growths grow in size very slowly and sometimes may remain static for a long time. Malignant tumours grow very quickly. Sometimes the swelling suddenly increases in size after remaining stationery for a long period — this suggests malignant transformation of a benign growth. If the swelling decreases in size — this suggests inflammatory lesion. The patient should also be asked whether he has noticed any change in the surface or in consistency of the swelling.

6. **Exact site.**— Mostly the site of the swelling is obvious on inspection. In case of a huge swelling, the surgeon may be confused from which structure the swelling appeared. In these instances the patient may help the surgeon by telling him the exact site from which the swelling originated.

7. **Fever.**— Enquiry must be made whether the patient ran temperature alongwith the swelling or not. This suggests inflammatory swelling. Abscess anywhere in the body may be associated with rise of body temperature — typical examples being axillary abscess, gluteal abscess, ischiorectal abscess etc. Pyogenic lymphadenitis is often associated with fever. Sometimes Hodgkin's disease, renal carcinoma etc. are also associated with peculiar fever.



Fig.3.5.— Multiple swellings of neurofibromatosis (Von Recklinghausen's disease).

8. **Presence of other lumps.**— 'Whether the patient ever had or has any other lump'? Neurofibromatosis, diaphyseal aclasis etc. will always have multiple swellings. Similarly Hodgkin's disease generally shows multiple lymphoglandular enlargements. Abscesses may occur one after the other.

9. **Secondary changes.**— Some swellings present secondary changes such as softening, ulceration, fungation, inflammatory changes etc. The patients should be asked for the secondary changes specifically.

10. **Impairment of function** — particularly of the limb or spine may be associated with a swelling near about. Enquire about the nature of loss of movement and intensity of it and how much of it is due to the swelling. An osteosarcoma near knee joint may cause partial or total loss of knee movement. Similarly a cold abscess from caries spine will cause limitation of movement of the spine.

11. **Recurrence of the swelling.**— If the swelling recurs after removal, this often indicates malignant change in a benign growth or the primary tumour was a malignant one. Certain other swellings are notoriously known to recur e.g. Paget's recurrent fibroid. Cystic swelling may recur if the cyst wall is *not completely* removed.

12. **Loss of body weight.**— Appearance of swelling may be associated with loss of body weight. This indicates that the swelling may be either a malignant growth or a cold abscess with generalized tuberculosis.

13. **Past history.**— This may reveal presence of similar swelling or recurrence of swelling. Past history of syphilis or tuberculosis may offer clue to the present swelling.

14. **Personal history.**— Habit of eating betel leaf, betel nut, slaked lime or tobacco, may be the aetiological factor for growth in the mouth, tongue, cheek or lip. 'Chutta Cancer' of hard palate is seen in women who smoke cigars with the burning ends in their mouths. 'Khaini Cancer' occurs due to mixture of lime and tobacco kept in the gingivolabial sulcus.

15. **Family history.**— This is quite important, as many diseases have familial incidence. Tuberculosis, Von Recklinghausen's disease, many malignant tumours often recur among family members.

PHYSICAL EXAMINATION



Fig.3.6.— A case of sacrococcygeal teratoma.



Fig.3.7.— A case of keloid in its typical position over the chest wall following a small abscess.

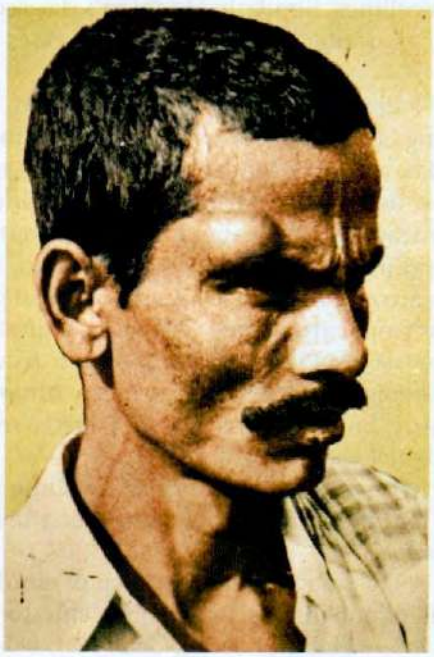

Fig.3.8.— Shows the typical site of the dermoid cyst at the outer canthus of the eye.

GENERAL SURVEY.— When a patient presents with a swelling, the patient should be looked at as a whole. Cachexia or malnutrition may be obvious in first look. The attitude of the patient is also very important. Abnormal attitude may be either due to a swelling like osteosarcoma pressing on the nerve leading to paresis or paralysis of the distal limb or the swelling may be a displaced fracture or dislocation and the limb assumes abnormal attitude due to that. Raised temperature and pulse rate are always associated with inflammatory swelling.

LOCAL EXAMINATION

A. **INSPECTION.**— It must be remembered that a good

clinician always spends some time in observation. The students should make it a practice and should not hasten to touch the swelling as soon as he sees it.

In *inspection* the following points should be precisely noticed :—

1. **Situation.**— A few swellings are peculiar in their positions such as dermoid cysts are mostly seen in the midline of the body or on the line of fusion of embryonic processes e.g. at the outer canthus of the eye — that means on the line of fusion between the fronto-nasal process and the maxillary process (Fig. 3.8) or behind the ear (Fig. 3.9) (post auricular dermoid) — on the line of fusion of the mesodermal hillocks which form the pinna.

One must always note the **extent** of the swelling in vertical and horizontal directions on the case note.



Fig.3.9.— Post-auricular dermoid.

2. **Colour.**— Colour of the swelling sometimes gives a definite hint to the diagnosis. Black colour of benign naevus and melanoma, red or purple colour of haemangioma (Fig. 3.53) (according to whether it is an arterial or venous haemangioma), bluish colour of ranula are obvious and diagnostic.

3. **Shape.**— The shape of the swelling must be noted — whether it is ovoid, pear-shaped, kidney-shaped, spherical or irregular. Sometimes the students, by mistake, utter the term 'circular' to describe the shape of the swelling. A swelling cannot be circular as we do not know about the deeper dimension of the swelling. So it is wiser to say 'spherical' to describe this swelling.

4. **Size.**— To have first hand knowledge about the swelling, one must know the size of the swelling. On inspection, we shall miss the deeper dimension, but shall have the other two dimensions. These must be mentioned clearly in your history sheet the vertical and horizontal dimensions.



Fig.3.10.— Papilloma.



Fig.3.11.— Cauliflower surface of squamous cell carcinoma.

5. **Surface.**— On inspection, it may be difficult to have a clear idea about the surface of the swelling. But in certain swellings, the surface may be very much obvious and diagnostic, e.g. cauliflower surface of squamous cell carcinoma, irregular numerous branched surface of a papilloma etc.

6. **Edge.**— The edge of the swelling may be clearly defined or indistinct. The swelling may be pedunculated or sessile.

7. **Number.**— This is important as this may give a clue to the diagnosis. Some swellings are always multiple, such as diaphyseal aclasis, neurofibromatosis, multiple glandular swellings

etc. Some swellings are more known to be solitary, e.g. lipoma, dermoid cyst etc.

8. **Pulsation.**— The swellings, arising from the arteries, are pulsatile, e.g. aneurysms and vascular growths, such as carotid body tumour. The swellings, which lie just superficial to the artery in close relation with it, will be pulsatile. This pulsation is called *transmitted pulsation*, whereas those which originate from the arterial walls give rise to *expansile pulsation*.

9. **Peristalsis.**— Certain swellings are associated with visible peristalsis e.g. congenital hypertrophic pyloric stenosis. A few swellings cause intestinal obstruction and thus show visible peristalsis.

10. **Movement with respiration.**— Certain swellings arising from the upper abdominal viscera move with respiration e.g. those arising from liver, spleen, stomach, gallbladder, hepatic and splenic flexures of the transverse colon.



Fig.3.12.— Sarcoma of the left humerus interfering with venous return of the upper limb leading to excessive oedema and wrist drop from nerve involvement.

11. **Impulse on coughing.**— The swellings, which are in continuity with the abdominal cavity, the pleural cavity, the spinal canal or the cranial cavity, will give rise to impulse on coughing. The patient is asked to cough and the swelling will be seen giving rise to an impulse while the patient is coughing. In case of children, crying will work as coughing.

12. **Movement on deglutition.**— A few swellings which are fixed to the larynx or trachea move during deglutition e.g. thyroid swellings, thyroglossal cysts, subhyoid bursitis and pre-or paratracheal lymph node enlargement.

13. **Movement with protrusion of the tongue.**— A thyroglossal cyst moves up along with protrusion of the tongue showing its intimate relation with the thyroglossal tract.

14. **Skin over the swelling.**— This will be *red and oedematous*, where the swelling is an inflammatory one. The skin becomes *tense, glossy with venous prominence*, where the swelling is a sarcoma with rapid growth. Presence of a *black punctum* over a cutaneous swelling indicates sebaceous cyst. *Pigmentation* of the skin is seen in moles, naevi or after repeated exposures to deep X-rays. *Presence of scar* indicates either previous operation (when the scar is a linear one with suture marks), injury (a regular scar) or previous suppuration (when the scar is puckered, broad and irregular). Sometimes the skin over a growth looks like the peel of an orange — *Peau d' orange* (Fig. 30.9) which is due to oedematous swelling from blockage of small lymphatics draining the skin. This is most peculiarly seen in breast carcinoma. Presence of *ulcer* on the skin over the swelling is examined as discussed in the next Chapter.

15. **Any pressure effect.**— It is always essential to conclude the inspection by examining the limb distal to the swelling. In many cases this will give suggestion as to what may be the diagnosis. An axillary swelling with oedema of the upper limb means the swelling is probably arising from the lymph nodes. Wasting of the distal limb indicates the swelling to be a traumatic one and the wasting is due to either non-use of the limb or due to injury to the nerves. Sometimes a swelling may be seen in the neck with venous engorgement. This should immediately give rise to suspicion of possibility of retro-sternal prolongation of the swelling, giving rise to venous obstruction.

B. **PALPATION.**— This is the most important part of local examination which will not only corroborate the findings of inspection, but also will explore some other findings, which will give a definite clue to the diagnosis. The students must be very methodical in this examination and follow a definite order, which is given below, so that they would not miss any important examination. The students should also be very gentle in palpation not to hurt the patients and a few swellings may be malignant and may well spread into the system due to reckless handling.

1. **Temperature.**— Local temperature is raised due to excessive vascularity of the swelling. It may be due to infection or due to well-vascularised tumour (e.g. sarcoma).

This examination should be done first in palpation, as manipulation of the swelling during subsequent examinations may increase the temperature without any definite reason. *Temperature of the swelling is best felt by the back of the fingers.* (Fig. 3.13)

2. **Tenderness.**— It must be remembered that this is a sign, which is elicited by the clinician. When the patient complains of pain due to the pressure exerted by the clinician, the swelling is said to be 'tender'. To elicit tenderness, one should be very gentle and should not give too much pain to the patient. It is a good practice to keep an eye on the patient's facial expression while palpating the swelling to note whether this is giving rise to pain or not. Inflammatory swellings are mostly tender, whereas neoplastic swellings are not tender.

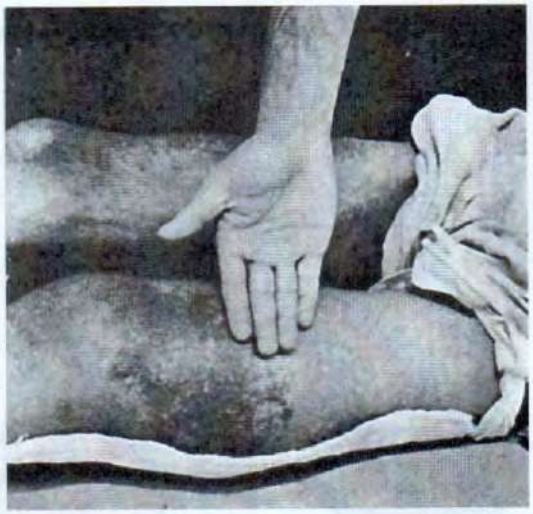

Fig.3.13.— Showing how to feel for local temperature with the back of the fingers which is more sensitive than the palmar surface.

3. **Size, Shape** and **Extent.**— By palpation, one can have an idea about the deeper dimension of the swelling, which remains unknown in inspection. The vertical and horizontal dimensions of the swelling are also better clarified by palpation. It is a good practice to mention in cm the vertical and horizontal diameters and should be sketched on the history sheet clearly indicating the *position* of the swelling as well.

The clinician should always try to find out the whole extent of the swelling. If a portion of the swelling disappears behind a bone, it should be clearly mentioned and its importance cannot be too impressed to the students.

4. **Surface.**— With the palmar surfaces of the fingers, the clinician should palpate the surface of the swelling to its entirety. The surface of a swelling may be smooth (cyst), lobular with smooth bumps (lipoma), nodular (a mass of matted lymph nodes) or irregular and rough (carcinoma). Sometimes the surface of the lump may be varied according to variable consistency.

5. **Edge.**— Very carefully, the edge or margin of the swelling is palpated. It may be well

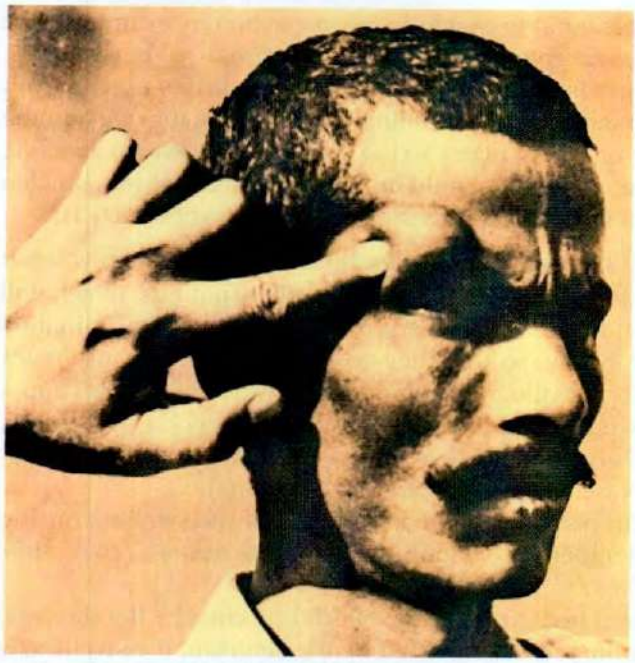

Fig.3.14.— Shows how to feel the margin of a swelling. The margin of a cyst yields to the palpating finger and does not slip away (cf. lipoma).

defined or indistinct — merging imperceptibly into the surrounding structures. Broadly speaking, neoplastic swellings and chronic inflammatory swellings have well-defined margins. Benign growths generally have smooth margins whereas malignant growths have irregular margins. Acute inflammatory swellings have ill-defined or indistinct margins.

The margins are palpated by the tips of the fingers. Swellings with well-defined margins tend to slip away from the finger. Benign tumour such as lipoma is often confusing with a cyst. The benign tumour has a smooth margin, so has a cyst. The most important finding, which differentiates benign tumour like lipoma from the cyst is that the margin of the former slips away from the palpating finger, but does not yield to it, whereas the margin of the latter yields to the palpating fingers and cannot slip away from the examining finger (Slip sign in Fig.3.15).

6. **Consistency.**— The consistency of a lump may vary from very soft to very hard. It depends on what it is made up of. When the swelling is of *UNIFORM consistency*, it gives a clue as to which anatomical structure it is derived from. It may be *soft* e.g. lipoma; *cystic* e.g. cysts and chronic abscesses; *firm* e.g. fibroma; *hard* but yielding e.g. chondroma, *bony hard* e.g. osteoma or *stony hard* e.g. carcinoma. The consistencies, just described, are all solid except the cystic one, which contains liquid within it. It should be borne in mind that consistency of a solid swelling may also be soft as seen in case of a lipoma. In case of gaseous swellings, e.g. gas gangrene, surgical emphysema, a *crepitus*

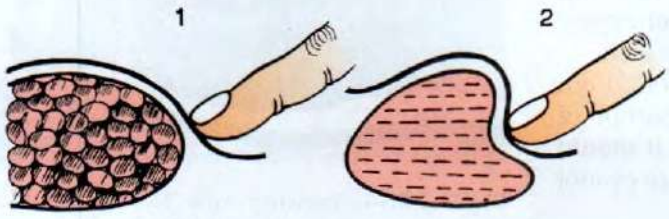

Fig.3.15.— Slip sign.— When the edge of a swelling is palpated, the margin of the solid swelling does not yield to the palpating finger but slips away from it; but in case of a cystic swelling the edge yields to the pressure of the palpating finger and does not slip away.



Fig.3.16.— Correct method of eliciting fluctuation. The fingers of the hand 'P' will remain passive and perceive the movement of the fluid displaced by the finger of the hand 'D'.

may be heard. Sometimes the swelling may be of ***VARIABLE*** *consistency*. This variability often indicates malignancy — either carcinoma or sarcoma.

While palpating for consistency, one must look for whether the swelling is getting moulded or not to pressure. It indicates that the content is a pultaceous or putty-like material. So the swelling must be a sebaceous cyst or a dermoid cyst or even an abdominal (colonic) swelling containing faecal mass. Sometimes the swelling *pits on pressure*. This means that there is oedematous tissue and most often the swelling is an inflammatory one.

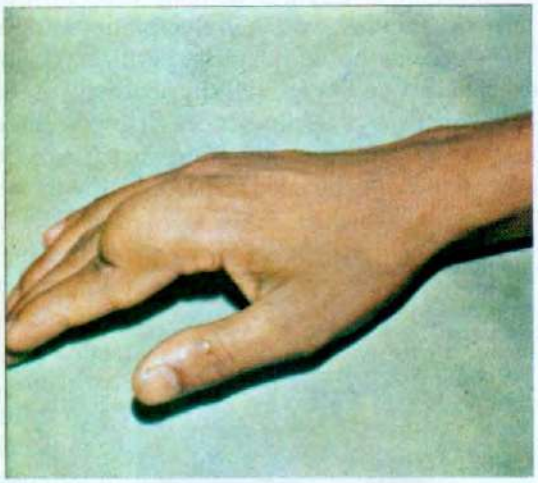

Fig.3.17.— Implantation dermoid at the dorsum of the left hand near the web between the index and the middle fingers.

7. **Fluctuation.**— A swelling fluctuates, when it contains liquid or gas. This test should be carried out by one finger of each hand. Sudden pressure is applied on one pole of the swelling. This will increase pressure within the cavity of the swelling and will be transmitted equally at right angles to all parts of its wall. If another finger of the other hand is placed on the opposite pole of the swelling, the finger will be raised passively due to increased pressure within the swelling. This means that the swelling is fluctuating.

(i) *This test should always be performed in two planes at right angles to each other.* A fleshy muscle (e.g. quadriceps femoris) sometimes shows fluctuation at right angle to its fibres, but not along the line of its fibres. (ii) *The two fingers should be kept as far apart as the size of the swelling will allow.* (iii) In case of the *swelling, which is freely movable,* it should be held fixed with the thumb and fore-finger of one hand, while the swelling is compressed on the other pole by the thumb and fingers of the other hand. The thumb and fore-finger, which have been used to fix the swelling, will feel increase of pressure within the swelling passively. Very often fluctuation is elicited in this manner in case of hydrocele. (iv) In case of *very small swelling,* which cannot accommodate two fingers, this test can be performed by simply pressing the swelling at its centre. The swelling containing fluid, will be softer at the centre than its periphery, while a solid swelling will be firmer at the centre than its periphery. This test is

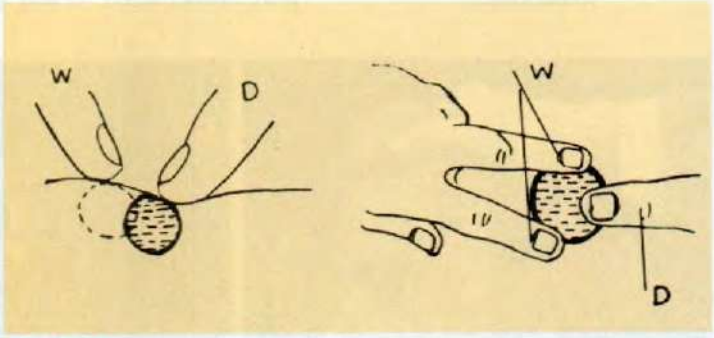

Fig.3.18.— Shows the method of eliciting fluctuation in case of a small swelling. In the first figure it is shown how a small swelling may be displaced as a whole by the displacing finger (D) and it shifts towards the watching finger (W) to elicit a false sense of fluctuation even when the swelling is a solid one. The second figure is the *correct method* of eliciting fluctuation in case of a small swelling. Two fingers of the left hand (watching fingers 'W') are placed on two sides of the swelling and the index finger of the right hand (displacing finger 'D') is pressed on the swelling to displace the fluid within the swelling.

known as ***Paget's test***. Another method is to keep two fingers of the left hand on the swelling so as to fix it and are called 'watching fingers'. Right index finger is used ('displacing finger') to press on the swelling to displace fluid inside the swelling which is felt by the 'watching fingers'. This test should be done in two planes at right angles to one another as the conventional method. The students should not try to perform traditional fluctuation test on a small swelling, as pressure exerted by one finger, will simply displace the swelling and fluctuation test cannot be performed. (v) *For very large swelling* more than one finger of each hand are used. Two or even three fingers may be used for providing pressure (displacing fingers) and palmar aspect of four fingers of the other hand may be used to perceive the movement of displaced fluid (watching fingers). (vi) *Very soft swellings sometimes yield false positive sense in fluctuation test*. The swellings which can be included in this list are : lipoma, myxoma, soft fibroma, vascular sarcoma etc. But if the students become careful while performing the fluctuation test, they will easily realise that these swellings yield to pressure, but fail to expand in other parts of the swelling like a true fluctuant swelling.



Fig.3.19.— Testing for translucency.

8. **Fluid thrill.**— In case of a swelling containing fluid, a percussion wave is seen to be conducted to its other poles when one pole of it is tapped as done in percussion. In case of a big swelling, this can be demonstrated by tapping the swelling on one side with two fingers while the percussion wave is felt on the other side of the swelling with palmar aspect of the hand. In case of a small swelling, three fingers are placed on the swelling and the middle finger is tapped with a finger of the other hand (as done in percussion), the percussion wave is felt by other two fingers on each side.





Figs.3.20 & 3.21.— Note how to examine for impulse on coughing in case of an adult and a child.

9. **Translucency.**— This means that the swelling can transmit light through it. For this, it must contain clear fluid, e.g. water, serum, lymph, plasma or highly refractile fat. A swelling may be fluctuant as it contains fluid, but may not be translucent when it contains opaque fluid, such as blood or pultaceous material (dermoid or sebaceous cyst). To carry out this test, darkness is essential. In day time, this can be achieved by a roll of paper, which is held on one side of the swelling, while a torch light is held on the other side of the swelling. The swelling will be seen to transmit the light, if it is a translucent swelling. The torch light should not be kept on the surface of the swelling, but on one side of the swelling, while the roll of paper on the other side so that the whole swelling intervenes between the light and the roll of paper. This will eliminate the possibility of false positive results.

10. **Impulse on coughing.**— In palpation, this test corroborates the finding detected in inspection. The swellings, which are likely to give rise to impulse on coughing, are : (i) those, which are in continuity with the abdominal cavity (e.g. herniae, ilio-psoas and lumbar abscesses), (ii) those, which are in continuity with the pleural cavity (e.g. empyema necessitatis) and (iii) those, which are in continuity with the spinal canal or cranial cavity (spinal or cranial meningocele).

The swelling is grasped and the patient is asked to cough. An impulse is felt by the grasping hand. Due to coughing, pressure is increased within the abdominal, pleural, spinal and cranial cavities. This increase in pressure is transmitted to the swelling, where the impulse is felt. *In case of children, this examination is performed when they cry.*



Fig.3.22.— Testing for compressibility in case of haemangioma of the upper eye lid.

11. **Reducibility.**— This means that the swelling reduces and ultimately disappears when it is pressed upon. This is a feature of hernia. Lymph, varix, varicocele, saphena varix, meningocele etc. are also reducible partly or completely.

12. **Compressibility.**— In contradistinction to reducibility, compressibility means the swelling can be compressed, *but would not be disappeared completely*. The compressible swellings may not have connections with the abdominal, pleural, spinal or cranial cavity. These swellings are liquid-filled and are mostly vascular malformations e.g. arterial, capillary or venous haemangiomas. Lymphangiomas are also compressible. The most important differentiating feature between a compressible swelling and a reducible swelling is that in case of the latter, the swelling completely disappears as the contents are displaced into the cavities from where they have come out and may not come back until and unless an opposite force, such as coughing or gravity is applied. But in case of the former, the contents are not actually displaced, *so the swelling immediately reappears* as soon as the pressure is taken off.

13. **Pulsatility.**— A swelling may be pulsatile (i) if it arises from an artery (expansile pulsation), (ii) if it lies very close to an artery (transmitted pulsation) or (iii) if the swelling is a very vascular one (telangiectatic sarcoma). It is very easy to detect whether a swelling is pulsatile or not, yet the students miss this test and land up with great



Fig.3.23.— Demonstration whether the pulsation is expansile or transmitted in nature.

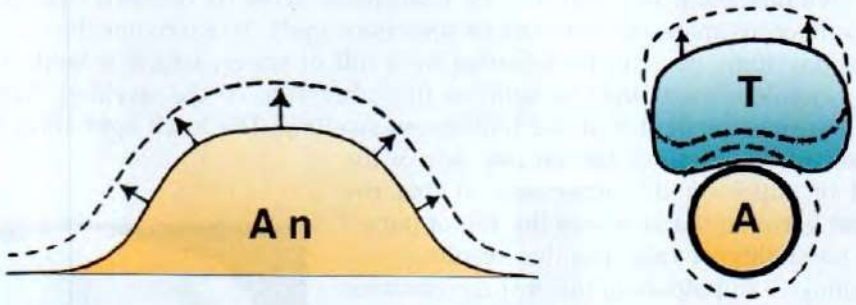

Figs.3.24 & 3.25.— Diagnostic representation of expansile and transmitted pulsation. 'An' is aneurysm & 'A' is an artery. 'T' is the tumour. See the text.

disaster (an aneurysm is sometimes incised by mistake considering it to be an abscess).

Two fingers, one from each hand, are placed on the swelling as far apart as possible (Fig.3.23). If the two fingers are raised with each throb of the artery, the swelling is a pulsatile one. When the two fingers are *not only raised, but also separated* with each beat of the artery, the pulsation is said to be an **'expansile'** one. When the two fingers are only raised, but *not separated,* the pulsation is said to be **'transmitted'**. In case of pulsatile swelling of the abdomen, the patient is placed in the knee-elbow position to determine whether it is an aneurysm of the abdominal aorta or a tumour lying in front of the abdominal aorta (transmitted pulsation). In case of the latter in this position pulsation ceases.

14. **Fixity to the overlying skin.**— The swellings, which originate from the skin (e.g. papilloma, epithelioma, sebaceous cyst etc.) will be obviously fixed to the skin. They will invariably move along with the skin unless they are fixed to underlying structures by malignant infiltration (e.g. epithelioma).

In case of the subjacent swellings, the students should learn how to know whether the swelling is attached to the skin or not. For this, one can do one of the following tests : (i) The skin is made to move over the swelling. If it is fixed to the skin, the skin will not move. (ii) The skin over the swelling is pinched up in different parts. When the skin is not fixed, it can be easily pinched up, which may not be possible when the swelling is fixed to the skin.

15. **Relations to surrounding structures.**— Clinically, the students should try to make out firstly the structure from which the swelling is originating and secondly whether the swelling is confined to its original structure or has invaded the other structures.

The tumours, arising from the **subcutaneous tissue**, are free from the overlying skin and from the underlying *contracted* muscle. If a lipoma is pushed sideways, the skin will be seen puckering in some places over the tumour. This is due to the presence of some fibrous strands, extending from the capsule of the tumour to the overlying skin. The students often mistake in finding out whether the tumour is fixed to the underlying structure or not. Even if the tumour is fixed to the underlying deep fascia and muscle, the tumour can be moved sideways. But *if the underlying muscle is made taut*, the tumour cannot be moved if it is fixed to the muscle.

The tumours, arising from **the deep fascia**, will not be as mobile as those arising from the subcutaneous tissue. But it is very difficult to find out whether the tumour is fixed to the deep fascia or not as this fascia cannot be made taut apart from the muscle.

In case of the tumours arising from the **muscle**, the swelling can be moved with the muscle relaxed. To know that the tumour is fixed to the muscle, the patient should be asked to carry out such movement *against resistance* to throw the particular muscle into contraction. When the tumour is arising from overlying subcutaneous tissue, but is fixed to the muscle, the tumour will

FIGURES SHOWING HOW TO MAKE A MUSCLE TAUT BY PUTTING IT INTO CONTRACTION AGAINST RESISTANCE

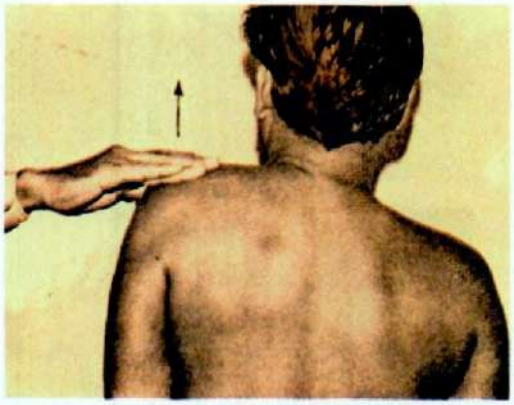

Fig.3.26.— Trapezius.

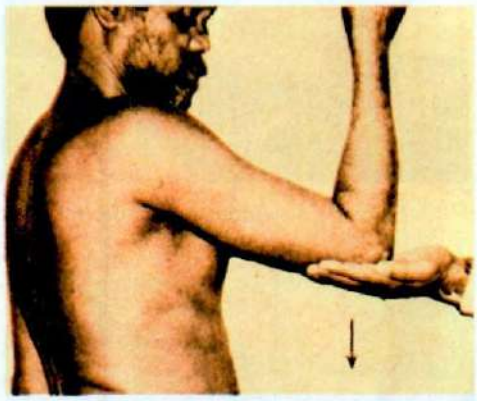

Fig.3.27.— Latissimus Dorsi.

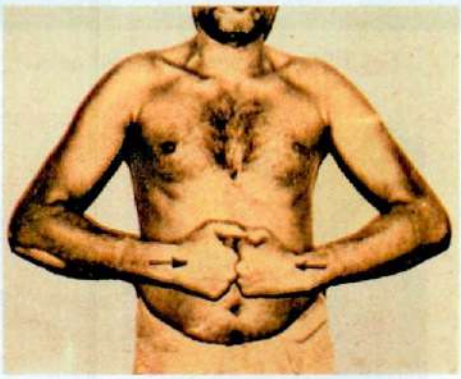

Fig.3.28.— Pectoralis major.

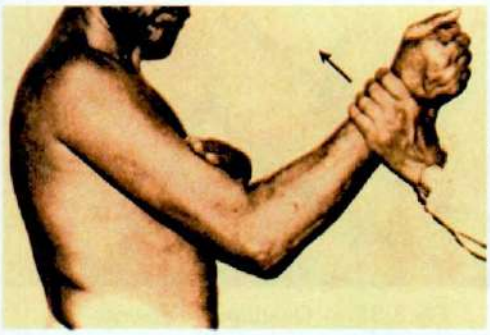

Fig.3.29.— Biceps Brachii.



Fig.3.30.— Triceps.



Fig.3.31.— Flexors of the wrist.

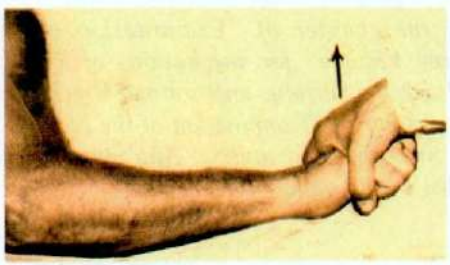

Fig.3.32.— Extensors of the wrist.

FIGURES SHOWING HOW TO MAKE A MUSCLE TAUT BY PUTTING IT INTO CONTRACTION AGAINST RESISTANCE



Fig.3.33.— Quadriceps Femoris.

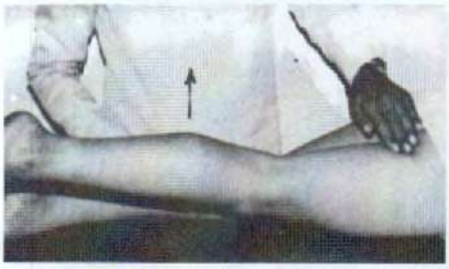

Fig.3.34.— Gluteus maximus.



Fig.3.35.— Gluteus medius.

See the chapter of "Examination of Peripheral Nerve Lesions" for the actions of Trapezius, the Deltoid, the Serratus anterior and Brachioradialis and the chapter of "Examination of the Neck" for that of the Sternomastoid muscle. Any other muscle can be tested in the same way.



Fig.3.36.— The Hamstrings.



Fig.3.37.— Adductors of the thigh.



Fig.3.38.— Extensors of the ankle.

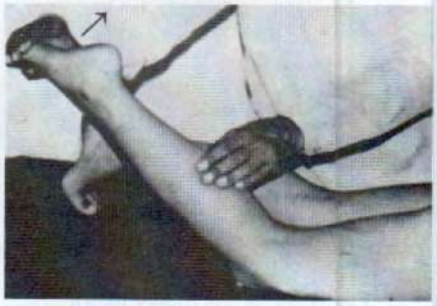

Fig.3.39.— Flexors of the ankle.

be *more prominent* and *cannot be moved along the line of the muscle fibres*. If the tumour is incorporated in the muscle, it will be fixed and *its size will be diminished* as soon as the muscle becomes taut. If the tumour lies deep to the muscle, it will *virtually disappear*, as soon as the muscle becomes taut.



Fig.3.40.— Shows how the swelling in connection with the tendon moves along with the tendon.

Sometimes a swelling becomes evident only when the muscle contracts. This is due to *tear in the muscle or in the tendon* concerned.

Swelling in connection with **the tendon** of a muscle moves along with the tendon and becomes fixed when the muscle is made taut against resistance.



Fig.3.41.— Rupture of the long tendon of the biceps.

Swellings, in connection with **the vessels** and **the nerves**, do not move along the line of the said vessel or the nerve but moves to a little extent at right angles to their axes.

Swelling in connection with a **bone**, is absolutely fixed even when the overlying muscle is absolutely relaxed and cannot be moved apart from the bone.

C. **STATE OF THE REGIONAL LYMPH NODES.**— It cannot be impressed too strongly that no examination of a swelling is complete without the examination of the draining lymph nodes. The students should have knowledge of anatomy to find out which group of lymph nodes drain the particular area from which the tumour is originating. When the regional lymph nodes are enlarged, it is a good practice to examine the other groups of lymph nodes to exclude generalized lymphadenopathy.

D. **PERCUSSION.**— The importance of this examination is not much in case of a swelling. Its sole place is to find out the presence of a gaseous content within the swelling e.g. resonant note over a hernia; or to elicit slight tenderness e.g. Brodie's abscess.

Hydatid thrill is a special sign in case of a hydatid cyst. The index, middle and ring fingers of the left hand are placed on the surface of the swelling so that the middle finger rests on the dome of the swelling and the other two fingers as placed as far apart as the size of the swelling will permit. The right middle finger is used to percuss on the left middle finger and a sensation of thrill is felt by the other two fingers. This is due to displacement of the daughter cysts in the fluid of the mother cyst and then strike back the wall of the mother cyst to produce the typical 'hydatid thrill'.



Fig.3.42.— Auscultating for a machinery murmur in an extensive cirsoid aneurysm.

E. **AUSCULTATION.**— All pulsatile swellings should be auscultated to exclude presence of any bruits or murmurs. 'Machinery murmur' is heard in an aneurysmal varix.

F. **MEASUREMENTS.**— This is important not only to find out increase in swelling at definite intervals, but also to find out if there is any wasting distal to the swelling.

G. **MOVEMENTS.**— In case of a swelling, the students must not forget to examine the

movements of the nearby joint to exclude any impairment. This should be noted in the history sheet and is of particular importance to find out if the swelling has involved the joint or not.

H. **EXAMINATION FOR PRESSURE EFFECT.**— Swellings will inevitably exert pressure on the surrounding structures. Its effect must be noted by the following examinations :

(i) The arterial pulse distal to the swelling is felt. Sometimes the swelling may *press on the main artery* of the limb and causes weak pulse distally.

(ii) The *nerves may be affected* by the pressure of the swelling. This will cause wasting, paresis or paralysis of the muscles supplied by the nerve with or without sensory disturbances.

(iii) The swelling may even exert its pressure on the subjacent bone by eroding it. This is sometimes seen in aneurysm and dermoid cyst on the skull.

GENERAL EXAMINATION

It is very much tempting while examining a swelling to do all with the swelling and forget about the rest of the body. This will lead to innumerable misdiagnoses. So one must examine the patient as a whole.



Fig.3.43.— Feeling for erosion of the skull in case of a dermoid cyst.

In case of malignant swelling, the importance of general examination is well established. This will give an idea about the site of metastasis, if any. An enquiry should be made about cough, haemoptysis or pain in the chest for pulmonary metastasis. The *chest* should be examined very carefully for presence of consolidation and pleural effusion. *Liver* should always be examined as this may be the organ affected by metastasis. General examination of the *abdomen* should be carried out to exclude the possibility of peritoneal metastasis. The *spine,* the *pelvis,* the *trochanters of the femurs,* the *skull* should be examined to exclude bony metastasis.

If the swelling is suspected to be a gumma or a condyloma, the patient should be examined generally to find out *other syphilitic stigmas* (See page 66).

In case of lymph node enlargement, one should always examine the *other groups of lymph nodes* to find out the cause of lympho-glandular enlargement.

SPECIAL INVESTIGATIONS

1. Examination of the **blood** for total count (T.C.), differential count (D.C.), haemoglobin (Hb%), erythrocyte sedimentation rate (E.S.R.) and sugar are very much informatory so far as the diagnosis of a swelling is concerned. Inflammatory swellings will obviously show leucocytosis (increased total count) and increased number of polymorphs in differential count. Chronic inflammatory swellings and malignant swellings will show increased E.S.R. and low haemoglobin percentage (anaemia). In case of recurrent abscesses and carbuncles, one should not forget to do the sugar estimation of the blood. Many a case of diabetes mellitus will be revealed through this test.

In case of syphilis, W.R. or Kahn test or complement fixation test of the serum is very important.

2. **In urine,** estimation of sugar is very important in case of recurrent abscesses and carbuncles to find out if the patient is suffering from diabetes.

3. **Aspiration** and examination of the aspirated material physically, chemically, microscopically and bacteriologically are very important in case of chronic cystic swellings.

4. **Fine Needle Aspiration Biopsy (FNAB) or Fine Needle Aspiration Cytology (FNAC).**— These investigations are often used nowadays to avoid extensive operation of open biopsy. A fine needle (of 22 or 23 gauge) fitted with a tight fitting syringe is used for this technique. The tissue aspirated is examined microscopically, chemically and bacteriologically. For cytology the cellular suspension obtained by aspiration is smeared on a slide. It is dried, fixed with absolute alcohol and stained with Papanicolaou Technique.

Exfoliative Cytology — has little scope in case of a swelling. In this technique the cells shed from the tumour located in a hollow viscus is taken out and examined under microscope, stained (Papanicolaou) and unstained. This technique is particularly applied in case of G.I. tumours, respiratory tract tumours (sputum or through endoscope), urinary bladder (through endoscope) and female genital tract.

5. **X-ray** examination is indispensable in case of bony swellings and to find out if the subjacent bone has been eroded by an aneurysm or a dermoid cyst.

Chest X-ray should be taken when pulmonary metastasis is to be excluded in case of a malignant growth.

6. **Skin test.**— (a) *Tuberculin test* — if positive in infants and young children suggests tuberculous lesion. If this test is negative in adult, it can straightway exclude possibility of tuberculous origin of the swelling.

(b) *Casoni's test* becomes positive in case of a hydatid cyst; but a negative result cannot exclude hydatid cyst.

7. **Ultrasonography.**— This is a simple, inexpensive, non-invasive and safe technique. It produces mechanical vibrations at a high frequency which is imperceptible to human ear. These are detected by transducer and can measure depth and dimensions of various structures within the body. This technique is based on principle of reflection of sound waves of high frequency at the junction of different tissue levels in the body. The reflected echoes are converted in the transducer into small electrical changes. Images commonly are displayed on a Television monitor as an electronic representation of the returning echoes. One dimensional or A-mode scan provides histogram of echo intensity along the line of tissue examined. In two dimensional or B-mode scan the morphologic structures are portrayed in two dimensions as the transducer can be moved in transverse, longitudinal or oblique directions. In 1974 Grey-scale imaging was introduced which renders varying echo intensities, as differing shades of grey with increased amount of information. Real-time imaging is a further step ahead in technology and provides more information. As ionising radiation is not used, it is particularly safe and can be used in children and pregnant women.



Fig.3.44.— The upper picture is a three dimensional CT Scan which shows fracture dislocation of cervical vertebra. Whereas the lower figure shows simple CT Scan of the same case.

It is particularly used to determine whether a mass is solid or cystic.

8. **Computed Tomography (CT Scan).**— This technique provides unique two-dimensional representation of differing radiographic densities throughout a cross-sectional volume of tissue.

It avoids the confusing superimposition of organs and accurately records small variation in tissue density. Its limitations are its complexity and great expense. Radiation burden may become significant necessitating careful application. As the part of the body is evaluated in thin tomographic section many images may be required to completely evaluate large anatomic regions like abdomen. The whole body scan can be obtained through a series of transverse sections by gradually moving the body through a ring of tubes and detectors.

It provides more accuracy than that of ultrasonography in assessment of any growth e.g. its size, shape, local spread and general dissemination. It helps in exact anatomical localization of deep seated masses even in obese individuals.

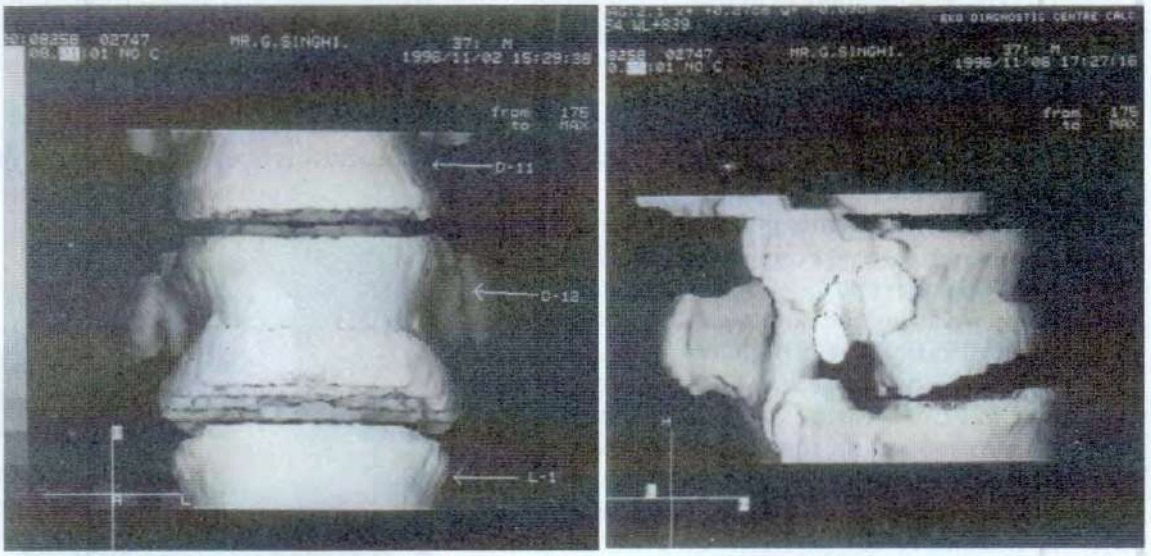

Figs.3.45 & 3.46.— Both these figures show AP and lateral views of three dimensional CT Scan of a case of collapsed fracture of vertebra (D12).

Three Dimensional CT Scan (3D CT Scan) — is now available which provides 3 dimensional picture of the structure or organ of the body. It is also possible with the help of the computer to resect or deduct a portion of the structure to get better view of the interior of the particular structure. In Fig.3.44 a complete 3D CT Scan of the cervical vertebrae with fracture-dislocation is shown and in the next figure a sagital section of the same vertebrae are shown to see the inside of the spinal canal and to know how much it has been reduced by the fracture-dislocation which might have caused damage to the spinal cord.

9. **Magnetic Resonance Imaging (MRI)** or **Nuclear Magnetic Resonance (NMR)** — This is the latest and most potentially dramatic efficient diagnostic armamentarium. These images are derived from radio waves emitted by protons, which when exposed to a magnetic field, can be excited by absorption of energy from radio frequency pulses. Most protons in the body, are within water molecules and their properties differ from tissue to tissue, thus potentially making it possible to image a variety of structures in the body. For more details students are referred to page no. 564 of the same author's 'A Concise Textbook of Surgery'.



Fig.3.47.— MRI shows tumour of the spinal cord shown by arrow.



Fig.3.48.— MRI with contrast medium shows how clearly the spinal cord tumour can be delineated (shown by arrow).

It provides a fine demonstration of soft tissues and bones for greater clarity of any swelling thereabout.

It is now *possible to use a contrast medium* for Magnetic Resonance Tomography. The contrast medium used is known as Magnevist which is specially made for Magnetic Resonance Tomography (MRT) and it is well tolerated by the body. It is eliminated from the body almost completely within 24 hours. Such contrast medium is mostly used in cranial and spinal MRT. After injection of Magnevist, the resulting opacification of areas with dysfunction of the blood-brain barrier (e.g. glioblastoma) and of other intracranial and intraspinal lesions of non-cerebral origin provides diagnostic information additional to that obtainable with a plain scan. The patient is to fast for 2 hours before the examination. The safety rules customary for MRI must be observed e.g. exclusion of cardiac pacemakers and ferromagnetic implants. The dose required is administered intravenously as a bolus injection. The *contrast-enhanced* MRT (Fig.3.48) is commenced immediately afterwards though optimal opacification is generally achieved within a period of about 45 minutes after the injection of Magnevist. In general, administration of 0.2 ml. Magnevist per Kg body weight is sufficient for good opacification.

10. **Angiography.**— For a few swellings this investigation is of value. For all aneurysmal swellings this investigation is a must. This investigation is also of value in differentiating a cyst from a tumour. In case of malignant tumour this investigation may show abnormal disposition of small arteries in and around the tumour as also the 'contrast pool' inside the tumour which is significant.

11. **Biopsy** is by far the most important investigation of a swelling. This is particularly done in case of suspected malignant tumours. The biopsy is generally taken from the margin of the tumour. The risk of spread of malignancy from biopsy is more theoretical than practical. There are various methods of biopsy.—

(a) NEEDLE BIOPSY.— In this method a hollow needle is introduced into the swelling and a core of tissue is taken out for histological examination. Various types of needles have been used

for various organ swellings e.g. Vim Silvermann needle for liver, Travenol Tru-cut needle for prostate through the perineum.

(b) **DRILL BIOPSY** — is performed by an apparatus consisting of a small sharp cannula within which is attached a high speed compressor air drill. This is claimed to be better than needle biopsy and has been mostly used in case of breast lumps. The core of tissue obtained by this method is now examined for histopathological report. Accuracy has been claimed to the tune of more than 90% in case of breast lumps.

(c) **PUNCH BIOPSY.**— This method is more often used in case of tumour for hollow viscera or solid viscera. With punch biopsy forceps pieces of tissue are taken from the *margin* of the tumour alongwith surrounding normal tissue or from the *base* of the tumour. Typical four quadrant biopsy is taken from a big ulcer of the stomach.

(d) **OPEN BIOPSY.**— This is performed by operation. After getting access to the tumour a slice of tissue (Incisional biopsy) or the whole of the tumour (excisional biopsy) is excised and then histopathological examination of the tumour is performed.

Incisional biopsy — has the theoretical disadvantage of spreading the tumour to the adjoining tissues.

Excisional biopsy — is safe and better. It is done by excising the tumour with a margin of healthy surrounding tissue in case of malignant growth. But in case of confirmed benign tumours only the tumour is excised. It is better, as malignant change in a benign growth may be detected by this technique. The whole tumour can be examined histopathologically. It is also safe as it does not allow dissemination of the tumour. Whenever possible excisional biopsy should be carried out in case of suspected tumours.

12. In case of suspected malignant tumours, the patient should be **followed up** to find out if the tumour recurs or not.

DIAGNOSIS OF A SWELLING

While diagnosing a swelling, the clinician should first find out, whether the particular swelling is originating from — the *skin*, the *subcutaneous tissue*, the *muscles*, the *vessel*, the *nerve* or *bone* and secondly, the cause of the swelling — whether it is a *congenital, traumatic, inflammatory, neoplastic* or *otherwise.*



Fig.3.49.— Cavernous haemangioma on the face.

Congenital swellings are generally present since birth e.g. haemangioma, cystic hygroma, meningocele etc. A few swellings in this group may not appear since birth, but will make their appearance later in life e.g. branchial cyst, dermoid cyst, thyroglossal cyst etc.

Traumatic swellings develop immediately after a trauma e.g. haematoma, fracture with displacement, dislocation, rupture of a muscle etc.

Inflammatory swellings may be either of *acute* variety or *chronic* variety.

Acute inflammatory swellings present with redness (rubor), pain (dolor), heat (calor), swelling (tumor) and impairment of function (Functio laesa). Of these five signs and symptoms stress must be given to pain, redness and heat. Not infrequently a few rapidly growing sarcomas e.g. osteosarcoma may mimic an acute inflammatory swelling with pain (which appears even before the swelling), redness, swelling, heat etc. Probably *the differentiating features* in favour of acute inflammatory swelling which one should look for are tenderness, brawny induration and oedema. Presence of fluctuation means presence of pus, which indicates that the swelling is an inflammatory one. Moreover, the related lymph nodes will be affected and will show signs of acute lymphadenitis. Though slight rise of body temperature is not unusual in sarcoma yet it is never of the hectic type, which may be noted in acute inflammation. Leucocytosis is a constant feature of acute inflammation, which may or may not be present in sarcoma.

Chronic inflammatory swellings will show the same signs and symptoms as the acute inflammatory swellings but in very much subdued form. In this case, swelling is more than the other features like pain, redness, heat etc. Brawny induration and oedema are conspicuous by their absence. So, at times it becomes rather difficult to differentiate chronic inflammatory swellings from malignancy. There may be slight rise of temperature, which may be associated with slight tenderness and fixity in a rapidly growing malignant growth. *The most important differentiating feature* is the history of occasional diminution in the size of the swelling, which goes in favour of an inflammatory swelling. A tumour always increases in size either rapidly or very slowly. It may even remain stationary for a long time but *never recedes.*

Neoplastic swellings may be either benign or malignant.

Benign tumours grow slowly, are encapsulated, move freely (Fibroadenoma of the breast — better known as 'Breast Mouse'), hardly infiltrate the surrounding tissues and never metastasize either to the regional lymph nodes or to the distant organs. These tumours may undergo secondary changes of which malignant transformation seems to be the commonest. *Malignant tumours* may be either carcinomas which arise from epithelial cells or sarcomas which originate from the connective tissues. As a rule, malignant tumours are notoriously known for their rapid growth and metastasis — either to the regional lymph nodes or to distant organs. Secondary changes such as ulceration and degeneration may be noticed in malignant growths. The students should always keep in mind that *pain is conspicuous by its absence* in malignant growths, barring osteosarcomas where pain precedes the swelling. Though too much importance cannot be given to the age of the patient, yet the students should know that the carcinoma affects the old and the sarcomas affect the young commonly.

Characteristics of benign and malignant growths.—

	BENIGN	MALIGNANT
	Occurs at younger age.	Seen usually above 40 years of age, but may occur at younger age.
	Symptoms.—	
1.	Duration.— Slow growth.	1. Rapid growth.
2.	Pain.— Usually absent.	2. May be painful at late stage, barring osteosarcoma which is painful from the beginning.
3.	Loss of weight.— Never seen.	3. A feature of malignant growth.
4.	Loss of function.— Usually not seen.	4. Seen quite early.

	BENIGN	MALIGNANT
	Signs.—	
1.	Cachexia, anaemia and loss of weight.— Usually absent.	1. Usually present.
2.	Mobility.— Freely mobile.	2. Fixed early due to infiltration.
3.	Surface.— Usually smooth.	3. Usually irregular.
4.	Margin.— Definite and smooth.	4. Not definite and irregular.
5.	Consistency.— Usually firm.	5. Either hard or of varying consistency.
6.	Pressure Effects.— Usually absent.	6. Often present.
7.	Regional lymph nodes.— Not enlarged.	7. Early involved and enlarged.
8.	Distant metastasis.— Almost never seen.	8. A feature of malignant growth — a late feature.
9.	Secondary changes.— Not seen.	9. Often come across.
10.	Recurrence.— Never recurs after excision.	10. Often recurs after excision.
	Histology.—	
1.	Cell differentiation.— A feature of benign growth.	1. Cells are usually undifferentiated.
2.	Polarity.— Cells are arranged as parent tissue.	2. Polarity is lost.
3.	Capsule.— Always encapsulated.	3. No capsule formation as local infiltration is the rule.
4.	Anaplasia.— Not seen.	4. A feature of malignant growth.
5.	Nuclear structure.— Same as the parent tissue without mitosis.	5. Nucleus becomes larger, hyperchromatic with mitosis.

It may so happen that a tumour may be benign to start with, but may undergo malignant transformation at some stage. The **malignant transformation** is recognized by — (i) Sudden increase in the size of the swelling; (ii) Increase in vascularity of the tumour with rise of local temperature; (iii) Fixity of the tumour and infiltration of the surrounding tissues e.g. involvement of the facial nerve in case of a parotid tumour, or malignant change in a thyroid lobule is suspected when a patient complains of hoarseness of voice (due to involvement of recurrent laryngeal nerve) or dyspnoea (due to involvement of the trachea) or dysphagia (due to involvement of oesophagus); (iv) Secondary changes in the tumour either in the form of increase in pigmentation (e.g. malignant melanoma), ulceration and bleeding; (v) Appearance of pain, which is a late feature of malignant disease; (vi) Involvement of regional nodes; (vii) Appearance of distant metastasis.

In the differential diagnosis I shall only discuss the swellings arising from the *skin* and the *subcutaneous tissues.* The swellings originating from the muscle, tendon sheath, the vessel, the nerve or the bone are discussed in the appropriate chapters.

DIFFERENTIAL DIAGNOSIS

CONGENITAL :

DERMOID CYST (Sequestration dermoid).— This cyst generally develops in the line of embryonic fusion. So this cyst may appear anywhere in the midline of the body as also in places where the two embryonic processes meet each other e.g. at the outer angle of the orbit (Fig. 3.8) (where the fronto-nasal process and the maxillary process fuse with each other), behind the pinna (Fig. 3.9) (Post auricular dermoid), just below the tongue in the midline (Sub-lingual dermoid) etc.

The characteristic features of the swelling will be similar to those of a cyst. There will be presence of fluctuation but translucency will be absent due to the presence of pultaceous material inside the cyst. The swelling is round and smooth and the margin will yield to the pressure of the finger and will not slip away (cf. Lipoma). The swelling will be free from the skin and from the deeper structures. When the underlying structure is a bone an indentation in the bone may be felt at the margin of the swelling (Fig. 3.43). Dermoid cyst in the scalp may be (a) fully outside the skull bones or (b) outside the skull but attached to the duramater through defect in the skull or (c) partly extracranial and partly intracranial connected with a stalk or (d) fully intracranial lying between the skull and the dura (rarest). Sequestration dermoid never elicits impulse on coughing except the rare (c) type which occasionally may elicit impulse on coughing.

TUBULO DERMOID and TERATOMATOUS DERMOID are described in the same author's 'A Concise Textbook Of Surgery' page 80 and are out of scope here.

Implantation or acquired dermoid (Fig. 3.52 and Fig. 3.17).— It is *not a congenital swelling* in the true sense, but it is described here as it is included in the category of the dermoid cyst. It is actually a traumatic swelling and results from the surface ectoderm being driven into the subjacent tissue. So, the origin is more or less like a dermoid cyst but it is always a sequel of trauma. This is commonly seen in a finger or a hand from a needle prick or a prick with a thorn.



Fig.3.50.— Strawberry haemangioma (Capillary haemangioma) of the cheek.

HAEMANGIOMAS.— These are vascular malformations or hamartomas and may arise from the capillary or the vein or the artery and accordingly called a capillary haemangioma or cavernous haemangioma or a plexiform (cirsoid) haemangioma respectively.

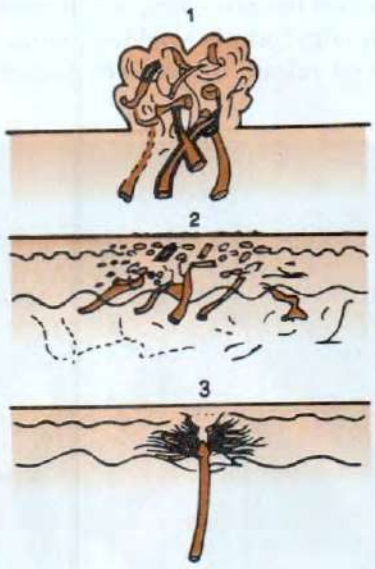

Fig.3.51.— A schematic diagram to show 1.— Strawberry Naevus; 2.— Port-wine stain, which is a collection of dilated intradermal capillaries. 3.— Spider Naevus, in which there are visible radiating branches from a single arteriole.

(a) **Capillary Haemangiomas** — are bright red or purple coloured patches of varying sizes. These are generally flat and not much raised above the skin surface. Pressure may cause complete disappearance or diminution of the colour which returns immediately when the pressure is released. There are six varieties of capillary haemangioma which are well known in surgical practice:

(i) ***Port-wine stain*** is a diffuse telangiectasia with practically no swelling.

(ii) ***Salmon patch*** is usually present since birth and often seen in the forehead or on the occiput. It usually disappears before first birthday.

(iii) ***Spider Naevus*** has a central red spot with numerous radiating fine blood vessels like the legs of a spider. It is often seen over manubrium sterni. Spider naevus is often multiple and tend to increase in number over the years. It is mostly seen on the upper half of the trunk, face and arms. Spider naevi do not cause any change of skin temperature and are not tender. These fade completely when compressed with the finger and



Fig.3.52.— Implantation dermoid in the middle finger.

refill as soon as the pressure is released. Sometimes it may be acquired from a generalized disease like liver cirrhosis, tumours destroying the liver and tumours producing oestrogen.

(iv) ***Vin rose patch.***— It is a congenital condition causing mild dilatation of intradermal subpapillary plexus giving rise to pale pink colour to the skin. This can occur anywhere without any symptom. It is often associated with other vascular abnormalities e.g. extensive haemangiomata, giant limb due to arteriovenous fistula and/or lymphoedema.

(v) ***Campbell de Morgan spot.***— This is caused by dilated capillaries fed by a single or cluster of arterioles giving rise to a bright red spot. It is about 1 to 3 mm in diameter. The cause is unknown. This condition is rarely seen in people less than 45 years of age. These appear suddenly one at a time, but gradually may become multiple often affecting one area of skin. These are symptomless. These are seen on both aspects of trunk, more on the upper half than the lower. Occasionally may be seen on the limbs and almost unseen on the face. These are usually circular and have a sharp edge which may be raised. Important feature is that though these are collection of dilated capillaries, these are not totally compressible, but always fade.

(vi) ***Strawberry angioma*** is a sessile lobulated circumscribed swelling. Its surface looks like a strawberry. These generally appear at birth and often regress spontaneously a few months or years after birth. Incidence of multiple strawberry naevi is not unknown.

(b) **Cavernous Haemangioma** — is a bigger haemangioma than the preceding one. It consists of dilated spaces containing blood and gives rise to soft spongy bluish swelling, which is compressible and can be emptied by pressure but reappears on release of pressure. Common occurrence is seen in the lips, cheeks, face (Fig.3.49), brain, etc. It is interesting to know that surface haemangiomas are often associated with similar affection in the internal organs e.g. haemangiomas of the face may be associated with haemangiomas of the brain on the same side. So, once haemangioma is discovered, all possible sites should be searched.

(c) **Plexiform Haemangioma** — is nothing but a network of dilated interwoven arteries like a bag of pulsating earth worms (*CIRSOID ANEURYSM* — Fig.3.54).

(d) **Congenital arteriovenous fistula** — is the result of persistence of congenital communication between the arteries and veins affecting the extremities usually. The diagnosis is made by warm limb, enlargement of the limb, localized bruit over the fistula, presence of varicose veins and insufficiency of the distal circulation. Acquired arteriovenous fistula may appear following trauma or may be created surgically for haemodialysis.

(e) **Glomangioma (Glomus tumour).**— It is not a congenital tumour in the true sense. It is a



Fig.3.53.— Typical red colour cavernous haemangioma on the chest of the baby (congenital).

specialized arteriovenous communication surrounded by smooth muscle cells and large epitheloid or cuboidal cells called glomus cells. The sensory nerves (both medullated and nonmedullated) end at these epitheloid cells and make this tumour very much painful. Even the slightest pressure will give rise to an excruciating pain. The commonest site of this tumour is just beneath the nail near the finger tip. It looks like a small reddish blue spot. It does not blanch on pressure as a haemangioma. The tumours are subcutaneous and they can occur anywhere in the body, but are usually seen at the extremities of the limbs and often at subungual position. The lesion has a bluish tinge due to the blood content and the subungual lesions are usually 1 to 2 millimetres in size. It is a benign tumour which never turns malignant.



Fig.3.54.— Cirsoid aneurysm in the forehead.

TRAUMATIC :

Traumatic swellings arising from the skin and subcutaneous tissues are rare. *Haematoma* following a trauma may give rise to swelling. The other important swelling in this connection is the *implantation dermoid* which has already been discussed under the heading of 'Dermoid Cyst'.

INFLAMMATORY :

ERYSIPELAS.— It is a spreading cuticular lymphangitis which may follow even a scratch. The causative organism is mostly Str. Pyogenes. The conditions which predispose this disease are debilitating state and poor health of the patient. The condition commences as a rose-pink rash which extends to the adjacent skin. The vesicles appear sooner or later over the rash and rupture. Serous discharge comes out from these vesicles. When it affects loose areolar tissues such as orbit, scrotum, etc., there is considerable swelling of the part due to oedema of the subcutaneous tissue and thus very much resembles cellulitis.

To distinguish between a true erysipelas and cellulitis the following points in favour of erysipelas should be borne in mind : (i) The typical rosy-red rash disappears on pressure and fills stiff; (ii) The raised rash of erysipelas has a sharply defined margin — which is better felt than inspected (this is the most important point); (iii) The vesicles of erysipelas contain serum in contradistinction to the cellulitis where they contain pus; (iv) In case of the face, Milian's ear sign i.e. erysipelas can spread into the pinna (being cuticular affection) whereas cellulitis cannot, owing to close adhesion of the skin to cartilage of the ear.

CELLULITIS.— It is a spreading inflammation of the subcutaneous and fascial tissues leading to suppuration, sloughing or even gangrene (especially in cases of diabetes) of the affected part. The commonest organism is again Streptococcus pyogenes. The organisms gain access through an accidental wound, however trivial it may be. The victims are generally diabetic or debilitated individuals with poor nutrition. It is a condition which requires intense attention of the surgeon as it may lead to septicaemia and may turn fatal.

The affected part becomes swollen, hot and tender. The condition starts with redness, itching and stiffness at the site of inoculation. The part gradually looks brawny and becomes oedematous which is demonstrated by pitting on pressure. There is no definite edge (cf. erysipelas). The lymph vessels may stand out as red streaks (lymphangitis), the regional lymph nodes draining the area become enlarged and show the picture of acute lymphadenitis. Varying degree of constitutional disturbances such as fever and toxaemia are common.

The students should remember two things in connection with cellulitis. (i) In cellulitis of the

scrotum, one should always exclude the possibility of presence of extravasation of urine with it. (ii) In children, cellulitis occurring near a joint (particularly the knee joint), one should remember the possibility of acute osteomyelitis as the commonest cause of this condition.

ABSCESS.— An abscess is a collection of pus within the body. There are three varieties of abscesses seen in surgical practice :—

(i) **Pyogenic Abscess.**— This is the commonest variety of abscess and may result from cellulitis or acute lymphadenitis. The organisms gain entry either directly through the penetrating wound or local extension from adjacent focus of infection or haematogenous or lymphatic spread from a distance. At first the infected part becomes red hot and quite tender. When pus develops, the pain takes a typical character of throbbing in nature. There will be brawny induration and oedema (demonstrable by pitting on pressure). Fluctuation may or may not be present (as in parotid abscess).

(ii) **Pyaemic Abscess.**— These are generally multiple in number, either develop simultaneously or a number of them crop up in succession only after one has been incised. This condition results when infective emboli circulating in the blood lodge in different parts of the body and give rise to multiple abscesses. The peculiarity of these abscesses are that they commonly occur in the subfascial plane and do not present the features of a common abscess. These are non-reacting in nature i.e. acute features are absent. But constitutional disturbances are tremendous with high fever, rigor and toxaemia.

(iii) **Cold Abscess.**— As the name suggests, this abscess is cold and non-reacting in nature. It does not produce hot and painful abscess as seen in pyogenic abscess. Brawny induration, oedema and tenderness are conspicuous by their absence. Cold abscess is almost always a sequel of tubercular infection anywhere in the body commonly in the lymph nodes and bone. Caseation of the lymph nodes forms the cold abscess. The commonest sites are at the neck and axilla. Sometimes cold abscesses are seen at the loin, at the back or at the side of the chest wall. These are sequel of tuberculous affection of the spine, ribs and posterior mediastinal group of lymph nodes. Cold abscesses may also originate from the ends of the bones and joints and gradually come to the surface through the fascial planes.

BOIL (Furuncle).— Infection of a hair follicle with Staphylococcus aureus leads to this condition. It may be associated with perifolliculitis, which may proceed to suppuration. It starts with a painful and indurated swelling which gradually extends. There will be tremendous tenderness with surrounding oedema. After a couple of days, there will be softening at the centre on the summit of which a small pustule appears. It may burst spontaneously discharging greenish slough. After this, a deep cavity develops lined by granulation tissue, which heals by itself. Boils are common on the back and neck. Furuncle of the external auditory meatus is very painful as the skin is more or less attached to the underlying cartilage and there hardly remains any space for the swelling to develop, so a great tension develops which leads to pain. Perianal boils when rupture form sinuses. Boils may lead to cellulitis particularly in those persons whose immunity is less. Boils may also lead to infection of the neighbouring hair follicles where number of hair follicles are too many (e.g. axilla) leading to hydradenitis. Boils may lead to infection of the regional lymph nodes.

CARBUNCLE.— It is a bigger form of boil and the causative organism is again Staphylococcus aureus. This is due to infective gangrene of the subcutaneous tissue where the infection has already spread. Generally men above 40 years of age are sufferers and they are mostly *diabetic.*

Carbuncles are commonly seen on the back, in the nape of the neck where the skin is coarse and the vitality of the tissue is less.

It commences as painful and stiff swelling which spreads very rapidly with marked induration. The overlying skin becomes red, dusky and oedematous. Subsequently the central part softens, vesicles and later on pustules appear on the surface. These burst allowing the discharge to come out through several openings in the skin. The sieve like or cribriform appearance of the carbuncle is pathognomonic. These openings enlarge and ultimately coalesce to produce an ulcer at the floor of which lies the ashy-grey slough. Finally the slough separates leaving an excavated granulating surface, which heals by itself. The resistance of the individual is poor as in a diabetic subject. The sloughing process may extend deeply into the muscle or even bone. Constitutional symptoms and toxaemia may vary according to the degree of the resistance of the individual.

NEOPLASTIC :

BENIGN NEOPLASMS :

PAPILLOMA.— This is a simple overgrowth of all layers of the skin. Mostly it is a pedunculated growth having branched villous processes. It consists of a central axis of connective tissue, blood vessels and lymphatics. The surface is covered with epithelium in the form of squamous, transitional or columnar according to the site of the tumour.

Papilloma may appear at any age. The commonest complaint is the swelling and nothing else. Sometimes, it may be injured to become red, swollen, ulcerated and even inflamed to present with the symptoms accordingly.

It may occur anywhere in the body. But here only the clinical features of the papilloma arising from the skin will be discussed. It may be papilliferous and pedunculated, which may vary in length starting from a long peduncle to a very short peduncle or even sessile. Cutaneous papilloma is soft and solid. It moves with the skin and its base is not indurated like an epidermoid carcinoma. Sometimes the surface of the growth may be hard, when it is called 'Horny papilloma'. *Complications* are ulceration, bleeding and malignancy.

Other common sites besides the skin are the lip, the tongue, the vocal cord, the colon, the rectum, the kidney, urinary bladder and the breast.

FIBROMA.— This is a tumour of the fibrous tissue. Considering the wide spread distribution of the fibrous tissue in the body, true fibroma is of rare occurrence. Most fibromas are combined with other mesodermal tissues, such as fat (Fibrolipoma), the muscles (Fibromyoma), nerve sheath (Neurofibroma) etc. The last named tumour may be seen in multiple numbers, which is called Neurofibromatosis (Von Recklinghausen's disease).

Fibroma gives rise to a painless, firm, circumscribed swelling (Fig. 3.55), which moves freely on the underlying structures. According to consistency, fibroma may be hard or soft (according to the amount of fibrous tissue it contains). Soft fibromas are often indistinguishable from sarcoma. *Paget's recurrent fibroid (Desmoid tumour)* — an unusual type of fibroma arising from the rectus sheath is notorious for recurrence and stands in the borderline of malignancy.

LIPOMA.— A lipoma is a cluster of fat cells which become overactive and so distended with fat that it produces a palpable swelling. This is the commonest tumour of the subcutaneous tissue. It may occur anywhere in the body, hence it is known as *'universal tumour'*, but mostly seen in the back of the neck, shoulder and the back. Though subcutaneous lipoma is the commonest and will be discussed in details, yet the students should keep in mind that lipoma may develop in other places, e.g. *Intermuscular, Subfascial, Parosteal, Subserous, Submucous* (G.I. Tract), *Intra-articular, Subsynovial, Subdural* or *Extradural* (spine).

There are mainly 3 varieties of lipoma — 1. Encapsulated variety; 2. Diffuse variety and 3. Multiple lipomas.

1. *ENCAPSULATED SUBCUTANEOUS LIPOMA.*— This is the commonest variety. Pathologically



Fig.3.55.— Fibroma of the foot.

it consists of normal fat which contains overactive fat cells and is arranged in lobules separated by fibrous septa and enclosed in a delicate capsule. A lipoma is usually small but it may attain very big size. Lipoma may occur at any age, but it is rarely seen in children. It is a painless, slowly growing, lobulated and soft swelling. It can occur anywhere in the body, though more commonly seen in the neck, in the back, around shoulder and in the upper limbs. The overlying skin is usually of normal colour. Only in case of very large lipoma the skin may be stretched with dilated veins over the tumour. But such feature is more common in case of naevolipoma. The surface is smooth and lobulated. The edge is definite and slips under the palpating finger, which is known as ***'slip sign'***. This sign is helpful to differentiate this condition from a cyst in which case the edge does not slip away from the palpating finger, but yields to it. Consistency is soft but does not fluctuate. In normal body temperature the fat remains almost in semiliquid condition and consequently slight fluctuation may be elicited and thus lipoma is often called a *'semifluctuant'* swelling. Though lipoma does not contain fluid, yet a large lipoma may transilluminate with the light from ordinary torch. A lipoma is a freely mobile swelling over the deeper structures such as muscles and fasciae. So a lipoma can be easily moved over a taut underlying muscle either along its long axis or at right angles to it. It is not attached to the skin, so that the skin over the swelling can be pinched up apart from the swelling. But there are fibrous strands which connect the capsule of the lipoma to the skin and that is why when the skin overlying the tumour is moved, there is dimpling on the skin.

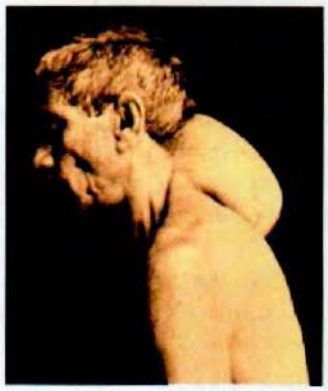

Fig.3.56.— A pedunculated lipoma at the nape of the neck.

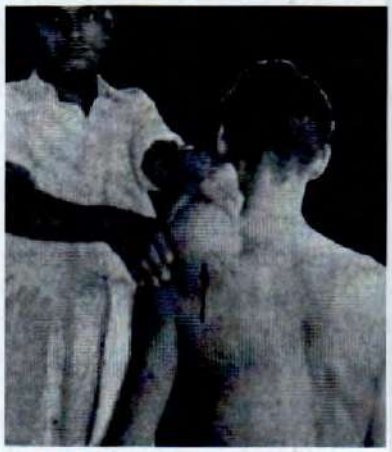

Fig.3.57.— Showing how a lipoma is freely mobile over a contracted muscle. The trapezius muscle has been made taut by shrugging the shoulder up against resistance with one hand and the lipoma is moved with the other hand.

Sometimes lipoma contains dilated blood vessels when it is called 'Naevolipoma'. If a lipoma contains excessive amounts of fibrous tissue, it is called 'Fibrolipoma'. When a lipoma contains nerve tissue, it becomes painful and is called 'Neurolipoma'.

Complications.— A lipoma when present for a long time may undergo certain changes. This is particularly true in cases of lipoma in the subcutaneous tissue of the thigh, buttock or retroperitoneal lipoma. Such changes are — (i) myxomatous degeneration, (ii) saponification, (iii) calcification, (iv) infection, (v) ulceration due to repeated trauma and (vi) malignant change (liposarcoma), which the students should always keep in mind. Certain authorities believe that lipoma never turns into malignancy. If liposarcoma does occur (more often seen in the retroperitoneal tissue), it arises de novo and not in a benign lipoma.

2. *DIFFUSE VARIETY.*— This is quite rare and does not possess the typical features of lipoma, hence it is often called *'Pseudolipoma'*. It is seen in the subcutaneous and intermuscular tissue of the neck and gradually may extend to the cheek. There is no capsule of this tumour. It hardly gives any trouble barring being unsightly. It is often found in persons taking excessive alcohol.

3. *MULTIPLE LIPOMAS.*— It is often called 'Lipomatosis'. The tumours remain small or moderate in size and are sometimes painful as these contain nerve tissue and are called *neurolipomatosis.* These are mostly seen in the limbs and in the trunk. Lipomata of the different sizes and shapes may be seen. Macroscopically and microscopically these are not different from solitary lipoma. *Dercum's disease* (adiposis dolorosa) is a variety of this condition in which there are tender lipomatous swellings particularly affecting the trunk. This is more common in women.

NEUROFIBROMA.— This tumour contains both neural (ectodermal) and fibrous (mesodermal) elements. Controversies still exist about its origin. This tumour should not be confused with *neurilemmoma (Schwannoma).* Generally neurofibroma occurs in multiple number. But local or single neurofibroma is not unseen.

Local Neurofibroma.— Neurofibroma may appear at any age but commonly seen in adults. It occurs in the subcutaneous tissue and presents as a slightly painful nodule, which is a firm, smooth swelling and can be moved in lateral direction but not along the direction of the nerve from which it arises. Paraesthesia and tingle sensation along the distribution of the nerve are quite common. This is due to pressure effect of the tumour on the nerve fibres. **Complication** though rare yet occasionally seen and these are cystic degeneration and sarcomatous changes. 'Acoustic tumour' is an example of this variety when it arises from the 8th cranial nerve.

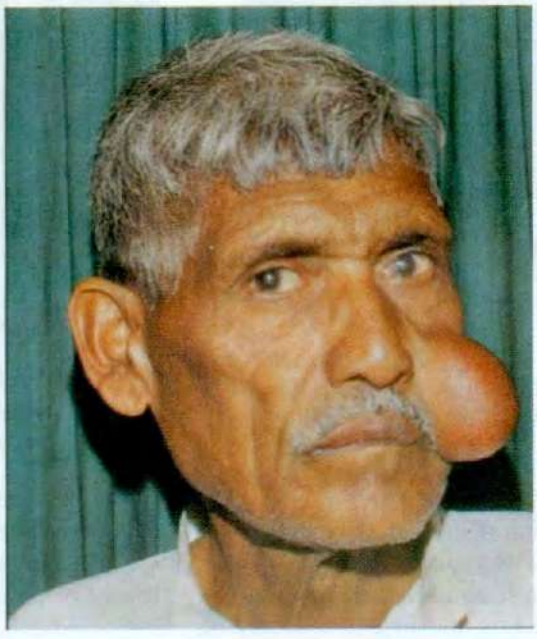

Fig.3.58.— A local neurofibroma affecting face.

Generalized Neurofibromatosis (Von Recklinghausen's disease).— These are multiple neurofibromas spread all over the body involving the cranial, the spinal and the peripheral nerves. The tumours are said to originate from the perineurium and epineurium. It is a *congenital (autosomal dominant)* disease. This condition may be associated with light brown pigmentation ('Cafe au Lait' patch), acoustic neuroma, pheochromocytoma etc. Malignant change (neurofibrosarcoma) is seen in 5% of cases. Multiple



Figs.3.59 & 3.60.— Von Recklinghausen's disease. See the text.

nodules may present even at birth, but they may increase in size and number in subsequent years. The patient is almost covered with nodules of different sizes all throughout the body. Mostly they are in the subcutaneous tissue and some may even become pedunculated. The nodules vary in consistency from very firm (even hard) to soft nodules. Neurological disturbances are uncommon. ***Complications*** are (a) Pigmentation of skin; (b) Neurological pressure symptoms e.g. deafness in acoustic neuroma, spinal cord compression by 'Dumb-bell tumour', mediastinal syndrome in case of mediastinal tumour; (c) Cystic degeneration; (d) Important sarcomatous change (Neurofibrosarcoma); (e) It may be a part of multiple endocrine adenopathy type II B in which neurofibromas affecting lips, eyelids and face are associated with medullary carcinoma of thyroid, pheochromocytoma (hypertension) and hyperparathyroidism.



Fig.3.61.— Plexiform neurofibromatosis occurring in connection with the ophthalmic division of the trigeminal nerve.



Fig.3.62.— Pachydermatocele — a rare variety of plexiform neurofibromatosis.

Plexiform Neurofibromatosis.— This tumour usually occurs in connection with the branches of fifth cranial nerve. The swelling is enormous with myxofibromatous degeneration and unsightly. It hangs down in folds. This tumour occasionally affects the upper limb and may be associated with generalized neurofibromatosis. Sarcomatous change is very rare in this condition.

Elephantiasis Neurofibromatosis.— In this condition the skin of the affected region becomes coarse dry and thickened resembling an elephant's skin. The subcutaneous tissue is replaced by fibrous tissue, which is enormously thickened and oedematous. As differential diagnosis one must remember the *other causes of elephantiasis*. These are *filarial elephantiasis, following* en bloc excision of the lymph nodes for carcinoma of the breast or penis and *elephantiasis graecorum* of nodular leprosy affecting the face and forearm.

Pachydermatocele.— It can be described as a variant of plexiform neurofibromatosis, in which the neck is affected from where coils of soft tissue hang down resulting in an unsightly deformity.

SCHWANNOMA (NEURILEMMOMA).— While neurofibroma is a benign tumour which contains a mixture of neural (ectodermal) and fibrous (mesodermal) elements, neurilemmoma

arises from Schwann cell of neurilemma which is ectodermal in origin and is so rare as to be often forgotten. It is a benign, well encapsulated tumour, which forms a single, round or fusiform firm mass on the course of a large nerve. Schwannoma is white to grey, firm and well capsulated lesion. The commonest site is the acoustic nerve, though this tumour has also been seen in the posterior mediastinum and in the retroperitoneal space. Multiple lesions are extremely rare. Neurilemmoma is a definite benign lesion and does not show any tendency to malignant transformation. Clinically, a mass of usually 1 to 2 cm may be detected along the course of a nerve. Radiating pain may be complained of along the distribution of the nerve. It gradually displaces the nerve fibres and the nerve fibres are never seen to be entangled into the tumour. It may often be asymptomatic, not tender, no nodal involvement and no tendency to malignant transformation.

LYMPHANGIOMA.— Lymphangioma is congenital in origin. Localized cluster of dilated lymph sacs in the skin and subcutaneous tissues which cannot connect into the normal lymph system grows into lymphangioma. Three types are usually seen — (a) Simple or capillary lymphangioma; (b) Cavernous lymphangioma and (c) Cystic hygroma.

(a) *SIMPLE or CAPILLARY LYMPHANGIOMA.*— This type presents as circumscribed lesion which appears as small vesicle or small blister or slightly elevated skin patch. These lesions are also called *lymphangioma circumscriptum.* The size varies from 0.5 to 4 mm in diameter. A large area of skin may be involved on the inner side of the thigh, buttock, on the shoulder or in the axilla. The whole lesion is soft and spongy. There may be multiple cysts or one or two large cysts. Fluctuation, fluid thrill and translucency test are always positive. The swelling is not compressible. The margins of the swelling are indistinct. The skin vesicles contain clear fluid which looks watery and yellow but blood in the vesicles turns them brown or dark red. The regional lymph nodes are usually not enlarged unless the cysts become infected. It must be remembered that the tissues between the cysts have normal lymph drainage and they are not oedematous. The blood and nerve supply of the area of lymphangioma circumscriptum are also normal.

(b) *CAVERNOUS LYMPHANGIOMA.*— These present as bigger lymphatic swellings and are situated rather deep as compared to the capillary variety. It occurs commonly on the face, mouth, lips (causing enormous enlargement of the lip which is called macrocheilia), the neck, the tongue (a common cause of macroglossia), the pectoral region and axilla. The lesion is a soft and lobulated swelling containing single or multiple communicating lymphatic cysts. The swelling is obviously fluctuant and brilliantly translucent. The cyst is often interspersed among muscle fibres causing difficulty in dissection for excision of the cyst.

(c) *CYSTIC HYGROMA.*— This is the most common form of lymphangioma. This exhibits large cyst like cavities containing clear watery fluid. It is in fact a collection of lymphatic sacs and probably represents a cluster of lymph channels that failed to connect into the normal lymphatic pathways. Majority (75%) of the cystic hygromata are seen in the neck. 20% are seen in

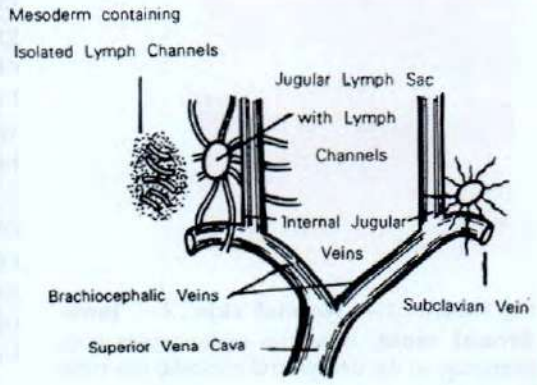

Fig.3.63.— Development of a cystic hygroma. The isolated lymph channels, which become segregated from the jugular lymph sac, form multilocular cystic hygroma at the root of the neck in the posterior triangle.

the axilla and remaining 5% are found scattered in different parts of the body — in the mediastinum, groin, pelvis and even retroperitoneum.

Macroscopically, cystic hygroma consists of multiple locules filled with lymph. In the depth the locules are bigger and towards the surface the locules become smaller and smaller in size. The content of the cyst is clear watery lymph or straw coloured fluid containing cholesterol crystals and lymphocytes. The fluid does not coagulate.

It is mostly seen in children and is usually reported to be present since birth. Disfigurement is the main symptom. The swelling is painless, though occasionally may be painful when it becomes infected. This is a soft swelling which shows positive fluctuation and translucency test. In fact this is a brilliant translucent swelling unless it is infected or when bleeding occurs inside the cyst. It is partially compressible as fluid in one loculus can be compressed into the other. It is often called *'hydrocele of the neck'* particularly when it is unilocular. The regional lymph nodes should not be enlarged unless the lesion gets infected.

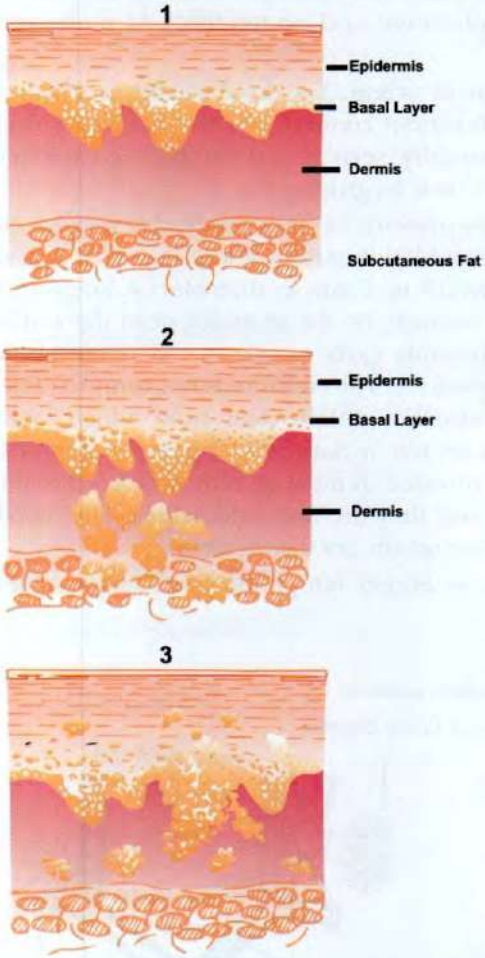

Fig.3.64.— 1.— **Normal skin**. 2.— **Intradermal mole**, here the melanocytes conglomerate in the dermis and clinically this mole looks flat or raised, smooth or warty, hairy or non-hairy and it is always benign. 3.— **Junctional mole**, here the melanocytes conglomerate in the epidermis and dermis, clinically it looks flat or raised, smooth or warty, is always non-hairy and *may turn malignant*.

Complications rarely occur in such a lesion like (i) infection, (ii) rupture of the cyst leading to lymphorrhoea; (iii) respiratory obstruction and rarely (iv) obstructed labour due to massive swelling before birth.

MOLES (pigmented naevus, freckles, benign melanoma).— 'Naevus' means a lesion which is present since birth. Although many of these may be present since birth, yet others appear later in life. This lesion contains an excess quantity of melanin, derived from melanocytes. The word 'benign melanoma' signifies that this growth is a benign neoplasm which means that its cells grow uncontrolled by the usual growth-limiting factors. But the histological feature of the mole is one of controlled overgrowth caused by excess stimulation, rather than excessive growth with normal stimulation. That is why a mole should better be called a 'Hamartoma' of melanocytes.

Every individual has a few moles at birth, and this number increases during life. Moles are more common in Caucasians living in hot countries, such as Australia, where the skin is exposed to more ultraviolet light. Though moles do occur in Negroes, but malignant change is very rare.

Disfiguring and black spot are the main symptoms. Moles can occur on any part of the body, though these are mostly seen on the limbs, the face and around the mucocutaneous junctions (the mouth and the anus). The colour varies from light brown to black. Though amelanotic moles do exist, yet without

pigment these moles cannot be recognized. Majority of the moles are 1 to 3 mm in diameter. Followings are the various **types** of moles depending on the further proliferation and growth :—

1. **HAIRY MOLE.**— This is a common variety. It is flat and slightly raised above the level of the skin. It has a smooth or slightly warty epidermal covering. It has hairs growing from its surface. There are also sebaceous glands which may become infected. This causes increase in swelling and tenderness.

2. **NON-HAIRY OR SMOOTH MOLES.**— This is also quite common. The surface is not elevated. The epithelium is smooth and there is no hair growing from its surface. The pigment is deeper than the hairy mole.

3. **BLUE NAEVUS.**— It is an uncommon variety of naevus. It is a type of mole which occurs deep in the dermis. The thick overlying layers of the dermis and epidermis mask the colour of the melanin and make it look blue. The overlying skin is smooth and shiny. It is commonly seen on the face, dorsum of the hand, feet and buttocks (mongolian spot) of babies or children.



Fig.3.65.— Cystic hygroma at the right side of the neck of a baby.

4. **JUNCTIONAL NAEVUS.**— If the growth and movements of melanocytes stop before they have all migrated into the dermis, there will be clusters of cells of various stages of maturity in the epidermis and dermis. This lesion is called a 'Junctional naevus' as it is centred around the junctional or basal layer of the epidermis. These moles are immature, unstable and can turn malignant. *In fact majority of malignant melanoma begin in junctional naevi.* Junctional naevus is a smooth or elevated naevus of all shades. This lesion may occur anywhere in the body either from the birth or appear later in life. This naevus occurs more commonly on the palms, soles, digits and genitalia. In fact any naevi occurring in these areas should be considered as junctional naevi and hence there is higher incidence of malignant melanoma in these sites.



Fig.3.66.— Shows a typical case of basal cell carcinoma.

5. **COMPOUND NAEVUS.**— From the above description it is clear that two distinct varieties of mole are

available — intradermal and junctional. When intradermal and junctional features are both present in one mole it is called a 'compound naevus'.

6. **JUVENILE MOLE.**— A mole showing junctional activity before puberty is called a 'juvenile mole'. The reason for a special name of such a mole is that microscopically it looks so active that it is often thought to be malignant, but ultimately it turns into a mature benign intradermal mole and not into a malignant melanoma.

7. **HUTCHINSON'S FRECKLE (LENTIGO).**— It is worthy of special note. This term is used to describe a large area of dark pigmentation. It is commonly seen on the face and neck in elderly people. The surface is smooth but there may be nodule of junctional activity and may turn malignant. Because the background pigmentation is so dark, areas of malignant change may pass unnoticed.

MALIGNANT :

BASAL CELL CARCINOMA (Rodent ulcer).— This tumour of low-grade malignancy is common in white-skinned people. It originates from the basal layer of the rete Malpighii of the skin. The exposed skin is commonly affected and exposure to sunlight or ultra-violet irradiation seems to be the predisposing factor, therefore Australia is the most commonly affected country. 90% of this tumour is found in the upper part of the face above the line drawn from the angle of the mouth to the lobule of the ear, the commonest site being inner or outer canthus of the eye. Middle aged or old people are usually the victims.





Figs.3.67 & 3.68.— Basal cell carcinoma, mostly seen in the upper half of the face. The 1st picture shows an early case whereas the 2nd picture shows a late case of rodent ulcer.

It starts as a small brownish-red nodule with translucent colour and shiny surface showing a net work of capillaries. At this stage it is diagnosed due to its hardness, painlessness and presence of capillaries. Later on the tumour becomes ulcerated with a well defined hard and raised edge (but not everted as seen in epithelioma) with a beaded appearance. There is a central scab but the margin gradually spreads and infiltrates into the surrounding tissues as well as deeper tissues even up to the bone. This characteristic feature of eroding the tissues, which come in contact with it, has given it the name **'rodent'**. At first it may itch, but at a later stage it may be painful if it has eroded any nerve.

Dissemination by lymphatic or blood vessels does not occur. So the *regional lymph nodes are not enlarged* and there will be no metastasis to the distant organs. There may be squamous celled carcinomatous change, though very rare.

SQUAMOUS CELL CARCINOMA (syn. epidermoid carcinoma or epithelioma).— This is a more malignant tumour than the preceding one. The elderly people are the usual victims. It may affect the normal skin but there are a few predisposing factors which the students should keep in mind. These are previously irradiated skin, a long standing ulcer e.g. varicose ulcer, scar from a burn

(Marjolin's ulcer), repeated irritation of the skin by various chemicals such as dyes, tar etc. and a few premalignant conditions such as Bowen's disease, Leukoplakia, Paget's disease etc.

This tumour originates from prickle cell layer of the skin. It may give rise to sessile cauliflower mass or fungating ulcer *with raised and everted margin*. The base is always indurated and hard as also the edge. There may be blood-stained or purulent discharge if the tumour is secondarily infected. The regional lymph nodes are often involved as lymphatic spread is quite common and takes place early. But they may be involved by secondary infection and not due to metastasis only. Metastatic lymph nodes are hard in consistency and may invade the deeper structure to be fixed and inoperable.

MALIGNANT MELANOMA.— It is a malignant tumour of melanocytes, which originate from the neural crest and so ectodermal in origin. It may occur de novo or in a benign mole. Malignant melanoma is rare before puberty, though it may even occur in children. Majority of patients range between 20 and 40 years of age. Girls are affected more than the boys in the ratio of 2 to 3 : 1. It is very common in Caucasians and extremely rare in Negroes. Melanocytes are stimulated by ultraviolet light. It is more commonly seen in the face, neck, soles, palms, digits, toes and external genitalia, which are common sites of junctional naevus. It may even occur in the choroid of the eye, in the meninges, in the rectum and anal canal and beneath the nail (which is called subungual melanoma), particularly in the thumb and great toe. The main symptom is cosmetic disfigurement caused by the enlarging lesion which brings the patient to the surgeon. Malignant melanoma is not painful, but it often itches. Sometimes lymph node enlargement or distant metastasis may be the first symptom. Colour of the tumour may vary from pale pinkish-brown to black. Usually there is a purple hue around the tumour due to rich blood supply. There is no increase of temperature and the tumour is not tender. The size varies considerably and clinically the tumour can be staged either according to Clark's level of invasion or according to Breslow, which is beyond the domain of this book and the students are referred to author's 'A CONCISE TEXTBOOK OF SURGERY'. When the tumour is small it is covered with smooth epithelium. When the tumour is bigger the overlying epithelium may die from ischaemic necrosis resulting in ulcer formation which is often covered with a crust. Bleeding and subacute infection are quite common in this tumour which make the surface often soft and boggy. The consistency of the tumour is usually firm. The regional lymph nodes are involved quite early and these are almost always enlarged when the patient presents to the surgeon. A halo of brown pigment may be seen in the skin around the tumour which indicates local infiltration of the tumour. Satellite nodules may be seen in the skin and subcutaneous tissue between the primary tumour and the nearest regional lymph nodes. This is due to lymphatic spread of the tumour by embolism which stops in the wall of the lymphatic and starts growing. These nodules are often hard in consistency. Malignant melanoma also metastasises through blood stream to the liver, lungs, bones and brain.



Figs.3.69 & 3.70.— Malignant melanoma of the eye, the liver is being palpated for secondary deposits.

As mentioned earlier malignant melanoma may occur (90%) in a pre-existing benign mole. So one must remember the cardinal symptoms and signs of malignant change in a mole. These are : (i) Sudden increase in size. (ii) Change in colour (the moles become darker which may be patchy; very occasionally malignant melanocytes do not produce melanin and the growth does not show dark colour — ***amelanotic melanoma***. (iii) Ulceration and bleeding with minor injury is quite characteristic. It may even bleed when the mole is rubbed off. (iv) There may be a pigmented halo around the tumour which indicates local spread and malignancy. Satellite nodules may also develop in the intradermal lymphatic. (v) Involvement of regional lymph nodes and distant organs e.g. the liver, the lungs, the brain etc. are indicative of malignancy.

SARCOMA.— This is a malignant tumour of connective tissue. It may occur from any structure derived from mesoblastic origin. In contradistinction to the carcinomas, the sarcomas usually affect younger age group. These are rapid growing tumours and disseminate mainly by the blood stream (cf. carcinoma). Lymphatic spread does not occur early and is not important in these tumours. Sarcomatous cells produce similar tissue from which they originate, e.g. osteosarcoma, fibrosarcoma, chondrosarcoma etc.

The tumours very rapidly infiltrate neighbouring structures. The patients usually present with a big swelling with varying consistency, diffuse margin and the skin over the swelling becomes stretched, glossy with engorged veins. As the growth is very vascular, pulsation may be felt (Telangiectatic sarcoma). As the blood-spread is very common, the lungs are often affected with metastasis.

SYNOVIAL SARCOMA (Syn. malignant synovioma).— This highly malignant tumour arises from the synovial membrane of a joint, tendon sheath or a bursa. It may occur at any age but the boys of the second and third decades are usually affected.

The patients usually present with a swelling at or near a joint, pain in the affected joint and limitation of movements of the said joint. X-ray shows a soft tissue shadow with flecks of calcification, but there is seldom any alteration of the joint line. Skiagraphy of the chest may reveal pulmonary metastasis. The diagnosis is confirmed by biopsy which will reveal mass of fusiform cells.



Fig.3.71.— Fibrosarcoma (a rare tumour) at the lower part of the back.

OTHER SWELLINGS :

SEBACEOUS CYST.— This is a cyst of the sebaceous gland due to blockage of the duct of this gland which opens mostly into the hair follicle. The gland becomes distended by its own secretion. Obviously it contains sebum, which is yellowish white cheesy pultaceous material. Almost always there is a black spot on the swelling, which is the obstructed opening and is called *punctum*. This swelling is fixed to the skin but is quite movable over the deeper structures. Sebum can be squeezed

out from this cyst through the punctum. Sometimes punctum is not visible, so other theories have come up to indicate its origin. These are — (i) it arises from a fragment of epidermal cell nest following blunt or penetrating injury; (ii) it arises from hair follicle. It is commonly seen in young adults, though no age is exempt. It may occur anywhere in the body except palm and sole, though it is commonly seen in the scalp, face and scrotum. It may be single or multiple. It is smooth and of round shape whose margin yields to the palpating finger. Fluctuation test is always present though transillumination test is always negative.

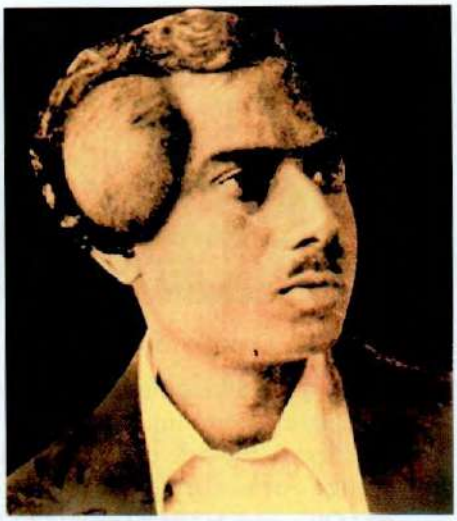

Fig.3.72.— Shows a big sebaceous cyst on the outer side of the forehead. Note the baldness over the cyst — a characteristic feature.



Fig.3.73.— Cock's peculiar tumour of the scalp.

Complications are — (a) Infection when the cyst becomes enlarged and painful; (b) Ulceration; (c) Rupture and sinus formation; (d) Calcification; (e) Carcinomatous change; (f) Cock's peculiar tumour and (g) Sebaceous horn.

After the sebaceous cyst has been ruptured and chronic infection spreads to the surrounding tissues from the sebaceous cyst it may lead to a painful, boggy, fungating and discharging mass, quite often known as ***Cock's peculiar tumour*** (Fig.3.73).

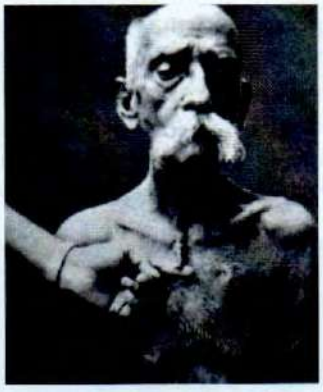

Fig.3.74.— Sebaceous horn.

Sometimes slow discharge of sebum from a wide punctum may harden as soon as it comes out to form a ***Sebaceous horn*** (Figs.3.72 & 3.74), which is nothing but inspissated sebaceous material.



Fig.3.75.— Sebaceous horn over the knee.

CONDYLOMA.— This is a manifestation of the secondary stage of syphilis. It is nothing but hypertrophy of the epidermis occurring at the



Fig.3.76.— Condyloma at the anus.

mucocutaneous junction e.g. angle of the mouth, anus (Fig.3.76), vulva etc. It looks like a fungating, sessile, raised but flat growth with moist and sodden surface.

WARTS.— These are patches of overgrown skin with hyperkeratosis. This may occur at any age but commonly found in children, adolescents and young adults. In the first few weeks these swellings grow upto their full sizes. The growth seems to be stimulated by a virus.

The main complaint of the patient is disfiguring. Sometimes the warts become painful when they are repeatedly rubbed or become infected. These usually persist for quite a long time and even they disappear. Kiss lesions may appear in the skin where they frequently come into contact with warts. This condition frequently affects the hands, the face, the knees, the sole of the feet (plantar warts) and axilla. Warts are usually firm and covered with rough surface and filiform excrescences. This disease seems to be a familial one.

KELOID and **HYPERTROPHIC SCAR.**— This is not a tumour but an overgrowth of the fibrous tissue which is concerned in wound healing and strengthening of the wound. A wound contains blood and fibrin, which is replaced by collagen and fibrous tissue and finally the fibrous tissue is organized to give the wound maximum strength. Nature controls this healing process in such a manner that normally the scars are thin with minimum fibrous tissue.

In abnormal cases there may be an excessive amount of fibrous tissue in the scar, which is called **hypertrophic scar**. Predisposing factors seem to be extra stimulus to the fibrous tissue formation during healing process. These are infection, excessive tension, the incision which crosses natural creases (Langer's lines) etc. In contradistinction to the hypertrophic scar, *in a keloid the fibrous tissue extends beyond the original wound* into the normal tissue and gradually infiltrates the surrounding healthy tissue. These often occur after

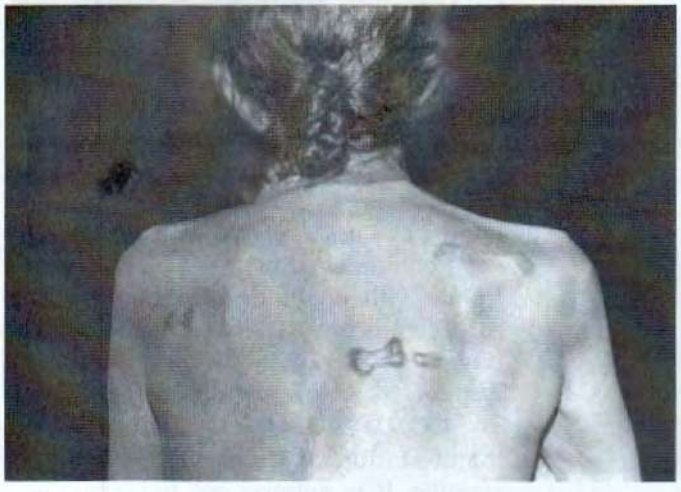

Fig.3.78.— Keloids at the back.

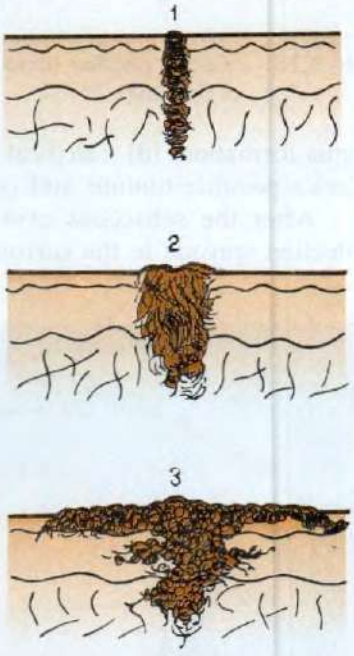

Fig.3.77.— 1.— Normal scar; 2.— Hypertrophic scar; 3.— Keloid.

burns, healing of an ulcer, vaccination or even after healing of small boils (Figs.3.2, 3.3 & 3.4).

A **keloid** is unsightly, sometimes tender and itching. It is an irregular firm elevation of the skin with finger like extensions. That the keloid is spreading can be determined by noting its edge which is pink and more tender. The following points should be remembered to differentiate a keloid from a hypertrophic scar: (i) it is itching, (ii) it is spreading, (iii) it is tender and (iv) it is vascular. The last but not the least point, which the students should always keep in mind, is its tendency to affect the Negroes and tuberculous patients.

CALLOSITY and **CORN.**— These conditions are quite common and are not unknown to anybody. A **callosity** is a raised thickened patch of hyperkeratosis commonly seen in areas of the body which undergo excessive wear and tear and repeated minor traumas e.g. gardener's hand. Histologically there is increased thickening of the epidermis, particularly the stratum corneum and the granular layer.

A **corn** on the other hand is a circumscribed horny thickening, cone-like in shape with its apex pointing inwards and the base at the surface. Being circumscribed it is palpable as a nodule. It is thicker than a callosity and causes more concern to the patient. This occurs at the site of friction and often spontaneously disappears when the causing factor is removed. Histologically it is composed of keratin masses with intact basal layers. It is often caused by ill-fitting and tight shoes chiefly affecting feet and toes.

KERATOACANTHOMA (Molluscum Sebaceum).— It is a rapidly developing tumour composed of keratinising squamous cells and is usually situated on the exposed areas of skin and resolves spontaneously even untreated. It is commonly seen in middle life or older age and males are affected more commonly than females (3:1). Predisposing factors are (i) Exposure to Sun as this lesion is more often seen in the face, head and upper limbs, (ii) Contact with tar and mineral oil and (iii) Infection may play a role.

Pathologically, the tumour is situated in the dermis and globular in form. The epidermis is thin over the lesion from which it is separated by narrow connective tissue except at the mouth where the lesion and the epidermis are connected. The lesion is proliferating squamous cells arising from the sebaceous gland and progresses along the duct of the gland. This lesion is more often seen in places where there are plenty of sebaceous glands.

Clinically, this lesion presents as a firm, rounded reddish papule or nodule which gradually increases in size for first 6 to 8 weeks and may reach a size of about 2 cm in diameter. The bulk of the lesion is firm and rubbery, but the central core is hard. The epidermis over it is smooth and shiny. There may be telangiectases with reddish surface. The centre contains horny plug covered by a dark brown crust. The crust falls off, ulcer develops and the lesion starts regression spontaneously. Spontaneous healing takes about 6 months. Recurrence is noticed following spontaneous resolution or surgery particularly in lips and fingers. The progress of the growth made many people in the past to regard this lesion as an epithelioma, but spontaneous regression favours this diagnosis. Regional lymph nodes are not enlarged.

The origin of the lesion seems to be the sebaceous gland from which keratosis starts surrounding the duct of the gland. The cause is unknown. This lesion commonly affects older people and occurs mostly in the face or in places where there are plenty of sebaceous glands.

GRANULOMA PYOGENICUM (Pyogenic granuloma).— This lesion looks like a haemangioma — dark, red, firm small nodule of 1 to 2 cm diameter. This lesion is an over-growth of the granulation tissue which is being stimulated by chronic infection. This *rapidly growing swelling* bleeds easily and is not at all painful. This lesion occurs mostly in the face and the hands which are likely to be injured more frequently. This lesion may become infected. It bleeds easily. Very

rough handling may break it off at its base with slight bleeding, but only to reform within a few days. One should exclude squamous carcinoma.

SEBORRHOEIC WART (Senile wart or Seborrhoeic Keratosis or basal cell Papilloma).— This is a benign tumour which is mostly seen in the elderly and women at the time of menopause. It is commonly seen in Caucasians and rare among Indians and Negroes. It occurs commonly in the face, trunk and arms. Both sexes are almost equally involved. This seems to be a familial disease transmitted by autosomal dominant gene.

Pathologically, it is a benign overgrowth of the epidermis containing swollen abnormal epithelial cells, which raise the lesion above the level of normal skin. It is semitransparent and assumes oily appearance. Malignant change has been recorded particularly when skin is exposed to carcinogen, otherwise it is extremely rare.

Clinically, it presents as a raised, hypertrophic slightly greasy skin with rough papilliferous surface with distinct margin. Size varies from a few millimetres to 2 to 3 cm in diameter. It is a slow growing lesion. It seldom bleeds by trauma which makes the lesion swell and turn brown, which may confuse this lesion with melanoma. This lesion may become infected and painful. It is a little firmer than normal skin and can be picked up. Regional lymph nodes are not enlarged.

SOLAR KERATOSIS (Senile Keratosis).— As the name suggests it is a hyperkeratotic lesion of the skin and the predisposing factor is prolonged exposure of the skin to the sun. Obviously the common sites are the face, the ears, the dorsal aspects of the hands and fingers. The usual victims are old people who have engaged themselves very much in outdoor activities. At first the lesion occurs as thickened patch having yellowish grey or brown colour. It may turn into an ulcer with slight central cavity and raised plaque of skin at the periphery. This lesion is very much localized to the skin and its involvement to the underlying structure simply indicates malignant transformation. *It is a potentially malignant condition.* It takes about 10 years for malignant transformation and the result is squamous cell carcinoma which is slow growing with little tendency to metastasise. Regional lymph nodes are not involved but if they are involved it indicates malignant transformation.

BOWEN'S DISEASE.— *This is a precancerous condition.* The lesion looks like brown indurated thickened mass covered with crust with well defined edge. When crusts are removed the papules can be seen to have oozy, slightly bloody, papilliferous surface. The lesion may ooze serosanguineous discharge. The condition must be suspected and biopsy should be advised, which will reveal large clear cells as found in Paget's disease. It occurs equally in the exposed and covered areas, particularly at sites of repeated trauma. Its usual victims are the old people. 50% of patients will develop malignant cancer of the skin in about 6 to 8 years time.

Chapter

4 EXAMINATION OF AN ULCER

An ulcer is a break in the continuity of the covering epithelium — skin or mucous membrane. It may either follow molecular death of the surface epithelium or its traumatic removal.



Fig.4.1.— Epitheliomatous ulcer.

HISTORY.— The following points are particularly noted in the history of a case of an ulcer:

1. **Mode of Onset.**— How has the ulcer developed— following a trauma or spontaneously? Traumatic ulcers generally heal by themselves if the traumatic agent is removed. But the ulcer may take a turn towards chronicity if the trauma continues that means traumatic agent persists, e.g. dental ulcer of the tongue. Again healing of an ulcer is delayed if it lies over a joint for want of rest.

Ulcers which originate spontaneously may follow swelling, which may be matted tuberculous lymph nodes or gumma or a rapidly growing malignant tumour (epithelioma or malignant melanoma). Ulcers may be present in the leg with varicose veins or vascular insufficiency. Sometimes a malignant ulcer (Marjolin's) may develop on the scar of a burn. See Fig.4.12.

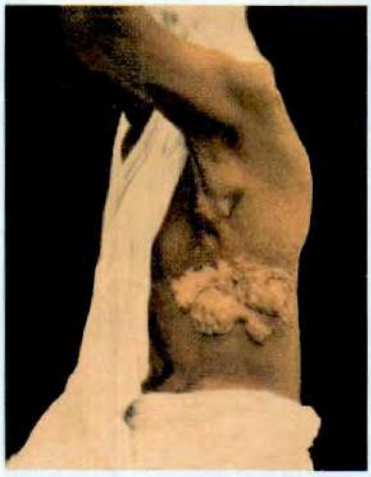

Fig.4.2.— Marjolin's ulcer developed at the loin from the scar of a burn.

2. **Duration.**— How long is the ulcer present there? An acute ulcer will be present for a shorter duration, whereas a chronic ulcer will remain for a long period. In this context, one must also know *the incubation period*, i.e. the time interval between the exposure and the onset of the ulcer. In Hunterian chancre (Syphilis) this incubation period is 3 to 4 weeks, whereas in chancroid (soft sore) this period is about 3 to 4 days.



Fig.4.3.— Marjolin's ulcer developed in the scar of a burn.

3. **Pain.**— Is the ulcer painful? Only those ulcers associated with

inflammation will be painful. Syphilitic ulcers and trophic ulcers resulting from nerve diseases (tabes dorsalis, transverse myelitis, peripheral neuritis) are painless. Tuberculous ulcers are slightly painful. Ulcers from malignant diseases such as epithelioma or basal-cell carcinoma are absolutely painless to start with and never become painful unless they infiltrate structures supplied by pain nerve endings.

4. **Discharge.**— Does the ulcer discharge or not? If it discharges enquiry must be made about its nature — serum, pus or blood.

5. **Associated disease,** if present.— Nervous diseases such as tabes dorsalis, syringomyelia, transverse myelitis and peripheral neuritis may result an ulcer (trophic or perforating ulcer). Generalized tuberculosis, nephritis or diabetes may lead to ulcer formation. Syphilis at the primary stage gives rise to chancre and in the tertiary stage gives rise to a gummatous ulcer.

PHYSICAL EXAMINATION

GENERAL SURVEY.— In case of ulcer, one should not give all attention to the ulcer only. Due consideration must be given to the general examination of the patient. Ulcer may well be a sequel of malnutrition, general atherosclerosis, syphilis, tuberculosis etc.

LOCAL EXAMINATION

A. **INSPECTION.**— The following points are particularly noted :—

1. **Size and Shape.**— *Tuberculous ulcers* are generally oval in shape but their coalescence may give an irregular crescentic border. *Syphilitic ulcers* are similarly circular or semilunar to start with but may unite to form a serpiginous ulcer. *Varicose ulcers* are generally vertically oval in shape. *Carcinomatous ulcers* are irregular in size and shape. The size of an ulcer is important to know the time which will be required for healing. A bigger ulcer will definitely take a longer time to heal. To record exactly the size and shape of an ulcer, a sterile gauge may be pressed on to the ulcer to get its measurements.

2. **Number.**— Tuberculous, gummatous, varicose ulcers and soft chancres may be more than one in number.

3. **Position.**— This is very important and often by itself gives a clue to the diagnosis. An ulcer on the medial malleolus of a lower limb which shows varicose veins, is obviously a *varicose ulcer. Rodent ulcers* are usually confined to the upper part of the face above a line joining the angle of the mouth to the lobule of the ear, occurring frequently near the inner canthus of the eye (see Fig.3.69). *Tuberculous ulcers* are commonly seen where tuberculous adenopathy is commoner, that means in the neck, axilla (Figs. 4.8 & 4.9) or groin. *Lupus* — a form of cutaneous

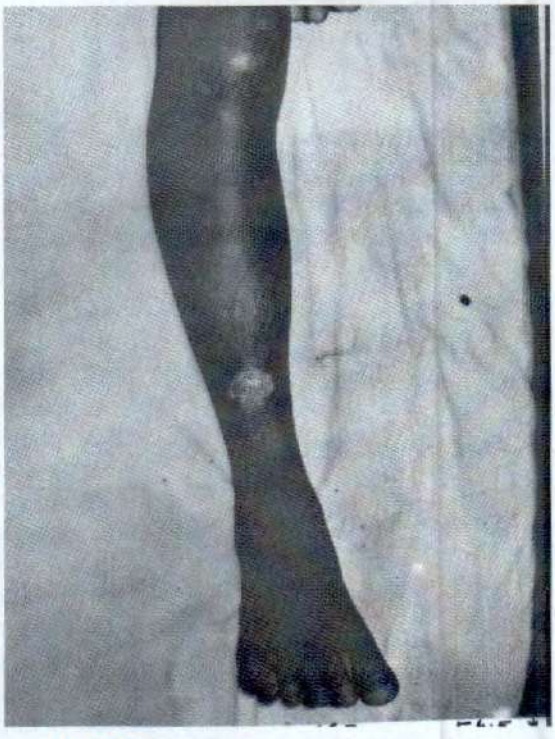

Fig.4.4.— Chronic ulcer in the leg, which refuses to heal.



Fig.4.6.— Lupus Vulgaris — a form of cutaneous tuberculosis occurring on the face.

tuberculosis occurs more frequently on the face, fingers and the hand. *Hunterian chancre* and *soft sores* will obviously be found over the external genitalia. *Gummatous ulcers* are more commonly seen over the subcutaneous bones such as tibia, sternum, skull etc. *Perforating* or *trophic ulcers* are commoner on the heel of the foot or on the ball of the foot, which carries maximum weight of the body. *Malignant ulcers* may occur anywhere in the body but more commonly seen on the lips, tongue, breast, penis and anus.





Figs.4.8 & 4.9.— Typical undermined edge of a tuberculous ulcer in the axilla. The probe can be easily insinuated between the edge and the floor of the ulcer. Also note in Fig.4.8 the scars of healed tuberculous ulcers in the neck.

4. Edge.— This is another important finding of an ul-cer which by itself not only gives a clue to the diagnosis of the ulcer but also to the condition of the ulcer. The term *'edge'* should not be confused with the term *'margin'* (see palpation in page 65). In a *spreading ulcer*, the edge is inflamed and oedematous



Fig.4.5.— Rodent ulcer in its late stage.

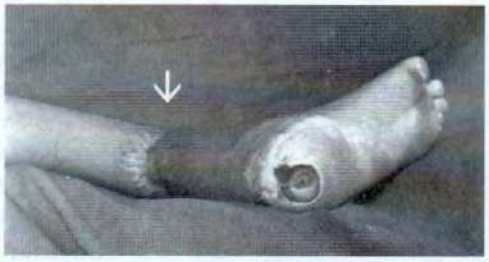

Fig.4.7.— Trophic ulcer at the heel resulting from nerve injury, the scar of which is shown by arrow.



Fig.4.10.— Venous ulcer in its typical site. Note the varicose veins in the upper part of the leg and thigh.

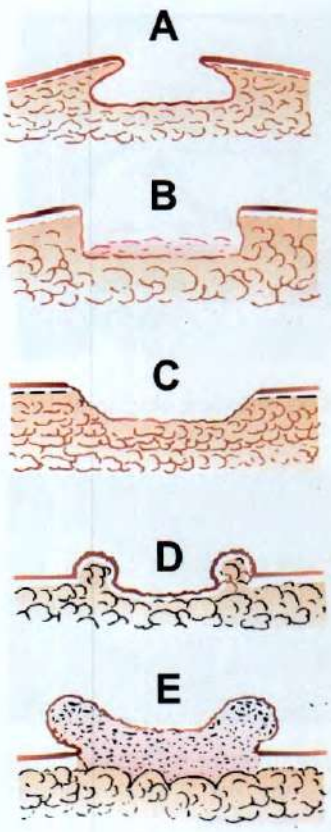

Fig.4.11.— Diagrammatic representation of different types of edge of ulcers. (A) Undermined edge. (B) Punched out edge. (C) Sloping edge. (D) Raised and a pearly-white beaded edge of rodent ulcer. (E) Rolled out (everted) edge of an epithelioma.

whereas in a *healing ulcer* the edge, if traced from the red granulation tissue in the centre towards periphery, will show a blue zone (due to thin growing epithelium) and a white zone (due to fibrosis of the scar).



Fig.4.12.— A chronic ulcer in the gluteal region which has followed burn and is taking a turn towards Marjolin's ulcer.

Five common types of ulcer edge are seen in surgical practice (See Fig. 4.11) :—

(i) *Undermined edge* — is mostly seen in tuberculosis. The disease causing the ulcer spreads in and destroys the subcutaneous tissue faster than it destroys the skin. The overhanging skin is thin, friable, reddish blue and unhealthy. (ii) *Punched out edge* — is mostly seen in a gummatous ulcer or in a deep trophic ulcer. The edge drops down at right angle to the skin surface as if it has been cut out with a punch. The diseases which cause the ulcers are limited to the ulcer itself and do not tend to spread to the surrounding tissue. (iii) *Sloping edge* is seen mostly in healing traumatic or venous ulcers. Every healing ulcer has a sloping edge, which is reddish purple in colour and consists of new healthy epithelium. (iv) *Raised and pearly-white beaded edge* — is a feature of rodent ulcer. This type of edge develops in invasive cellular disease and becomes necrotic at the centre. (v) *Rolled out (Everted)* edge — is a characteristic feature of squamous-celled carcinoma or an ulcerated adenocar-cinoma. This ulcer is caused by fast growing cellular disease, the growing portion at the edge of the ulcer heaps up and spills over the normal skin to produce an everted edge.



Fig.4.13.— Shows how to palpate for the base of the ulcer.

5. **Floor.**— This is the exposed surface of the

ulcer (cf. base, at the bottom of the next page). When floor is covered with red granulation tissue, the ulcer seems to be healthy and healing. Pale and smooth granulation tissue indicates a slowly healing ulcer. Wash-leather slough (like wet chamois leather) on the floor of an ulcer is pathognomonic of gummatous ulcer. One must be very careful to note what is there at the floor of an ulcer. A trophic ulcer penetrates down even to the bone, which forms the floor in this case. A black mass at the floor suggests malignant melanoma.

6. **Discharge.**— The character of the discharge should be noted, its amount and smell. A healing ulcer will show scanty serous discharge, but a spreading and inflamed ulcer will show purulent discharge. Sero-sanguineous discharge is often seen in a tuberculous ulcer or a malignant ulcer. If the ulcer is infected with B-pyocyanea, the discharge will be greenish. It is always advisable to take a bacteriological swab of the ulcer.

7. **Surrounding area.**— If the surrounding area of an ulcer is glossy, red and oedematous, the ulcer is acutely inflamed. Very often the surrounding skin of a varicose ulcer is eczematous and pigmented. A scar or a wrinkling in the surrounding skin of an ulcer may well indicate an old case of tuberculosis.

8. Even the **whole limb** should be examined in case of an ulcer. Presence of varicose vein and deep vein thrombosis will indicate the ulcer to be a varicose ulcer. Neurological insufficiency will indicate the ulcer to be a trophic one.

B. **PALPATION.**—

1. **Tenderness.**— An acutely inflamed ulcer is always exquisitely tender. Chronic ulcers such as tuberculous and syphilitic ulcers are slightly tender. Varicose ulcers may or may not be tender. Neoplastic ulcers are never tender.

2. **Edge and margin.**— These two terms should not be confused and both these terms demand separate entity. *'Margin'* is the junction between normal epithelium and the ulcer, so it is the boundary of the ulcer (see Fig. 4.14). ***'Edge'*** is the area between the margin and the floor of the ulcer. Activity is maximum at the margin and edge of the ulcer, though the degree of activity will vary according to the type of the ulcer.



Fig.4.14.— Diagrammatic representation of various parts of an ulcer. See the text.

In palpation the different types of the edge of the ulcers are corroborated with the findings of inspection. Besides this, a careful palpation of the edge and the surrounding tissue will give a clue to the diagnosis. Marked induration (hardness) of the edge is characteristic feature of a carcinoma, be it a squamous-celled carcinoma or adenocarcinoma. A certain degree of induration or thickness is expected in any chronic ulcer, whether it is a gummatous ulcer or a syphilitic chancre or a trophic ulcer.

3. **Base** (On which the ulcer rests).— The students must understand the difference between the floor (i.e. exposed surface within the ulcer) and the base (on which the ulcer rests and it is better felt than seen) of an ulcer. If an attempt is made to pick up the ulcer between the thumb and the index finger, the base will be felt. Slight induration of the base is expected in any chronic ulcer but marked induration (hardness) of the base is an important feature of squamous-celled carcinoma and Hunterian chancre.

4. **Depth.**— The students must make an assessment regarding depth of the ulcer. It can be recorded in the examination sheet in millimetres. Trophic ulcers may be as deep as to reach even the bone.

5. **Bleeding.**— Whether the ulcer bleeds to touch or not? It is a common feature of a malignant ulcer.

6. **Relations with the deeper structures.**— The ulcer is made to move over the deeper structures to know whether it is fixed to any of these structures. A gummatous ulcer over a subcutaneous bone (tibia or sternum) is often fixed to it. Malignant ulcer will obviously be fixed to the deeper structure by infiltration.

7. **Surrounding skin.**— Skin around the ulcer must be palpated and examined. Increased temperature and tenderness of the surrounding skin indicates the ulcer to be of acute inflammatory origin. The mobility of the surrounding skin is examined. Fixity to deeper structures indicates the malignant nature of the lesion. Surrounding skin is tested for nerve lesion (loss of sensation or motor deficit). Try to feel the peripheral nerves around for abnormal thickening or tenderness. Feel the main arteries supplying the part. The artery may be blocked (atherosclerotic, Buerger's disease, Raynaud's disease) in case of arterial or ischaemic ulcer. It is imperative to know the state of vein around the ulcer particularly when venous ulcer is suspected. Venous ulcer may or may not be associated with varicose veins of the limb.

C. **EXAMINATION OF LYMPH NODES.**— This part of the examination is very important, but unfortunately the students often forget to do this. In *acutely inflamed ulcers,* the regional lymph nodes become enlarged, tender and show the signs of acute lymphadenitis. Later on, the nodes become soften to form an abscess. In *tuberculous ulcer* the lymph nodes become

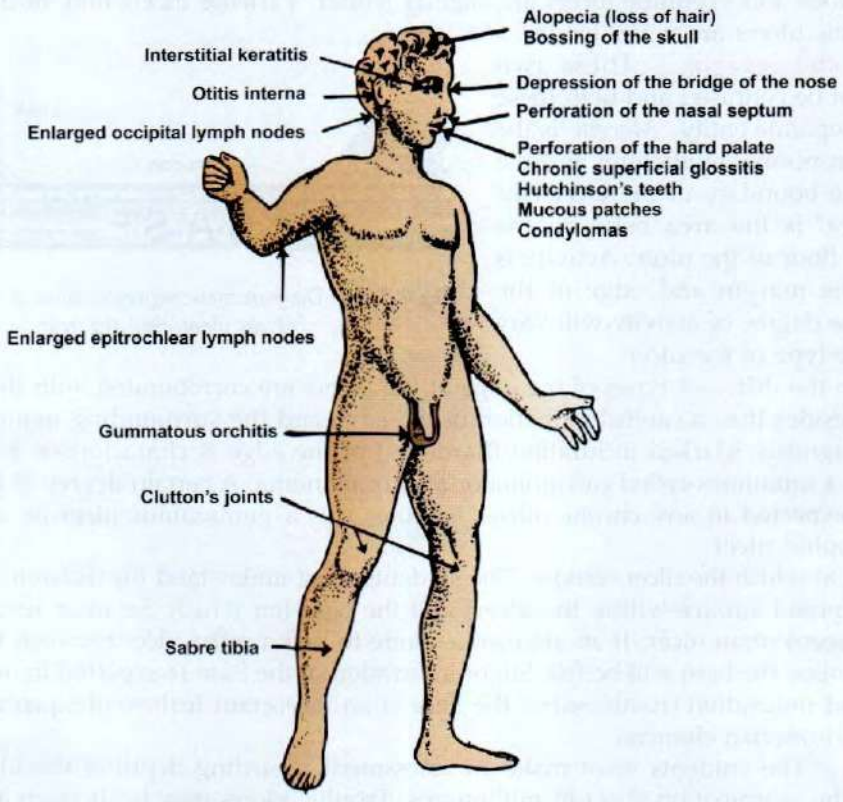

Fig.4.15.— Shows the common sites of syphilitic stigmas.

enlarged, matted and slightly tender. In *Hunterian chancre,* the regional lymph nodes remain discrete, firm and shotty. This type of lymph nodes is pathognomonic of hard (Hunterian) chancre. In *gummatous ulcers,* the lymph nodes are not usually involved. In *rodent ulcer* also the lymph nodes are not affected possibly because of the early obliteration of the lymphatics by the neoplastic cells. In *malignant ulcer* the nodes are stony hard and may be fixed to the neighbouring structures in late stages. Simple enlargement of lymph nodes in malignant disease does not suggest lymphatic metastasis. The lymph nodes may be enlarged because of secondary infection rather than anything else. So palpation of the lymph nodes in case of malignant ulcer is very important. Stony hard consistency will suggest secondary involvement.

D. **Examination for vascular insufficiency.**— When the ulcer is situated on the lower part of the leg, one should always search for *varicose veins* in the upper part of the leg or thigh. If there is no varicose vein and the cause of ulcer is not determined, the clinician must examine the condition of the arteries proximal to the ulcer. Atherosclerosis, Buerger's disease, Raynaud's disease etc. may be the cause of the ulcer from poor circulation.

E. **Examination for nerve lesion.**— Trophic ulcers develop as a result of repeated trauma to an insensitive part of the patient's body. This is mostly seen in the sole, as this is the weight-bearing zone if there is sensory loss. It may well lead to ulcer formation. So presence of trophic ulcer indicates some neurological (particularly sensory) disturbance, either in the form of tabes dorsalis or transverse myelitis or peripheral neuritis.

GENERAL EXAMINATION

1. When the ulcer is suspected to be *syphilitic,* a thorough search should be made for presence of other syphilitic stigmas in the body as shown in Fig.4.15.
2. If the ulcer appears to be *tuberculous,* all the lymph nodes in the body should be examined along with other examination such as the chest, the neck, the abdomen etc.
3. If the ulcer seems to be due to atherosclerotic or Buerger's disease *(ischaemic),* the whole body must be examined for presence of atherosclerosis or its complication anywhere in the body. Moreover Buerger's disease is a bilateral condition and the other limb should always be examined.
4. When the ulcer is a *trophic* (perforating) one general examination must be made to know the type of nervous disease present with this condition.

SPECIAL INVESTIGATIONS

1. **Routine examination of the blood** — e.g. total count and differential count of W.B.C., haemoglobin percentage, R.B.C. count, erythrocyte sedimentation rate (E.S.R.) should always be done in a patient with an ulcer. Blood sugar estimation may be performed to exclude diabetes. W.R. and Kahn test should be done to exclude syphilis. In tuberculous ulcers, lymphocyte count will be high and E.S.R. will also be high. The patient may be anaemic.
2. **Examination of the Urine** — particularly sugar estimation, to exclude diabetes, is important.
3. **Bacteriological examination of the discharge** of the ulcer is particularly important in inflamed and spreading ulcers. This will not only give a clue as to the type of organism present in the ulcer, but also its sensitivity to a particular antibiotic. 'In dark ground illumination' *Treponema pallidum* can be detected from the serous discharge of hard chancre. The chancre is first cleaned with saline, the serous discharge from the chancre is taken with a platinum loop and placed on

a slide, which is seen under microscope 'in dark ground illumination'. Discharge from tuberculous ulcer will show acid fast bacilli and should be sent for guineapig inoculation test.

4. **Skin test.**— Mantoux test is more important in children to diagnose tubercular ulcer and in adults to exclude tubercular ulcer.

5. **Chest X-ray** — is important in tuberculous ulcers to detect any primary focus in the lung. It is important to exclude metastatic deposit in the lungs in case of malignant ulcers.

6. **Biopsy** — in malignant ulcers, is very important. The biopsy is generally taken from the edge of the ulcer taking a portion of surrounding healthy tissue. Biopsy material is then examined histologically to know the type of tumour, its invasiveness and whether differentiated or anaplastic.

7. **X-ray of the Bone and Joint** — is required when the ulcer is situated very near a bone or joint. In gummatous ulcer, it produces new bone formation and 'sabre tibia', which is discussed more elaborately in the chapter of "Examination of bony lesion".

8. **Contrast Radiography.**— Arteriography may be helpful to diagnose arterial or ischaemic ulcer. Ascending functional phlebography is helpful to diagnose deep vein thrombosis in case of venous ulcer.

9. **Imaging Technique.**— 1. *Radioactive fibrinogen test* using ^{125}I-labelled fibrinogen is quite accurate (90%) in detecting deep vein thrombosis particularly in its formation stage. 2. *Technetium*^{99} clearance is used to know the blood flow of the calf muscle. More recently this isotope is used to take arterial imaging with gamma camera.

CLASSIFICATION OF ULCERS

Two types of classification of ulcers are possible :— clinically and pathologically.

CLINICALLY, an ulcer may be either of 3 types.— (a) **Spreading ulcer,** when the surrounding skin of the ulcer is inflamed and the floor is covered with profuse and offensive slough without any evidence of granulation tissue. The edge is inflamed, oedematous and ragged. It is a painful ulcer. The draining lymph nodes are inflamed, enlarged and tender and may be suppurated with abscess formation.

(b) **Healing ulcer** means the ulcer is healing. The floor is covered with pinkish or red healthy granulation tissue. The edge is reddish with granulation, while the margin is bluish with growing epithelium. The discharge is slight and serous.

(c) **Callous or Chronic ulcer** means the ulcer shows no tendency towards healing. The floor is covered with pale granulation tissue. Sometimes it shows typical wash-leather slough in gummatous ulcer which is an example of this type. Discharge is scanty or absent. The base is considerably indurated and so is the edge and surrounding skin.

PATHOLOGICALLY, the ulcers can be classified into :

(A) **Non-specific ulcers.**— These ulcers can be further classified into the following categories — (1) *Traumatic* — can be either (i) mechanical, e.g. dental ulcer of the tongue from jagged tooth, from pressure of a splint etc. or (ii) physical from electrical or X-ray burn or (iii) chemical from application of caustics. These types of ulcers heal quickly and do not become chronic unless supervened by infection or ischaemia, which may turn this ulcer to chronicity. (2) *Arterial* — as occurs in atherosclerosis, Buerger's disease, Raynaud's disease (primary and secondary) etc. (3) *Venous* — e.g. varicose ulcer in postphlebitic limb. (4) *Neurogenic (Trophic)* — e.g. bed sore and perforating ulcer. (5) *Associated with malnutrition* e.g. tropical ulcers, which occur in the legs and feet of the people in the tropical countries. Infection by Vincent's organisms (Bacteroides Fusiformis) from a small abrasion may cause such ulcer. Wrongly, ulcers secondary to anaemia,

rheumatoid arthritis, diabetes, avitaminosis are sometimes included under this type of ulcer, but these ulcers should be classified separately. (6) Ulcers *may be associated with certain other diseases* like gout, diabetes, anaemia, avitaminosis, erythrocyanosis frigida, rheumatoid arthritis etc. In gout the skin over the gouty deposit (tophi) ulcerates and the chalky contents exude. In diabetes slight injury to the glucose laden tissue may cause chronic infection and subsequently ulcer develops, it can also occur from ischaemia due to diabetic atherosclerosis and diabetic polyneuropathy. (7) *Certain other types of ulcers* require special mention e.g. Bazin's ulcer, Martorell's ulcer etc. Bazin's ulcer is found in fatty adolescent girls particularly on the calves as purplish nodules followed by indolent ulcers. Martorell's or hypertensive ulcer is found in people suffering from hypertension. It often affects legs where patches of skin necrosis are first noticed. It cannot be classified under arterial group as it is not generally associated with atherosclerosis.

(B) **Specific ulcers** — e.g. Tuberculous, syphilitic, soft sores, actinomycosis (see chapter 23 of this book and page 90 of Author's 'A CONCISE TEXTBOOK OF SURGERY') and Meleney's ulcers.

(C) **Malignant ulcers** — e.g. Epithelioma, Marjolin's ulcer, rodent ulcer (see page 54) and malignant melanoma (see page 54).

DIFFERENTIAL DIAGNOSIS

Traumatic ulcer.— Traumatic ulcer can be either (i) *mechanical*, e.g. dental ulcer of the tongue from jagged tooth, from pressure of a splint etc. or (ii) *physical* from electrical or X-ray burn or (iii) *chemical* from application of caustics. This ulcer heals quickly unless supervened by infection or ischaemia, which may turn this ulcer to chronicity.

Ischaemic or Arterial ulcer.— These ulcers are rare compared to venous ulcer. Arterial ulcers are due to peripheral arterial disease (atherosclerosis is the commonest followed by Buerger's disease and Raynaud's disease) and poor peripheral circulation. This condition is more often seen in older people and are episodes of trauma and infection of the destroyed skin over a limited area of the leg or the foot. When it occurs secondary to Buerger's disease, younger men between 20 and 40 years of age are affected. In this case patches of dry gangrene may be present alongwith arterial ulcer. Such ulcers tend to occur on the anterior and outer aspects of the leg, dorsum of the foot, on the toes or the heel (the parts exposed to trauma).

Unlike venous ulcer (which is painless) pain is the main complaint of this disease. When this ulcer occurs on the inner side of the ankle, possibility of venous ulcer should be excluded. Venous ulcer usually occurs above the medial malleolus, whereas arterial ulcer tends to occur below the medial malleolus. Moreover there is often a history of intermittent claudication and even rest pain in majority of cases of arterial ulcer. If the leg is kept elevated above the heart level, the ulcer shows no sign of healing and the patient will complain of pain in this position. *On examination* these ulcers are punched out with destruction of the deep fascia (cf. venous ulcer). The tendons, bone or underlying joints may be exposed in the floor of the ulcer which is covered by minimal granulation tissue. Peripheral arterial pulses should always be felt. Pulse of dorsalis pedis artery is almost always either feeble or absent. Presence of ischaemic changes can be detected in the foot e.g. pallor, dry skin, loss of hair, fissuring of nails etc. Arteriography is important to detect the arterial disease.

Venous ulcer.— These ulcers are typically situated on the medial aspect of the lower third of the lower limb. Though these ulcers are often associated with varicose veins in the upper part of the limb yet the term 'varicose ulcer' will not be justified. These ulcers are not caused by the presence of varicose veins but these are complications of deep vein thrombosis. Eczema and

pigmentation are often seen around these ulcers. The ulcer is slightly painful in the beginning but gradually the pain settles down and the main symptoms become discomfort, unsightliness and discharge. For detail description the students are referred to author's 'A CONCISE TEXTBOOK OF SURGERY' Page 268 and author's 'A TEXTBOOK ON SURGICAL SHORT CASES' Page-154.

Trophic ulcer (Neurogenic).— These ulcers have punched-out edge with slough in the floor thus resembling a gummatous ulcer. Bed-sore and perforating ulcers are typical examples of trophic ulcers. These ulcers develop as the result of repeated trauma to the insensitive part of the body. So some neurological disturbances in the form of loss of sensation is the cause behind this ulcer formation. These ulcers are commonly seen on the heel and the bail of the foot when the patient is ambulatory and on the buttock and on the back of heel when the patient is non-ambulatory. These ulcers start with callosity under which suppuration takes place, the pus comes out and the central hole forms the ulcer which gradually burrows through the muscles and the tendons to the bone. The resulting is a callous ulcer with punched out corny edge. Floor is covered with offensive slough and tendons and even bone can be seen here. The base is slightly indurated. The surrounding skin has no sensation. The cause may be spinal or leprosy or peripheral nerve injury, diabetic neuropathy, tabes dorsalis, transverse myelitis or meningomyelocele.

Tropical ulcer.— This ulcer may result from various diseases as it has been mentioned in the earlier section. The most important feature of this ulcer is its callousness towards healing. Its edge is slightly raised and exudes copious serosanguineous discharge. This ulcer practically retains the same size for months and years. In some cases, it destroys the surrounding tissue and thus spreads widely. Every effort should be made to detect the cause behind the ulcer and to treat accordingly. Otherwise, it may retain its existence or even spreads rapidly so as to require amputation.

Diabetic ulcer.— Three factors play to produce diabetic ulcer. (i) Diabetic neuropathy. (ii) Diabetic atherosclerosis causing ischaemia and (iii) Glucose laden tissue is quite vulnerable to infection and thus ulcer is formed.

When the ulcer is due to neuropathy a trophic ulcer results. The features are same as trophic ulcer with less sensation to the surrounding skin. When the ulcer is due to ischaemia, an ischaemic (arterial) ulcer results, but it is less painful than typical arterial ulcer. Infective ulcer is a type of spreading ulcer. Blood sugar estimation and urine examination should be performed to prove this diagnosis.

Tuberculous ulcer.— This mostly results from bursting of caseous lymph nodes. This type of ulcer may also develop when cold abscess from bone and joint tuberculosis breaks out on the surface. The ulcer is slightly painful. Such ulcer is usually seen in the neck, axilla and groin according to frequency. The most characteristic feature of this ulcer is its edge which is thin, reddish blue and undermined. There is pale granulation tissue with scanty serosanguineous discharge in the floor and slight induration at the base, which indicates that this ulcer is a chronic one. The regional lymph nodes are enlarged, non-tender and matted. Blood examination, Mantoux test, microscopic and guineapig inoculation test of the discharge, chest X ray are the investigations to be performed to diagnose such ulcer.

Lupus Vulgaris (Fig. 4.6).— It is a form of cutaneous tuberculosis, occurs commonly in the face and hand and the usual victims are the children and young adults. It starts very superficially as single or multiple cutaneous nodules which gradually turn into multiple superficial ulcerations of the skin. These ulcers remain active at the periphery and spread outwards whereas in the centre they gradually heal. Due to its destructive nature at the periphery it is called 'lupus' which means 'wolf'. Squamous cell carcinoma may grow from the scar of lupus vulgaris to form Marjolin's ulcer.

Syphilitic ulcers.— (i) *Hard Chancre* appears on the external genitalia 3 to 4 weeks after infection in the first stage of the disease. It is painless and possesses a characteristic indurated base, which feels like a button. In the penis chancre is found commonly in the coronal sulcus and frenum. Lymph nodes are enlarged, mobile, firm, discrete, painless and show no tendency towards suppuration. Extra-genital chancres which are seen in the nipple, lip, tongue and anal canal are not often indurated and may be slightly painful. Treponema pallidum can be demonstrated in serous discharge of the ulcer.

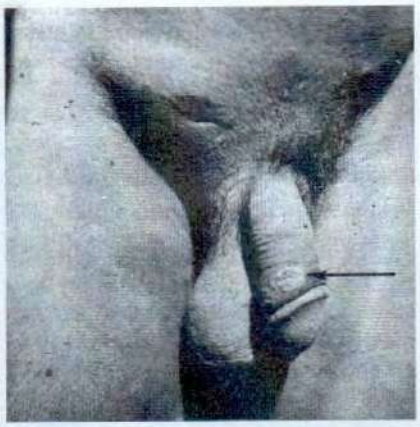

Fig.4.16.— Hunterian chancre on the penis with involvement of inguinal lymph nodes.

(ii) *Mucous patches* and *condylomas* are the characteristic lesions of the secondary stage of syphilis.

Mucous patches are white patches of sodden thickened epithelium. These are small, round, superficial, transient erosions particularly in the mouth which coalesce to form snail-track ulcer.

Condylomas are raised, flat, white and hypertrophied epithelium. Both these lesions usually occur at the mucocutaneous junctions e.g. angles of the mouth, anus, vulva etc. These are called *Condyloma Lata* and should be clearly differentiated from *Condyloma acuminata* which are warts or papillomata often caused by a virus (HPV). In this stage of the syphilis there is generalized painless enlargement of the lymph nodes, particularly the epitrochlear and suboccipital groups which are diagnostic to some extent. There is also generalized coppery red rash, motheaten alopecia, iritis and arthritis in this stage.

(iii) *Gummatous ulcers* occur in tertiary (late stage) syphilis. These ulcers are result of obliterative endarteritis, necrosis and fibrosis and are mostly seen over the subcutaneous bones (e.g. tibia, sternum, ulna and skull), in the scrotum in relation to the testis, upper part of the leg etc. The most characteristic feature is punched-out indolent edge and yellowish grey gummatous tissue (wash-leather slough) in the floor. Pain and tenderness are totally absent. Lymph nodes are seldom involved unless secondarily infected as the lymphatics are early closed by perivascular inflammatory reaction. W.R. and Kahn tests are positive.



Fig.4.17.— Gummatous ulcer in the sternomastoid showing punched out edge and wash-leather slough in the floor.

Soft Chancre or sore (Ducrey's).— These are multiple painful acute ulcers with oedematous edge and yellowish slough on the floor. These are seen on external genitalia. These ulcers generally appear 3 days after infection and discharge copious purulent secretion. The regional lymph nodes show the picture of acute lymphadenitis with tendency towards suppuration. This leads to soft swelling in the inguinal region known as bubo.

Meleney's ulcer.— These ulcers are seen in the postoperative wounds either after the operation for perforated viscus or for drainage of empyema thoracis. It is also found, though rare, on the dorsum of the hand. This type of ulcer is due to symbiotic action of microaerophilic non-haemolytic streptococci and haemolytic staphylococcus aureus. Nowadays other synergistic pairs have been isolated from



Fig.4.18.— 'Kangri Cancer' on the back of thigh. While being seated Kangri (portable charcoal brazier) is placed on the ground between the thighs. 45% of Kangri cancers are seen on the thighs. Other places where Kangri cancers can be seen are the abdominal wall (Fig.1.1), the legs, the groins etc. Majority lesions are ulcers, though one may find nodular growths or fungating growths.

such ulcer. This ulcer is most commonly seen in the abdomen as postoperative gangrenous wound following perforated viscus or in the thorax following drainage of empyema thoracis. Rarely it is seen on the leg (more often associated with ulcerative colitis) or on the dorsum of the hand. It is a spreading ulcer which is very painful with signs of toxaemia. It is an undermined ulcer as it destroys the tissues at the depth. The floor contains abundant foul smelling granulation tissue with copious seropurulent discharge. If not treated, the patient's general condition deteriorates and he will die ultimately. Clinically, it is an undermined ulcer with lot of granulation tissue in the floor. It is surrounded by deep purple zone, which in its turn is surrounded by an outer zone of erythema. This particular condition is painful, toxaemic and the general condition deteriorates without treatment.

Epithelioma (squamous cell or epidermoid carcinoma).— It arises from prickle cell layer of the skin and hence may occur anywhere in the body. But it is more commonly seen on the lips, cheek, hands, penis, vulva and old scars. It may also occur in the internal organs e.g. tongue, buccal cavity, pharynx, larynx and oesophagus. In certain columnar cell area it may occur following metaplasia to squamous cells e.g. cardiac end of stomach, gallbladder etc. Similarly in certain transitional cell areas it may occur following metaplasia to squamous cells e.g. pelvis of kidney, urinary bladder etc. Histologically this tumour presents 'structureless mass of keratin' surrounded by prickle cells in concentric manner as seen in 'onion skin'. This whole appearance is called 'cell-nest' or 'epithelial pearl'. This 'cell-nest' however is absent in rapidly growing tumour and in the mucous membrane e.g. oesophagus, urinary bladder etc.

It is mostly seen after 40 years of age. It begins as a small nodule which enlarges and gradually the centre becomes necrotic and sloughs out and thus ulcer develops. Such an ulcer is oval or circular in shape, but size varies considerably. The edge of the ulcer is raised and everted. Floor is covered by necrotic tumour, serum and blood. There may be some granulation tissue, but is pale and unhealthy. Base of the ulcer is indurated, which is the pathognomonic sign of epithelioma. In early cases epithelioma can be moved with the skin over the underlying structures. But later on it becomes fixed due to involvement of the deeper structures. Regional lymph nodes are almost always enlarged be it due to metastasis or secondary infection. When metastasised the nodes become hard, gradually matted and fixed. 'Kangri cancer' is also an example of epithelioma.

Marjolin's ulcer.— This is a squamous cell carcinoma arising from a long-standing benign ulcer or scar. The commonest ulcer to become malignant is a long-standing venous ulcer. The scar which may show malignant change is the scar of an old burn. It is a slowgrowing and less malignant squamous carcinoma. It is slight different from typical squamous carcinoma in the sense that its edge is not always raised and everted. Unusual nodules may develop as carcinoma.

Lymphatic metastasis is unusual as the lymphatics are already destroyed or occluded by previous chronic lesion of the skin. It is absolutely painless. Unlike squamous carcinoma it is radioresistant as it is relatively avascular and there is extensive fibrosis.

ULCERS OF THE LEG

Ulcers of the lower part of the leg, the ankle and the foot are common problems faced by the surgeons all over the world. The followings are the common causes of ulcer peculiar to this place. Of course, the other types of ulcers discussed above can also occur in the leg.

Venous ulcer.— The basic cause of the venous ulcer is abnormal venous hypertension in the lower third of the leg. The terms "varicose ulcer", "post thrombotic ulcer" and "gravitational ulcer" are also used as synonyms of venous ulcer. When the calt pump and the main deep veins are normal, even the slightest movements empty the superficial veins lowering the superficial venous pressure. The main pathway of the venous drainage of the ankle skin in the erect posture is via the ankle perforating veins. When the valves of this vein are damaged there will be local venous hypertension. This condition is aggravated by obstructed main deep veins. Post-canalisation of the thrombosed deep veins leads to destruction of the valves of the deep veins and this becomes the main contributing cause for ankle venous hypertension. The most important complication of this venous ulcer is the development of the carcinoma (Marjolin's ulcer) from the growing edge of the ulcer.

Majority of venous ulcers follow many years of venous disease, so the patients are usually of the age group of 40 to 60 years. Women are affected far more often than men. Discomfort and tenderness of the skin, pigmentation and eczema exist for months or years before a venous ulcer develops. The ulcer is painful in the beginning but once it settles down and becomes chronic it becomes painless.

Venous ulcers are mainly found in lower part of the leg on its medial side. These are never seen above the junction of the middle and upper thirds of the leg. Venous ulcer can be of any shape and size. The edge is sloping and pale purple-blue in colour. The margin is thin and blue of growing epithelium. The floor is formed by pale granulation tissue. This ulcer is usually shallow and flat and never penetrates the deep fascia. The discharge is seropurulent with occasional trace of blood. The base of the ulcer is fixed to the deeper structures. The surrounding skin shows signs of chronic venous hypertension — pigmentation, induration and tenderness. There may be scars of previous ulcers. Varicose veins may or may not be seen in the proximal limb. Regional lymph nodes (inguinal group) are only enlarged if the ulcer becomes infected.

It must be remembered that squamous carcinoma can arise from the margin of a long-standing venous ulcer. When the edge of a long-standing venous ulcer is raised and everted or somewhat different from what described above should arouse suspicion of malignancy. The base of the ulcer becomes hard. This malignant ulcer is called *Marjolin's ulcer*. Biopsy should always be taken to confirm malignancy.

Arterial Ulcer.— These are rare compared to venous ulcer. Ulcers are due to peripheral arterial disease and poor peripheral circulation. These are often seen in older people and are episodes of trauma and infection of the destroyed skin over a limited area of the leg or the foot. The ulcers tend to be punched out and destroy the deep fascia (unlike the venous ulcer) and may expose the tendons at the base. When these ulcers occur at the inner side of the ankle the diagnosis is frequently overlooked, but a history of intermittent claudication with discolouration of one or more toes becomes the differentiating feature.

Ulcer from congenital arteriovenous fistula may be the rare cause of ulcer in the lower part

of the leg. The peculiar feature of this ulcer is that it occurs at a comparatively early age and presence of venous encroachment around the ulcer.

Erythrocyanoid ulcer (Bazin's disease).— These ulcers are associated with "erythrocyanosis frigida", which is an exclusive disease of young women. Abnormal amount of subcutaneous fat with thick ankles combined with an abnormally poor arterial supply are the predisposing factors. The blood supply of the lower third of the leg and the ankle are derived from a number of perforating arteries arising from the posterior tibial and peroneal arteries. In erythrocyanoid cases these arteries may be abnormally small and even absent causing low-grade ischaemia of the whole ankle region. The patient finds that the ankle skin is abnormally sensitive to temperature changes. When the weather is cold, the ankle is blue, cold and often tender. In hot weather chronic reactive hyperaemia becomes evident with the ankle becomes hot, oedematous, swollen and painful. The patient is much troubled by chilblain. Palpation of the leg will reveal small, superficial and painful nodules which break down to form ulcers. These ulcers are small and multiple.

Gummatous ulcer.— See page 71.

Martorell's ulcer (hypertensive ulcer).— This is a condition of old age and associated with atherosclerosis. A local patch of skin on the back or outer side of the calf suddenly necroses and sloughs away leaving a punched-out ulcer extending down to the deep fascia. This condition is peculiar by the characteristic severe pain which the patient experiences and the most prominent symptom. This condition may be bilateral and the underlying pathology is the sudden obliteration of the end arterioles of the skin of this region which is already having a sparse arterial supply from atherosclerosis. It is noteworthy that all peripheral foot pulses are usually present. It may take months to heal.

Infective ulcers.— Ulceration from tuberculosis and syphilis are becoming rare and have been discussed in details in the earlier section. The ulcers which are now coming in the limelight are the staphylococcus aureus ulcer, which may occur at any age and takes the form of multiple, small, red, scabbed sores on the leg or the ankle. This type is almost always due to constant reinfection as a result of unclean habits, poor hygenic and inadequate dressings. Anaemia and poor nutritional status are the predisposing factors. "Footballer's ulcer" directly over the sheen is due to staphylococcal infection and repeated trauma. If not properly treated, the ulcers become chronic and adherent to the bone.

Meleney's ulcer.— Originally this ulcer is described in relation to infected abdominal and thoracic operative wounds. But this may occur in the leg either de novo (in ulcerative colitis) or more commonly as a complication of a previously existing ulcer. It is due to symbiotic action of the micro-aerophilic non haemolytic streptococci and staphylococcus aureus. The most important clinical characteristic feature is burrowing, that means undermining of the ulcer with lot of granulation tissue on the floor. It is surrounded by deep purple zone which in its turn is surrounded by outer zone of erythema. These ulcers are very painful, tender, show a tendency to spread, make the patients toxaemic and the general condition of the patient deteriorates without treatment.

Ulcers complicating various diseases.— These ulcers may develop de novo or in venous ulcers which suddenly get worse and become more painful. Gross anaemia, polycythemia, leukaemia, rheumatoid arthritis, Paget's disease, ulcerative colitis etc. are the conditions mainly responsible. In rheumatoid arthritis the ulcer occurs from break down of a nodule, varies in size, becomes punched-out, shallow (remain within the subcutaneous tissue), becomes painful, without induration and slow to heal.

Ulcers secondary to osteitis deformans (Paget's disease) are mostly situated over the convexity of anteriorly bowed tibia, with the edges densely adherent to the bone which forms its base.

Tropical ulcer.— This ulcer seems to be due to infection by Vincent's organisms (Bacteroides Fusiformis) from a small abrasion and breach of continuity of the skin due to trauma or insect bite. The lesion commences as a papule-pustule with a zone of surrounding inflammation and induration. Pain is an important symptom at this stage with acute lymphadenitis. These pustules burst in two or three days forming ulcers whose edges are undermined and raised. Copious serosanguineous discharge with considerable pain is important feature. The ulcer becomes indolent and refuses to heal for months and even years. In others, it heals after a long-period leaving a parchment like pigmented scar. Occasionally squamous carcinoma may supervene.

Yaws.— The causative organism is Treponema Pertenue. The ulcers can be found on the leg or foot as abrasions of the bare-foot are the routes of entry. These are painless. It heals in a few weeks forming tissue paper like scar.

Chapter

5 EXAMINATION OF A SINUS OR A FISTULA

Sinus.— A sinus is a blind track leading from the surface down to the tissues. There may be a cavity in the tissue which is connected to the surface through a sinus. The sinus is lined by granulation tissue which may be epithelialized.

Fistula.— It is a communicating track between two epithelial surfaces, commonly between a hollow viscus and the skin (external fistula) or between two hollow viscera (internal fistula). The track is lined with granulation tissue which is subsequently epithelialized.

Causes of persistence of a sinus are : (1) presence of foreign body or necrotic tissue (e.g. sequestrum or a suture material) in the depth; (2) absence of rest; (3) non-dependent drainage or inadequate drainage of an abscess; (4) when a specific chronic infection (e.g. tuberculosis, actinomycosis etc.) is the cause; (5) when the track becomes epithelialized; (6) sometimes there may be a dense fibrosis around the wall of the track and the cavity preventing their collapse, as occurs in chronic empyema.



Fig.5.1.— Osteomyelitic sinus showing sprouting granulation tissue at the mouth of the sinus.

Causes of persistence of a fistula are : once a true fistula has been formed, it seldom shows any intention towards healing. Moreover irritant discharge such as urine, faeces, bile etc. are passed through the fistula and prevents its healing. But one thing should always be remembered that if the natural passage is made patent, all abnormal offshoots heal spontaneously.

HISTORY

Certain sinuses and fistulae are present since birth e.g. *preauricular sinus.* When *a sinus is due to osteomyelitis,* the patient will give a history of high fever followed by swelling and pain in the bone concerned. An abscess will develop, subsequently this will gradually move towards the surface and will burst resulting a discharging sinus. Sometimes a history of discharge of bone chips may be elicited. The sinus will persist so long as there will be necrotic bone (sequestrum) at the depth of the wound. In case of *tuberculous sinus,* a previous history of lymph nodes enlargement or tuberculous affection of the bone or joint may be elicited. Subsequently a cold abscess will develop which will burst (or be incised) leading to a sinus. In case of a sinus or fistula in the perianal region a previous history of perianal or ischiorectal abscess may be given by the patient. Intermittent contraction of the anal sphincter will prevent proper rest to the part and thus interfere with healing of the sinus or the fistula.

PAIN.— If pain is associated with, inflammatory nature of the sinus or blockage of the opening of the sinus or fistula is assured.

FEVER and REDNESS OF THE SURROUNDING SKIN also suggest inflammatory origin of the sinus or fistula.



Fig.5.2.— Shows a tuberculous sinus following tuberculous lymphadenitis in the inguinal region.

PAST HISTORY.— This is important as a few diseases are prone to develop sinus or fistula later in life e.g. Tuberculosis, Crohn's disease, ulcerative colitis and actinomycosis. Colloid carcinoma of rectum may produce anal fistula in later stage. Sinus or fistula may develop as a complication of operation performed earlier.

FAMILY HISTORY.— A few diseases often involve more than one member of the same family which may predispose sinus or fistula formation e.g. tuberculosis, Crohn's disease, ulcerative colitis etc. Even fistula-in-ano is often seen in more than one member in a family.

LOCAL EXAMINATION

A. **INSPECTION.**— The following points are carefully noted :

(1) **Number.**— Though majority of the fistulae which occur in the body are single, yet a few are notoriously known for their multiplicity. These are 'Watering Can' perineum, Crohn's disease affecting the rectum and anal canal which produces multiple anal fistulae, actinomycosis always produces multiple sinuses and sometimes ulcerative colitis may produce multiple fistulae.



Fig.5.3.— 'Watering-Can' perineum. Each opening is shown with a probe.

(2) **Position.**— Diagnosis of many sinuses and fistulae can be made only looking at the position of these sinuses and fistulae. *Preauricular sinus* (due to failure of fusion of the ear tubercles) is situated at the root of the helix or on the tragus of the pinna, the direction of sinus being upwards and backwards. The *branchial fistula* (due to failure of fusion of the second branchial arch with the fifth) is almost always situated at the lower third of the neck just in front of the sternomastoid muscle. The *pilonidal sinus* is mostly seen in the middle behind the anus. Multiple indurated sinuses in the upper part of the neck suggest the diagnosis *of actinomycosis. Tuberculous sinus* often takes a peculiar position which by itself mentions the diagnosis. A single sinus over the lower irregular jaw is mostly due to *osteomyelitis.*



Fig.5.4.— Branchial fistula typically situated just in front of lower third of the sternomastoid.

(3) **Opening of the sinus.**— Sprouting granulation tissue at the opening of the sinus suggests presence of foreign body at the depth, e.g. sequestrum, a drainage tube, bullet etc. The opening of a tuberculous sinus is

often wide and the margin is thin blue and undermined.

(4) **Discharge.**— It is always advisable to look for the character of the discharge. In osteomyelitis it is often pus. In tuberculous ulcer it is often serosanguineous and most important is often presence of sulphur granules in the discharge of actinomycotic sinuses. In case of fistulae, urine, faeces, bile etc. may be seen coming out.

(5) **Surrounding Skin.**— There may be a scar in the surrounding tissue which may indicate chronic osteomyelitis or previously healed tuberculous sinus etc. There may be surrounding dermatitis and pigmentation which are characteristic features of Crohn's disease and actinomycosis.

B. **PALPATION.**— While palpating a sinus or a fistula the following points should be noted :

1. **Tenderness.**— Is the sinus tender? The sinus from inflammatory source will be tender (e.g. osteomyelitis).

2. **Wall of the sinus** — is palpated to note any *thickening* there. Chronic sinuses will have thick wall due to presence of fibrosis surrounding the wall of the sinus.

3. Mobility.— Is the sinus mobile over the deep structures? Sinuses resulting from osteomyelitis are fixed to the bone, which becomes irregular, thickened and tender.

4. **Lump.**— Presence of lump in the neighbourhood of a sinus often indicates tuberculous lymphadenitis.

C. **EXAMINATION WITH A PROBE.**— This is important but should be performed with due precaution. This examination will inform the clinician about (i) the direction and the depth of the sinus, (ii) presence of any foreign body such as sequestrum, which will be moveable, at the depth of the wound, (iii) whether the fistula is communicated with a hollow viscus or not and (iv) whether fresh discharge comes out on withdrawal of the probe or not.

D. **EXAMINATION OF DRAINING LYMPH NODES.**— This examination is always essential and should not be missed under any circumstances.

GENERAL EXAMINATION

Depending on the site and cause of the sinus, examination of the particular system should be performed. In case of a sinus in the loin, the spine, ribs and the kidneys should be examined to know the exact cause of the lesion. In case of a sinus due to chronic empyema, the chest should be thoroughly examined. In case of a sinus due to osteomyelitis, the bone should be examined as described under 'Examination of diseases of bone'. In case of fistula around the anus a thorough examination not only of the anal canal and rectum both manually and proctoscopically should be called for but also sigmoidoscopic examination and examination of the whole abdomen should be performed. In case of multiple fistulae in the perineum and scrotum, the lower urinary track should be thoroughly examined. In case of a groin sinus the hip joint and the spine should be examined as it may be due to bursting of cold abscess originating from there.



Fig.5.5.— Shows osteomyelitic ulcer from osteomyelitis of the right clavicle of a young boy.

SPECIAL INVESTIGATIONS

1. **Examination of the discharge** — is of utmost importance to come to a diagnosis. It should be examined macroscopically, physically, chemically, microscopically (e.g. for sulphur granules in case of actinomycosis) and bacteriologically.

2. **X-ray Examination.**— (a) Straight X-ray may show a sequestrum and osteomyelitic change of the bone concerned or presence of opaque foreign body.

(b) Injection of radio-opaque fluid (lipiodol or hypaque) into a sinus (sinogram) or a fistula (fistulogram) will indicate the cause of the sinus or fistula by delineating its course.

3. **Examination using coloured solution.**— (a) Sterilized methylene blue may be pushed through a catheter into the urinary bladder and if the colour is detected in the vagina vesicovaginal fistula is confirmed.

(b) Charcoal powder may be used in the food to confirm presence of upper G.I. tract fistula by detecting charcoal particles in the discharge of the fistula after a few hours.

(c) Coloured drug e.g. pyridium may be used to confirm presence of urinary fistula, as the coloured drug is excreted through the urine.



Fig.5.6.— A sinus in the appendicectomy scar is being examined with a probe.

I. CLASSIFICATION OF SINUSES.—

1. **Congenital** e.g. preauricular sinus.

2. **Traumatic** e.g. following trauma a foreign body may be implanted into deep tissues and following infection a sinus may persist.

3. **Inflammatory** e.g. osteomyelitic sinus, tuberculous sinus, actinomycotic sinus or sinus of a chronic abscess which discharges pus due to inadequate treatment of acute abscess.

4. **Neoplastic** e.g. sinus due to degenerative change of a malignant growth or due to secondary infection of a malignant growth which was incised for drainage.

5. **Miscellaneous** e.g. pilonidal sinus.

II. CLASSIFICATION OF FISTULA.—

1. **Congenital** e.g. branchial fistula, thyroglossal fistula, rectovesical fistula, vesicovaginal fistula, tracheo-oesophageal fistula, umbilical fistula.

2. **Traumatic.**— Such fistula may occur after operation or after accidental injury to certain viscera e.g. salivary fistula, pancreatic fistula, biliary fistula, faecal fistula, urinary fistula etc.

3. **Inflammatory.**— Abscess related to a viscus if bursts to the exterior may develop a fistula e.g. appendicular fistula or external fistula following diverticulitis of colon.



Fig.5.7.— Shows how the track of fistula-in-ano can be delineated by injecting radio-opaque fluid.

4. **Malignant.**— Advanced carcinoma of one viscus may either infiltrate into the neighbouring viscus to form a fistula (internal fistula) or may infiltrate into the parietes to form external fistula e.g. carcinoma of the rectum may involve urinary bladder in males to produce rectovesical fistula. Carcinoma cervix may involve urinary bladder in females to produce uterovesical fistula. Extensive malignant lesion of abdominal viscus may involve umbilicus to produce umbilical fistula (faecal fistula).

Chapter

6 EXAMINATION OF PERIPHERAL VASCULAR DISEASE AND GANGRENE

HISTORY

1. **Age and Sex.**— Atherosclerosis is obviously a disease of old age. It affects men more often than women. Buerger's disease (Thromboangiitis obliterans) is commonly seen in men between 20 and 40 years of age. Raynaud's disease is a disease of young women. Diabetic arteriopathy is commoner in middle age.

2. **Limbs affected.**— Buerger's disease and atherosclerotic gangrene commonly affect the lower limbs, but Raynaud's disease mainly affects the upper limbs. A patient who presents with superficial gangrene of the finger, the following causes should specially be considered : Raynaud's disease, the cervical rib, scalenus anticus syndrome, Morvan's disease — painless whitlow in syringomyelia.

3. **Bilateral or unilateral.**— In Buerger's disease and Raynaud's disease the affection is usually bilateral. Atherosclerotic gangrene may be unilateral to start with but often ends as a bilateral disease. Gangrene due to embolism is mostly unilateral. Diabetic gangrene may be unilateral or bilateral.

4. **Mode of onset.**— Gangrenes due to atherosclerosis, Buerger's disease and Raynaud's disease occur spontaneously and gradually. Embolic gangrene starts suddenly and the patient feels severe pain radiating down the course of the artery. Diabetic gangrene may start from slight trauma such as caused by careless paring of the toe nail or mild infection.

5. **Pain.**— Note its *site, character, radiation, whether it increases in walking or exercise, whether it disappears when the exercise stops and whether it becomes worse on application of warmth.* When circulation of the limb is impaired, two types of pain are noticed : (1) intermittent claudication and (2) rest pain.

INTERMITTENT CLAUDICATION.— Though literary 'claudio' means 'I limp', yet the term claudication is used here to describe the muscle pain due to accumulation of the excessive P-substance owing to inadequate blood flow. It is a pain in the muscles, *usually the calf* and it is described by the patient as a *cramp.* Of course the site of the pain depends on the level of arterial occlusion e. g. in the foot in Buerger's disease in which the arterial occlusion is mostly in the lower tibial or plantar arteries; in the calf in case of arterial occlusion in femoro-popliteal junction which is very common; in the thigh when the occlusion is at the opening of the superficial femoral artery and in the buttock in case of occlusion in the bifurcation of the common iliac artery or the aorta. The pain develops *only when the muscles are working.* The pain *disappears when the exercise stops.*

The patient often complains that after walking a distance, called the *'claudication distance* , the pain starts. Sometimes if the patient continues to walk the metabolites increase the muscles blood flow and sweep away the P-substances produced by exercise and pain disappears (Grade I).

More often the pain continues and the patient can still walk with effort (Grade II). But mostly the pain compels the patient to take rest (Grade III, Boyd's classification).

REST PAIN.— This pain is *continuous and aching in nature.* This pain seems to be due to ischaemic changes in the somatic nerves. *It is the cry of the dying nerves.* The pain is worse at night, gets aggravated by elevation of the leg above the level of the heart and is relieved by hanging the leg below the level of the heart. It usually affects the most distal part first that means the tip of the toes. The painful part becomes very sensitive and any movement or pressure causes an acute exacerbation.

6. **Effects of heat and cold.**— Application of warmth will increase the symptoms of arterial occlusion. Raynaud's phenomenon i.e. intermittent attack of pallor or cyanosis is often seen in Raynaud's disease and sometimes in Buerger's disease.

In Raynaud's disease a number of attacks can be seen — each attack is comprised of 3 stages viz. (i) *Local syncope,* in which the affected digits become cold and white with tingling and numbness. These changes are due to spasm of the digital arteries. (ii) *Local asphyxia,* in which the white digits turn blue with burning sensation; This change is due to slowing of circulation and accumulation of reduced haemoglobin. (iii) *Local recovery,* in which the bluish discolouration gradually disappears and the digits regain normal colour due to release of spasm of digital arteries. Such attacks are repeated, till in the end patches of superficial ulceration and gangrene appear at the finger tips, which is known as *local gangrene.*

7. **Paraesthesia.**— When the muscle pain begins, the patient often feels numbness, pins and needles and other types of paraesthesia in the skin of the foot. This is due to shunting of blood from the skin to muscle.

8. **History of superficial phlebitis.**— This is characterized by swelling, redness and minor pain in the affected part. It occurs in high proportion of cases of Buerger's disease.

9. **Involvement of other arteries.**— Enquiry must be made if there is complain *of fainting, transient black out, chest pain, weakness* or *paraesthesia* in the upper limbs, *blurred vision, abdominal pain* to exclude occlusive arterial disease anywhere in the body.



Fig.6.1.— Shows typical gangrene of the great and the middle toes of the left leg.

10. **Impotence** — due to failure in erection is not uncommon symptom in case of bilateral internal iliac artery occlusion.

11. **Past History.**— The patient with arterial occlusion may give a history of previous cardiac attacks or embolic syndromes. The patient may be diabetic. There may be a history of exposure to cold (Frost Bite) etc.

12. **Personal History.**— Excessive smoking has been incriminated as causing thromboangiitis obliterans and worsening atherosclerotic disease.

13. **Family History.**— It is amazing to know that arterial disease particularly atherosclerosis is often familial and if you practice the habit of asking if other members of the family are affected with the same disease or not, you will find quite a few are or were suffering from this disease.

PHYSICAL EXAMINATION

Considerable constitutional disturbances may be observed in severe acute ischaemia from embolus and in gas gangrene. There may be lowering of the blood pressure and increase in the

pulse rate in both these conditions. In chronic ischaemia there is not much constitutional disturbances.

LOCAL EXAMINATION

A. **INSPECTION.**— 1. **Change in colour** is the most noticeable feature of an ischaemic limb. To detect minor change in the colour the clinician should put the affected limb and its fellow side by side. Marked pallor is a remarkable feature of sudden arterial obstruction as seen in case of embolism or in spasm of the arterioles in Raynaud's disease. Congestion and purple-blue cyanosed appearance are the characteristic features of severe ischaemia and pregangrenous stage. As soon as the limb is elevated it becomes pallor.



Fig.6.2.— Ainhum affecting the fourth toe. Note that the line of demarcation is grooved in.

2. **Signs of Ischaemia.**— While examining a case of arterial insufficiency, one must know the signs of ischaemia. These are : thinning of the skin, diminished growth of hair, loss of subcutaneous fat, shininess, trophic changes in the nails which become brittle and show transverse ridges and *minor ulceration* in the pressure areas such as heel, malleoli, ball of the foot, tips of the toes etc.

3. **Buerger's postural test.**— This test must be carried out in broad day light. The patient lies on his back on the examining table. The patient is asked to raise his legs one after the other keeping the knees straight. The legs of a normal individual remain pink even if they are raised to 90°. But in case of an ischaemic limb elevation to a certain degree will cause marked pallor and the veins will be empty and 'guttered'. The angle (between the limb and the horizontal plane) at which such pallor appears is called 'Buerger's angle' or the 'Vascular angle'. A vascular angle of less than 30° indicates severe ischaemia. If the feet do not become pallor and occlusive arterial disease is suspected the following addition may be performed. The elevated legs are supported by the examiner, while the patient flexes and extends his ankles and toes to the point of fatigue. If there is occlusive arterial disease the sole of the foot assumes cadaveric pallor and the veins on the dorsum of the foot become empty and guttered. The feet are now lowered so that the patient adopts sitting posture. Within 2 or 3 minutes a cyanotic hue spreads over the affected foot, whereas no change will be observed in case of healthy limb. This is due to cyanotic congestion.

4. **Capillary filling time.**— After elevating the legs, the patient is asked to sit up and hang his legs down by the side of the table. A normal leg will remain pink as it was during elevated position. But an ischaemic leg will first become pallor when elevated and gradually become pink

in horizontal position. This change of colour takes place slowly and is called 'the capillary filling time'. In severe ischaemia it takes about 20 to 30 seconds to become pink. Then the ischaemic limb again changes colour and becomes purple-red quickly. This is due to the filling of the dilated skin capillaries with deoxygenated blood.

5. **Venous refilling.**— After keeping the limb elevated for a while if it is then laid flat on the bed, there will be normal refilling of the veins within 5 seconds. But in ischaemic limb it will be delayed. If a normal limb is raised to about 90° there will be gradual collapse or 'guttering of the veins'. But in ischaemic limb the veins are seen collapsed either in the horizontal position or as soon as it is lifted to even 10° above the horizontal level.

In established gangrene the following points are noted : (1) **Extent** and **Colour** of the gangrenous area. This is important to ascertain the level of arterial occlusion. In gas gangrene, besides the typical odour of sulphurated hydrogen, the muscles also change their colour to brick-red, green or even black according to the stage of the disease.



Fig.6.3.— Shows a typical case of ainhum where the 5th toe is affected and is almost shredding off.

(2) **Type** — of the gangrene should be noted — whether *dry* i.e. the part becomes mummified or *wet* and putrefying as seen in diabetic gangrene.

(3) **Line of demarcation** — is often seen between the dead gangrenous part and the normal living limb. In gangrene due to all the conditions this line of demarcation is poorly marked except in ainhum. In this condition there is a linear deeping groove at the base of the little or the fourth toe, which is the pathognomonic feature (Figs.6.2 & 6.3).

(4) It is always advisable to observe the **limb above** the gangrenous area. This may be congested, oedematous or pale, which indicates the possibility of later involvement of this area. There may be black patches, which indicate 'skip lesions'.

B. **PALPATION.**— 1. **Skin temperature.**— The temperature is best felt with the back of the fingers. It is always essential to compare the two limbs and to feel the whole of the affected limb to find out the zone where the temperature changes from the normal warm temperature to cold skin of the ischaemic site. It is wiser to feel for the temperature rather than to assess the temperature by looking at the colour of the limb. The purplish red and congested limb may be very cold.

2. **Capillary refilling.**— The tip of the nail or the pulp of a toe or a finger is pressed for a few seconds and the pressure is released. The time taken for the blanched area to turn pink after the pressure has been released is a crude indication of capillary blood flow. This time will be definitely longer in case of ischaemic limb.

3. **Venous refilling.**— The two index fingers are placed side by side on a vein. The fingers are now pressed firmly and the finger nearer the heart is moved proximally keeping the steady pressure on the vein so as to empty the short length of the vein between the two fingers. The distal finger is now released. This will allow venous refilling to be observed. This is poor in ischaemic limb and is increased in arteriovenous fistula. This is known as *Harvey's sign.*

4. **Crossed leg test** (Fuchsig's test).— This is performed to detect popliteal pulsation. The patient is asked to sit with the legs crossed one above the other so that the popliteal fossa of one leg will lie against the knee of the other leg. The patient's attention is diverted by taking history. The crossed leg will show oscillatory movements of the foot which occur synchronously with the pulse of the popliteal artery. If the popliteal artery is blocked, this oscillatory movement will be absent.

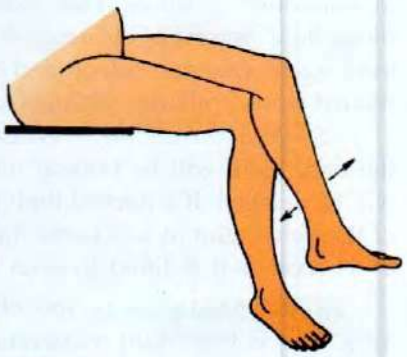

Fig.6.4.— Movements of the foot of the crossed leg are noticed only when the corresponding popliteal artery of the crossed leg is patent.

5. **Cold and warm water test.**— To provoke the arteriospasm in case of Raynaud's disease the patient is asked to put her hand into ice-cold water. This will initiate the attack and the hand becomes white. The patient is then asked to dip her hand in warm water. The hand will become blue due to cyanotic congestion.

6. **Elevated arms test.**— This test is performed when thoracic outlet syndrome is suspected. The patient is asked to abduct his shoulders to 90 degrees and at the same time the upper limbs are externally rotated fully. Now the patient is instructed to open and close the hands for a period of 5 minutes. A normal individual can perform this without any difficulty. Whereas the patient with thoracic outlet syndrome will complain of fatigue and pain in forearm muscles, paraesthesia of the forearm and tingling and numbness sensation in the fingers. Majority of these patients fail to complete this test due to pain and distress and they drop their arms. If this test is performed in case of cervical disc syndrome patient will feel pain in the neck and shoulders, though little distress is felt in the forearm and hand.

7. **Allen's test** to know the patency of radial and ulnar arteries.— The patient is asked to clench his fist tightly. The surgeon presses on the radial and ulnar arteries at the wrist. After 1 minute the patient is asked to open the fist. The palm appears white. Now pressure on the radial artery is removed and the change in colour of the hand is noted. If the radial artery is blocked the colour remains white, but if it is patent the palm assumes normal colour. Now the pressure on the ulnar artery is removed. Now the test is repeated and the pressure on the ulnar artery is first removed keeping pressure on the radial artery. If the ulnar artery is blocked the hand remains white, but if it is patent the palm assumes normal colour.

8. **Branham's Sign** or Nicoladonis sign.— This is performed when arteriovenous fistula is suspected. A pressure on the artery proximal to the fistula will cause reduction in size of swelling, disappearance of bruit, fall in pulse rate and the pulse pressure returns to normal.

9. **Costoclavicular compressive manoeuvre** or test.— Patient's radial pulse is felt. The patient throws shoulders backwards and downwards as an exaggerated military position. This will compress the subclavian artery between the clavicle and the first rib leading to reduction or disappearance of the radial pulse. Simultaneously a subclavian bruit may be heard.

10. **Hyperabduction manoeuvre.**— Patient's radial pulse is again monitored. The affected arm is now passively hyperabducted. This will cause reduction or disappearance of the radial pulse due to compression by the pectoralis minor tendon in pectoralis minor syndrome. An axillary bruit may be heard near the position where pectoralis minor tendon crosses the axillary artery.

11. **Gangrenous area.**— By feeling the gangrenous area one can assess the type of gangrene. In case of dry gangrene the part will be hard and shrivelled, whereas in case of wet gangrene the part will be oedematous with or without crepitation.





Figs.6.5 & 6.6.— Bilateral gangrene of the toes encroaching feet in a case of diabetic.

12. **Crepitus.**— Presence of crepitus is the characteristic feature of gas gangrene. This is due to presence of gas within the muscles.

13. **Limb above the gangrenous area.**— It is always a good practice to palpate the limb above the gangrenous area as a routine. Tenderness along the line of the blood vessel indicates recent thrombosis. Pitting on pressure suggests oedema which may be due to inflammatory condition and thrombophlebitis.

14. **Palpation of the blood vessels.**— This is probably the most important part of the examination so far as an ischaemic limb is concerned. Disappearance of arterial pulsation below the level of occlusion is the rule. The only exception is the presence of good collateral circulation when the pulse may be diminished but does not disappear.

An apparently normal peripheral pulse may disappear after exercising the patient to the point of claudication. This 'disappearing pulse' is a sign of unmasking the preliminary stage of arterial occlusion. The disappearing pulse reappears after a minute or two following cessation of exercise.





Figs.6.7 & 6.8.— Showing the correct and incorrect methods of feeling the dorsalis pedis pulse. The white line in the second figure represents the artery and the palpating finger should be placed anywhere over this line as shown in the first figure. The artery disappears through the proximal end of the first metatarsal space into the sole. Therefore searching for the pulse beyond this spot as shown in the second figure is a wrong procedure.



Fig.6.9.— Palpation of anterior tibial artery. Note that the extensor hallucis longus is made taut by extending the great toe and the artery is palpated just lateral to the tendon.

An expansile arterial pulsation indicates presence of aneurysm.

So much important is the feel of an artery. When there is embolus in an artery, the artery becomes firm and tender. Soft, non-tender, non-pulsatile artery means that the embolus has lodged higher up. In embolism, the pulse can usually be traced down to the point where it meets the obstruction. Here there is often a small tender swelling and the pulse is lost below.



Fig.6.10.— Feeling for the posterior tibial pulse.

The following arteries are often required to be examined:

The dorsalis pedis artery — is felt just lateral to the tendon of the extensor hallucis longus. It is absent in 10% of cases.

The posterior tibial artery — is felt just behind the medial malleolus midway between it and the tendo Achillis.

The anterior tibial artery — is felt in the midway anteriorly between the two malleoli against the lower end of tibia just above the ankle joint and just lateral to the tendon of the extensor hallucis longus which is made prominent by asking the patient to extend his great toe (Fig. 6.9).

The popliteal artery — is rather difficult to feel as it lies deep behind the knee. The knee is flexed to 40° with the heel resting on the bed, so that the muscles around the popliteal fossa are relaxed. The clinician places his fingers over the lower part of popliteal fossa and the fingers are moved sideways to feel the pulsation of the popliteal artery against the posterior aspect of the tibial condyles. It is rather impossible to palpate this artery in the upper part of the popliteal fossa as the artery lies between the two projecting femoral condyles.

This artery can also be palpated by turning the patient into prone position and by feeling the artery with the finger tips after flexing the knee passively with another hand (Fig.6.12).



Fig.6.11.— Method of palpating the posterior tibial artery in a gangrenous foot.



Fig.6.12.— Feeling for the popliteal pulse.

The femoral artery — is felt at the groin just below the inguinal ligament midway between the anterior superior iliac spine and the symphysis pubis.

The radial and ulnar arteries — are felt at the wrist on the lateral and on the medial sides of its volar aspect respectively.

The brachial artery — is felt in front of the elbow just medial to the tendon of biceps.

The subclavian artery — is felt just above the middle of the clavicle.

Common carotid artery — is felt in the carotid triangle just in front of the sterno-mastoid muscle against the carotid tubercle of the sixth cervical vertebra.

The superficial temporal artery — is felt just in front of the tragus of the ear.

When the pulse is feeble or absent, the pulsation of the examiner's own finger may be mistaken for that of the patient. In that case the clinician may palpate his own superficial temporal artery and compare the doubtful pulse of the patient. Otherwise he can also compare the patient's radial artery with the doubtful pulse of the patient's lower extremity (Fig. 6.14).



Fig.6.13.— Feeling for the femoral pulse.



Fig.6.14.— When the dorsalis pedis pulse is very feeble or absent, the examiner's own arterial beat may be mistaken for that of the patient. Under such circumstances simultaneous palpation of patient's radial pulse eliminates the error.

While examining the artery the following points are noted : (a) Pulse — its volume and tension. (b) Condition of the arterial wall — whether atheromatous or not. (c) Thrombosis of the vessels — when the artery is thrombosed it feels midway between firm and soft and one can feel something within the artery. It must be remembered that in Buerger's disease not only the distal arteries but also the veins are thrombosed.

One should always compare with the pulsation of the same artery on the other side. In cervical rib and scalenus anticus syndrome, the two radial pulses are felt simultaneously after pulling both the arms downwards. This will cause diminution or obliteration of the pulse on the affected side.

15. **Neurologic examination.**— Sensation of the gangrenous area is often

lost. The patient is unable to move the part when the viability of the deeper tissues becomes at stake. On the border line of the gangrene the skin becomes hyperaesthetic.

In case of superficial ulceration, one must exclude other disorders of the central nervous system e.g. hemiplegia, transverse myelitis, syringomyelia, tabes dorsalis etc.

16. **Adson's test.**— This test is positive in presence of cervical rib and scalenus anticus syndrome due to compression of the subclavian artery. The patient sits on a stool. He is instructed to take a deep breath in and to turn the face to the affected side. The examiner examines his radial pulse, which is often obliterated due to compression of the subclavian artery.

17. **Examination of the lymph nodes** (See chapter 8).

C. **AUSCULTATION.**— The importance of this examination cannot be overexaggerated. It is advisable to listen along the course of all major arteries. A systolic bruit over an artery is due to turbulent blood flow beyond stenosis. One should not exert too much pressure on the bell of the stethoscope, lest it should obliterate the artery and cause an artificial bruit. Systolic murmur can also be heard over an aneurysm. A bruit is also heard on the renal artery in case of hypertension due to renal artery stenosis. A continuous machinery murmur may be heard over an arteriovenous fistula. *Blood pressure of both the arms* are measured to exclude affection of subclavian, brachiocephalic or axillary artery. *Reactive hyperaemia* test is performed to know the severity of arterial ischaemia. This is done by inflating a sphygmomanometer cuff around the limb to 250 mm Hg for 5 minutes. Then the cuff is deflated and the time of appearance of red flush in the skin is noticed. It is 1 to 2 seconds in case of normal limb and it will be delayed in case of arterial occlusive disease and it may never appear in case of severely ischaemic limb.



Fig.6.15.— Adson's test. See the text.

GENERAL EXAMINATION

1. Atherosclerosis is a generalized disease and the patient must be examined thoroughly to exclude ischaemic heart disease, cerebro-vascular disease, hypertension, renal artery stenosis etc.

2. In embolic manifestation, the heart is examined for presence of cardiac murmur, which may indicate certain lesion to cause embolus formation.

3. Diabetes is often accompanied by atherosclerosis.

4. Peptic ulceration is sometimes found to be accompanied with these diseases.

SPECIAL INVESTIGATIONS

1. **Blood.**— Routine examination of blood along with W.R. (for syphilitic endarteritis obliterans), sugar (for diabetes), urea and electrolytes will give a clue to the diagnosis. Estimation of serum β-lipoprotein, triglyceride and cholesterol should be performed when atherosclerosis is suspected.

2. **Urine.**— Routine urine examination along with sugar will help the clinician to know whether the patient is diabetic or not and selective examination of urine from each kidney by ureteric catheterization will help the clinician to know whether there is renal vascular insufficiency or not.

3. **Straight X-Ray.**— This is helpful to diagnose (i) arteriosclerosis with presence of arterial calcification (Monckeberg's degeneration): (ii) aneurysm with flecks of calcium to outline it; (iii) gas gangrene with presence of gas as dark spots in soft tissue and (iv) cervical rib.

4. **Arteriography.**— This is the most reliable method of determining the state of the main arterial tree. This procedure gives information about the size of the lumen of the artery, the course of the artery, constriction and dilatation of the arteries and the condition of the collateral circulation ('Run off'). Hypaque 45 (Sodium Diatrizoate) is the contrast medium often used. Either of the following two methods is generally used :

(a) RETROGRADE PERCUTANEOUS CATHETERIZATION.— Under general or local anaesthesia with proper aseptic precaution a special needle and a cannula are introduced into the femoral or brachial artery (Seldinger technique). The common femoral artery is used for aortoiliac, renal, mesenteric and femoropopliteal arteriography, whereas the brachial artery is used for subclavian, vertebral, carotid and thoracic angiography. The needle is now withdrawn and a flexible guide wire is threaded through the cannula. The cannula is withdrawn and a polythene catheter is passed over the guide wire into the artery for a distance.

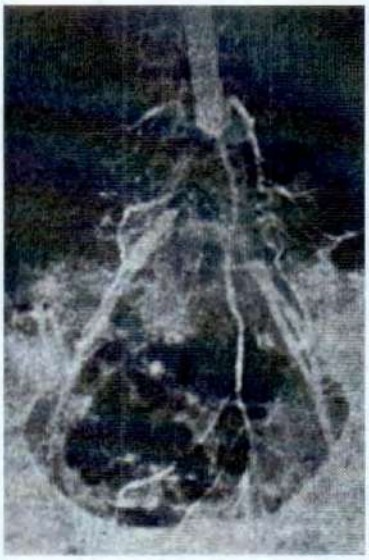

Fig.6.16.— Aortography showing an embolus obstructing the bifurcation of aorta.

To avert the dangers of arteriography namely (a) iodine sensitivity and (b) dissection of the arterial wall if the tip of the needle is partly within the wall of the artery, a *trial injection* of 5 to 10 millilitres of 45% hypaque is made. This will ascertain the position of the tip of the needle.

Either a ***free flush arteriography*** or a ***selective angiography*** is done. In free flush arteriography the tip of the catheter lies in the main aorta and a 'bolus' of 30 millilitres of the same contrast medium is injected rapidly. Series of X-ray exposures are made to see particularly the whole length of the arterial tree, the origins and the adjacent part of its branches. In selective angiogram the tip of the catheter is introduced into the corresponding artery to delineate the artery and its branches precisely.

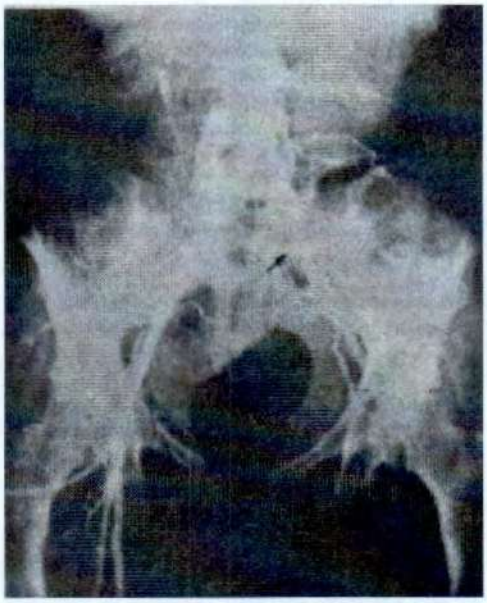

Fig.6.17.— Arteriography showing common iliac artery blockage.

(b) DIRECT ARTERIAL PUNCTURE.— This method is used in carotid angiogram. Abdominal aorta (translumbar route) may be chosen for aortoiliac and femoropopliteal arteriography when the femoral arteries are occluded or the retrograde method has failed to produce necessary information.

5. **Determination of blood velocity by Ultrasound Doppler Effect.**— By placing the probe of the apparatus over an artery, audible signals can be heard. Normal arterial sound consists of first, second and third sounds. In patients with occlusive lesion, abnormal signals can be obtained distal to the block and will be lost entirely over the site of the block. These abnormal sounds result from collateral flow and are of low pitch. The second and third sounds are absent when the flow signals are detected just below the stenotic lesion where high velocity flow is present, a single high-pitched continuous sound is present indicating turbulent flow.

This simple apparatus can be used to measure blood pressure at the ankle and at the arm. Normally the ankle systolic blood pressure is greater than the brachial (arm) systolic blood pressure by 5 to 15 mm Hg. So, the ratio of the ankle blood pressure and arm blood pressure will also be greater than one and is known as 'pressure index'. If this pressure index becomes less than one it indicates some degree of arterial occlusion. When the ankle blood pressure goes down to 30 mm Hg. or less, it indicates severe ischaemia and imminent gangrene.

6. **Isotope technique.**— Xenon 133 dissolved in isotonic saline is injected intramuscularly and the clearance of which has been used to study the blood flow in the calf muscles. Recently Technetium 99 has become the isotope of choice though the technique remains essentially the same. More recently intravenous injection of isotope has been used to get a direct arterial visualization. For this a gamma camera is used to picturise the blood flow in a limb.

7. **Electromagnetic flow meter.**— When a column of blood moves an electric potential is produced which is proportional to the velocity of blood and the magnetic field strength. The electric potential is produced at right angles to the flow. It bears a linear relationship to the velocity of the blood flow. Two electrodes are placed diametrically opposite to each other in contact with the arterial wall. This is the 'cuff' type of electromagnetic flow meter. The electrodes on the surface of the artery pick up an electromotive force induced in the blood by its motion through the magnetic field and feed it back to suitable electronic amplification. Such a method can detect the change in the rate of the blood flow of 1 %. But the greatest disadvantage of this technique is that the artery has to be exposed.

8. **Blood Lipids.**— Abnormal high level of blood lipids e.g. blood cholesterol, lipoproteins, triglycerides etc. is often found in atherosclerotic occlusion. Many of these patients are diabetic, though they may not show increased level of sugar in the blood. For this, glucose tolerance test should be performed.

9. **Investigation for vasospasm.**— In early part of Raynaud's disease or Buerger's disease, vasospasm is the main cause of arterial obstruction. It is at this stage that sympathectomy plays its greatest role. Later on organic changes develop and sympathectomy does not do much good to the patient. So, importance of finding out the degree of vasospasm cannot be overemphasized to assess the value of sympathectomy. The method is nerve block with local anaesthetic e.g. the posterior tibial nerve behind the medial malleolus, the ulnar nerve behind the medial epicondyle or spinal anaesthesia in case of whole lower limb. Any rise of skin temperature is recorded and is compared with the rise of mouth temperature.

$$\text{Brown's vasomotor index} = \frac{\textbf{Rise of skin temp. – Rise of mouth temp.}}{\textbf{Rise of mouth temperature}}$$

Operation is only advisable when the index is 3.5 or more.

10. **Plethysmography.**— This method is one of the earliest methods of measuring blood flow in human limbs. Venous outflow from a limb is briefly arrested while allowing arterial inflow to measure the volume change in the limb which is proportional to the arterial inflow. Three systems have been used e.g. water-filled volume recorder, air-filled volume recorder and the mercury in a silastic strain gauze. This technique is still a good non-invasive method of measurement of blood flow. But it has rarely been found suitable for screening method for surgery, as the surgeon is more interested to know the site of the arterial block rather than to measure the blood flow as such. Recently **segmental plethysmography** has been introduced by placing venous occlusion cuffs around the thigh, calf and ankle. The cuffs are inflated to 65 mm Hg and the pulsation is the quantitative measure of the arterial diseases.

11. **Oscillometry.**— This is of particular value in detecting arterial pulsation at different levels of the limb. In embolism, a sudden decrease in the movement of its needle is obtained at the level of arterial occlusion. In thromboangiitis obliterans, if no pulsation is obtained in the leg, amputation should be performed in the thigh. But if oscillation can be seen in the leg a lower amputation should be advised.

SIGNS OF GANGRENE

1. Change of colour — pale, bluish purple and finally black; 2. Loss of temperature; 3. Loss of sensation; 4. Loss of pulsation and 5. Loss of function.

CLINICAL TYPES

1. **Dry gangrene.**— This results from gradual occlusion of arterial circulation, mostly seen in atherosclerosis. The affected part becomes dry, shrivelled, hard, mummified and discoloured from disintegration of haemoglobin.

2. **Moist (wet) gangrene.**— This results when the artery is suddenly blocked, as by an embolus or when gangrene is superimposed on and associated with inflammation. Due to infection and putrefaction the affected part becomes oedematous with blebs. Crepitus can be felt when there is presence of gas as seen in gas gangrene.

The term **'Pregangrene'** is used to describe the changes in the tissue to indicate that its blood supply is so precarious that it will soon be inadequate to keep the tissue alive.

CAUSES OF ISCHAEMIA can be broadly classified as follows :—

Large artery occlusion	*Small artery occlusion*
1. Atherosclerosis (Chronic).	1. Buerger's disease.
2. Embolism (Acute).	2. Raynaud's disease.
	3. Embolism.
	4. Diabetes.
	5. Scleroderma.
	6. Physical Agents — Trauma, Radiation, Electric burns, Pressure necrosis.

CAUSES OF GANGRENE

1. **Cardiovascular disease.**— Senile gangrene (due to atherosclerosis); embolic gangrene; Raynaud's disease; Buerger's disease; cervical rib; syphilitic gangrene (due to endarteritis obliterans).

2. **Traumatic gangrene.**— Direct (injury to the main artery) or indirect (crushing of the tissues).

3. **Infective gangrene.**— (a) Acute e.g. carbuncle, cancrum oris and postoperative progressive gangrene following drainage of empyema and appendicectomy, (b) Gas gangrene.

4. **Diabetic gangrene.**

5. **Nervous diseases.**— Syringomyelia, tabes dorsalis, peripheral neuritis, leprosy, caries spine, fracture-dislocation of spine etc.

6. **Physical gangrene.**— Due to heat, cold (Frost Bite), corrosive, X-ray etc.

DIFFERENTIAL DIAGNOSIS

Senile gangrene.— The usual victims are generally elderly persons above 50 years of age. The lower limbs are commonly involved. The patient will first complain of intermittent claudication. The claudication distance will gradually be reduced. There will be marked coldness of the feet and the patient will soon complain of 'rest pain'. Gradually dry gangrene will be developed with superficial ulceration. Various special investigations as stated above will help the clinician to diagnose the condition and the level of the block. Straight X-ray may reveal calcification of the arterial wall. Arteriography is also very helpful in detecting the site of block. Patients with bilateral internal iliac occlusion may complain of impotence, which is known as *Leriche's syndrome.*

Buerger's disease (Thromboangiitis obliterans).— The usual victims of this disease are *young men* below 40 years of age. It is the inflammatory reaction in the arterial wall with involvement of the neighbouring vein and nerve, terminating in thrombosis of the artery. The lesions in Buerger's disease are segmental and usually begin in arteries of small and medium size. Both upper and lower extremities are affected. In lower extremity the disease generally occurs beyond popliteal artery, starting in tibial arteries extending to the vessels of the foot. The disease has also affected the arteries of the G.I. tract, lungs and heart. Early in the course of Buerger's disease the superficial veins are involved producing the characteristic migratory, recurrent superficial phlebitis. So far as aetiology is concerned this disease has a striking association with cigarette smoking. Majority patients of Buerger's disease come from lower socio-economic groups. An autoimmune aetiology has been postulated and familial predisposition has been reported.

The pedal arteries are involved first and the patients complain of pain while walking at the arch of the foot (foot claudication), somewhat less often at the calf of the leg, but never at the thigh or buttock (which is common in atherosclerosis). Pain is typical of intermittent claudication, which progresses to 'rest pain'. Gradually postural colour changes appear followed by trophic changes and eventually ulceration and gangrene of one or more digits and finally of the entire foot or hand may ensue. Buerger's test will be positive. Buerger's disease can be differentiated from Raynaud's disease by sex incidence, the extremity affected and disappearance of peripheral pulses. It is differentiated from senile gangrene by the age, by its association with superficial phlebitis and pitting oedema. Characteristic arteriographic appearance of this disease is the smooth and normal appearance of larger arteries combined with extensive occlusion of the smaller arteries alongwith extensive collateral circulation.

Raynaud's disease.— It is a disease of young women and commonly the upper limbs are affected specially the fingers (the thumb is generally escaped). The disease is characterized by Raynaud's phenomenon which is nothing but a series of attacks of local syncope, local asphyxia and local gangrene (see the text). Local syncope consists of tingling, numbness and blanching. Local asphyxia consists of pain and cyanosis. These two attacks are repeated until patches of

anaemic ulceration appear at the finger tips which is known as the stage of local gangrene. The *pulses remain unaffected,* as this is the disease which affects arterioles. Troublesome sweating is sometimes associated with this condition.

Embolic Gangrene.— The onset is sudden with agonizing pain radiating down the course of the artery. Distal to the occlusion the limb becomes cold and numb. Superficial veins remain empty. Presence of localized tenderness at the site of embolus and complete disappearance of pulse below this level are the pathognomonic features of this disease. The heart when examined carefully often gives an indication of the source of the embolus.

Thoracic outlet syndrome.— This syndrome is caused by compression of the brachial plexus or subclavian artery and/or vein in the region near the thoracic outlet. It may be caused by (i) cervical rib, (ii) scalenus anticus muscle, (iii) costoclavicular syndrome, (iv) pectoralis minor syndrome, (v) wide first thoracic rib, and (vi) fracture of the first rib or clavicle.

Neurologic symptoms are pain, paraesthesia and numbness in the fingers and hand in the ulnar nerve distribution. Symptoms of arterial compression include pain, numbness, paraesthesia, coldness and weakness of the hand. Venous symptoms include oedema, venous distension, pain and cyanosis. Costoclavicular compressive manoeuvre, hyperabduction manoeuvre and Adson's test will be positive.

Cervical rib.— Again young women are the usual victims. The symptoms gradually appear due to sagging down of the shoulder girdle with the advent of puberty. Sometimes symptoms appear later in life due to weakness of the muscles of the shoulder girdle. Presence of cervical rib does not always reveal symptoms or brings the patient to the surgeon. Symptoms of the cervical rib are mainly caused by angulation of the subclavian artery over the cervical rib and by the pressure irritation of the lowest trunk of the brachial plexus which contains the sympathetic nerve fibres to the upper limb. These symptoms will only appear when the muscles of the shoulder girdle will become weak and both the artery and the nerve trunk will be compressed on the cervical rib.

Symptoms of cervical rib can be described in 3 groups : —

(a) *LOCAL.*— The patient presents with hard and fixed lump in the lower part of the posterior triangle of the neck. There may be local pain and tenderness in the supraclavicular region.

(b) *NEUROGENIC.*— Symptoms are produced by pressure irritation of the lower trunk of brachial plexus. The symptoms can be divided into *sensory* (e.g. tingling, numbness and pain along the medial side of the forearm and hand), *motor* (e.g. loss of power of the hand with wasting of the thenar and hypothenar eminences leading ultimately to claw hand) and *vasomotor* (e.g. excessive sweating of the hand and circulatory impairment leading to gangrene).

(c) *VASCULAR.*— Pain in the forearm is often complained of which becomes worse with exercise. The hand becomes colder than its fellow on the opposite side. When the hand is elevated it looks pale and it becomes blue on prolonged dependent position due to cyanotic congestion. Numbness of the fingers is complained of and the radial pulse becomes feeble on the affected side.

X-ray often reveals the cervical rib, though sometimes a fibrous band in its place causes the symptoms like cervical rib and will not be seen by X-ray.

The **scalenus anticus syndrome** is one in which the clinical pictures very much resemble those of the cervical rib. Here the pull of the scalenus anterior muscle, which compresses the subclavian artery and the lower trunk of the brachial plexus, is responsible for the symptoms. Adson's test is helpful to arrive at the diagnosis.

Ainhum.— This condition is commoner in adult males, only occasionally found in women and children. Negroes, people of Central Africa, Central America and the East are more prone to be affected. It usually affects the little toe, sometimes the fourth and rarely the third, second or the great toe. Though it is rare in upper limbs yet cases are on the record when the terminal phalanx of the little finger has been involved. The disease starts as a linear groove in the skin on the inner and plantar side of the root of the toe. Frequently the involvement is bilateral affecting both the feet simultaneously or one after the other. The groove gradually deepens and extends round the whole circumference of the toe. The distal part becomes swollen as if the root of the toe has been tied with a ligature. The patient's main complaint is continuous and progressive pain. Rarely this pain may be absent. In course of time the toe falls off.

Infective gangrene.— (A) *CARBUNCLE.*— See page 46.

(B) CANCRUM ORIS — occurs in the mouth of the children usually in the terminal stage of typhoid fever, measles, kala-azar etc. The disease starts as stomatitis and causes ulceration and extensive sloughing. The condition is toxaemic manifestation of the severe diseases. This condition is more often seen in the undernourished. The affected area becomes ischaemic and very much swollen and ultimately undergoes gangrenous changes. Large areas of the cheeks, lips and even jaws are destroyed.

(C) *GAS GANGRENE.*— The causative organisms are mainly Clostridium Welchii and less commonly CI. septicum and CI. oedematiens. These organisms are present in the intestine and in soil. Gas gangrene is usually met with in street accident. Incubation period varies from a few hours to a few days. The onset is sudden accompanied by pain in the wound, swelling, fever, vomiting and toxaemia. Characteristic odour of H_2S may be obtained. Gradually the whole limb becomes swollen and tense with crepitation on palpation over the muscles. The muscles if exposed are seen brick-red or green or black according to the stage of the disease. The toxins produced by the anaerobic organisms exert a selective action on the adrenals and causes marked lowering of blood pressure. The diagnosis is confirmed by X-ray which reveals gas bubbles.

Types.— (i) Local type — when a single muscle is affected. (ii) Subcutaneous type — is very confusing as the crepitus becomes well spreading for a considerable distance around the wound. But the muscles are not affected. The infection seems to be localized in the subcutaneous tissue plane. (iii) Gas abscess — is also confusing as it is not a true example of gas gangrene but indicates only presence of gas around foreign body which has been lodged within the muscle. (iv) Group type — when a group of muscles is involved. (v) Massive type — when the whole limb is affected.

Diabetic gangrene.— This is quite commonly seen in diabetic individuals. There are three factors in causing diabetic gangrene; (i) atherosclerosis of the peripheral arteries; (ii) peripheral neuritis interfering with trophic function and (iii) diminished resistance to trauma and infection of the sugar-laden tissue. The gangrene is usually moist owing to infection (which is predominantly of fungal variety), unless atherosclerotic factor plays the major part when it becomes dry in nature.

Syphilitic gangrene.— This condition is very rare and is caused by endarteritis obliterans and gummatous infiltration of the arterioles. The patient is usually of middle age when the gangrene is often of dry type. Other syphilitic stigmas and positive W.R. and Kahn test will clinch the diagnosis.

Neuropathic gangrene.— Such gangrene is not due to ischaemia but due to lack of sensation. It is normally painless and progressive. Such gangrene occurs due to repeated trauma, compression and infection of the part which has lost sensation. The three features of such gangrene

are — (i) it is painless, (ii) the surrounding skin has lost sensation and (iii) the surrounding tissues have normal blood supply.

Carotid occlusive disease.— It occurs due to atherosclerosis at the origin of the internal carotid artery or at the bifurcation of the common carotid artery. Carotid stenosis causes transient, recurrent and progressive strokes causing hemiplegia of the contralateral side. When anyone presents with brief episodes of weakness, tingling or pins and needles or loss of sensation on one side of the body, which last for a few minutes and then fully recover, remember the possibility of carotid artery occlusive disease and auscult over the carotid artery if there be any bruit heard. If such episodes are ignored, it may cause a major stroke.

Subclavian steal syndrome.— This is due to atherosclerotic stenosis of the subclavian artery proximal to the site of origin of the vertebral artery. Reduction in pressure in the subclavian artery beyond the stenosis results in retrograde flow from the brain stem down the vertebral artery to the arm (so blood is stolen from brain). Exercise of the upper arm produces syncopal attacks due to ischaemia of the brain stem with visual disturbances alongwith decreased pulse and blood pressure in the symptomatic arm. There may be localized bruit in the supraclavicular space.

Aortic-arch occlusive disease (Takayasu's arteritis).— Sometimes a non-specific arteritis affects major branches of the aortic arch. This arteritis involves all layers of the aortic wall. It is particularly noticed among young Japanese women. It affects mainly the head, face and upper extremities in the form of transient fainting, headache, atrophy of the face, optic nerve atrophy and paraesthesia and weakness of the upper limbs. There may be fever, malaise and general arthralgia.

Anterior compartment syndrome.— Any condition which increases fluid in the anterior compartment of the leg, causes increase of pressure in this closed space surrounded by deep fascia. This causes obstruction of veins in the beginning which increases accumulation of fluid in this compartment, so that intracompartmental pressure gradually exceeds arterial pressure causing occlusion of arteries in this compartment leading to ischaemia of the distal limb. Pain is the first and most important symptom. Gradually erythema of the skin over the anterior compartment is noticed and later on dorsalis pedis pulse becomes diminished or absent leading to ischaemic changes in the toes.

Acrocyanosis.— The basic pathology is the slow rate of blood flow through skin due to chronic arteriolar constriction may be due to constant spasm in response to an overactive vasomotor system. This results in a high percentage of reduced haemoglobin in the capillaries and this is the cause of cyanotic colour. This condition affects young women. Coldness and blueness of the fingers and hands are persistantly present for many years. It must be remembered that in this condition there is *persistent, painless* cold and cyanosis of the hands and *feet*. Though this condition mimics Raynaud's syndrome, yet the italic words in the previous sentence are the distinguishing features. The peripheral pulses are usually normal.

ACUTE ARTERIAL OCCLUSION

Sudden occlusion of a major peripheral artery can be due to (A) Arterial embolus, (B) Trauma or (C) Acute arterial thrombosis.

(A) Arterial embolus.— 'Embolus' is a greek word which means 'something thrown in'. Two types of embolisation may occur — cardioarterial embolisation or arterioarterial embolisation. *Cardioarterial embolisation* occurs in majority of cases of emboli in the lower extremity and

such emboli originate in the heart either due to atrial fibrillation, mitral stenosis or myocardial infarction. *Arterioarterial embolisation* originates from atherosclerotic plaque which has been ulcerated. In the lower extremity emboli usually lodge at the bifurcation of common femoral artery or at the bifurcation of popliteal artery or at the bifurcation of common iliac artery or at the bifurcation of aorta in order of frequency. In superior extremity the commonest site is at the bifurcation of the brachial artery followed by the axillary artery near shoulder joint.

The result of arterial embolisation is the immediate onset of severe ischaemia of the tissue supplied by the involved arteries.If untreated, gangrene occurs in 50% of cases. The peripheral nerves are very sensitive to ischaemia and this leads to pain, paraesthesia and paralysis,

(B) **Arterial trauma** may also cause acute arterial occlusion. The causes of arterial trauma are:— (a) Most arterial injuries result from *penetrating wounds* which partly or completely disrupt the walls of the arteries. (b) Pressure on a major artery by an angulated bone. (c) Intimal rupture of a major artery due to fracture or dislocation. (d) Injury to a major artery by a bone fragment. Followings are the fractures and dislocations which may cause acute arterial occlusion — (i) Supracondylar fracture of humerus; (ii) Supracondylar fracture of femur; (iii) Dislocated shoulder; (iv) Dislocated elbow; (v) Dislocated knee.

(C) **Acute arterial thrombosis.**— The most common site is the lower end of the femoral artery where it leaves subsartorial canal to enter the popliteal space. Commonly acute thrombosis occurs in an artery considerably narrowed by arterial disease. Moreover acute-on-chronic arterial thrombosis may occur in which case acute conditions develop on already existing chronic occlusion.

Pain in the limb is the most important and initial symptom which affects the limb distal to the acute arterial occlusion. Numbness and weakness are also present. The ischaemic portion of the limb assumes a cadaveric pallor described as 'waxy' pallor. Within 1 hour or so the part becomes cyanosed. The prominent veins become emptied and guttered. Pulses distal to the obstruction are absent. The local temperature of the ischaemic area is appreciably cold. There may be calf tenderness or pain on dorsiflexion of foot in an otherwise anaesthetic limb. The clinical features of acute arterial occlusion are best described by 5 'P's — **P**ain, **P**aralysis, **P**araesthesia, **P**allor and absent **P**ulses. Neurologic symptoms carry a prognostic value. If motor and sensory functions are intact, the extremity will survive. In majority of cases there may be some sensory disturbances only, which vary from paraesthesia to anaesthesia.

In *aortic embolism,* pain is felt in both the lower limbs, there is also loss of movements of hips and knees. Coldness and numbness and change of colour affect the inferior extremities below the hip joints or midthighs.

In *femoral embolism,* femoral pulse may be felt, but it affects the leg and foot. Numbness, coldness and change of colour are seen below the knee joint.

In *popliteal embolism,* there is pain in the lower leg and foot, there is loss of movement of the toes. Coldness, numbness and change of colour are seen only in the foot.

In *axillary embolism,* pain involves the whole of the upper arm. Numbness, coldness and change of colour are noticed in the hands and distal forearm. There may be loss of movements in the wrist and fingers.

In *brachial embolism* pain is complained of in distal forearm and hand. Numbness, coldness and change of colour are only seen in the fingers.

It is always advisable to examine the heart alongwith E.C.G. Though angiography is quite helpful in diagnosing the case it may delay operation. So in these cases clinical diagnosis is more considered before operation. Doppler ultrasound may be of some help.

ANEURYSM

Definition.— Dilatation of a localized segment of arterial system is known as aneurysm.

Broadly, an aneurysm can be classified into 3 types — (a) True aneurysm, (b) False aneurysm and (c) Arteriovenous aneurysm.

(a) *True aneurysm* is one, which contains all the three layers of the arterial wall in the aneurysm. (b) *False aneurysm* is one, which has a single layer of fibrous tissue at the wall of the sac.

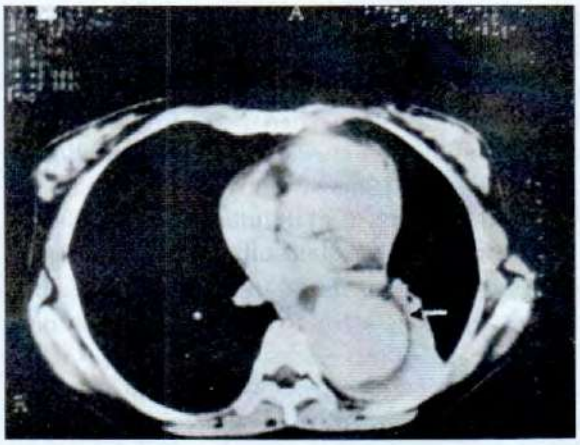

Fig.6.18.— Dissecting aneurysm of the thoracic aorta.

A true aneurysm, *according to shape*, may be fusiform, saccular or dissecting aneurysm. FUSIFORM ANEURYSM occurs when there is uniform expansion of the entire circumference of the arterial wall. SACCULAR ANEURYSM is an expansion of a part of the circumference of the arterial wall. This is usually traumatic. DISSECTING ANEURYSM occurs when tunica intima ruptures usually beneath an atheromatous plaque and the blood is forced through the intima to enter between the inner and outer courts of the tunica media.

An aneurysm can occur in any artery, though abdominal aorta, femoral and popliteal arteries are more commonly affected. However splenic, renal and carotid arteries have also undergone aneurysmal changes.

CAUSES.— Aneurysm usually occurs due to weakening of the wall of the artery. Aneurysms can be I. Congenital or II. Acquired.

I. *CONGENITAL.*— (i) Congenital aneurysm may occur in the cerebral blood vessels particularly in the circle of Willis due to congenital deficiency of the elastic lamina at the sites of branching — this is known as *Berry aneurysm.* (ii) Cirsoid aneurysm (Fig.3.54). (iii) Congenital arteriovenous fistula. (iv) Congenital aneurysm may occur in Marfan's syndrome or Ehler-Danlos syndrome.

II. *ACQUIRED* varieties are further classified into A. Traumatic, B. Degenerative and C. Infective.

A. *Traumatic* may be due to (i) direct trauma such as penetrating wounds to the artery. (ii) Irradiation aneurysm. (iii) Arteriovenous aneurysm from trauma. (iv) Indirect trauma may cause aneurysm e.g. at the subclavian artery distal to the point where it crosses the cervical rib.

B. *Degenerative* is by far the most common group and (i) atherosclerosis is the commonest cause of aneurysm. (ii) A peculiar aneurysm of the abdominal aorta is noticed in young South African Negroes which is due to intimomedial mucoid degeneration.

C. *Infective.*— (i) Syphilis. (ii) Acute infection may lead to formation of aneurysm. (iii) Mycotic aneurysm. (iv) Aneurysm may occur in an artery traversing tubercular cavity in the lung, (v) Infected embolus resting on peripheral artery may produce weakening of the wall forming aneurysm. (vi) Aneurysm may occur in an artery situated at the base of a peptic ulcer. (vii) Arteritis, particularly polyarteritis.

SYMPTOMS.— Aneurysm may be asymptomatic, when it is detected accidentally.

(i) The commonest presenting symptom is a *dull aching pain.* (ii) *Acute pain* may occur when the vessel suddenly stretches. (iii) *Severe pain,* bursting in nature, is complained of when an aneurysm ruptures and a large haematoma forms. *Referred pain* is due to pressure on a nerve e.g. patients with abdominal aortic aneurysm may present with sciatica. (iv) A common mode of presentation is a *pulsatile mass* — more often seen in femoral and popliteal aneurysm. (v) Sometimes patients may present with *severe ischaemia of the lower limb* due to thrombosis of the aneurysm, which is more common in popliteal aneurysm. (vi) Patient may present with less severe ischaemia caused by emboli originating in the aneurysm. (vii) Aneurysm may present with *venous obstruction* and *thrombosis* when enlargement of artery causes direct pressure on the neighbouring vein. Presentation is painful swollen and blue limb.

EXAMINATIONS.— (i) Pulsatile swelling exhibiting expansile pulsation in the course of an artery should be suspected as aneurysm. (ii) Pulsation diminishes when pressure is applied proximal to the swelling. (iii) The swelling is compressible. (iv) A thrill may be palpable over the swelling. (v) On auscultation, a systolic bruit may be heard over the swelling. (vi) The swelling can be moved sideways but not along the course of the artery. (vii) Evidence of peripheral arterial insufficiency or venous obstruction may be present in the distal limb.

Effects of aneurysm.— A. *Effects of pressure on neighbouring structure.*— (i) Pressure on veins — leads to oedema of distal limb. (ii) Pressure on the nerves — leads to altered sensation e.g. pain, numbness, tingling and paraesthesia. (iii) Pressure on bones — leads to erosion of the bones. (iv) Pressure on adjacent organs — may cause dysphagia if oesophagus is pressed by aortic aneurysm; aortic aneurysm may burst into stomach causing severe haematemesis. (v) Pressure on the skin — causes stretching of overlying skin which becomes red and oedematous showing features of inflammation and thus aneurysm has been incised with the wrong diagnosis of an abscess with grave consequences.

B. *Thrombosis.*— Laminated thrombus in an aneurysm may reduce the blood to the distal limb. Sometimes arteriography cannot diagnose an aneurysm as such thrombosis does not show dilated sac in arteriography.

C. *Emboli formation.*— Multiple small emboli may originate from aneurysm and block very distal arteries leading to intermittent claudication, rest pain and even gangrene of the toes.

Complications of aneurysms.— 1. *Pressure on adjacent structures.*— See above. 2. *Thrombosis* and *emboli formation* — leads to circulatory insufficiency of the inferior extremity. 3. *Infection* — may occur from organisms in the blood and signs of inflammation become evident. 4. *Rupture* — is the gravest and ultimate complication of aneurysm. 5. *Spontaneous cure* — occasionally occurs particularly in saccular aneurysm due to gradual formation of clot.

Differential diagnosis.— 1. *Swellings over the arteries* — which yield 'transmitted pulsation'. Pseudopancreatic cyst is an example.

2. *Swelling beneath the artery* e.g. cervical rib pushing up the subclavian artery.

3. *Pulsating tumours* e.g. telangiectatic osteosarcoma, very vascular osteoclastoma, metastasis from hypernephroma and follicular carcinoma of thyroid, aneurysmal bone cyst.

4. *An abscess.*

Arteriography is the main diagnostic tool, though sometimes it cannot reveal dilatation of the artery due to presence of laminated thrombus inside the arterial sac.

ARTERIOVENOUS ANEURYSM.— Communication between an artery and adjacent vein leads to arteriovenous aneurysm or arteriovenous fistula. CAUSES are (i) *CONGENITAL e.g.* cirsoid aneurysm. (ii) *ACQUIRED* — mainly traumatic. (a) When the artery and the vein communicate through a short wide channel it is called *aneurysmal varix.* (b) When anastomosis becomes indirect

through an intermediate sac lying in the soft tissues it is called *varicose aneurysm.* (iii) *IATROGENIC.*— Arteriovenous fistula is created surgically for renal dialysis.

MANIFESTATIONS.— A. *SYSTEMIC EFFECTS.*— (i) Cardiac output increases. (ii) Heart rate increases. (iii) Pulse pressure increases i.e. diastolic pressure diminishes with increase in systolic pressure. (iv) Right and left atrial pressures are increased with increase in pulmonary wedge pressure. (v) The blood and plasma volume increase. (vi) The heart size increases with cardiac hypertrophy. (vii) Congestic cardiac failure in case of arteriovenous fistula. (viii) Central Venous Pressure (CVP) is often increased. (ix) Sometimes bacterial endocarditis may associate with this condition.

B. *LOCAL EFFECTS.*— (i) *Aneurysmal dilatation* at the site of fistula. (ii) Extensive collateral circulation with increase in temperature of the limb. (iii) The limb may be increased in length due to increase in bone growth from elevated local temperature. (iv) *A thrill* over the site of the lesion is quite characteristic. (v) The veins are enlarged and varicosed.

CLINICAL FEATURES.— 1. A pulsatile swelling may be detected if the lesion is superficial. 2. There is increased temperature of the skin with port-wine discolouration due to increased collateral circulation. 3. Distended superficial veins. 4. Increased length of the limb is noticed particularly when the fistula is congenital. 5. On palpation, a thrill is detected at the site of the lesion. Pressure on the artery on the proximal of the fistula causes diminution of the swelling. 6. Below the fistula the limb is ill-developed and feels cooler. 7. Below the fistula muscle wasting may be noticed alongwith ischaemic changes. Even indolent ulcer may be noticed — this is due to inadequate arterial supply below the fistula due to diversion of blood into the veins. 8. Auscultation reveals continuous bruit. 9. *Branham's sign* — in which if a finger is pressed on the artery proximal to the fistula there will be slowing of pulse rate and rise in diastolic pressure.

Chapter

7 EXAMINATION OF VARICOSE VEINS

A vein is called 'varicose' when it is dilated and tortuous. There are various places in the body where veins show tendency towards varicosity e.g. veins of the lower limb, spermatic veins, oesophageal veins and haemorrhoidal veins. In this chapter we shall only discuss the varicose veins of the lower limbs. The others will be discussed in appropriate chapters.

So far as the aetiology is concerned varicose veins mostly occur due to incompetence of their valves. It is not found in other animals and seems to be a part of penalty of erect posture which the human beings have adopted. It occurs commonly in those whose works demand standing for long hours e.g. conductors, drivers of the trams etc. Yet it is not uncommon in women. So some other aetiologic factors seem to play major roles. These are tone and contractility of the muscles of the lower limb being encircled by a tough deep fascia. Incompetence of valves, which may be a sequel of venous thrombosis, seems to be the most important factor in initiating this condition. Varicosity may also be secondary, predisposed by any obstruction which hampers venous return e.g. tumours (abdominal tumours, fibroid, ovarian cyst, abdominal lymphadenopathy), pregnancy, loaded colon, retroperitoneal fibrosis, ascites. A hormonal factor (progesterone?) gives an indication of occurrence of this disease in females. In younger age group congenital arteriovenous fistula may be the cause of varicose vein.

HISTORY.— 1. AGE.— Though varicose vein can affect individuals of all age groups, yet middle-aged individuals are the usual sufferers.

2. SEX.— Women are affected much more commonly in the ratio of 10 : 1.

3. ETHNIC GROUP.— Varicose veins are less commonly seen in primitive civilizations — the poor in Africa and Far East.

4. OCCUPATION.— Certain jobs demand prolonged standing e.g. tram drivers, policemen etc. and the persons involved in these jobs often suffer from varicose veins. Varicose veins may also occur in individuals involved in excessive muscular contractions e.g. Ricksaw-pullers and athletes. It is doubtful if these occupations cause the varicose veins or they just exacerbate the symptoms already present.

Symptoms.— The commonest symptom is the *pain* which is aching sensation felt in the whole of the leg or in the lower part of the leg according to the position of the varicose vein particularly towards the end of the day. The pain gets worse when the patient stands up for a long time and is relieved when he lies down. One thing the student must always remember that it is not the varicose veins which produce the symptoms, but it is the disordered psychology which is the root of all evils. So it is not impossible to come across asymptomatic varicose veins on one side and severe symptoms with very few visible varicose veins on the other side.

Patient may complain of bursting pain while walking, which indicates deep vein thrombosis. Night cramps may also be present. The ankle may swell towards the end of the day and the skin of the leg may be itching. Some patients complain of severe cramps at nights. Varicose ulcer may be seen on the medial malleolus.

A few questions should be asked.— (i) Whether the patient is feeling difficulty in standing or walking, which indicates presence of deep vein thrombosis. (ii) The patient should be asked if he has any other complaint than varicose vein itself. He may feel such complaint as irrelevant. If the patient is suffering from constipation or a swelling in the abdomen, it may be a cause of secondary varicose vein.

Past history.— Enquiry must be made if the patient had any injection treatment or operation for varicose veins. Any serious illness or previous complicated operation may cause deep vein thrombosis which is the cause of varicose vein now.

Personal history.— Women should be asked about obstetric history, like details of previous pregnancies. Whether the patient suffered from 'white leg' during the previous pregnancies. If the patient had contraceptive pills for quite a long time, as this may cause deep vein thrombosis.

Family history.— It is not uncommon to find varicose veins to run in families. Often patient's mother and sisters might have suffered from this disease.

PHYSICAL EXAMINATION

A. **INSPECTION.**— 1. **Varicose veins.**— Note, which vein has been varicosed — *long saphenous* or *short saphenous* or both. In case of the former a large venous trunk is seen on the medial side of the leg starting from in front of the medial malleolus to the medial side of the knee and along the medial side of the thigh upwards to the saphenous opening. This venous trunk receives tributaries in its course. In case of short saphenous vein varicosity the dilated venous trunk is seen in the leg from behind the lateral malleolus upwards in the posterior aspect of the leg and ends in the popliteal fossa.

2. **Swelling.**— It may be (a) either *localized* as in case of varicose veins affecting a segment of superficial vein or the whole trunk of a venous system — either long or short saphenous vein. Localized swelling may also be due to superficial thrombophlebitis. (b) *Generalized* swelling of the leg is mostly due to deep vein thrombosis.

3. **Skin of the limb.**— (i) **COLOUR.**— Local redness is usually due to superficial thrombophlebitis. Generalized change of colour may be white *(phlegmasia alba dolens)* also known as 'white leg'. This is due to swollen limb from excessive oedema or lymphatic obstruction. More important for this chapter is when the skin of the limb becomes congested and blue due to deep vein thrombosis and this condition is called *phlegmasia cerulea dolens.* In such severe venous obstruction the arterial pulses may gradually disappear and venous gangrene may ensue.

(ii) **TEXTURE.**— The affected limb should be carefully inspected to note (a) if the skin is stretched and shiny due to oedema following deep vein thrombosis. (b) If there is eczema or pigmentation of the skin affecting mostly the medial aspect of the lower part of the leg (around medial malleolus). (c) If there is any ulceration, often seen on the medial aspect of the lower part of the leg, which is known as the venous ulcer (See page 73 & 104 and Fig.4.10). (d) *Scar* may be seen at the lower part of the leg which may be due to healed venous ulcer or previous operation for varicose veins. (e) One should also carefully inspect the toes to note if there is loss of hair or increased brittleness of the nails due to chronic varicosity which may indicate impending venous gangrene.

4. The patient should be asked to cough and it is noted whether there is any *impulse on coughing* at the saphenous opening ('Saphena-varix'). This test is known as Morrissey's test which is more elaborately described in the section of palpation.

B. **PALPATION.**— Examination of the varices is very important. The aim is to locate the incompetent valves communicating the superficial and deep veins.



Fig.7.1.— Fine demonstration of long saphenous varicosity.

1. **Brodie-Trendelenburg test.**— This test is performed to determine the *incompetency of the sapheno-femoral valve* and other communicating systems. This test can be performed in two ways. In both the methods, the patient is first placed in the recumbent position and his legs are raised to empty the veins. This may be hastened by milking the veins proximally. The sapheno-femoral junction is now compressed with the thumb of the clinician or a tourniquet is applied just below the sapheno-femoral junction and the patient is asked to stand up quickly. (1) In first method, the pressure is released. If the varices fill very quickly by a column of blood from above, it indicates incompetency of the sapheno-femoral valve. This is called a positive Trendelenburg test. (2) To test the communicating system, the pressure is not released but maintained for about 1 minute. Gradual filling of the veins during the period indicates *incompetency of the communicating veins,* mostly situated on the medial side of the lower half of the leg allowing the blood to flow from the deep to the superficial veins. This is also considered as a positive Trendelenburg test and the positive tests are indications for operation.



Figs.7.2 to 7.4.— Show how to perform Trendelenburg test. See the text.

In case of short saphenous vein same test is done by pressing the sapheno-popliteal junction.

2. **Tourniquet test.**— It can be called a variant of Trendelenburg test. In this test the tourniquet is tied round the thigh or the leg at different levels after the superficial veins have been made empty by raising the leg in recumbent position. The patient is now asked to stand up. If the veins above the tourniquet fill up and those below it remain collapsed, it indicates presence of incompetent communicating vein above the tourniquet. Similarly if the veins below the tourniquet fill rapidly whereas veins above the tourniquet remain empty, the incompetent communicating vein must be below the tourniquet. Thus by moving the tourniquet down the

leg in steps one can determine the position of the incompetent communicating vein.

The number of incompetent communicating sources in the lower limb in the long saphenous vein is the sapheno-femoral junction (most important), the mid-thigh perforator, the lower-thigh perforator and the lower leg perforators on the medial side.

In case of short saphenous incompetence — application of the venous tourniquet to the upper thigh has the paradoxical effect of increasing the strength of the reflux, as shown by faster filling time. The sign, which has not been described before, is pathognomonic of varices of the short saphenous system. The mechanism is very simple — application of the upper thigh tourniquet blocks off the normal internal saphenous system which is carrying most of the superficial venous return and thus thrown into greater prominence the retrograde leak for the saphenous-popliteal junction. Final definite proof of short saphenous incompetence is obtained through following examination :— The saphenopopliteal junction is marked with a pen with the patient standing. The short saphenous vein is emptied by elevation of the leg, firm thumb pressure is applied to the ink mark. The patient is made to stand. The pressure is released and the vein will be filled immediately. For all practical purposes that *there is no other incompetent perforating vein in the short saphenous system should be remembered.*



Fig.7.5.— Shows how to perform Perthes' test.

3. **Perthes' test.**— The affected lower extremity is wrapped with elastic bandage. With the elastic bandage on the patient is instructed to move around and exercise. Severe crampy pain is complained of if there is deep vein thrombosis. Of course arterial occlusive disease should be excluded.

4. **Perthes' test** (Modified).— This test is primarily intended to know whether the deep veins are normal or not. A tourniquet is tied round the upper part of the thigh tight enough to prevent any reflux down the vein. The patient is asked to walk quickly with the tourniquet in place (Fig. 7.5). If the communicating and the deep veins are normal the varicose veins will shrink whereas if they are blocked the varicose veins will be more distended.

5. **Schwartz test.**— In a long-standing case if a tap is made on the long saphenous varicose vein in the lower part of the leg an impulse can be felt at the saphenous opening with the other hand.

6. **Pratt's test.**— This test is performed to know the positions of leg perforators. Firstly an Esmarch elastic bandage is applied from toes to the groin. A tourniquet is then applied at the groin. This causes emptying of the varicose veins. The tourniquet is kept in position and the elastic bandage is taken off. The same elastic bandage is now applied from the groin downwards. At the positions of the perforators 'blow outs' or visible varices can be seen.



Fig.7.6.— Shows how to perform Schwartz test.

These are marked with a skin pencil.

7. **Morrissey's Cough Impulse Test.**— The limb is elevated to empty the varicose veins. The limb is then put to bed and the patient is asked to cough forcibly. An expansile impulse is felt in the long saphenous vein particularly at the saphenous opening if the sapheno-femoral valve is incompetent. Similarly a bruit may be heard on auscultation.

8. **Fegan's method to indicate the sites of perforators.**— In standing posture the places of excessive bulges within the varicosities are marked. The patient now lies down. The affected limb is elevated to empty the varicosed veins. The examiner palpates along the line of the marked varicosities carefully and finds out gaps or pits in the deep fascia which transmit the incompetent perforators.

9. One should look *for pitting oedema* or *thickening, redness* or *tenderness* at the lower part of the leg. These changes are due to chronic venous hypertension following deep vein thrombosis. Sometimes a progressive sclerosis of the skin and subcutaneous tissue may occur due to fibrin deposition, tissue death and scarring. This is known as *lipodermatosclerosis* and is also due to chronic venous hypertension. This may follow formation of venous ulcer.

C. **PERCUSSION.**— If the most prominent parts of the varicose veins are tapped, an impulse can be felt by the finger at the saphenous opening. This is known as *Schwartz test* (Fig.7.6). Sometimes the percussion wave can be transmitted from above downwards and this will imply absent or incompetent valves between the tapping finger and the palpating finger.

D. **AUSCULTATION.**— The importance of auscultation is limited to the arteriovenous fistula, where a continuous machinery murmur may be heard.

E. **Regional lymph nodes** (inguinal) — are only enlarged if there be venous ulcer and this is infected.

F. **Other limb** — should be examined for presence of varicose veins and different tests to exclude deep vein thrombosis, incompetent perforators and venous ulcer to plan treatment.

GENERAL EXAMINATION

Examination of the abdomen.— Of the general examinations, examination of the abdomen is probably the most important so far as a case of varicose vein is concerned. Sometimes a pregnant uterus or intrapelvic tumour (fibroid, ovarian cyst, cancer of cervix or rectum) or abdominal lymphadenopathy may cause pressure on the external iliac vein and becomes responsible for secondary varicosity.

Complications of varicose veins.— 1. HAEMORRHAGE.— It may occur from minor trauma to the dilated vein. The bleeding may be profuse due to high pressure within the incompetent vein. Simple elevation of the leg does a lot to stop such bleeding. 2. PHLEBITIS.— This may occur spontaneously or secondary to minor trauma. Mild phlebitis may be produced by the sclerosing fluid used in the injection treatment. In this condition varicose vein becomes extremely tender and firm. The overlying skin becomes red and oedematous. Pyrexia and malaise may be associated with. 3. ULCERATION (Fig. 4.10).— This is more due to deep venous thrombosis rather than varicose veins alone. The patients often give previous history of venous thrombosis suggested by painful swelling of the leg. After thrombosis has been recanalised the valves of the deep veins are irreparably damaged. The deoxygenated blood gets stagnated in the lower part of the leg particularly on the medial side where there are plenty of perforating veins. The superficial tissue loses its vitality to certain extent and a gravitational ulcer follows either spontaneously or following minor trauma. The majority of patients with venous ulcers have incompetent communicating veins. The arteries and nerves should be examined to exclude other causes of

ulceration. These ulcers are commonly found at the lower third of the leg, usually on the medial side and even on the foot, but *never* above the junction of the middle and lower thirds of the leg. Venous ulcers are shallow and flat. The edge of the ulcer is sloping and pale purple-blue in colour. The floor is usually covered with pink granulation tissue. In chronic ulcers white fibrous tissue are more seen than pink granulation tissue. The discharge is seropurulent with trace of blood. The surrounding tissues show signs of chronic venous hypertension i.e. induration, tenderness and pigmentation. These ulcers have ragged edges. If the ulcer is healing, a faint blue rim of advancing epithelium may be seen at the margin. Rarely malignancy can develop at the edge of a long standing venous ulcer *(Marjolin's ulcer)*. A patient when presents with long history of venous ulceration with edge raised and everted or different from the typical features of ulcer described above and when the inguinal lymph nodes are enlarged — it is suspicious of a Marjolin's ulcer (Malignant change in a chronic ulcer). 4. PIGMENTATION. 5. ECZEMA. 6. LIPODERMATOSCLEROSIS.— This means the skin becomes thickened, fibrosed and pigmented. This is due to high venous pressure which causes fibrin accumulation around the capillary and it also activates white cells. 7. CALCIFICATION OF VEIN. 8. PERIOSTITIS in case of long-standing ulcer over the tibia. 9. EQUINUS DEFORMITY.— This only results from long-standing ulcer. When the patient finds that walking on the toes relieves pain, so he continues to do so and ultimately the Achilles tendon becomes shorter to cause this defect.

CAUSES of Varicose veins in the lower limb.—

Primary

Cause is not known. The valves are incompetent both of the main vein or of the communicating veins. Venous walls may be weak which permit dilatation causing incompetence of valves. Very rarely there may be congenital absence of valves.

Secondary

I. *Obstruction to venous outflow* — 1. Pregnancy, 2. Fibroid, 3. Ovarian cyst, 4. Pelvic cancer (of cervix, uterus, ovary or rectum), 5. Abdominal lymphadenopathy, 6. Ascites, 7. Iliac vein thrombosis, 8. Retroperitoneal fibrosis.

II. *Destruction of valve* — from deep vein thrombosis.

III. *High pressure flow* — from arteriovenous fistula.

VENOUS THROMBOSIS

It must be said in the beginning that deep vein thrombosis is mostly an asymptomatic disease. Only one fourth of the cases of deep vein thrombosis present with minor complaints. Various techniques have been introduced to detect asymptomatic deep vein thrombosis as they are dangerous and cause pulmonary embolism. Various preventive measures are also being practised all over the world to reduce the incidence of deep vein thrombosis. But these are beyond the scope of this book and only the symptoms and signs of deep vein thrombosis, though rare, will be discussed here.

HISTORY

The patient may complain of pain and swelling of the leg. There may be slight fever. If the patient has already had pulmonary embolism he may complain of chest pain, breathlessness and haemoptysis.

PHYSICAL EXAMINATION

INSPECTION.— Swelling of the leg is the most important feature which steals the show. The swelling is mainly found just around the ankle or little higher up. The swollen leg may become very much painful and is called **phlegmasia alba dolens.** When all the deep veins become blocked, the skin becomes congested and blue, which is called **phlegmasia cerulea dolens.**

PALPATION.— **Homan's sign.**— Passive forceful dorsiflexion of the foot with the knee extended will elicit tenderness in the calf. Gentle pressure directly on the calf muscles in the relaxed position will also elicit pain. Care must be taken to be gentle in manipulation lest it may dislodge a clot and cause pulmonary embolism.

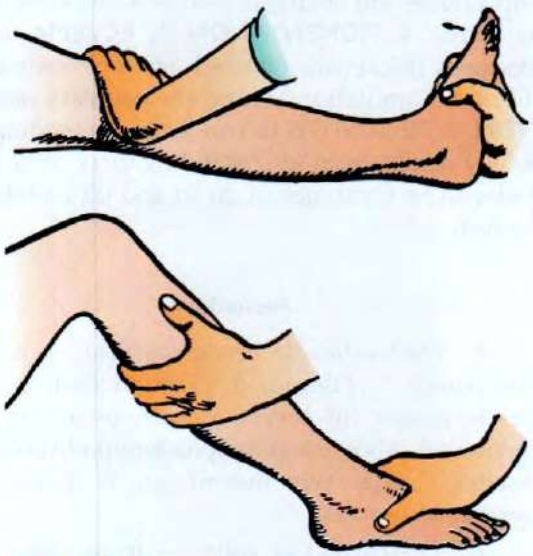

Figs.7.7 & 7.8.— Showing two methods of eliciting calf tenderness; (a) indirectly by forcible dorsiflexion of the foot (Homan's Sign) and (b) directly by squeezing the calf muscles from side to side (Moses' sign).

Squeezing of the relaxed calf muscles from side-to-side is also painful as the thrombosed deep veins in the calf are always tender and this test is known as ***Moses' sign.***

Direct palpation of the deep veins such as femoral or popliteal vein may become painful if they are thrombosed.

Measurements — often reveal swollen calf muscles.

TYPES OF VENOUS THROMBOSIS

Deep vein thrombosis (Phlebothrombosis).— This condition commonly occurs after operation under general anaesthesia, when the calf muscles remain idle and fail to maintain the normal flow of blood within the deep veins, thus causing thrombosis. It also occurs following child birth, immobility or any debilitating diseases. As has already been mentioned this condition is mostly asymptomatic. Only about 1/4th of cases produce symptoms and signs.

Pain and swelling of the calf or whole leg are the main symptoms. The onset of symptoms is often sudden. Sometimes it is severe enough to make walking difficult. If the patient has pulmonary embolism he may complain of breathlessness, haemoptysis and pleuritic pain.

Most important physical sign is *swelling of the leg.* This swelling may affect the thigh if the thrombosis is in the iliac vein or just around the ankle if the thrombosis is confined to the calf. The muscles which contain the thrombosed veins become *hard* and *tender.* Change in the texture of the muscle is more important than tenderness, as there are many conditions which make muscles tender, but there are very few conditions which make the muscle stiff and hard.

Forcible dorsiflexion of the foot which stretches the calf muscles will produce pain, which goes by the name of **'Homan's sign'** (Fig. 7.7).

With obstruction of veins the lower limb gets swollen and oedematous, which is called **phlegmasia alba dolens** or a 'white leg'.

When thrombosis of the veins obstruct outflow of blood from the limbs, the superficial veins dilate and the leg feels hot. With obstruction of all the main veins the skin becomes congested and blue, which is known as **phlegmasia cerulea dolens.** Later on arterial pulses may

temporarily disappear and venous gangrene may develop.

Superficial vein thrombosis (Thrombophlebitis).— This is an inflammatory condition and occurs after intravenous transfusion (commonest cause) or in varicose veins. Pain is the main feature. The patient may run temperature. The skin appears inflamed. The vein feels hard and tender. The resulting thrombus is firmly attached to the vein, so incidence of pulmonary embolism is very much less in comparison to phlebothrombosis. Spontaneous thrombophlebitis may sometimes be migratory (thrombophlebitis migrans), which may be associated with Buerger's disease, polycythaemia, polyarteritis and visceral carcinoma (bronchus, pancreas, stomach or lymphoma). Sometimes it may be idiopathic. It may also be iatrogenic (intravenous injection and injuries). Even if the patient has varicose veins, he should be thoroughly examined to exclude any occult cancer.

SPECIAL INVESTIGATIONS

If one relies solely on clinical findings there will be a failure to diagnose this condition in 50% of patients. A fatal pulmonary embolus may well be the first indication of thrombosis. To the contrary there may be extensive involvement of veins by the thrombotic process without clinical signs. In these cases destruction of venous valves with the sequelae of varicose veins, varicose eczema, ulceration and other trophic changes may result.

Radioactive fibrinogen test and ascending functional phlebography have gone a long distance to diagnose deep vein thrombosis in rather early stage.

Radioactive fibrinogen test.— At first ^{131}I-labelled fibrinogen was used. Subsequently ^{125}I-labelled fibrinogen was employed due to its softer radioaction and its detectability with much lighter and mobile apparatus. The thyroid gland is firstly blocked by sodium iodide (100 mg) given orally 24 hours before the intravenous injection of 100 microcuries of ^{125}I-labelled fibrinogen. The scintillation counter is first placed over the precordial region and the radioactivity over the heart is measured. The machine is adjusted so that this reading represents 100%. The legs are elevated on an adjustable stand to decrease venous pooling and to give access to the calf for the scintillation counter. Counting is performed along the lower extremity at two inches interval. Preoperative counting can be compared with the postoperative counting on the 1st, 3rd and 6th days after operation. An increase in the percentage value of 20 or more represents formation of thrombus in the deep veins of the legs.

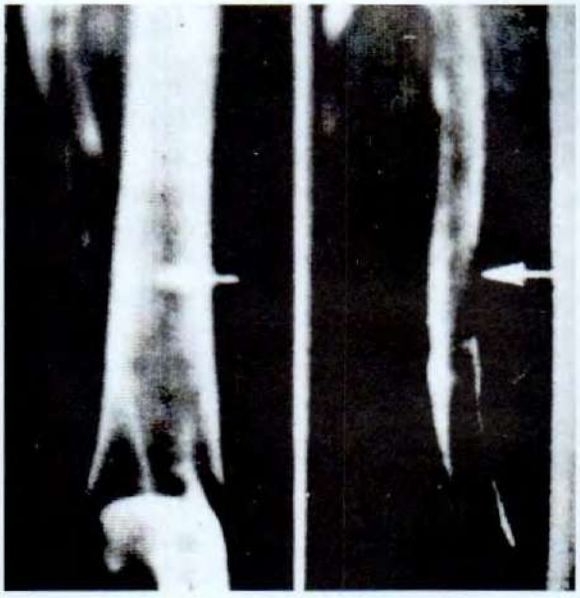

Fig.7.9.— Ascending functional phlebography showing deep venous thrombosis by arrow.

Phlebography.— The patient lies on a mobile table in horizontal position. 45% sodium diatrizoate is injected slowly into a vein on the dorsum of the great toe. A pneumatic cuff just above the ankle directs the contrast medium into the deep veins. Another cuff at the mid-thigh

position confines the contrast medium initially to the lower leg. The amount and rate of injection of the contrast medium is controlled by the filling of the veins as viewed on the television screen. The patient is asked to dorsiflex and plantarflex his foot thus propelling the contrast medium into the tibial veins. When the veins are filled films are taken of the leg in two planes. At the end of the procedure the contrast medium is washed off the leg veins by injecting 100 ml of normal saline containing heparin.

Ascending functional cinephlebography can be obtained by continuous observation of the flow of the contrast medium on the television screen as it progresses through the tibial veins. Function of the valves can be particularly noticed. Similarly the popliteal and femoral veins can also be assessed. The valvular function is considered to be normal when both the valve cusps are seen to open and close with onward flow of blood and no retrograde flow occurs even with the Valsalva manoeuvre.

Doppler Ultrasonogram.— The sensing probe is placed over the femoral vein in the groin. This normally transmits a venous hum. If the calf is squeezed or the calf muscles contract, it changes hum into a roar due to increased blood flow. If there is deep vein thrombosis (femoral or popliteal) between the calf and the groin, the roar does not occur.

Duplex Imaging.— This technique involves the use of B mode ultrasound and a coupled Doppler probe. It allows direct visualization of the deep veins. It provides anatomical and physiological variations. Though it is costly, it is replacing venography.

Ultrasound and CT Scan — should be performed when secondary varicose vein is suspected due to abdominal tumours.

Chapter

8 EXAMINATION OF THE LYMPHATIC SYSTEM

Lymphatic system includes lymph nodes and lymphatics. At first clinical features of the diseases of the lymph nodes will be described followed by diseases of the lymphatics.

HISTORY

The following points are particularly noted while taking the history of the patient.

1. **Age.**— Tuberculous lymphadenopathy and syphilis are diseases of the young age. Acute lymphadenitis can occur at any age. Primary malignant lymphomas occur at young age, though secondary malignant lymphadenopathy occurs in old age.

2. **Duration.**— In acute lymphadenitis the history is short, whereas it is long in chronic lymphadenitis, tuberculosis etc.

3. **Which group was first affected?.**— In case of generalized involvement of the lymph nodes, the clinician should know which group of lymph nodes was first affected. This may give a clue to the diagnosis. Cervical group of lymph nodes is first affected in many cases of Hodgkin's disease, tuberculosis, etc.; to the contrary inguinal group of lymph nodes is first affected in filariasis, lymphogranuloma inguinale etc. But too much stress should not be laid on this point.

4. **Pain.**— Is the involvement of the lymph nodes painful? The nodes are painful in both acute and chronic lymphadenitis, but are painless in syphilis, primary malignant lymphomas and secondary carcinoma.

5. **Fever.**— Evening rise in temperature is a characteristic feature of tuberculosis. In filaria a periodic fever (especially during the full or new moon) is very common. In Hodgkin's disease, intermittent bouts of remittent fever (Pel-Ebstain fever) is quite peculiar to this disease.

6. **Primary focus.**— Whenever the lymph nodes are enlarged, it is the usual practice to look for the primary focus in the drainage area of the lymph nodes. This should be done particularly in acute and chronic septic lymphadenitis. An insignificant abrasion or inflammation in the drainage area may lead to lymphadenitis.

7. **Loss of appetite and weight.**— This is often complained of in case of malignant lymphadenopathies.

8. **Pressure effects.**— Patient may complain of pressure effects due to enlarged lymph nodes. Patient may complain of swelling of face and neck due to venous and lymphatic obstruction by the enlarged superior mediastinal group of lymph nodes or lymph nodes at the root of the neck. Enlarged retroperitoneal lymph nodes and para-aortic lymph nodes in Hodgkin's disease may cause oedema and venous congestion of lower limbs. Dyspnoea may be complained of in case of enlargement of mediastinal group of lymph nodes due to pressure on trachea or bronchus. Dysphagia may be complained of when oesophagus is pressured.

9. **Past History.**— This should be particularly enquired into in syphilis, tuberculosis, secondary carcinoma etc. Enlargement of epitrochlear and suboccipital groups of lymph nodes

may elude the clinician if he does not ask the past history of primary syphilis; as these lymph nodes may be enlarged in the secondary stage of syphilis. Similarly a patient who presents with enlarged cervical group of lymph nodes may give a past history of tuberculosis and the diagnosis becomes easy without thorough clinical examination and costly special investigations. Sometimes a patient with penile cancer may present with lump in the abdomen, which is nothing but enlarged iliac group of lymph nodes. A patient with enlarged cervical lymph nodes may give history of previous lung tuberculosis if specifically asked for.

10. **Family History.**— Sometimes tuberculosis runs in families and should be asked for. Lymphosarcoma and other types of lymphomas have also shown a tendency to run in families.

PHYSICAL EXAMINATION

GENERAL SURVEY

Malnutrition, cachexia, anaemia and loss of weight are often seen in cases of tuberculous lymphadenitis, primary and secondary malignant lymphadenopathies.

LOCAL EXAMINATION

A. **INSPECTION.**— *Swellings at the known sites of the lymph nodes should be considered to have arisen from them* unless some outstanding clinical findings prove their origin to be otherwise.

Swellings.— The swellings are examined in the same fashion as has been described in chapter 3 under "Examination of a lump or a swelling". That means the *number, position, size, surface,*



Fig.8.1.— Cervical lymph node swelling in tuberculosis.

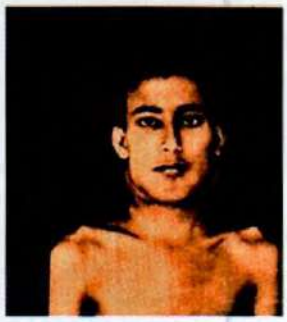

Fig.8.2.— Cervical lymph node swelling on both sides in Hodgkin's disease.

etc. are noted. Of these the *position* is important, as it will not only give an idea as to which group of lymph nodes is affected, but also the diagnosis e.g. Hodgkin's disease and tuberculosis affect the cervical group of lymph nodes in the beginning; filariasis and lymphogranuloma inguinale affect the inguinal group of lymph nodes; secondary stage of syphilis involves the epitrochlear and occipital groups. *Number* is important — whether single or multiple groups are involved. A few

conditions are known to produce generalized involvement of lymph nodes. These are Hodgkin's disease, tuberculosis, lymphosarcoma, lymphatic leukaemia, brucellosis sarcoidosis etc.

Skin over the swelling.— In acute lymphadenitis the skin becomes inflamed with redness, oedema and brawny induration. In chronic lymphadenitis the skin over the swelling does not show such angriness. Skin over tuberculous lymphadenitis and cold abscess remains 'cold' in the true sense till they reach the point of bursting when the skin becomes red and glossy. Over a rapidly growing lymphosarcoma the skin becomes tense, shining, with dilated subcutaneous veins. In secondary carcinoma, though the skin remains free in the early stage, yet it becomes fixed to the swelling at later stage when the disease has gone beyond the scope of surgery. Not infrequently a scar, a sinus or an ulcer may be present by the side of or over the swelling. Scar often indicates previous bursting of cold abscess or a previous operation. So far as an ulcer or a sinus is concerned, the students are advised to examine them as described in chapter 4 & 5 respectively. Ulceration and sinus formation are not infrequent in lymphogranuloma inguinale.



Fig.8.3.— Shows fungating inguinal lymph nodes from carcinoma of the penis. If the femoral vessels are involved by such lymph nodes fatal haemorrhage may result.

Pressure effects.— Careful inspection must be made of the whole body to detect any pressure effect due to enlargement of lymph nodes. Oedema and swelling of the upper limb and lower limb may occur due to enlargement of axillary and inguinal groups of lymph nodes respectively. Swelling and venous engorgement of face and neck may occur due to pressure effect of lymph nodes at the root of the neck. Nearby nerves may be involved due to enlarged lymph nodes e.g. hypoglossal nerve may be involved from enlarged upper group of cervical lymph nodes due to Hodgkin's disease or secondary carcinoma. Dyspnoea and dysphagia may be complained of due to pressure on the trachea and oesophagus respectively.

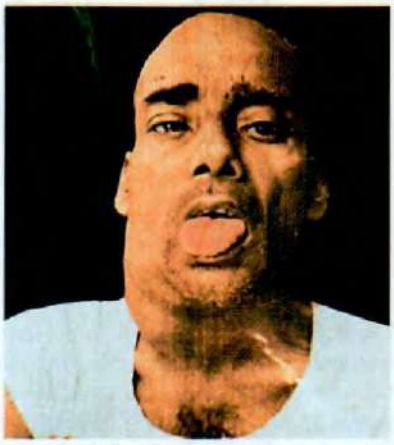

Fig.8.4.— Secondary carcinoma of the upper deep cervical lymph nodes on the right side has involved the hypoglossal nerve resulting in hemi-paralysis of the right side of the tongue. This is evident by the fact that when the tongue is protruded out the tip of the tongue is deviated towards the side of lesion.

B. **PALPATION.**— The swelling is palpated as discussed in Chapter 3 noting particularly, (i) the number, (ii) the situation, (iii) local temperature, (iv) tenderness, (v) surface, (vi) margin.

(vii) CONSISTENCY.— Enlarged lymph nodes should be carefully palpated with palmar aspects of the 3 fingers. While rolling the fingers against the swelling slight pressure is maintained to know the actual consistency of the swelling. *It must be remembered that normal lymph nodes without enlargement are not palpable.* Enlarged lymph nodes may be soft (fluctuating) or elastic and rubbery (Hodgkin's disease) or firm, discrete and shotty (syphilis) or stony hard (secondary carcinoma) or variable consistency — soft, firm and hard in places depending on the rate of the growth (lymphosarcoma).

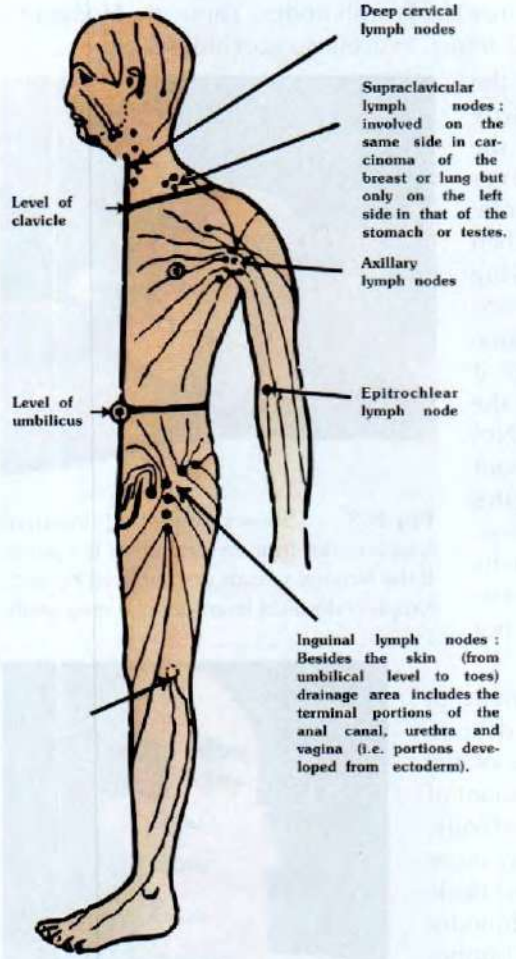

Fig.8.5.— Diagrammatic representation of the lymphatic drainage of the skin. The whole body has been broadly divided into three areas by two horizontal lines — one at the level of the clavicle and the other at the level of the umbilicus.

(viii) Whether the nodes are MATTED OR NOT?.— If there be periadenitis, the adjoining nodes become matted. This can be diagnosed by careful palpation unless they are very painful. Lymph nodes are often matted in case of tuberculosis, acute lymphadenitis and metastatic carcinoma.



Fig.8.6.— Shows involvement of the cervical, axillary and inguinal lymph nodes in Hodgkin's disease.

(ix) FIXITY TO SURROUNDING STRUCTURES.— The enlarged lymph nodes should be carefully palpated to know if they are fixed to the skin, the deep fascia, the muscles, the vessels, the nerve etc. Any primary malignant growth of the lymph nodes be it lymphosarcoma, reticulosarcoma, histiosarcoma or secondary carcinoma is often fixed to the surrounding structures — first with the deep fascia and underlying muscles followed by adjoining structures and ultimately the







Figs.8.7. to 8.9.— Shows involvement of the axillary and inguinal lymph nodes besides the cervical group in Hodgkin's disease. In Fig.8.9 the spleen is being palpated for enlargement. This should be the routine practice in all cases of lymph node enlargement.

overlying skin if remain untreated. In many cases of carcinoma of the penis the secondarily involved inguinal group of lymph nodes infiltrates the femoral vessels and causes fatal haemorrhage. Upper deep cervical lymph nodes when involved secondarily from any carcinoma of its drainage area may involve the hypoglossal nerve and cause hemiparesis of the tongue which will be deviated towards the side of lesion when asked to protrude it out. Cases are not unknown when the patient complains of dyspnoea or dysphagia due to pressure on the trachea or bronchus or oesophagus by enlarged lymph nodes from Hodgkin's disease or lymphosarcoma or secondary carcinoma.



Fig.8.10.— One should also palpate the liver in case of enlargement of lymph nodes since liver is also involved in Hodgkin's disease.

Drainage area.— Whenever a patient comes with enlarged lymph nodes it should be the routine practice to examine its drainage area. This is particularly important in inflammatory and neoplastic lesion (carcinoma or malignant melanoma) of the lymph nodes. *The lymphatic drainage of the body may be discussed in the following way* (see Fig. 8.5) :—

The cervical lymph nodes receive the lymphatics from the head, face, mouth, pharynx and neck, the left supra-clavicular lymph node (Virchow's) receives lymphatics from left upper limb, left side of the chest including the breasts and also the viscera of the abdomen including both the testes.

The axillary group of lymph nodes drains the upper limb of that side and the trunk which extends from the clavicle to the level of the umbilicus (including the breasts).

The inguinal lymph node drains the whole of the lower limb, the skin of the lower part of the abdomen below the level of the umbilicus, the penis, scrotum, perineum, vulva, anus, buttock, lower part of the back including the terminal parts of the anal canal, urethra and vagina (the portions which are developed from the ectoderm). That means the drainage area of the inguinal lymph nodes extends from the level of the umbilicus down to the toes.

GENERAL EXAMINATION

1. **Lymph nodes in other parts of the body** — should always be examined in any case of lymph node involvement. Not infrequently this examination reveals many cases of hidden generalized involvement of lymphatic system, e.g. Hodgkin's disease, lymphosarcoma, lymphatic leukaemia, tuberculosis, brucellosis, sarcoidosis etc.
2. **Always examine (a) spleen, (b) liver, (c) mesenteric** and **iliac lymph nodes** (Hodgkin's disease).
3. **Examine the lungs for tuberculosis and secondary metastasis.**
4. **Syphilitic stigmas** — in syphilis (see Fig.4.15).
5. **Parotid and lacrimal glands** — in sarcoidosis.

THE LYMPHATICS

Besides acute and chronic lymphangitis, lymphoedema constitutes the major disease of the lymphatics.



Fig.8.11.— Lymphoedema of the arm following radical mastectomy.

Lymphoedema — is caused by accumulation of lymph within the tissues. It mainly affects the subcutaneous tissues of the limbs. This is due to stagnation of lymph within the lymphatics. The causes may be classified into A. Congenital malformation (primary lymphoedema) and B. Acquired obstruction (secondary lymphoedema).

HISTORY

1. **Age.**— Primary lymphoedema may reveal itself in young age, whereas secondary lymphoedema mostly presents in middle and old ages.
2. **Sex.**— Somehow or other females are more affected than males so far as primary lymphoedema is concerned. Even secondary lymphoedema is more common in women following radical mastectomy or due to involvement of the iliac and inguinal nodes from malignant tumours of the uterus or ovary.
3. **Distribution.**— Lymphoedema following filariasis is more common in tropical countries and Orissa seems to be the most affected state in India.
4. **Complaints.**— Not many complaints are associated with this disease particularly the primary lymphoedema. This is slowly progressive swelling of the limb and the genitalia which takes even years to develop.

To the contrary secondary lymphoedema is often associated with some sort of complaints such as complaints of malignant growth, filariasis etc. It often follows operation like extirpation of lymph nodes, e.g. radical mastectomy.

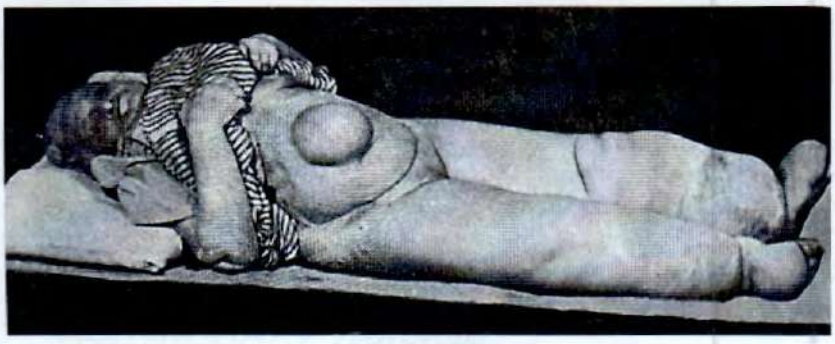

Fig.8.12.— Huge elephantiasis of both the legs.

LOCAL EXAMINATION

One should look for prominent lymphatic vessels as red streaks progressing towards the regional lymph nodes. There may be brawny oedema around. This is characteristic of acute lymphangitis. There may be subcutaneous nodules along the lymphatics as in case of malignant melanoma and carcinoma. In case of malignant melanoma these nodules are often of deep brown to black colour.

In the early stage this oedema pits on pressure, but gradually the subcutaneous tissue becomes fibrosed and the skin becomes keratotic (Elephantiasis). In case of secondary lymphoedema examination must include regional lymph nodes and general examination to find out the diagnosis.

SPECIAL INVESTIGATIONS

1. **Blood.**— Routine examination of blood is essential for (a) leucocytosis particularly polymorphs (acute lymphadenitis); (b) lymphocytosis (tuberculosis, lymphatic leukaemia etc.); (c) Eosinophilia is often seen in case of filariasis; (d) raised E.S.R. (tuberculosis, secondary carcinoma and primary malignant lymphadenopathy); (e) W.R. and Kahn test (syphilis); (f) Microfilaria in the peripheral blood vessels when the patient is sleeping (Filariasis). Complement fixation test should be performed for lymphogranuloma inguinale and syphilis.

2. **Aspiration** — of the abscess is essential for diagnosis be it a cold abscess or lymphogranuloma inguinale. In cold abscess one will look for acid-fast bacilli. In lymphogranuloma inguinale, pus from unruptured bubo is diluted ten times with normal saline and sterilized at 60° centrigrade, 0.1 ml of the solution is injected intradermally. Appearance of a reddish papule within 48 hours at the site of injection indicates the test to be positive. This test is known as Frei's intradermal test, which is specific for lymphogranuloma inguinale.

3. **Mantoux test and guineapig inoculation test** — are specific for tuberculosis.

4. **Gordon's biological test** — is specific for Hodgkin's disease. An emulsion of the affected lymph nodes is injected into a rabbit intracerebrally. This will initiate encephalitis within a few days.

5. **Biopsy.**— This is probably the most important special investigation in this concern. Many cases may not be diagnosed clinically and with the help of the above special investigations. Biopsy should be called for in these cases. Under local and general anaesthesia according to the circumstances, the isolated or matted lymph nodes are excised and examined both macroscopically and microscopically.

In TUBERCULOSIS, the lymph nodes on section show translucent, greyish patches in the early stage. As the disease advances these become opaque and yellowish, which is the result of necrosis and caseation. Microscopically the tubercles will be found which consist of the epitheloid cells and giant cells having peripherally arranged nuclei in the early stage. After one week, lymphocytes with darkly stained nuclei and scanty cytoplasm make their appearance. By the end of the second week caseation appears in the centre of the tubercle follicle. So in the centre of the tubercle follicle lies eosin stained caseation surrounded by giant cells and epitheloid cells around which remains a zone of chronic inflammatory cells e.g. lymphocyte and plasma cells, around which are the fibroblasts.



Fig.8.13.— Lymphangiography.

In HODGKIN'S DISEASE, the lymph nodes are firm and elastic and on section have a uniform grey translucent and moist appearance. Occasionally yellow patches of necrosis may brake the homogeneity. Microscopically its most important feature is cellular pleomorphism. There are lymphocytes, lymphoblasts and large mononuclear and multinucleated cells known as Reed-Sternberg cells which are the hallmark and pathologists always look for them to confirm the diagnosis. When the nucleus is single, it may be convoluted or ring shaped. In case of multinucleated forms generally there are two centrally placed nuclei, one of which is the mirror image of the other. Besides these giant cells there are also polymorphonuclears, eosinophils

and plasma cells to add to pleomorphism. There are also reticular elements shown by silver staining.

In **LYMPHOSARCOMA**, the cut surface of the lymph node is greyish white and bulging. Microscopically the normal structure of lymph node disappears and is replaced by diffuse arrangement of monotonously uniform large lymphoblast with hyperchromatic nucleus and scanty cytoplasm. The characteristic feature is that there is no increase of silver staining reticulum.

In **RETICULUM-CELL SARCOMA** — the microscopic picture shows abundance of reticulum cells with faintly acidophilic cytoplasm. The nucleus is double the size of lymphocytes and is commonly infolded to give a reniform appearance. Sometimes pseudopod-like processes may be seen in both the nuclei and the cytoplasms. Moreover the characteristic feature is the well distribution of silver staining reticulum, which has got intimate relation to the tumour cells.

In **SECONDARY CARCINOMA**, the tumour cells reach the nodes through the lymphatics by two methods — permeation or embolism. The carcinomatous cells first enter the peripheral lymph sinuses, gradually permeate the sinuses between the follicles and cords and finally destroy the normal architecture of the nodes. The microscopical structure of the secondary carcinoma very much resembles that of the primary one — whether epidermoid, adenocarcinoma, anaplastic etc. Indeed more often the secondary growth is more typical and characteristic than the primary one.

6. **Radiological examination.**— In case of enlarged cervical lymph nodes, X-ray of the chest is essential, not only to find out enlargement of the mediastinal lymph nodes, but also to detect pulmonary tuberculosis or bronchogenic carcinoma as the cause of enlargement of cervical lymph nodes. Calcified tuberculous lymph nodes may easily be seen in X-ray film. But *tomography* will be essential to know particularly about the mediastinal lymph nodes.

7. **Lymphangiography.**— This test is of immense value in finding out the causes of lymphoedema, lymph node enlargement and sites of lymph node metastasis in various carcinoma (particularly malignancy of the testis) and malignant melanoma.

Injection of patent blue dye into the web between the toes will show lymphatics on the dorsum of the foot. One of these lymphatics is cannulated and ultrafluid lipiodol (Radio-opaque dye) is injected to visualize on X-ray the main lymphatic channels of the leg and subsequently the lymph nodes. Irregular filling defect in the lymph node means secondary metastasis. Soap bubble or foamy appearance is seen in Hodgkin's disease. Coarse nodular storage pattern is seen in lymphosarcoma and marginal sunburst appearance is the feature found in reticulum cell sarcoma.

In malignant melanoma, sometimes radio-active phosphorus is added to the radio-opaque dye for lymphangiography. This will destroy the malignant cells in the lymph nodes. This process is called *'endolymphatic therapy'*.

Lymphadenography.— Radio-opaque dye is injected directly into the lymph nodes either in vivo or during operation. After a few hours X-rays are taken to delineate the lymph nodes. The various pathologies involving the lymph nodes are more clearly seen by this technique as mentioned above.

8. **CT Scan.**— In case of abdominal and mediastinal lymph nodes enlargements, this investigation is extremely helpful.

9. **Mediastinal-scanning** — with Gallium 67 is sometimes performed to know whether the mediastinal lymph nodes are involved or not.

10. **Laparotomy.**— This seems to be the last court of appeal in Hodgkin's disease. This is required not only to know the clinical staging of the disease by wedge biopsy of the liver and by biopsy of the aortic, mesenteric and iliac nodes and a small chip biopsy from iliac bone but

also as treatment by splenectomy as the spleen is involved in about 90% of cases of the abdominally involved Hodgkin's disease and to obviate splenic irradiation due to its complications.

CAUSES OF ENLARGEMENT OF LYMPH NODES

A. **INFLAMMATORY.—**

(a) ACUTE LYMPHADENITIS.

(b) CHRONIC LYMPHADENITIS.

(c) GRANULOMATOUS LYMPHADENITIS — the aetiologic agents may be bacterial, viral or fungal. From BACTERIAL origin are tuberculosis, syphilis, tularaemia, brucellosis etc.; From VIRAL origin are lymphogranuloma venereum, cat-scratch disease, infectious mononucleosis; From PARASITOLOGICAL origin is filariasis due to infestation of Wuchereria Bancrofti and toxoplasmosis; From FUNGAL origin are blastomycosis, histoplasmosis and coccidioidomycosis (not actinomycosis, as lymph node enlargement is unusual in this disease). In this group may be added condition like sarcoidosis, whose aetiology is still controversial.

B. **NEOPLASTIC.—**

(a) BENIGN — almost non-existent.

(b) MALIGNANT —

1. *Primary.—*

OLD CLASSIFICATION.—

(i) Giant follicle lymphoma;

(ii) Lymphosarcoma;

(iii) Reticulum cell sarcoma;

(iv) Hodgkin's disease.

NEW CLASSIFICATION.— The classification, which is currently used, is based on the classification of Rappaport et al or Lukes et al. It is as follows :

Primary malignant lymphomas can be broadly classified into two groups — (i) Diffuse lymphomas (56%) and (ii) Nodular lymphomas (44%). The latter type is more prevalent in females but is distinctly rare in children and blacks. But these two groups are actually types of proliferation that any of the malignant lymphomas can exhibit at some points of their evolution. The natural history of the disease is primarily related to the cell type in which a nodular pattern indicates a slower evolution and a better prognosis than a diffuse one. It is also interesting to note that most nodular lymphomas change later to a diffuse pattern but maintaining the same cell composition.

The classification based on cell types are :

(i) Malignant lymphoma, undifferentiated type;

(ii) Malignant lymphoma, histiocytic type;

(iii) Malignant lymphoma, lymphocytic type (poorly differentiated);

(iv) Malignant lymphoma, lymphocytic type (well-differentiated);

(v) Malignant lymphoma, mixed type (histiocytic-lymphocytic);

(vi) Malignant lymphoma, Hodgkin's type — (a) lymphocytic predominance; (b) nodular sclerosis; (c) mixed cellularity; (d) lymphocytic depletion.

2. *Secondary.—*

Metastatic lymph node enlargement is often seen from Carcinoma, Malignant Melanoma or rarely from Sarcoma of the draining region.

C. **LYMPHATIC LEUKAEMIA.**

D. **AUTOIMMUNE DISORDERS.—**

(i) Juvenile rheumatoid arthritis (Still's disease).

(ii) Other Collagen diseases such as Systemic lupus erythematosus, Polyarteritis nodosa and scleroderma.

Causes of generalized lymph nodes enlargement.—

1. Tuberculosis;
2. Syphilis — secondary stage;
3. Infectious mononucleosis;
4. Sarcoidosis;
5. Brucellosis;
6. Toxoplasmosis;
7. Hodgkin's disease;
8. Lymphosarcoma;
9. Lymphatic leukaemia.

DIFFERENTIAL DIAGNOSIS

Acute lymphadenitis.— The nodes become enlarged and painful. The overlying skin becomes warm, red and brawny oedematous. On palpation the nodes are extremely tender. This condition may subside with the primary focus or end in suppuration when fluctuation can be elicited in the centre and pitting on pressure at the periphery. Finding of primary infective focus in the drainage area confirms the diagnosis.

Chronic non-specific (pyogenic) lymphadenitis.— Clinically it is often impossible to differentiate this condition from tuberculous lymphadenitis in its early stage. The nodes become moderately enlarged, slightly tender and elastic with or without matting. A history of acute lymphadenitis can be obtained which gradually attains chronicity. In the cervical group oral sepsis and lesions of the scalp are usually the common causes. In the groin, besides infected cuts and ulcers, walking on bare and cracked feet may lead to this condition amongst labourers.

Hyperplasia.— Lymph nodes may respond to infection by enlarging. In various carcinomas the regional lymph nodes may be enlarged, due to inflammation rather than from spread of carcinoma. By palpation it is very difficult to know if the enlarged lymph nodes contain any malignant cells or not. Microscopically the hyperplasia may be primarily located in the reactive centres, in the intervening lymphoid tissue or within the sinuses.

Tuberculous lymphadenitis.— This is commonly found in children and young adults. The cervical lymph nodes are most frequently involved followed by mediastinal, mesenteric, axillary and inguinal groups according to the order of frequency. *Clinically three stages are discernible.* In the *first stage* the nodes become simply enlarged without matting. This is known as lymphadenoid type and differentiation from chronic septic lymphadenitis becomes difficult. In the *second stage* due to the advent of periadenitis the enlarged nodes become adherent to one another (matted). This is the most characteristic feature of tuberculous lymph nodes. Later on caseation takes place in the interior of the nodes so that the nodes become softer with gradual formation of cold abscess. This is the *third stage.* Gradually the cold abscess makes its way towards the surface and ultimately bursts forming a typical tubercular ulcer or a sinus which refuses to heal.

Syphilitic lymphadenitis.— *In the primary stage* the lymph nodes in the groin become enlarged along with presence of genital chancres. The nodes are painless, discrete, firm and shotty. These nodes do not show any tendency towards suppuration. In extra-genital chancres occurring in the lips, breasts etc. the nodes may become inflamed, painful and matted. *In the secondary stage*

generalized involvement of nodes may occur affecting particularly the epitrochlear and occipital groups. The characteristics are similar to those found in the primary stage. *In the tertiary stage* the lymph nodes are seldom involved. Other syphilitic stigmas (see Fig.4.15), positive W.R. and Kahn tests along with presence of Treponema pallidum in dark ground illumination from the primary lesion confirm the diagnosis.

Filarial lymphadenitis.— The inguinal nodes are commonly affected and this condition is more often found in males. The lymph nodes become enlarged and tender. A history of periodic fever with pain (especially during the full or new moon) is very characteristic. Swelling of the spermatic cord with dilatation of lymphatic vessels (lymphangiectasis) is often found in filariasis. There may be thickening of the skin of the scrotum. Microfilaria can be demonstrated in the blood drawn at night. Eosinophilia is the rule. Biopsy of lymph nodes may reveal adult filaria within them.



Fig.8.14.— Filarial lymphadenitis.

Lymphogranuloma inguinale.— It is a type of venereal disease caused by a filtrable virus of the psittacosis-lymphogranuloma inguinale group which is transmitted through sexual intercourse. The primary lesion is often insignificant but the secondary lesion with enlarged lymph nodes in the medial part of one or both the groins is the presenting feature. The iliac lymph nodes may also be involved. Soon periadenitis occurs and the mass becomes brawny. Gradually the nodes suppurate and may break down to discharge thick yellowish-white pus. The resulting sinus persists for quite a long time. Biopsy, Frei's test and complement fixation test are confirmatory.

Cat-scratch disease.— This is due to a virus of lymphogranulomapsittacosis group. This disease is characterized by fever, toxaemia and malaise from localized inflammation around the lesion. The regional lymph nodes are enlarged and suppuration often occurs in due course.

Infectious Mononucleosis (Glandular fever).— This causes generalized enlargement of lymph nodes which are firm, elastic and slightly tender. It is associated with sore throat, rash, splenic enlargement and irregular fever. Lymphocytosis and positive Paul Bunnell test help in the diagnosis.

Sarcoidosis.— This may be due to tissue reaction against antigen or tubercle like bacillus. Parotid and lacrimal glands enlargement, skin lesion like papule and nodule, bone cyst, hypercalcaemia and above all generalized enlargement of lymph nodes are features of this disease. Kveim's test — a nodule develops within a month of intradermal injection of sarcoid tissue, is very much confirmatory.

NON-HODGKIN'S LYMPHOMAS.—

1. **Undifferentiated lymphomas.**— This is a malignant proliferation of primitive cells having scanty cytoplasm and a round or oval nucleus with delicate chromatin. Burkitt's lymphoma is regarded as specific variant of this type of lymphoma. It has a peculiar geographic distribution, mostly seen in tropical Africa and New Guinea. Typically Burkitt's lymphoma affects children and young adults. It has a great tendency for extra-nodal involvement such as the jaws, ovaries, abdominal organ, retroperitoneum and the central nervous system. Untreated cases follow a rapid fatal course.

2. **Histiocytic lymphoma.**— Lymph nodes involved by the histiocytic lymphoma (reticulum cell sarcoma) may be matted together and contain large necrotic areas. The lesion is composed

of large cells with round to oval, sometimes pleomorphic vesicular nuclei and containing prominent nucleoli. Fibrosis with hialinization of the stroma is sometimes prominent separating the tumour cells in clusters or cords.

3. **Lymphocytic lymphoma.**— The individual nodes are not adherent. They appear highly cellular and occasionally contain areas of necrosis. *In poorly differentiated variant the* cells are large than matured lymphocytes but smaller than histiocytes. The nuclei are round, oval and irregular with focal chromatin clumping and a distinct nucleolus. Nuclear indentations are often present. *In well-differentiated lymphocytic lymphoma* the cells are similar to normal mature lymphocytes. It is very difficult to differentiate this type of lymphoma from chronic lymphocytic leukaemia. The clinical history, the peripheral blood count and the bone marrow findings are required to make such distinction.

4. **Mixed lymphoma.**— This designation should be restricted to tumours in which both histiocytes and lymphocytes are present in significant amounts. A nodular pattern of growth is common in the early stage, but majority however develop into a diffuse lymphoma of histiocytic type.

Clinically one should be particular to stage the lymphomas. Stages I lesions have a good prognosis, but unfortunately they comprise only 1/3rd of all the cases. Routine use of lymphangiography has demonstrated that most patients with non-Hodgkin's malignant lymphoma have wide spread disease at the time of diagnosis. In a series about 40% were in stage IV at the time of diagnosis. Malignant lymphoma involving a high cervical lymph node is the one most likely to be localized. Spread by involvement of contiguous lymph node groups is found in majority of the cases of non-Hodgkin's lymphoma. In regard to the cell type the average survival is longer for the well-differentiated lymphocytic type, intermediate for the poorly lymphocytic type and shorter for the histiocytic variety. Involvement of mesenteric lymph nodes is exceptional in Hodgkin's disease, but quite common in other types of lymphoma. Among extranodal involvement the bone marrow and the spleen are the common sites.

HODGKIN'S DISEASE.— The onset of this disease is about a decade earlier than lymphosarcoma and reticulosarcoma but it is not uncommon in young children. The symptoms are more local than constitutional except in acute cases. The most common presentation is painless and progressive enlargement of the lymph nodes, first detected in the cervical group on one side and then on the other. It may be that the deeper lymph nodes such as the mediastinal and mesenteric groups may have been involved earlier. The associated symptoms such as malaise, weight loss and fever are quite characteristic. Recurrent bouts of remittent fever is quite characteristic of this disease. Pressure effects by enlarged mediastinal lymph nodes such as venous engorgement, cyanosis of the head and neck and difficulty in respiration due to pressure on the bronchus are sometimes the presenting features. Bone pain with vertebral collapse secondary to bony metastasis, though rare, should be kept in mind. Root-pain, and even paraplegia may develop due to pressure on the spinal cord from deposits in the vertebrae or pressure by retroperitoneal nodes on the nerve roots while they come out of the intervertebral foramina. A peculiar feature of this disease is the complaint of enhanced pain at the sites of disease induced by drinking alcohol.

On examination, the lymph nodes are elastic and rubbery to feel. The nodes tend to remain discrete moveable with little tendency towards matting and softening. Splenic enlargement is a significant finding of this disease and is found in not less than 75% of the cases. Hepatomegaly is found in about 50% of the cases. Progressive anaemia is more or less constant and may be due to splenomegaly or bony metastases. Occasionally eosinophilia is associated with megakaryocytosis and increased platelet count. Sometimes jaundice is seen due to excessive

haemolysis of red cells or involvement of liver. The course of the disease varies with the pathological type of the disease. Death may occur within a few weeks or the patient may survive longer without any treatment. The special investigations have already been discussed.

CLINICAL STAGING OF THE HODGKIN'S DISEASE : *Stage I* — Involvement of a single lymph node region or involvement of a single extralymphatic organ or site (IE).

Stage II.— Involvement of two or more lymph node regions on the same side of the diaphragm alone or with involvement of limited contiguous extralymphatic organ or tissue (IIE).

Stage III.— Involvement of lymph node regions on both sides of the diaphragm, which may include the spleen (III S) and/or limited contiguous extralymphatic organ or site (III E, III ES).

Stage IV.— Multiple or disseminated foci of involvement of one or more extralymphatic organs or tissues with or without lymphatic involvement.

All stages are further subdivided on the basis of absence (A) or presence (B) of the following systemic symptoms e.g. fever, weight loss more than 10%, bone pain etc.

PATHOLOGICALLY Hodgkin's disease can be divided into four categories, which is important so far as the prognosis of the disease is concerned. The more numerous are the lymphocytes, the more favourable is the prognosis.

Type 1.— Lymphocyte-predominant Hodgkin's disease.

Type 2.— Mixed-cellularity — a diffuse infiltrate of lymphocyte, histiocytes, eosinophil and plasma cells that obliterate the normal architecture.

Type 3.— Nodular sclerosis is often seen in clinical stage I and is associated with better prognosis.

Type 4.— Lymphocytes depletion pattern — the most ominous form.

Secondary Carcinoma.— The nodes become enlarged, irregular and fixed to all the surrounding structures (including the skin) which are gradually pulled towards the mass. The most important characteristic feature is their stony hard consistency. Although painless to start with, continuous pain of varying severity will appear as the growth increases. Fungation into the skin occurs in neglected cases. Discovery of the primary growth confirms the diagnosis.



Fig.8.15.— Disseminated metastases in the lymph vessels from malignant melanoma of the foot.

Malignant Melanoma.— Affection is always secondary. The involved nodes grow much more rapidly and are less hard than those due to secondary carcinoma. When they break out or are divided after removal, black pigmentation becomes evident.

Lymphatic Leukaemia.— This is characterized by a generalized involvement of lymph nodes with enlargement of the spleen. The most important diagnostic feature is marked increase in the number of lymphocytes and their precursors in the blood.

Chapter

9 EXAMINATION OF PERIPHERAL NERVE LESIONS

History of present illness.— History of trauma is usually associated with peripheral nerve lesion. Besides trauma, there is only other way of involvement of a peripheral nerve, and that is by infiltration of the nerve by malignant growth. The types of trauma which may injure a peripheral nerve may be a wound — either an incisional cut (e.g. by a broken glass) or a penetrating wound (e.g. a stab or a gun shot wound), or a fracture and /or dislocation, in which case the nerve is injured by the fractured segment or the dislocated bone rather than the trauma directly. Incisional wound or the penetrating wound may injure the nerve anywhere in the body but commonly seen at the wrist when the median or the ulnar nerve becomes the victim. Injury to the nerve caused by fracture or dislocation is commonly seen in the arm when the radial nerve is injured by the fractured shaft of the humerus, at the elbow in the supracondylar fracture of humerus when the median, the ulnar or the radial nerve may be injured. In fracture of the medial epicondyle the ulnar nerve is usually affected. In both the supracondylar fracture and the fracture of the medial epicondyle, there may be late paralysis of the ulnar nerve which is known as 'tardy ulnar palsy' — due to involvement of the nerve in callus formation. In fracture of the neck of fibula, the lateral popliteal nerve is often injured. In subcoracoid dislocation of the humerus and fracture of the neck of the humerus, the axillary nerve may be injured leading to paralysis of the deltoid. In posterior dislocation of the hip, subtrochanteric fracture and supra-condylar fracture of the femur, the sciatic nerve may be injured. The most peculiar feature is that generally the common peroneal portion of the sciatic nerve is involved.

Lesion of the brachial plexus, though rare, is yet interesting anatomically. *The upper lesion* (Erb-Duchenne) is caused by the injury which causes forcible increase of the angle between the neck and shoulder thus stretching upper trunk of the brachial plexus. This type of injury may occur during difficult labour when a pull on the head of the foetus is made while the shoulder is arrested inside or due to fall of a load on the shoulder. *The lower lesion* (Klumpke) of a brachial plexus may occur when the arm is being forcibly hyperabducted. This can occur when a falling person tries to catch an object. This will stretch the lower trunk of the brachial plexus.

Sometimes the patient complains of a constant intense burning pain after an injury even after the wound has healed. This is called *causalgia* and is caused by partial nerve injury. This type of pain may commence immediately following the injury or more often after a month or so when the skin wound has healed.

Past history.— Sometimes patients may present with peripheral nerve lesion without a history of trauma. The patient indicates the lesion to be spontaneous. In these cases, an enquiry must be made whether an injection has been made in the arm or in the thigh or any site near the nerve lesion. Irritating drug such as quinine when injected intramuscularly in the deltoid or in the thigh may affect the axillary nerve or the sciatic nerve respectively. Whether the patient is suffering from diabetes or leprosy. Often such patients present first with loss of sensation of a patch of skin. Is there any past history of diphtheria?

Sometimes the patients may not complain of nerve involvement immediately after injury but may complain of this later on when the wound has healed. In these cases enquiry must be made whether the wound was infected or not, as infection will lead to fibrosis and will not allow proper regeneration of the nerve.

Personal history.— When the onset of the peripheral nerve lesion is spontaneous, an enquiry must be made whether the patient is diabetic, alcoholic or works with lead or arsenicals.

LOCAL EXAMINATION

A. INSPECTION.—

1. **Attitude and deformity.**— Many a diagnosis of the peripheral nerve injury can be made easily by the peculiar attitude and deformity of the limb concerned. Of these the followings are commonly seen and will be discussed.

Wrist drop is seen in paralysis of radial nerve, which supplies all the extensors of the wrist joint.

Foot drop is caused by paralysis of the lateral popliteal nerve which supplies the dorsiflexors and evertors of the foot.



Fig.9.1.— Wrist drop. The arrow shows the scar of a compound supracondylar fracture of the humerus.



Fig.9.2.— Winging of the scapula.

Winging of the scapula (prominence of the vertebral border of the scapula) indicates paralysis of the long thoracic nerve of Bell.

Clawhand (Main en griffe) means hyperextension of the metacarpophalangeal joints and flexion of the proximal and distal interphalangeal joints. This deformity is due to paralysis of the interossei and lumbricals, which are concerned with flexion of the metacarpophalangeal joints and extension of interphalangeal joints. The flexors of the fingers are unaffected. This deformity is seen in lesions of the ulnar nerve, more markedly in combined lesion of the ulnar and the median (this supplies first and second lumbricals) nerves and in Klumpke's paralysis. The extensor digitorum is mainly concerned with extension of the metacarpophalangeal joints and has little action in extension of the interphalangeal joints. Those muscles being unopposed by the interossei in the metacarpophalangeal joints and the flexors of the fingers act unopposed by the interossei on the interphalangeal joints. This causes the deformity.

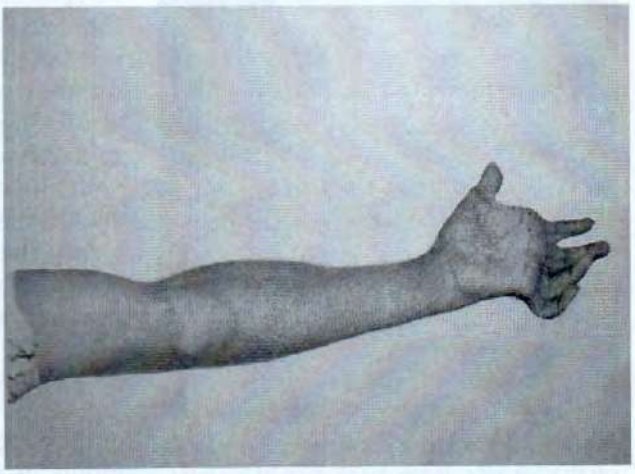

Fig.9.3.— One can see the clawhand due to injury to ulnar nerve, the wound scar at elbow is clearly seen.

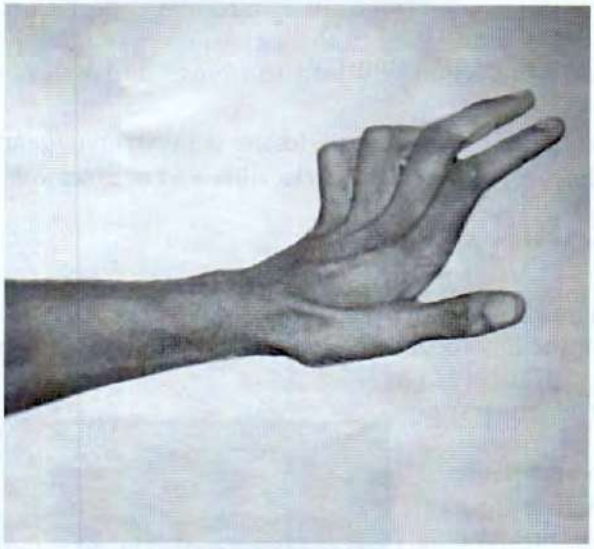

Fig.9.4.— Clawhand.

'Ape-thumb' deformity and the *'pointing index'* are due to lesion of the median nerve. The former deformity is due to paralysis of the opponens pollicis and the latter deformity is due to paralysis of the lateral half of the flexor digitorum profundus, both supplied by the median nerve.



Fig.9.5.— Erb's paralysis.

The typical *'policeman receiving the tip'* deformity is due to upper lesion of the brachial plexus (Erb-Duchenne). Since this lesion affects the Erb's point, which is the commencement of the upper trunk of the brachial plexus from the 5th and 6th cervical nerves and the point of emergence of the suprascapular nerve and the nerve to the sub-clavius, the abductors and lateral rotators of the shoulder (deltoid, supra- and infraspinatus and teres minor) and the flexors and supinators of the elbow (biceps, brachialis, brachioradialis and supinator) are mainly paralysed. In this deformity the arm hangs by the side of the body and internally rotated with forearm extended at the elbow and fully pronated (Fig. 9.5).

2. **Wasting of the muscles.**— This will be always obvious in long standing paralysis. So it is the rule to compare with the sound side always. Wasting of the deltoid, thenar and hypothenar eminences, hollows between the metacarpals due to atrophy of the interossei should be looked for and when the corresponding nerve is damaged this becomes obvious. Sometimes measurement of the circumference may be required to establish definitely muscular wasting.



Fig.9.6.— Note the wasting of the deltoid on the left side. It has been caused by intramuscular injection of quinine which has affected the axillary nerve.

3. **Skin.**— The skin becomes dry (no sweating due to involvement of the sympathetic nerve), glossy and smooth with disappearance of cutaneous folds and subcutaneous fat in complete paralysis. In partial lesion, there may be causalgia. Vaso-motor changes in the form of pallor, cyanosis, excessive sweating and trophic disturbances such as ridged and brittle nails, scaly skin etc. may become evident. Sometimes trophic ulcers may be seen.

4. **Scar or wound.**— Scar indicates previous wound and by looking at the scar one may guess whether the wound was infected or not. Presence of scar or wound will also give an indication as to which nerve may be injured (Fig. 9.1).

B. **PALPATION.**—

1. The **temperature** of the affected limb should always be compared with that of the normal side. The paralysed parts are usually cold.

2. **Muscles.**— Paralysed muscles are generally wasted in long standing cases. They are softer and more flabby. The function of the muscles will obviously be hampered.

3. **Skin.**— Whether any part of the limb is anaesthetised or not? This is very important as this will give a clue as to which nerve has been affected. As for example in case of lesion of the axillary nerve (due to dislocation of shoulder or fracture of the neck of the humerus) the deltoid muscle will be paralysed, but cannot be tested as the dislocation or fracture will itself prevent abduction of the shoulder. In this case if the students remember that the axillary nerve is also concerned in supplying cutaneous twigs to the skin over the lower part of the deltoid, that part will automatically be anaesthetised and the diagnosis of injury to the axillary nerve will be established.

If the skin of the affected side is seriously palpated an area of hyperaesthesia can be detected which is the site of nerve regeneration. By the shifting of this site of hyperaesthesia one can assess the speed of regeneration of the nerve.

4. **Scar.**— If present, should be palpated for tenderness, which indicates adhesion of the nerve to the scar.

C. **MUSCLES POWER.**— While investigating for muscle power, one must have a clear conception about the anatomy as to which nerve supplies which muscle. It may so happen that the muscle concerned is supplied by more than one nerve. In that case, the clinician will not be able to assess the severity of the nerve injury by investigating the muscle power. As for example, the flexor muscles of the fingers are supplied by the median nerve mostly except for the medial half of the flexor digitorum profundus which is supplied by the ulnar nerve. So the patient with median nerve injury will be able to flex the fingers (with the help of lumbricals, interrossei and

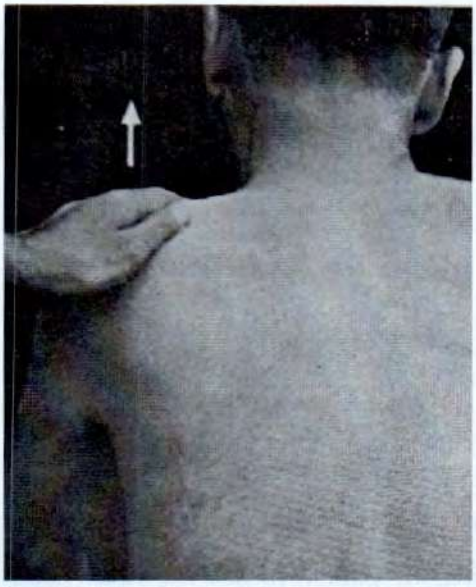

Fig.9.7.— Trapezius muscle is being tested against resistance to know intactness of the accessory nerve.

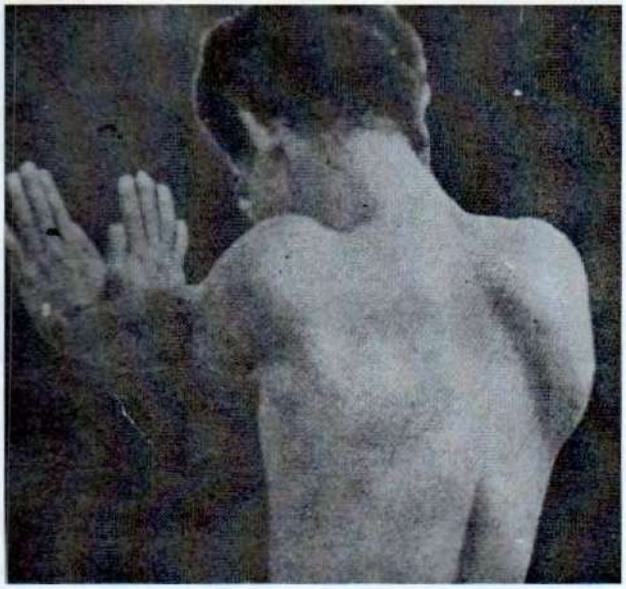

Fig.9.8.— Note the winging of the right scapula as the patient pushes against the wall. It indicates paralysis of the muscle due to involvement of the long thoracic nerve.

medial half of flexor digitorum profundus) and the wrist (with the help of flexor carpi ulnaris). To test whether a particular nerve is injured or not, the muscle which is exclusively supplied by the same nerve should be examined for muscle power. The patient is asked to carry out the movement of the joint against resistance which is performed by the same muscle supplied exclusively by the nerve concerned. Followings are the gradations of the muscle power which has been quoted according to Medical Research Council, London.

Gradation of Muscle power.— 0.= complete paralysis, 1.= flicker of contraction, 2.= contraction with gravity eliminated alone, 3.= contraction against gravity alone, 4.= contraction against gravity and some resistance and 5.= contraction against powerful resistance (normal power).

The muscles to be tested for individual nerves are described below :—

ACCESSORY NERVE

Trapezius.— This muscle is tested by asking the patient to elevate the shoulder against resistance (Fig.9.7).

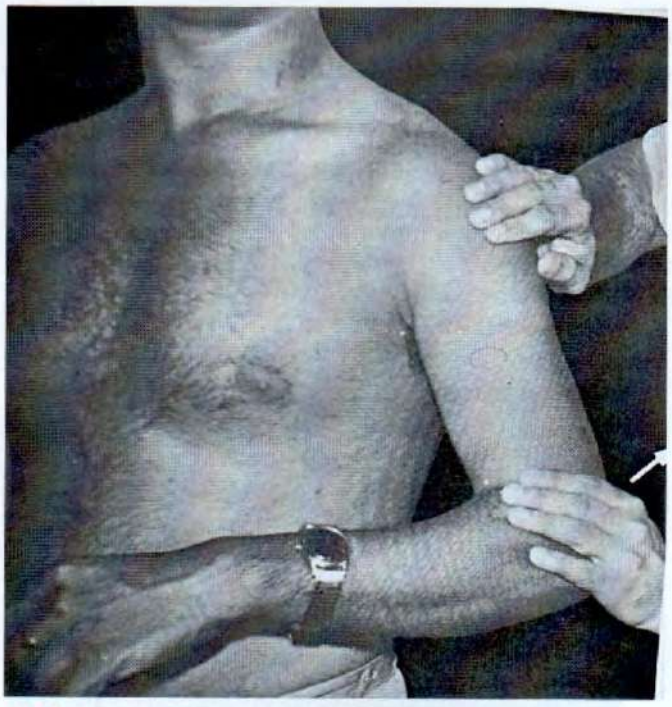

Fig.9.9.— The patient is asked to abduct the shoulder against resistance at the elbow. The other hand at the shoulder palpates the deltoid muscle to know if it is contracted or not.

HYPOGLOSSAL NERVE

Muscles of the tongue.— The patient is asked to protrude his tongue. In case of hemiparesis of the tongue due to involvement of the hypoglossal nerve of one side the tip of the tongue will be deviated towards the side of lesion.

LONG THORACIC NERVE

Serratus anterior.— The patient is asked to push against a wall with his outstretched hand. If the muscle is paralysed, the vertebral border and the inferior angle of the scapula will stand out from the chest wall — which is known as "winging of the scapula".

AXILLARY NERVE

Deltoid.— The patient is asked to abduct his shoulder with the elbow flexed at right angle against resistance (Fig. 9.9). With another hand the clinician palpates the muscle to know if it is contracting or not.

RADIAL NERVE

1) **Brachioradialis.**— The muscle is tested by asking the patient to flex the elbow joint keeping the forearm in midprone position against resistance. The muscle will stand out as a prominent band as shown in Fig.9.10.

2) **Extensor muscles of the wrist joint.**— Except the extensor carpi radialis longus which is



Fig.9.10.— The brachioradialis muscle is made to contract to know the intactness of the radial nerve.



Fig.9.11.— In case of radial nerve paralysis note that the fingers can be extended with the help of the interossei.

supplied by the radial nerve itself, all the other extensor muscles of the wrist joint are supplied by the posterior interosseous branch of the radial nerve. There will be "wrist drop" (Fig. 9.1) and inability to extend the wrist joint when these muscles are paralysed. To know the muscle power of these muscles the patient is asked to extend the wrist joint against resistance.

3) **Extensor digitorum.**— This muscle is mainly concerned with extension of the metacarpophalangeal joint. It also extends the interphalangeal joints along with the corresponding interossei and lumbricals. So when this muscle is paralysed the patient will not be able to extend the metacarpophalangeal joints *but will be able to extend the interphalangeal joints to some extent* (Fig. 9.11), the students must not forget this.

MEDIAN NERVE

1) **Flexor pollicis longus.**— The patient is asked to bend the terminal phalanx of the thumb against resistance while the proximal phalanx is being steadied by the clinician. This muscle is only paralysed when the median nerve is injured at or above the elbow.



Fig.9.12.— The terminal phalanx of the thumb is bent when the proximal phalanx is being steadied to know the power of the flexor pollicis longus.

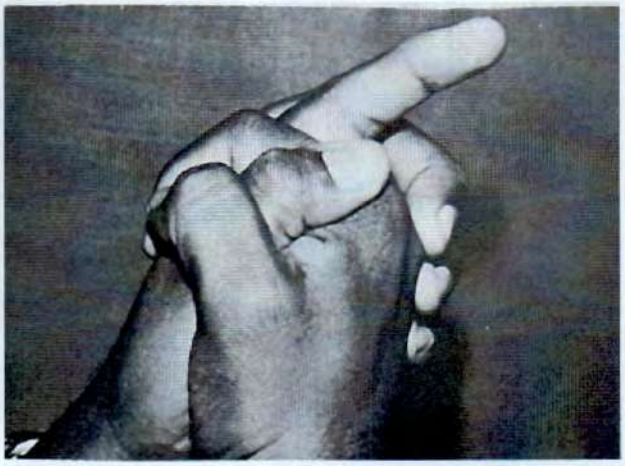

Fig.9.13.— Ochsner's clasping test.

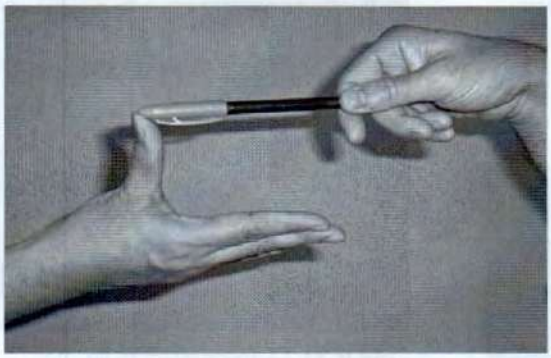

Fig.9.14.— Pen test is being performed to know the muscle power of abductor pollicis brevis.



Fig.9.15.— Testing the opponens pollicis against resistance of the clinician's fingers. During the test the thumb nail must remain in a plane parallel to the palm.

2) **Flexor digitorum superficialis and profundus (lateral half).**— In case of injury to the median nerve if the patient is asked to clasp the hands, the index finger of the affected side fails to flex and remains as a "pointing index". This test is known as *Ochsner's clasping test.*

3) **Abductor pollicis brevis.**— This muscle is concerned in abduction of the thumb that means the thumb moves upwards at right angle to the palm of the hand when the hand is laid flat on the table. This is done by asking the patient to touch the pen which is kept at a slight higher level than the palm of the hand with the thumb. This is known as *pen test.*

4) **Opponens pollicis.**— This muscle swings the thumb across the palm to touch the tips of the other fingers. The patient with paralysis of this muscle will be unable to do this movement. The students must not forget that a vicarious movement short of proper opposition movement is possible by adductor pollicis supplied by the ulnar nerve.

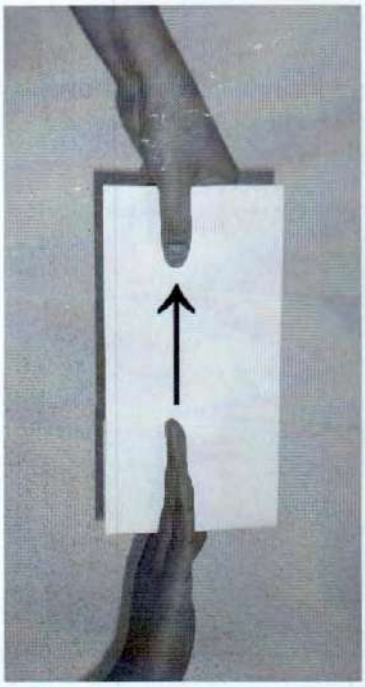

Fig.9.16.— The card test to note the strength of interossei.



Fig.9.17.— Interossei along with the lumbricals are concerned with extension of the interphalangeal joints. This is being tested while the proximal phalanx is being steadied.

ULNAR NERVE

1. **Flexor Carpi Ulnaris.**— When the wrist joint is flexed against resistance, the hand tends to deviate towards radial side.

2. **Interossei.**— The dorsal interossei are concerned with abduction of the fingers, while the palmar interossei adduct the fingers. Besides this, interossei along with the lumbricals flex the metacarpophalangeal joints and extend both proximal and distal interphalangeal joints.

(i) The patient is asked to abduct his fingers against resistance. This will give an idea about the muscle power of the dorsal interossei.

(ii) A card is inserted between the two fingers, which are kept extended. The patient is asked to hold the card by adducting these two fingers as tightly as possible. The clinician will try to pull the card out of his fingers. This will give an idea about the strength of the palmar interossei. This test is known as — *the card test.*

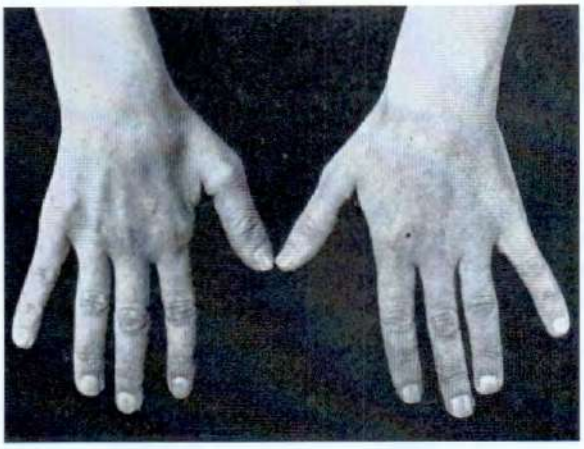

Fig.9.18.— Shows waisting of interosseous muscles in the right hand in case of cervical rib.

(iii) Flexion of the metacarpo-phalangeal joints cannot be tested, as this movement is also brought about by the Flexor digitorum superficialis and profundus.

(iv) While extension of the metacarpophalangeal joint is mainly the function of extensor digitorum, extension of the proximal and the terminal interphalangeal joints is mainly performed by the interossei along with the lumbricals through extensor expansions. The clinician steadies the proximal phalanx and the patient is instructed to extend the middle and terminal phalanges against resistance (Fig. 9.17). This will give an idea about the strength of the interossei and lumbricals.

3. **First palmar interosseous and adductor pollicis.**—The patient is asked to grasp a book between the

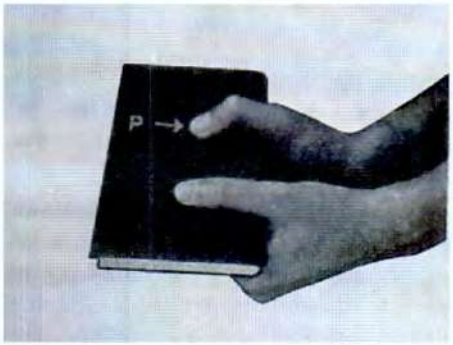

Fig.9.19.— Froment's sign. 'P' indicates the paralysed side.

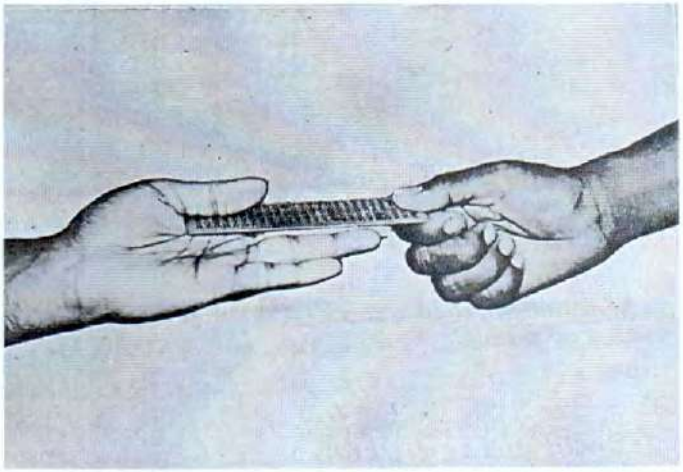

Fig.9.20.— Testing adductor pollicis and first palmar interosseous with a card.

extended thumb and the other fingers. If the ulnar nerve is intact the patient will grasp the book with extended thumb taking full advantage of the adductor pollicis and the first palmar interosseous muscles. But if the ulnar nerve is injured these two muscles will be paralysed and the patient will hold the book by flexing the thumb with the help of Flexor pollicis longus. This sign is known as "Froment's sign". This test can be performed with a card by asking the patient to hold the card firmly between the extended thumb and the other fingers.

SCIATIC NERVE

Complete lesion of this nerve is very rare and will cause complete paralysis of the hamstring muscles and all the muscles below the knee. What is more common is incomplete lesion of this nerve by subtrochanteric fracture of femur or posterior dislocation of the hip. The peculiar feature of this incomplete lesion is that it almost always involves the common peroneal part of the nerve.

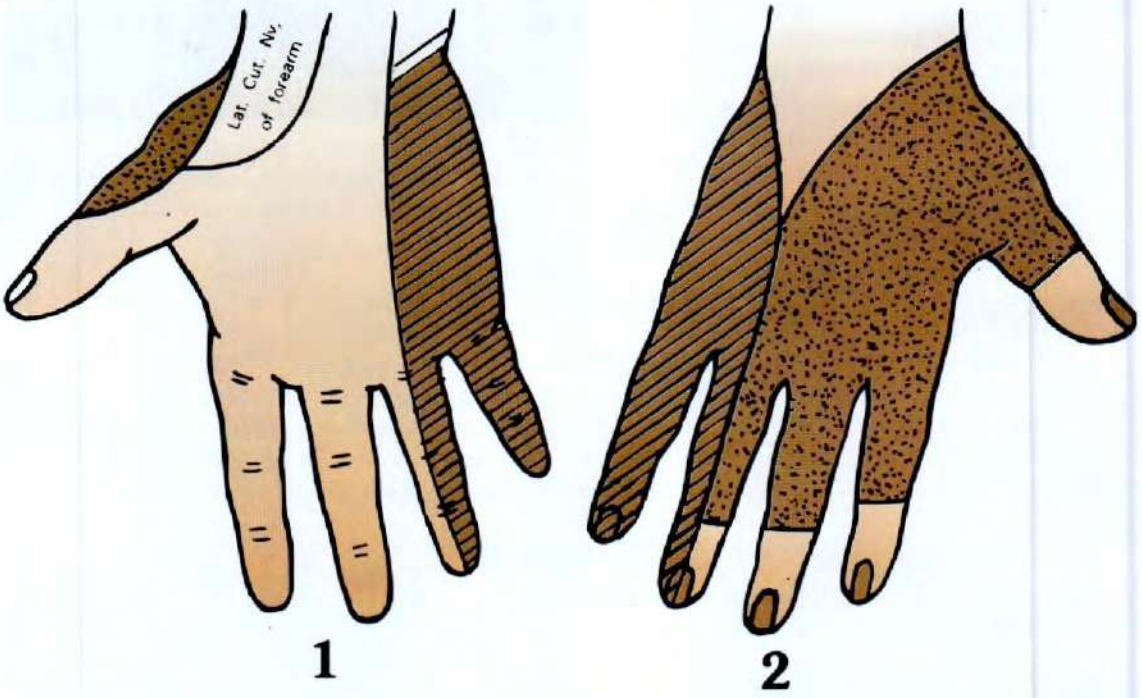

Fig.9.21.— Sensory distribution of the median nerve (shown as brown), radial nerve (shown as dotted area) and ulnar nerve (shown as striped area) of the hand is shown. 1.— Shows palmar aspect of the hand; whereas 2.— Shows dorsal aspect of the hand.

Common peroneal (Lateral popliteal) nerve.— This nerve supplies the extensor and peroneal muscles of the leg. So paralysis of these muscles will lead to a deformity of the foot known as "talipes equinovarus". The patient will be unable to dorsiflex and evert the foot. He will walk with undue lifting of the foot to clear the "dropped foot" off the ground.

Tibial (Medial popliteal) nerve.— This nerve supplies the plantar flexors of the ankle joint. In paralysis of these muscles the patient will be unable to plantar flex the joint. This will lead to a deformity known as "talipes calcaneovalgus". The muscles are tested by asking the patient to plantar flex the ankle joint against resistance.

D. **SENSATION.**—

The different forms of sensation are usually tested :—

(1) *Tactile sensitivity.*— This includes light touch, tactile localization, pressure and discrimination.

(2) *Pain.*

(3) *Temperature.*

(4) *Recognition of the size, shape and form of the object.*

(5) *Position — the appreciation of passive movement.*

(6) *Appreciation of vibration.*

To know the sensory loss and the type of sensory changes, patient's co-operation is absolutely essential. It largely depends on the patient's intelligence. It is the usual practice to apply the sensory stimulus first to an area of impaired sensation and its borders are made out *from the abnormal to normal area of sensation.*

1. **Tactile sensitivity.**— This can be differentiated into *protopathic sensation,* which is appreciation of gross touch and *epicritic sensation,* which is appreciation of light touch and accurate localization. A wisp of cotton wool is used for the latter sensation and the tip of the finger for the former sensation. The patient is asked whether he can feel the sensation and should be compared with that of the other side to know whether the sensation appreciated by the patient in the affected area is normal or not.

To discriminate between the two points is another test in this category and a compass is used for this purpose. Normally one should appreciate 2 mm of separation of points but will definitely



Figs.9.22 to 9.24.— Showing the sensory loss in the median nerve (shaded area in first two figures), ulnar nerve (the area demarcated by the black line in first two figures) and radial nerve (shaded area in 3rd figure) injury.

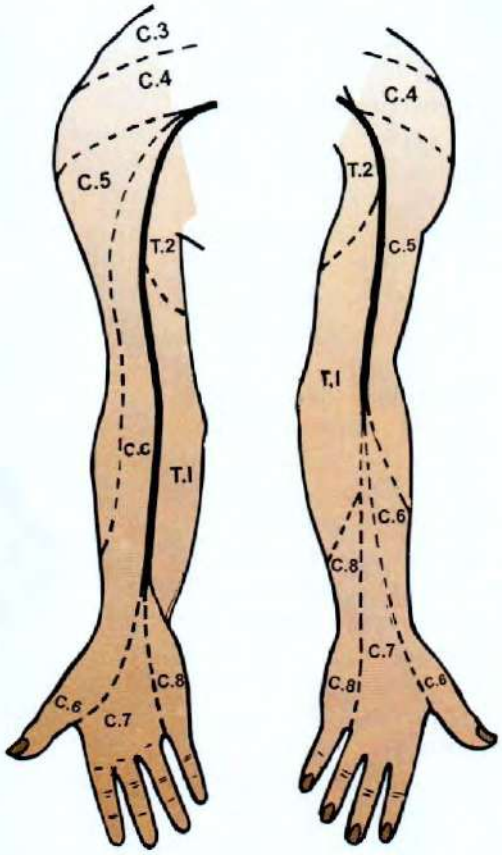

Figs.9.25 & 9.26.— It is a diagrammatic representation of the cutaneous supply of the various spinal nerves in the superior extremity.

be impaired in peripheral nerve lesion. This type of sensation is carried by the posterior column of the spinal cord to the parietal sensory area of the brain.

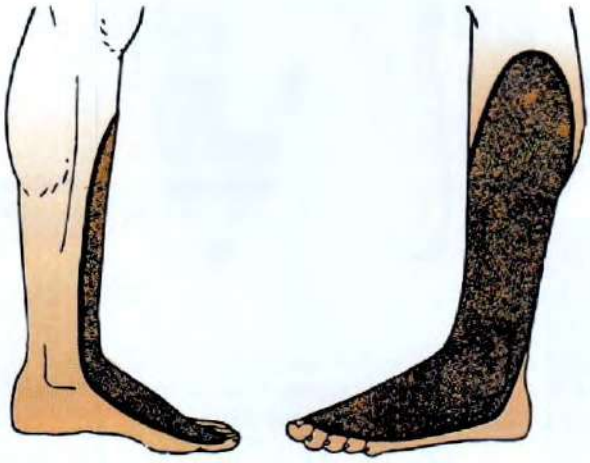

Figs.9.27 & 9.28.— Sensory loss in lesions of the lateral popliteal nerve.

2. **Pain.**— Pain may be of two varieties — a superficial cutaneous stimulation as the prick of a pin and a deep pressure sensation from muscles or bones. Care must be taken to elicit the difference between the sharpness of the point of a pin and a diffuse pain elicited by squeezing a muscle or an injury to the bone.

3. **Temperature.**— This is conveniently examined by using test tubes containing warm and cold water. The patient is asked to close his eyes and the part to be tested is touched with each test tube in turn. The patient has to say whether the tube feels warm or cold.

4. **Recognition of the size, shape and form of the object.**— Commonly one should be able to identify a familiar object which is kept on one's palm with closed eyes, e.g. a coin or a pencil or a pair of scissors etc. Loss of this faculty is known as Astereognosis. This may occur in posterior column lesion when it will be associated with defect in the position sense, vibration sense and light touch. It may also occur in lesion of the parietal lobe of the brain when position sense and light touch may be normal.

5. **Position sense.**— With closed eyes a normal person should identify the position of his joints or any movements there about. The patient is asked to close his eyes and a joint (as for example the great toe) is moved *passively*. The patient has to say whether the joint is being moved or not and if so in which direction.

6. **Appreciation of Vibration.**— A vibrating tuning fork of 128 Hz is placed on the surface of the body. This appreciation of vibration is lost in peripheral neuritis, posterior column disorder and tabes dorsalis.

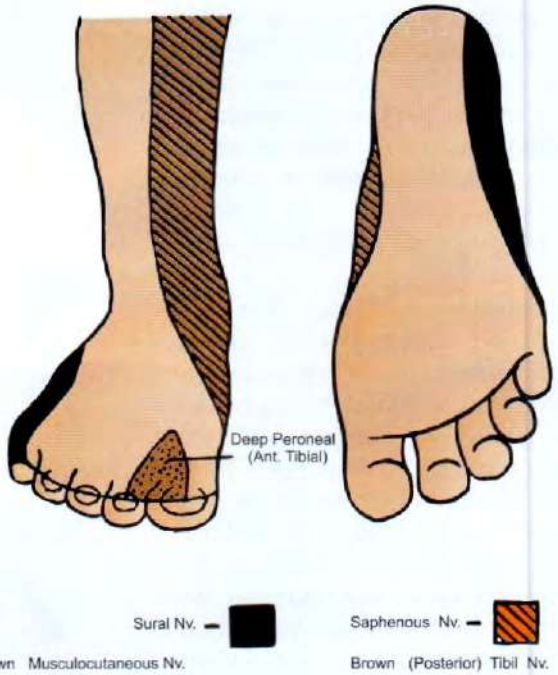

Figs. 9.29 & 9.30.— Sensory supply of the foot. Brown portion of the first figure is supplied by the musculocutaneous nerve, whereas brown portion of the second figure (sole of the foot) is supplied by the posterior tibial nerve.

E. **REFLEXES.**— In peripheral nerve injury the respective reflexes will be diminished or abolished.

F. **NERVE.**— When a peripheral nerve injury is suspected, one should always examine the whole course of the nerve. There may be evidence of injury such as displaced bone fragments or a scar to suggest an old injury.

The nerve should be palpated, as in many cases of leprosy there may be thickening of the involved nerve.

Moreover after injury to the nerve or suturing of the nerve, signs of regeneration can be assessed by the palpation. Regeneration starts after a couple of months and if gentle tapping over the course of the nerve *from distal to the proximal side* is made, a sensation of "pins and needles" or hyperaesthesia will be felt at the site of regeneration. This is known as **Tinel's sign.**

G. **MOVEMENTS.**— Movements of the joints are of two types — *active* and *passive*. Normally the range of active movement is similar to that of the passive movement of the same joint. But when the muscles, which are concerned in the movement, are paralysed or their tendons are torn, the passive movement will by far exceed the active movement of the same joint. So in case of peripheral nerve lesion one must note the extent of active as well as passive movements of the joint. In this context the students should remember that matting together of the muscles in the scar tissue, adhesion of the tendons with their sheaths or ankylosis of the joints will impair both the active and the passive movements of the joints.

H. **DEFORMITY.**— In peripheral nerve lesion paralysis of one group of muscles and unopposed action of the active group of muscles will definitely lead to deformity of the limb — whether it is wrist drop or foot drop or "Policeman taking the tip" etc. Deformity may also be from wasting of the muscles which are paralysed due to peripheral nerve lesion. In this respect the students should remember a fallacy that wasting of the muscles may be due to affections of the joints e.g. tuberculous arthritis, rheumatoid arthritis etc.

GENERAL EXAMINATION

In peripheral nerve lesion, one must exclude the general diseases like diabetes, leprosy, beriberi, syphilis, lead and arsenic poisoning etc. Besides these, alcoholism may be the cause of peripheral nerve lesion such as "Saturday night palsy".

In Klumpke's paralysis, there is every possibility that the cervical sympathetic supply may be affected which may produce Horner's syndrome. This syndrome is comprised of (i) myosis, i.e. contraction of the pupil due to paralysis of the dilator pupillae, (ii) ptosis, i.e. drooping of the upper eyelid due to paralysis of the levator palpabrae superioris, (iii) enophthalmos, i.e. regression of eye-ball due to paralysis of the Muller's muscle and (iv) anhidrosis, i.e. absence of sweating of the face and neck of that side.

SPECIAL INVESTIGATIONS

(1) **Blood** — for sugar to exclude diabetes and for W.R. and Kahn test to exclude syphilis are important investigations in peripheral nerve lesion.

(2) **Urine** is also tested for sugar to exclude diabetic peripheral neuritis.

(3) Nasal scrapping should be examined when leprosy is suspected.

(4) **Electrical responses.**— Denervated muscles will show 'reaction of degeneration', i.e. no response in Faradic stimulation and weak Galvanic response with reversal of polarity, that means A.C.C. becomes stronger than K.C.C. (normally K.C.C. or Kathodal closure contraction is stronger than A.C.C. or Anodal closure contraction). The reaction of degeneration starts to appear

from the fourth day after lesion and becomes fully established in about a fortnight.

(5) **Nerve conduction study** is useful to detect site of nerve lesion and evidence of regeneration.

TYPES OF INJURY OF THE PERIPHERAL NERVES.— According to extent of damage, injury to the peripheral nerves can be divided into three categories — 1. Neuropraxia, 2. Axonotmesis and 3. Neurotmesis.

1. **NEUROPRAXIA.**— This condition is equivalent to concussion, in which there is no organic damage to either the nerve fibre or its sheath, but there is a temporary physiological paralysis of conduction through the nerve fibres. It may occur due to minor stretching or torsion or vibratory effect of a high-velocity missile passing near the nerve. Clinically it is manifested by temporary loss of sensation, paraesthesia or weakness of the muscles supplied by the nerve. There is no reaction of degeneration. Recovery is complete, which may take a period of a few hours to even a few weeks.

2. **AXONOTMESIS** (Incomplete division).— In this condition there is division or rupture of nerve fibres or axons though the nerve sheath remains intact. Wallerian degeneration occurs in the distal portion of the broken axons. Recovery takes place slowly by down growth of the axons into the empty distal nerve sheath. There may be some loss of nerve fibres due to blockage of down growing axons by intraneural fibrosis. The relative positions of the axons are preserved and hence the quality of regeneration is quite good. Regeneration rate is 2 mm per day, which diminishes to 1 mm per day after a couple of months. Recovery is almost complete, though partial paralysis, slight sensory loss or causalgia may persist. Nerve conduction test is helpful to know the rate of regeneration. Axonotmesis usually results from a stress, traction or compression of the nerve in closed fracture and dislocations or from excessive zealed manipulation to reduce such injuries.

Clinically there is loss of sensation, tone and power of muscles with diminished reflex activity of the limb. Later on area of anaesthesia and paralysis of muscles will be restricted to those which are supplied by the damaged nerves only. Usually the total area affected is less than the known anatomical distribution of the nerve due to the fact that a few fibres within the nerve usually escape. There may be impaired circulation due to disuse which makes the affected portion cold and blue. There may be trophic changes e.g. the nails becomes brittle and the skin becomes thin. Reaction of degeneration appears, so that A.C.C. becomes greater than K.C.C.

3. **NEUROTMESIS.**— In this condition there is complete or partial division of the nerve fibres as well as their sheaths. Wallerian degeneration is noticed both in the distal segment and in the proximal segment. In the proximal segment retrograde degeneration takes place upto the first node of Ranvier. After fortnight the distal ends of the axons in the proximal segment start grow downwards. But, as there is a gap between the divided ends which is replaced by organic clots and fibrous tissue further downgrowth of the axons is not possible, so suturing is the only treatment if restoration of function is to be achieved. In the distal end typical Wallerian degeneration takes place, in which axis cylinder becomes fibrillated, medullary sheath breaks up into droplets of myelin and the cells of the sheath of Schwann are converted into phagocytes which remove remnants of axis cylinder and medullary sheath. The cells of Schwann proliferate forming a slight bulb at the commencement of the distal end from which sprouts of Schwann cells grow proximally towards the downgrowing axons of the proximal segment by chemotaxis.

There will be complete loss of motor, sensory and reflex functions of the limb supplied by the nerve. Secondary pathological changes may occur in the skin and joints of the affected part. Quality of regeneration is less perfect even after accurate nerve suturing. This is due to maldistribution of axons into the distal fragment. A motor nerve may grow down a sheath previously occupied by a sensory nerve, so it cannot function. Moreover a few axons will be wasted in the scar tissue at the suture line. So recovery of function will be worse in mixed

motor and sensory nerves, whereas it will be better if the nerve is pure motor or sensory nerve. So recovery of the radial nerve injury at the elbow will be better than the ulnar nerve or median nerve injury at the wrist.

CAUSES OF PERIPHERAL NERVE LESION.— These can be divided into two primary groups — A. Causes of single nerve involvement and B. Causes of multiple nerves involvement.

A. **Causes of single nerve involvement.—**

1. TRAUMATIC.— It may be due to (a) *closed injury* which usually causes either neuropraxia or axonotmesis lesion of the nerve or (b) *open injury* which usually causes neurotmesis.
2. INFLAMMATORY.— Herpes Zoster, leprosy, diphtheria.
3. NEOPLASTIC.— Neurofibroma, neurofibrosarcoma.
4. MISCELLANEOUS.— Tunnel syndrome, lead poisoning, arsenical poisoning, diabetes etc.

B. **Causes of multiple nerves involvement.—**

1. INFLAMMATORY.— Herpes Zoster, leprosy, diphtheria.
2. METABOLIC DISORDERS.— (a) Vitamin B Complex deficiency (particularly Bl). (b) Diabetes mellitus. (c) Alcoholism. (d) Porphyria.
3. IDIOPATHIC.
4. MISCELLANEOUS.— Lead poisoning, arsenical poisoning.

LEPROSY.— It is an infectious disease caused by mycobacterium leprae, an acid-fast bacillus almost similar to tubercle bacillus. The source of infection is mainly from nasal secretions of patients with lepromatous leprosy. According to resistant of the host two external varieties of leprosy are noticed — lepromatous leprosy and tuberculoid leprosy. In *lepromatous leprosy* there is least resistant from the host and the bacteria multiply with little cellular response. In *tuberculoid leprosy* there is resistance from the host and the tissue responses are strong. There are localized lesions where bacilli are present alongwith epitheloid cells, foreign body giant cells and many lymphocytes almost like a tubercle.

Clinically it is a systemic infection and mainly involves the skin, upper respiratory tract and peripheral nerves. Certain superficial nerves e.g. great auricular, superficial temporal and ulnar nerve at the elbow become swollen and tender. Common peroneal nerve at the neck of the fibula and median nerve at the wrist may also be affected. Tibial nerve above the flexor retinaculum and behind the medial malleolus may be affected. Patches of anaesthesia from involvement of cutaneous nerves is an important sign of this disease. Disfigurement of hands and feet which are seen in leprosy are not due to disease itself, but to the damage and misuse which follows loss of pain sensation.

DIFFERENTIAL DIAGNOSIS OF INDIVIDUAL NERVE LESIONS

BRACHIAL PLEXUS

Lesion in brachial plexus may be either complete or partial. COMPLETE LESION is rare and occurs only after severe accidents. It damages all the roots of the plexus. There will be anaesthesia of the whole of the upper limb except the upper part of the arm which is supplied by C3, 4 and 5. There will be complete paralysis of the arm, though long thoracic nerve supplying the serratus anterior or the nerve supplying the rhomboid may escape.

INCOMPLETE LESION may be due to stabs or cuts which involve any of the roots. But common injury is either upper brachial plexus lesion (Erb-Duchenne paralysis) or lower brachial plexus lesion (Klumpke's paralysis).

UPPER BRACHIAL PLEXUS LESION (ERB-DUCHENNE PARALYSIS) (Fig.9.5).— This injury occurs due to excessive depression of the shoulder or displacement of the head opening out the angle between shoulder and the neck. In adult it may occur due to fall of weight on the shoulder or motor cycle accident where the head is moved away from the shoulder. It may occur after difficult labour when the angle between the shoulder and the neck is opened out. It involves injury to C5 and C6 nerve roots. The muscles affected are the deltoid, the biceps, brachialis, brachioradialis and supinator. The affected limb becomes internally rotated, extended at the elbow and pronated in the well-known position of 'Policeman taking a tip'. There may be sensory loss over the outerside of the arm and upper part of the lateral aspect of the forearm.

LOWER BRACHIAL PLEXUS LESION (KLUMPKE'S PARALYSIS).— Such injury occurs due to forceful abduction of the shoulder, which may occur during breech presentation with arms above the head. In adult this injury may occur when a falling person clutches at an object or a person failing to obtain a foot hold on a passing bus may forcefully hyperabduct his arm. The C8 and T1 nerve roots may be affected, though T1 is more often involved. The result is paralysis of the intrinsic muscles of the hand (with clawhand and features of combined median and ulnar nerve palsy) with anaesthesia of the innerside of the forearm, hand and inner 1½ fingers. It is usually associated with Horner's syndrome which includes ptosis, enophthalmos, contraction of the pupil and anhidrosis of the affected side of the face.

ACCESSORY NERVE

This nerve passes downwards and backwards at right angle to the centre of the line connecting the angle of the jaw and the mastoid process. After supplying the sternomastoid muscle, it emerges from the posterior border of the same muscle at its junction of the upper third and lower two thirds. It then runs across the floor of the posterior triangle and disappears under cover of the trapezius muscle which it supplies. This nerve is rarely damaged by injury, but it is often involved during bloc dissection of the cervical lymph nodes or during removal of tuberculous lymph nodes. Very occasionally this nerve may be injured before it supplies the sternomastoid muscle. Even in these cases, complete paralysis of the sternomastoid muscle may not result due to the additional supply from second and third cervical roots, which this muscle derives. More often this nerve is injured during its course through the posterior triangle. In this case, the trapezius muscle will lose its nerve supply. In case of this muscle also there is additional supply from the third and fourth cervical nerves. On examination there will be drooping of the shoulder and the patient will be unable to elevate the shoulder against resistance (Fig. 9.7). Wasting of the trapezius will also be obvious. The sternomastoid muscle is tested by asking the patient to turn his head to the side *opposite* to the muscle against resistance. The muscle will stand out as a rigid band.

HYPOGLOSSAL NERVE

This nerve comes out of the skull through the hypoglossal or anterior condylar canal in the occipital bone. At first the nerve lies at a deeper plane behind the internal carotid artery, the internal jugular vein, the ninth, tenth and eleventh cranial nerves. Gradually it gains the interval between the internal carotid artery and the internal jugular vein and takes a half-spiral turn crossing the internal and the external carotid arteries and the loop of the lingual artery a little above the tip of the greater cornu of the hyoid bone, being itself crossed by the facial vein. It then passes deep to the tendon of the Digastric, the Stylohyoid and the posterior border of the Mylohyoid to gain the interval between the Hyoglossus and the Mylohyoid, where it comes in

relation with the deeper part of the submandibular salivary gland, the submandibular duct and the lingual nerve.

This nerve is liable to be damaged during dissection for bloc resection of cervical lymph nodes, during surgical removal of tuberculous lymph nodes in the submandibular region and during operative removal of the submandibular salivary gland.

Injury to the twelfth nerve will cause paralysis of that half of the tongue leading to hemiatrophy and diversion of the tip of the tongue to the same side when it is protruded out.

LONG THORACIC NERVE (NERVE OF BELL)

This nerve, which is comprised of the fifth, sixth and seventh cervical nerve roots, mainly supplies the serratus anterior muscle. This nerve may be injured along with the cervical nerve roots in a severe accident involving the brachial plexus. This nerve is also injured accidentally during operation on the chest wall or on the breast.

Paralysis of serratus anterior muscle will cause "winging" of the scapula, i.e. the vertebral border and the inferior angle of the scapula stand out when the patient is asked to push against a wall with extended arm (Fig. 9.8).

RADIAL NERVE

This nerve receives twigs from the fifth, sixth, seventh, eighth cervical nerves and from the first thoracic nerve. This nerve is a branch of the posterior cord of the brachial plexus. It descends behind the third part of the axillary artery and in front of the subscapularis and the tendons of the Latissimus dorsi and Teres major. It then passes obliquely across the back of the humerus, first between the lateral and the medial heads of the triceps being accompanied by the arteria profunda brachii to reach the lateral side of the humerus where it pierces the lateral inter-muscular septum and enters the anterior compartment of the arm. It then descends between the Brachialis on one side and the Brachioradialis above and the extensor carpi radialis longus below on the other side. In front of the lateral epicondyle it divides into its two terminal branches the *superficial* and the *deep*.

The *superficial branch* descends in front of the lateral epicondyle and lies in front of the Supinator and behind the Brachioradialis. It now runs in front of the pronator teres, the radial head of the flexor digitorum superficialis and the flexor pollicis longus. About 7cm above the wrist the nerve turns back round the lateral side of radius, pierces the deep fascia and divides into five dorsal digital nerves to supply the skin on the radial side of the thumb, adjoining part of the thenar eminence, the medial side of the thumb, the index finger, the middle finger and the lateral half of the ring finger. It must be remembered that these digital nerves do not supply upto the tip of the fingers, but they stop as far as the root of the nail in the thumb, as far as the middle phalanx in the index finger and upto the proximal interphalangeal joints in case of the middle and the ring fingers. The remaining distal areas of the skin are supplied by the palmar digital branches of the median and the ulnar nerves.

The deep branch (posterior interosseous nerve) winds round the lateral side of the radius between the two planes of fibres of the Supinator to reach the back of the forearm. Before it enters the Supinator muscle it gives a branch to the Extensor carpi radialis brevis and another to the Supinator. After it comes out of the Supinator, it gives off three short branches — to the Extensor digitorum, Extensor digiti minimi and Extensor carpi ulnaris and two long branches one to the Extensor pollicis longus and the Extensor indicis and another to the Abductor pollicis longus and the Extensor pollicis brevis.

The radial nerve itself, before it divides into its terminal branches, gives off the muscular branches to the Triceps, Anconeus, Brachioradialis, Extensor carpi radialis longus and lateral one fourth of the brachialis. It must be remembered that it sends off the twigs to supply the three heads of Triceps before it reaches the groove at the back of the humerus. It gives off the three cutaneous branches — the posterior cutaneous nerve of the arm, which arises in the axilla, the lower lateral cutaneous nerve of the arm to supply the skin of the lateral part of the lower half of the arm and the posterior cutaneous nerve of the forearm which supplies back of the forearm and wrist. The radial nerve also sends articular branches to the elbow joint.

The radial nerve may be injured (a) *in the axilla* by the use of a crutch, which is not properly adjusted (crutch palsy) or fracture dislocation of the upper end of the humerus or by attempts for reduction. It may be injured (b) *in the radial groove* either by fracture of the shaft of the humerus or by pressure on the arm at the edge of the operating table or at the edge of a chair or a pavement after a deep sleep being drunk (Saturday night palsy) or by inadvertent intramuscular injection on the radial nerve at this region. **The posterior interosseous nerve may be injured** by fracture or dislocation of the upper end of the radius or during operations involving this region.

According to the site of the injury the various muscles will be paralysed. As for example when the radial nerve is injured in the axilla all the muscles supplied by the radial nerve will be paralysed and the cutaneous sensation of the regions supplied by the cutaneous branches of the radial nerve will be abolished. When injury affects the radial nerve at the radial groove the Triceps muscle escapes, similarly the posterior cutaneous nerve of the arm. When the posterior interosseous nerve is injured, all the muscles supplied by the radial nerve itself and the cutaneous branches escape as also the supinator and the extensor carpi radialis brevis which are supplied before the site of injury.

The radial nerve through its posterior interosseous nerve is mainly concerned in supplying the extensors of the wrist joint. So the commonest complaint after radial nerve injury is inability of the patient to extend the wrist (Wrist drop) and metacarpophalangeal joints of the fingers. The students must remember that extension of interphalangeal joints is done by interossei through the extensor expansions. These interossei are supplied by the ulnar nerve and hence unaffected by radial nerve injury. If this knowledge of anatomy is lacking, extension of interphalangeal joints may be erroneously interpreted as signs of regeneration.

Brachioradialis is supplied by the radial nerve before it divides into the superficial and the deep branches. So by testing this muscle one can assess the level of the radial nerve injury. The muscle is tested by asking the patient to put the forearm in mid-prone position and flexing the elbow against resistance. The muscle will stand out prominent as shown in Fig.9.10. Bilateral wrist drop may occasionally be due to lead palsy, in which case the brachioradialis may escape and the paralysis of the other muscles is often incomplete.

MEDIAN NERVE

This nerve arises by two roots, one from the lateral cord (C5,6,7) and the other from the medial cord (C8 and T1) of the brachial plexus. The median nerve descends into the arm lying at first lateral to the brachial artery and at the level of the middle of the arm it crosses in front of the artery and descends on its medial side to the cubital fossa. The nerve enters the forearm between the two heads of the pronator teres crossing from medial to the lateral side the ulnar artery being separated by the deep head of this muscle. It then passes deep to the tendinous bridge that connects the humero-ulnar to the radial head of the Flexor digitorum superficialis and descends through the forearm deep to but adherent to the Flexor digitorum superficialis

and in front of the Flexor digitorum profundus. 5 cm above the wrist it emerges at the lateral edge of the Flexor digitorum superficialis and becomes superficial just above the wrist, where it lies between the tendons of the Flexor digitorum superficials and the Flexor carpi radialis. The nerve then passes deep to Flexor retinaculum to gain the palm of the hand. At this place the nerve may be compressed in the fibro-osseous canal to produce "carpal tunnel syndrome". A short and stout muscular branch comes out of the median nerve in the palm and supplies the Abductor pollicis brevis, the Opponens pollicis, the Flexor pollicis brevis and rarely the first dorsal interosseous muscle. It ends as palmar digital branches which are 4 to 5 in number and provide digital branches to the thumb, the index finger, the middle and lateral half of the ring finger. These palmar digital branches also supply the first and the second lumbrical muscles.

The branches of the median nerve in the arm are only vascular branches to the brachial artery and a muscular branch to the pronator teres.

The branches in the forearm are the *muscular branches* to all superficial flexor muscles e.g. the Pronator teres, Flexor carpi radialis, Palmaris longus and Flexor digitorum superficialis. *Anterior interosseous* nerve, which comes off the median nerve when it passes between the two heads of the pronator teres, supplies the lateral half of the Flexor digitorum profundus, Flexor pollicis longus and Pronator quadratus. *Articular branches* supply the elbow joint and the proximal radio-ulnar joint. The *palmar cutaneous branch* supplies the skin over the thenar eminence and the central part of the palm.

According to the level of the median nerve injury, the various muscles will be affected. The median nerve may be injured at the elbow by the supracondylar fracture, dislocation of the elbow joint or inadvertent use of the tourniquet. At the wrist, the median nerve is more commonly injured by cut injury and accidents as the nerve is comparatively superficial here.

(1) **Flexor digitorum superficialis and profundus (lateral half).**— These muscles are paralysed when the median nerve is injured at the elbow or above. When the patient is asked to clasp the hands, the index finger of the affected side fails to flex. Other fingers are flexed by the medial half of the profundus muscle, which is supplied by the ulnar nerve. This test is called *Ochsner's clasping test* and the index finger, which fails to flex is called the "pointing index".

(2) **Flexor pollicis longus.**— This muscle is also affected when the median nerve is injured at or above the elbow. When this muscle is paralysed, the patient is unable to flex the terminal phalanx of the thumb. This is tested by holding the thumb at its base and the patient is asked to bend the terminal phalanx as shown in Fig. 9.12.

(3) **Flexor carpi radialis.**— The hand deviates to the ulnar side when it is flexed against resistance.

(4) **Muscles of the thenar eminence.**— These muscles are paralysed and ultimately become wasted when the median nerve is injured anywhere at or above the wrist joint. The wasting of these muscles will be obvious on inspection as the eminence is flattened and the thumb apparently comes to the same plane as the other metacarpal bones. This is called "Simian" or "Ape-like hand".

Abductor pollicis brevis.— The action of this muscle is to draw the thumb forwards at right angle to the palm of the hand. The patient is asked to lay his hand flat on the table, a pen is held above the palm and the patient is asked to touch the pen with his thumb — the "pen test". In median nerve injury the muscles will be paralysed and this test will be negative.

It must be remembered that the first metacarpal bone is placed at right angle to the other metacarpal bones. So its flexion and extension occurs in the plane of the palm slight in front of it, whereas abduction and adduction occur at right angle to this plane.

Opponens pollicis. — This muscle brings the tip of the thumb towards the tips of other fingers.

While testing this muscle it must be noted that the real opposition movement is a swinging movement of the thumb across the palm and not a simple adduction movement of the thumb brought about by the adductor pollicis supplied by the ulnar nerve.

ULNAR NERVE

This nerve arises from the medial cord of brachial plexus comprising of C8 and T1. It runs downwards through the axilla on the medial side of the axillary artery, between it and the vein of the same name upto the middle of the arm. Here it pierces the medial intermuscular septum and reaches the posterior compartment of the arm in front of the triceps upto the elbow where it lies behind the medial epicondyle accompanied by the superior ulnar collateral artery. It enters the forearm between the two heads of the Flexor carpi ulnaris and descends along the medial side of the forearm lying *in front of* the Flexor digitorum profundus. At the wrist, it passes in front of the Flexor retinaculum on the lateral side of the pisiform bone and on the medial side of the ulnar artery and ends by dividing into *superficial* and *deep* terminal branches.

The branches of the ulnar nerve are :—

The muscular branches are two in number which supply the Flexor carpi ulnaris and the medial half of the Flexor digitorum profundus.

The palmar cutaneous branch — arises from the middle of the forearm, descends in front of the ulnar artery and supplies the ulnar artery, the skin of the medial aspect of the palm and sometimes Palmaris brevis.

The *dorsal branch* — supplies the medial side of the little finger and the posterior aspect of the adjacent sides of the ring and the little fingers and occasionally the adjoining sides of the middle and the ring fingers.

The *articular branch* — supplies the elbow joint.

The *superficial terminal branch* supplies the skin of the medial side of the hand, and through the palmar digital nerves the medial side of the little finger and the adjacent sides of the ring and little fingers. It also supplies the Palmaris brevis.

The *deep terminal branch* — passes between the Abductor digiti minimi and Flexor digiti minimi and then perforates the Opponens digiti minimi and supplies all these three muscles. It then crosses the hand and supplies branches to the interossei and to the third and the fourth lumbricals. It ends by supplying the two heads of the adductor pollicis.

Ulnar nerve may be injured at the elbow or at the wrist.

At the elbow this nerve may be injured (i) in supracondylar fracture either in recent injury by the fractured segments or in late cases (Tardy ulnar palsy) by the callus formed at the fractured site or by the cubitus valgus deformity as a sequel of malunion. (ii) In fracture of the medial epicondyle of the humerus this nerve is often injured. In all cases of open reduction of this fracture the ulnar nerve should be transposed anteriorly to prevent further damage to the nerve by friction or by involvement of the nerve in callus formation. *Anterior transposition* of the ulnar nerve should always be performed wherever there is possibility of the ulnar nerve involvement.

At the wrist the ulnar nerve may be damaged by the same injury as described under the median nerve. As this nerve is more superficially placed than the median nerve the possibility of injury to this nerve is more in this region.

Ulnar nerve injury will cause loss of sensation of the medial side of the hand, the whole of the little finger and a small part on the medial side of the ring finger.

The muscles which are involved in ulnar nerve injury anywhere above the wrist are muscles of the hypothenar eminence, the interossei, the third and fourth lumbricals and the adductor pollicis. When the ulnar nerve is injured at the elbow, besides the muscles mentioned above,

the Flexor carpi ulnaris and the medial half of the Flexor digitorum profundus will be paralysed.

The muscles are tested as follows :—

(1) **Flexor carpi ulnaris.**— When the wrist joint is flexed against resistance, the hand tends to deviate towards the radial side.

(2) **Interossei.**— These muscles extend the middle and the terminal phalanges of the fingers through the extensor expansions. These are also concerned in flexion of the metacarpophalangeal joints along with the lumbricals. Besides these, the dorsal interossei abduct the fingers and the palmar interossei adduct the fingers. So far as the flexion of the metacarpophalangeal joint is concerned, it cannot be tested as this joint is also flexed by the continued action of the Flexor digitorum superficialis and profundus. (i) These muscles can be tested for their *power of extension of the middle and the terminal phalanges.* This is tested by holding the proximal phalanx and asking the patient to straighten his finger against resistance (Fig. 9.17). The patient is asked to abduct his fingers against resistance. This test will reveal the *power of abduction of the dorsal interossei.* (iii) The patient is asked to adduct his fingers keeping straight. A card may be inserted between the two fingers for grasping. The card is now pulled out against the adducted fingers to see the *power of adduction of palmar interossei.* This test is known as the "card test".

SCIATIC NERVE

As has already been discussed the common peroneal part of the sciatic nerve is more often affected than the medial tibial part in injury to the sciatic nerve.

Common peroneal nerve.— This nerve itself is liable to be injured in fracture neck of fibula. This nerve supplies the extensor and peroneal groups of muscles of the leg as also through its musculocutaneous branch it supplies the anterior and lateral aspects of the leg and whole of the dorsum of the foot and toes except the skin between the great and the 2nd toe which is supplied by its deep peroneal (anterior tibial) nerve. So injury to this nerve will result in the foot drop and talipes equinovarus deformity. The sensory loss will affect the anterior and lateral aspect of the leg, dorsum of the foot and the toes.

Medial popliteal nerve.— This nerve is rarely injured except in open wounds. This nerve supplies the muscles of the calf e.g. the soleus, the gastrocnemius, the popliteus, the plantaris, the tibialis posterior, the flexor digitorum longus and the flexor hallucis longus. Through sural nerve it supplies the lateral part of the leg and sole and through plantar nerves it supplies the sole. So injury to this nerve will make the patient unable to plantar flex his ankle with loss of sensation of the whole of the sole. As it supplies the plantar muscles through the plantar nerves, there will be claw foot.



Fig.9.31.— A typical example of "winging of the scapula".

Chapter

10 DISEASES OF MUSCLES, TENDONS AND FASCIAE

In this chapter the non-specific diseases such as non-articular rheumatism, pathological tendon ruptures, tenosynovitis (simple, suppurative and stenosing), Dupuytren's contracture and ganglia will be discussed. These conditions affect more or less whole of the body.

HISTORY

The following points should be particularly noted while taking history :

1. **Pain.**— This is the most important complaint in the above conditions. Pain at the elbow, particularly while extending the wrist and fingers, is come across in "Tennis elbow". Similarly localized pain on the medial epicondyle of the humerus which is aggravated by flexing of the wrist against resistance is seen in Golfer's elbow. Pain during abduction of the shoulder particularly in the middle of the arc is the regular feature of supraspinatus tendinitis. Pain on the ligamentum patellae particularly during active extension of the knee indicates the diagnosis of patellar tendinitis. Similarly pain in the sole just in front of the calcaneum tuberosity is seen in plantar fasciitis. In Achilles' tendinitis pain is felt on the attachment of the Achilles' tendon and it is aggravated by plantar flexion of the ankle, more so when the patient tries to stand on his toes.

Pain is also a regular feature of tenosynovitis when the affected tendon is being used, be it a simple tenosynovitis or a stenosing tenosynovitis. In de Quervain's disease the patient complains of pain when the thumb is extended or abducted. In carpal tunnel syndrome the patient complains of a rest pain along the distribution of the median nerve.

2. **Deformity.**— It is the first complaint in conditions like Dupuytren's contracture, ganglia, rupture of the tendons e.g. long head of the biceps, Achilles' tendon etc. In the first two conditions deformity is obvious whereas in the rupture of tendons deformity becomes obvious only when the muscles concerned contract.

EXAMINATION

A. **INSPECTION.**— 1. **Deformity.**— In Dupuytren's contracture inspection is all that is necessary for the diagnosis. Localized thickening of the fascia, which affects the palmar fascia much more often than the plantar fascia, is a characteristic feature. Contracture of the fascia causes flexion of the fingers or toes. Most commonly this disease affects the ring finger first and then the little finger.

2. **Swelling.**— Abnormal swelling of a muscle particularly when it contracts is a feature of rupture of the tendon or the muscle concerned. A little thickening of the flexor sheath of the tendon of the finger is the feature of a " trigger finger".

B. **PALPATION.**— 1. **Tenderness.**— Localized tenderness on the particular point of the attachment of the tendon is diagnostic of any type of tendinitis e.g. supraspinatus tendinitis, patellar tendinitis, Achilles' tendinitis and plantar fasciitis. Similarly, localized tenderness on the

attachment of the extensor muscles of the forearm to the lateral epicondyle or the flexor muscles of the forearm to the medial epicondyle indicates 'Tennis elbow" or Golfer's elbow respectively.

2. **Deformity.**— Palpation of the deformity, which is come across in conditions like Dupuytren's contracture and ganglia, is more informative about the type of operation and the extent of dissection rather than diagnosis. Diagnosis is easy in these cases.

3. **Swelling.**— In stenosing tenovaginitis as seen in de Quervain's disease or trigger finger, palpation of the swelling of the sheath of the tendon is important. Gradually as consequence of constriction caused by the tendon sheath the tendon distal to the constriction may bulge out to form a swelling. In carpal tunnel syndrome a careful palpation will yield thickening of the flexor retinaculum and will reveal the neurological deficits of the median nerve due to this condition. In rupture of the tendon and muscles while the muscles concerned are contracting against resistance palpation of the swelling of the muscle will immediately make the diagnosis as to which muscle has been involved in rupture. As ganglion is a tense cystic swelling, fluctuation test may not be performed, but the swelling is softest at its centre.

DIFFERENTIAL DIAGNOSIS

Supraspinatus tendinitis.— Degenerative process of the supraspinatus tendon following deficient blood supply seems to be the cause of this condition. It commonly affects the middle aged and old people and males are predominantly sufferer than the females. The main complaint is the *pain* in the shoulder particularly felt during abduction and external rotation movements. Pain becomes very much aggravated during the middle third of the abduction arc when the head of the humerus comes very close to the acromion process and the degenerated supraspinatus tendon becomes compressed between the two bones. This condition is popularly known as "painful arc syndrome". That means when the patient abducts his arm, the first 60° is painless. The pain starts henceforth and continues till the arm reaches an angle of 120°. After this the pain subsides as the shoulder is further abducted. The second complaint of the patient is *stiffness* of the shoulder, which is popularly known as "frozen shoulder". The natural sequence is that the pain gradually subsides and the stiffness increases. Upto 3 months stiffness remains static, after which stiffness also gradually subsides in next 3 months.

The main sign is the localized tenderness over the insertion of the supraspinatus tendon. Sometimes degenerative calcification of the tendon may develop which becomes obvious radiologically. Degenerative process may proceed further as to cause spontaneous rupture of the tendon.

Tennis elbow.— In this condition the patient complains of pain on the lateral epicondyle of the humerus where the extensor group of muscles of the forearm is attached. The pain is aggravated when the patient tends to extend the wrist and the fingers, more so against resistance. On examination localized tenderness is felt on the lateral epicondyle where the extensor muscles of the forearm are attached.

Golfer's elbow.— This condition is more or less similar to the Tennis elbow, but on the medial side. Pain and tenderness are localized on the medial epicondyle of the humerus, where the flexor muscles of the forearm take origin. Patient complains of pain when asked to flex the wrist and fingers against resistance.

Achilles' tendinitis.— The patient complains of pain at the attachment of the Achilles' tendon to the bone. The condition is sometimes attributed to the unaccustomed prolonged walking or sometimes due to ill-fitting shoes.

Plantar fasciitis.— In this condition the patient experiences unbearable pain under the heel

particularly during walking when the weight of the body is carried by the heel. The cause seems to be a small tear in the attachment of plantar fascia to the os calcis. Non-specific infection from non-specific urethritis or from specific gonococcal infection may develop this condition. Sometimes a bony spur may be seen at the attachment of the plantar fascia. This may or may not be the cause of pain.

Fibrositis or fibrositic nodule.— This condition is also a type of non-articular rheumatism and a common cause of low back pain. The pain and tenderness is localized at the attachment of the erector spinae muscle or the fascia covering it.

Rupture of the supraspinatus tendon.— Spontaneous rupture of the supraspinatus tendon may occur due to degenerative change in the tendon in elderly individuals. The patient complains of sudden pain in the shoulder while involved in normal activities. The most important physical sign is *inability to initiate abduction*. So the patient leans to the affected side making an angle of abduction between his body and the arm initiated by gravity. After this he can continue the movement of abduction in a normal way. Thus the diagnosis may be escaped by the inexperienced.

Rupture of the long head of the biceps brachii.— This condition also affects elderly individual and also a sequel of degenerative process. The rupture commonly takes place in the bicipital groove and mostly spontaneous. The patient sometimes complains of a sudden pain in the upper arm, but it is often neglected. More commonly the patient complains of an abnormal swelling when he flexes his elbow due to bunching of the biceps muscle.

Rupture of the Achilles' tendon.— This is due to vascular insufficiency of the tendon and may occur due to violence on the contracted muscle while playing football etc. The presenting complaint and the signs are similar to the rupture of the biceps tendon described above.

Stenosing tenovaginitis.— The cause of this condition is rather unknown, but it involves mostly the common sheath of the abductor pollicis longus and extensor pollicis brevis (de Quervain's disease) and the fibrous sheath of the flexor tendons of the fingers and the thumb (Trigger finger).

De Quervain's disease.— Women between 40-50 years are the usual victims. In this condition the patient complains of pain and difficulty in abducting and extending the thumb. On examination a bulge is detected on the said tendons over the radial styloid process. Pain is felt if the thumb is adducted across the palm.

Trigger finger.— In this condition the tendon just distal to the constriction becomes swollen and can only be forced down through the constricted sheath by the powerful flexor muscle but the patient finds difficulty in extending the finger with rather weak extensor muscle. With continued effort he suddenly becomes successful in forcing the swollen tendon through the constricted sheath and as soon as it is done the finger becomes extended quickly and abruptly like a trigger of a pistol.

Carpal tunnel syndrome.— This condition is also an example of stenosing tenovaginitis. The only difference is that the cause is not only thickening of the flexor retinaculum but also some other pathology such as rheumatoid arthritis involving the synovial sheaths of the flexor tendons or dislocation of lunate bone which compresses on the contents of this osseo-fibrous canal, mainly the median nerve, also exits. The main complaint of the patient is some sort of difficulty in flexing fingers with pain and neurological deficits of the median nerve, e.g. paraesthesia or numbness or incoordination or weakness of the muscles innervated by median nerve. On examination, slight tenderness can be elicited on the carpal tunnel. There will be neurological signs along the distribution of the median nerve. Flexion movement of the fingers will be painful and conduction studies on the median nerve will demonstrate a delay at the carpal tunnel.

Dupuytren's contracture.— This condition mainly affects the palm and very occasionally the plantar fascia There is localized thickening and contracture of the palmar fascia. There may be nodules in the fascia or in the subcutaneous tissue indicating excessive fibrous tissue activity. This condition mostly affects the medial part of the palmar fascia in which the ring finger and less often the little finger become flexed. This is due to the fact that the extensions of the palmar fascia are attached to the proximal as well as middle phalanges.

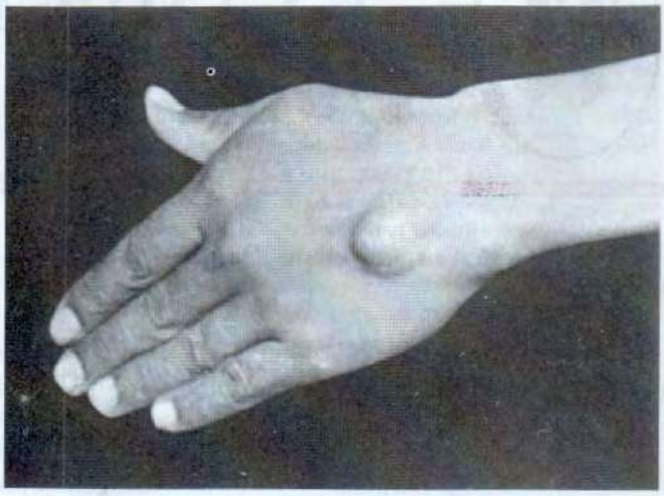

Fig.10.1.— A ganglion on the dorsal aspect of the wrist in relation with the extensor tendon of the finger.

The aetiology of this condition is not clearly known. Repeated trauma which was previously incriminated as the cause of this condition has been discarded due to the fact that it often involves the persons who do not inflict trauma so repeatedly in the palm. Its peculiar association with cirrhotic patients, epileptics who are having sodium hydantoin and Peyronie's disease add more to its intricacy.

On examination, there is thickening of the medial aspect of the palmar fascia with firm nodules within the fascia or in the subcutaneous tissue. The overlying skin is more or less fixed to the fascia and there is flexion deformity of the ring and the little fingers.

Ganglion.— This is a tense and cystic swelling containing gelatinous material in it. This mostly originates from the capsule of a joint or a tendon sheath. Tt may be due to a leakage in the capsule or the tendon sheath following trauma and subsequent encapsu-lation with fibrous tissue or it may be due to mucoid degeneration of the fibrous sheath. Ganglia are commonly seen on the dorsum of the wrist or the palm of the hand.

On examination, a tense and cystic swelling will be revealed in relation to a capsule of the joint or a tendon sheath. When it originates from a tendon sheath it can be moved sideways slightly but not at all along the length of the tendon particularly when the tendon is made taut.

Chapter

11 EXAMINATION OF DISEASES OF BONE

A bony lesion or a swelling is always fixed to the bone and cannot be moved apart from the bone.

HISTORY.—

1. **Age.**— Solitary cyst of a bone is seen in children upto the age of puberty and after that it becomes increasingly rare. Monostotic fibrous dysplasia, though rare, is chiefly a disease of adolescents but may remain symptomless till the bone breaks. Osteogenesis imperfecta (Brittle bones) congenita presents with multiple fractures, dwarfism and deformities since birth; whereas osteogenesis imperfecta tarda presents later near 10 years of age. Acute osteomyelitis is common in children. Tuberculous osteomyelitis may be seen at any age. Paget's disease (osteitis deformans) is a disease of old age. Nearly all benign bone tumours occur in adolescent and in young adults; Osteoclastoma occurs between 20 and 30 years of age. Primary malignant bone tumours mainly occur in young people; Osteosarcoma occurs between 15 and 30 years of age; Multiple myeloma occurs late — 30 to 50 years. Secondary carcinoma of bone is seen in old age above 40 years.



Fig.11.1.— Showing the characteristic sites of various types of bone diseases.

2. **Onset and progress.**— History *of trauma* is frequently obtained in many bone diseases particularly in acute osteomyelitis and osteosarcoma. *Spontaneous* development of swelling is most likely to be seen in cases of bone tumours. But even in these cases the patients may give a history of trauma, which has probably drawn the attention of the patient towards a small swelling which was so long unnoticed. *Acute onset* with high rise of temperature and toxaemia is a feature of acute osteomyelitis. In chronic osteomyelitis the onset is usually *insidious*, but acute exacerbation of chronic osteomyelitis is not uncommon. Malignant tumours *grow very rapidly* and the history is relatively short since the patient had discovered the swelling.

3. **Pain.**— Pain is always associated with inflammation. But in bone the peculiar feature is that the malignant growth *osteosarcoma* presents *with pain first and swelling later on.* Otherwise the tumours whether they are benign or malignant are painless to start with. One must note the **character** of the pain — whether it is *throbbing* (characteristic of inflammation) or

dull *aching* (characteristic of tumours in their late stages barring osteosarcoma).

4. **Duration.**— In acute osteomyelitis the duration is very short whereas chronic osteomyelitis resents healing for months and even years. In malignant bony tumours the duration is relatively short in comparison to the benign bony swellings.

5. **Sinuses.**— This may be present in chronic osteomyelitis either pyogenic or tuberculous. History of extrusion of bone chips strongly suggests pyogenic osteomyelitis.

6. **Similar swellings.**— An enquiry must be made if there is any similar swelling anywherelse in the body. In diaphyseal aclasis there will be multiple swellings arising from the metaphyses of different bones affecting a young boy.

7. **Past history.**— A past history of otitis media, pneumonia, typhoid fever, multiple boils etc. may be obtained in case of acute osteomyelitis.

8. **Family history.**— A few bony disorders run in families e.g. osteogenesis imperfecta congenita, achondroplasia, diaphysial aclasis, marble bone, cleido-cranial dysostosis, Marfan's syndrome etc.



Fig.11.2.— Shows a typical sinus following chronic osteomyelitis. Sprouting granulation tissue at the mouth of the sinus suggests presence of sequestrum underneath.

GENERAL SURVEY

(1) Anaemia, cachexia and malnutrition are come across in secondary carcinomas and a few primary malignant conditions of bone. (2) Toxic features with fever and malaise are noticed in acute osteomyelitis.

LOCAL EXAMINATION

INSPECTION.—

1. **Swelling.**— The swelling is examined as has been described in chapter 3. *All swellings arising from the bone will be fixed to it.*

2. **Skin overlying the swelling.**— In acute osteomyelitis the skin overlying the swelling will be red, oedematous and congested. In osteosarcoma the skin over the swelling remains tense, glossy with dilated veins. In tuberculous osteomyelitis cold abscess will lead to a swelling in the beginning and later on *sinus* formation. Chronic pyogenic osteomyelitis also presents with sinuses. The tuberculous sinus will reveal its characteristic features like undermined edge and bluish margin, whereas in chronic pyogenic osteomyelitis there will be sprouting granulation tissue which indicates presence of sequestrum at the depth. But both these sinuses will be fixed to the bone. Sometime there may be scar on the skin overlying the lesion. Depressed, puckered *scar* indicates previous suppuration and abscess formation.

3. **Pressure effects.**— It is always essential to have a look at the limb distal to the swelling. There may be oedema due to pressure of the bony swelling on the veins. There may be paresis due to involvement of the nerves by the bony swellings.



Fig.11.3.— Shows dilated subcutaneous veins in case of osteosarcoma.

4. **Neighbouring joints.**— Sympathetic effusion of the neighbouring joints is a common feature in acute osteomyelitis. Sometimes acute osteomyelitis may destruct the epiphyseal cartilage thereby hampering the growth of that particular bone. This may lead to deformities like manus valgus i.e. outward deviation of the hand due to the destruction of lower epiphysis of the radius and its deficient growth which is out grown by the normal development of the ulna. Genu valgum or genu varum may be the result of asymmetrical destruction of the lower epiphyseal cartilage of the femur. Deformed joints are also encountered in diaphyseal aclasis.

5. **Muscular wasting.**— This becomes prominent and obvious in probably one bony lesion i.e. tuberculous osteomyelitis.

6. **Shortening or lengthening of the bone** — may sometimes be seen following infection of the bone which either provokes the growth of the bone or destroys the epiphyseal cartilage and hence retards the growth of the bone.

PALPATION —

1. **Local Temperature.**— This is best palpated by the back of the fingers and local temperature is raised in acute pyogenic inflammatory conditions and in osteosarcoma.

2. **Tenderness.**— Inflammatory swellings are always tender. Tumours are generally non-tender.

3. **Swelling.**— It has already been emphasized that *all bony swellings will be fixed to the bone* and cannot be moved. Assessment must be made from which part of the bone the swelling has originated. The following points should be noted with details.

(i) *Situation.*— A swelling arising from the epiphysis is probably an osteoclastoma. Acute osteomyelitis, Brodie's abscess, tuberculous osteomyelitis, bone cyst, osteoma and osteosarcoma commonly start in the metaphysis. Ewing's tumour, multiple myeloma and syphilitic osteomyelitis are diseases of the diaphysis.

(ii) *Size* and *shape.*— A swelling, which is diffuse and very difficult to get at the margins probably due to extreme pain and tenderness, is an inflammatory swelling. Pedunculated swellings are generally exostoses. Spherical, ovoid and irregular swellings are generally tumours of the bone.

(iii) *Surface.*— Smooth and lobulated surface are features of benign growth. Irregularity are features of malignant growth and chronic infection.

(iv) *Edge.*— Ill-defined edge is the feature of inflammatory swelling and well-defined edge is the feature of new growth. As osteosarcoma is a very rapidly growing tumour it loses its well-defined edge.

(v) *Consistency.*— It is bony hard in osteoma. In osteoclastoma, the outer bony shell may be very thin as to yield or break during palpation ('egg-shell crackling'); otherwise when the outer covering is thick, it is also bony hard in consistency. In osteosarcoma the consistency varies — somewhere bony hard, somewhere firm and may be even soft at places. This is a diagnostic feature of osteosarcoma. In acute osteomyelitis, it will pit on pressure. Being a bony swelling its consistency should also be bony hard, but the condition is so painful and tender that the clinician hardly reaches the bone during palpation and can only palpate the soft tissues overlying the bone which pits on pressure.

(vi) *Pulsation.*— Is the swelling pulsatile? Some pathological condition of the bone may be pulsatile e.g. Telangiectatic osteosarcoma, aneurysmal bone cyst, occasionally highly vascular osteoclastoma, very rarely haemangioma of bone and highly vascular metastatic carcinomas from thyroid cancer and renal adenocarcinoma.

4. **Bony irregularity.**— A careful palpation of the affected bone is very essential. In chronic pyogenic osteomyelitis, syphilitic osteomyelitis and even tuberculous osteomyelitis the affected





Figs.11.4 & 11.5.— The patient is asked to dorsiflex both ankle joints. Note the foot drop on the right side due to involvement of the lateral popliteal nerve by an osteoma at the head of the fibula.

bone may be irregular. This irregularity will also be present in Brodie's abscess.

5. **Ulcers and sinuses.**— Whenever there is an ulcer or a sinus, it is good practice to hold the base of the ulcer or the sinus and to move it against the bone. Fixity to the bone indicates its relation with the bony lesion. These are commonly seen in chronic pyogenic osteomyelitis and tuberculous osteomyelitis. In case of the former there will be sprouting granulation tissue at the orifice of the sinus indicating presence of sequestrum in the depth and in case of the latter the ulcer will be undermining with bluish newly growing epithelial edge.

6. **Presence of fracture.**— Not infrequently patients with metastatic carcinoma present with pathological fracture. In fact sometimes this fracture becomes the first presenting symptom of the primary carcinoma which may be in the lung, kidney, breast, prostate, thyroid etc.

7. **Neighbouring Structures.**— While examining a case of bony lesion one must examine the neighbouring structures, i.e. the muscles — their power and mobility over the bony lesion, the nerves and the blood vessels. These structures may be involved by the lesion.

PERCUSSION.— Localized tenderness of chronic osteomyelitis, Brodie's abscess etc. may be well elicited by percussion. In case of spine and pelvis this can be elicited by gently striking with a fist.

AUSCULTATION.— In case of pulsatile swellings, this examination will be required to detect the presence of a murmur and to note its character.

MEASUREMENTS.— (i) *Length of the long bone.*— In osteomyelitis the bone may be shortened

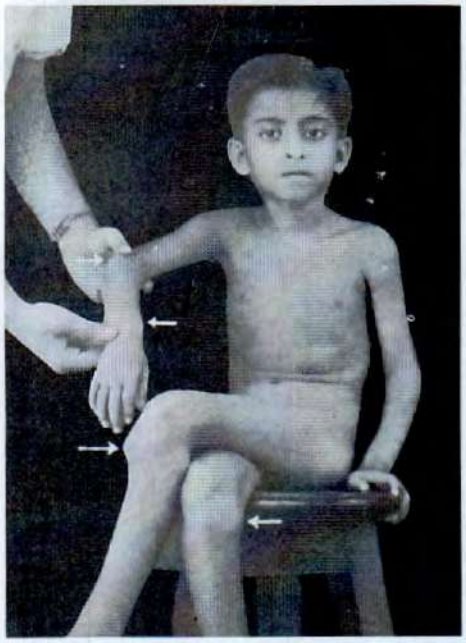

Fig.11.6.— Diaphyseal (metaphyseal) aclasis. Arrows indicate the exostoses.

or lengthened. Shortening will be found when the epiphyseal cartilage is destroyed and the bone may be lengthened when the metaphysis is included within the zone of hyperaemia. (ii) *Circumference of the limb* is measured if muscular wasting is suspected.

Examination of the neighbouring joints.— The neighbouring joints may be sympathetically effused in acute osteomyelitis. Osteoclastoma generally starts in the epiphysis and may involve the joint. Osteosarcoma, which mainly starts from the metaphysis, does not invade the epiphyseal cartilage until late and hence the joint remains unaffected.

Examination of the lymph nodes.— See Chapter 8.

Pressure effects.— Different swellings of the bone may press on the neighbouring blood vessels and the nerves to cause respective symptoms. Swellings of the distal limb and venous engorgement may be due to pressure on the neighbouring veins. Nerves may also be affected due to pressure effect of the bony swellings and 'foot drop' due to paralysis of the external popliteal nerve may be seen in case of a tumour of the upper end of the fibula.

GENERAL EXAMINATION



Fig.11.7.— Chronic osteomyelitis.



Fig.11.8.— Brodie's abscess.



Fig.11.9.— Bone cyst. Note that the expansion occurs along the long axis of the bone (cf. osteoclastoma).

1. In tuberculous osteomyelitis general examination must be made to exclude pulmonary tuberculosis and lymphadenitis. Enquiry must be made whether the patient had cough, evening rise of temperature, pain in the chest, haemoptysis, etc. Neck, axilla and groin must be palpated to exclude lymph node enlargement.

2. In syphilitic osteitis, one should look for other syphilitic stigmas in the body (See Fig.4.15). One must try to elicit the history of syphilitic contact.

3. In osteomyelitis a search should be made for infective foci in the skin, tooth, tonsil, ear, air sinuses, etc.

4. Certain bony lesions involve more than one bone at a time. Diaphyseal (metaphyseal) aclasis, generalized osteitis fibrosa, multiple myeloma are the examples of this condition. So the patient must be asked if there is any other bony swelling in his body or not.

5. In secondary carcinoma a thorough examination must be made to exclude primary carcinoma in the thyroid, kidneys, lungs, prostate, breasts, uterus, gastrointestinal tract, testis, etc.

SPECIAL INVESTIGATIONS

1. **BLOOD.**— (a) Leucocytosis is the feature of bony inflammation, particularly acute osteomyelitis. (b) In multiple myeloma the serum calcium level will be raised. There will be hyperproteinaemia, the globulin (particularly gamma globulin) being raised. (c) A rise in serum calcium indicates generalized osteolysis (which is seen in cases of hyperparathyroidism, metastatic bone tumours, multiple myeloma, sarcoidosis etc.). (d) A rise in serum alkaline phosphatase suggests osteoblastic activity as occurs in osteitis deformans and some sarcomas. (e) Higher level of serum acid phosphatase serves to distinguish prostatic metastasis in bone from other skeletal metastasis. (f) Reduced serum phosphorus and increased alkaline phosphatase with high E.S.R. are seen in osteomalacia. (g) W.R. and Kahn tests will be positive in cases of syphilitic osteitis.

2. **URINE.**— (a) Albumin may be present when amyloid disease has affected the kidneys in long continued suppuration as in osteomyelitis. (b) Presence of Bence Jones protein (a globulin) can be demonstrated in the urine of the patient by appearance of coagulation when the urine is heated to 55° C, its disappearance by further heat to 80°C and its reappearance again on cooling. But this appears in only 50% of multiple myeloma cases. Bence Jones protein may also be found in cases of skeletal carcinomatosis, leukaemia and rarely in nephritis.



Fig.11.10.— Osteoma at the lower end of the tibia.

3. **X-RAY EXAMINATION.**— It goes without saying that this examination is probably the most important special investigation, which clinches the final diagnosis. X-ray examination of the affected bone will reveal local pathology, whereas that of the other bones will reveal generalized involvement of the bones.

(A) **Affected Bone.**— In the first instance it must be noticed whether the bone is rarefied (i.e. of reduced density) as is often seen in tuberculous affection or is sclerosed (i.e. of increased density) as seen in syphilis, Paget's disease, marble bone or chronic osteomyelitis (sequestrum or involucrum).



Fig.11.11.— Exostosis at the upper end of the humerus.

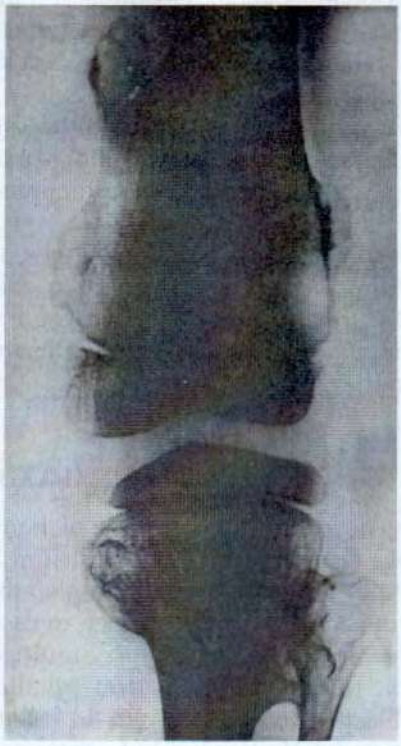

Fig.11.12.— Multiple exostoses are seen in diaphyseal aclasis.

In *Osteomyelitis*, it must be remembered that there is practically no place of X-ray examination in acute cases and diagnosis must be made clinically. In chronic osteomyelitis, a dense sequestrum and surrounding involucrum may be noticed. Density of the sequestrum is due to decreased mobilization of calcium from decreased blood supply, whereas in involucrum calcium deposition has just commenced.

In *Brodie's abscess* an osteolytic cavity will be seen surrounded by dense or sclerosed bone. There is hardly any sequestrum inside the cavity. Similar cavity is

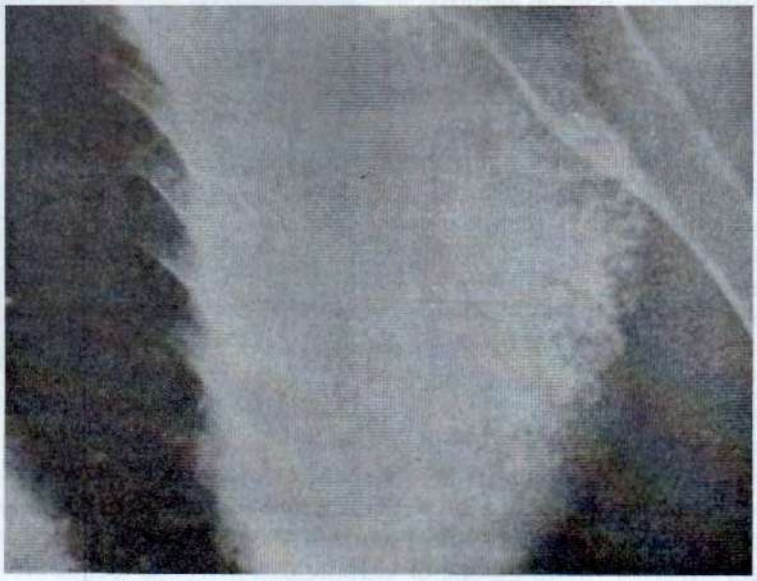

Fig.11.13.— A huge osteochondroma.



Fig.11.14.— Osteoclastoma affecting the lower end of the ulna. Note that the expansion occurs transversely (cf. Bone cyst).



Fig.11.15.— Chondroma at the lateral aspect of the knee joint. This is revealed in X-ray by an osteolytic lesion affecting the lateral condyle of the tibia (indicated by an arrow).



Fig.11.16.— Osteosarcoma showing the typical radiating spicule type.

seen in *bone cyst*, but surrounding sclerosis is conspicuous by its absence.

An *osteoma* is seen as a pedunculated bony outgrowth from the metaphysis. The growth of the osteoma continues so long the bone grows in length.

Osteoid osteoma is seen as a radiolucent nidus with a surrounding zone of bony sclerosis.

In *diaphyseal aclasis* multiple exostoses are seen.

In *chondroma*, whether enchondroma or ecchondroma, X-ray shows an osteolytic lesion with demarcated outline.

X-ray features of ***osteoclastoma*** are characteristic. The metaphysio-epiphyseal areas are seen to be enlarged and occupied by a cystic tumour. The cortex is thin with a sharp line of demarcation between the tumour and the unaffected shaft in contradistinction to the sarcomas. The expanding osteolytic lesion can continue to destroy the cortex, although usually it leaves some external rim. The cavity is traversed by bony trabeculae giving mosaic or soap-bubble appearance. Mostly the tumour grows eccentrically, often destroys the epiphyseal cartilage and it may penetrate the articular cartilage. Pathological fractures may occur. This tumour expands transversely whereas a bone cyst expands along the long axis of the bone.

X-ray appearance of ***osteosarcoma*** shows a combination of bone destruction and bone formation. The tumour has an ill-defined junction with the rest of the shaft. Three types are commonly seen — (i) Sclerotic type, usually found at puberty, shows dense new irregular bone with a few spicules projecting from its surface in the metaphysis. (ii) Osteolytic type shows an



Fig.11.17.— Osteochondroma.

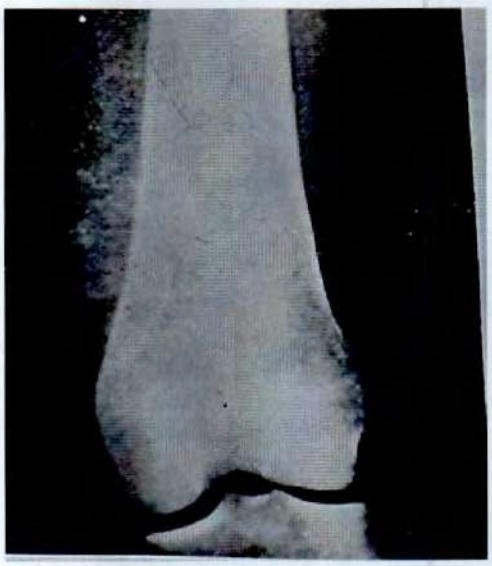

Fig.11.18.— Osteosarcoma affecting the lower end of the femur with typical sun-ray appearance.

eccentric translucent gap and at its edges a gradual increase of density compared to that of the normal bone is seen. (iii) The radiating spicule type. The cortex is almost always perforated. A small wedge-shaped area of ossification (Codman's triangle) is seen at the spot where the periosteum is elevated from the shaft. The periosteum may show sun-ray spicules due to calcification along the blood vessels supplying the raised periosteum. As the tumour spreads into the soft tissues its outline becomes indefinite. In bone sarcoma there is always the soft tissue shadows in the skiagram due to increased vascularity of the tumour.

Chondrosarcoma in skiagram shows frank destruction of the trabecular bone and cortex with an expanding lesion which contains irregular flecking and the mottling of calcified tissue. There may be new bone formation which extends outward.

Ewing's tumour grows from the diaphysis. There is widespread diffuse rarefaction with subperiosteal deposition of bone longitudinally — the so-called 'onion effect'.

X-ray is not reliable for early detection of ***secondary carcinoma*** in the bones. At least 50% of medulla must be destroyed before a lesion will be seen radiologically. Tomograms are more sensitive. Osteolysis without formation of new bone is the feature except in carcinoma of the prostate where osteosclerosis is observed. This is due to high level of alkaline phosphatase.



Fig.11.19.— Ewing's tumour affecting the femur.

(B) **X-ray examination of the other bones** should be taken in generalized affections of bones.

In ***Ricket***, X-ray will show general decalcification. The epiphysis is widened with delay in appearance of centres of ossification. The growth discs are too deep. The metaphysis is splayed out.

In ***Paget's disease*** the bone as a whole is thick and bent; its density in the vascular stage is decreased and in the sclerotic stage increased. The trabeculae are coarse and widely separated. This gives honey-comb appearance. Striated appearance is seen in the pelvis, sacrum and calcaneum. True cystic areas can be seen in the pelvis or long bones.

In ***Osteitis fibrosa (Hyperparathyroidism; Von Recklinghausen's disease)*** skiagram shows a mixture of osteoporosis, cystic changes and coarsening of the trabecular pattern. Cysts may extend beyond the confines of the long bones and there may be subperiosteal erosions of the cortex. There may be even disappearance of the terminal outline with only longitudinal trabeculae remaining.

In ***Multiple myeloma*** circumscribed areas of rarefaction affect the different bones, which may mimic secondary metastasis.

(C) **Lungs** must be X-rayed to exclude secondary deposits in the lungs in cases of osteosarcoma, chondrosarcoma, fibrosarcoma or suspected malignant osteoclastoma.

4. **ARTERIOGRAPHY.**— The changes of the character of the blood vessels supplying the tumour vary characteristically in all malignant tumours. The vessels become aimless, tortuous and engorged. Sometimes they end abruptly or terminate in pools of contrast which empty slowly. Early venous filling is also seen. But the most important feature is the presence of *'Contrast blush'*, which delineates the extent of the tumour. All these features may not be present simultaneously in all primary malignant tumours, but one or the other change will be obvious. But there are fallacies, e.g. a few malignant tumours do not show the characteristic arteriographic changes. Conversely some benign osteoclastomas can show these features. But there are two distinct places where its value is undebatable — (i) to define the extent of the tumour and (ii) to detect malignant change in Paget's disease, which may be difficult on an ordinary X-ray film.

5. **RADIOACTIVE SCANNING.**— This method depends upon the relatively high uptake of the radio-isotope in areas of bone with high mineral turnover and reflects the metabolic state of the bone. It can indicate the presence of local infection in the same fashion as a primary or metastatic bone tumour. So the scan reflects the metabolic process and a change in mineralisation. Thus positive bone scan is seen before X-ray changes. *Only very anaplastic tumours and quiescent, long-standing lesions fail to show positive results.*

Scanning is performed 1-4 hours after the intravenous injection of 5-10 mci of 99 Tcm-phosphates complex. The patient must empty his bladder before the pelvis is scanned as about 40% of the injected dose is excreted in the urine within first 4 hrs. after injection.

The gamma camera detects, records and displays the activity within its total field of view (about 25 cm diameter). Using a gamma camera and taking multiple overlapping views, it can detect a far greater number of counts leading to much better statistical quality than the whole body scanner in a similar time. The great potential value of bone scanning lies in its ability to detect early active lesions in bone before they are visible on X-ray. It might possibly be of value in clinical practice in the early detection of primary osteosarcoma, although usually they are already clearly visible on X-ray when the patient is first seen. But it is probably more valuable in detecting bone secondaries to know the spread of the disease, suitability of radical operation, differentiation between simple and pathological fracture, to find out the site suitable for biopsy and for staging reticulosis. It has been claimed that some 20% bone secondaries which are not visible on X-ray could be detected by radio-isotope scanning.



Fig.11.20.— Secondary carcinoma affecting the shaft of the humerus which leads to pathological fracture.

6. **BIOPSY.**— To know the exact pathology of the bony lesion, biopsy is very essential. It gives a clear picture of the disease and the cellular pattern. It is essential in all cases, for one cannot with certainty make the diagnosis on clinical or radiological ground alone. The only exception to this can be in Paget's sarcoma in the elderly, when the signs and X-rays alone may occasionally suffice, *Open biopsy* is still the popular method. The risk of dissemination which was supposed to be great, is now found to be absolutely theoretical. To give clear decision on frozen section biopsy is difficult and only a few institutions in the world can have the privilege to get pathologists of that grade. There is hardly any place of prophylactic small dose irradiation before taking biopsy. *Aspiration biopsy* though unrivalled in surgically difficult regions such as spine (where open biopsy is not possible), biopsy of limb tumours by means of wide-bore needle has never become popular in this country. This is partly due to reluctance on the part of pathologists to give opinion on small cores of tissues. *Marrow biopsy* is helpful in diagnosing multiple myeloma in which numerous plasma cells will be present.

7. **Bacteriological examination** of the pus obtained by aspiration in cases of acute osteomyelitis is of immense value to determine the causative organism and the most effective antibiotic by sensitivity test. Blood culture may be of use when septicaemia is suspected.

8. **Histopathological examination** of the tumour, either from *biopsy* or from curettage as done in osteoclastoma and bone cyst, is of great value in determining the diagnosis and to exclude possibility of malignant change. *Marrow biopsy* should be performed in case of multiple myeloma which reveals presence of numerous plasma cells.

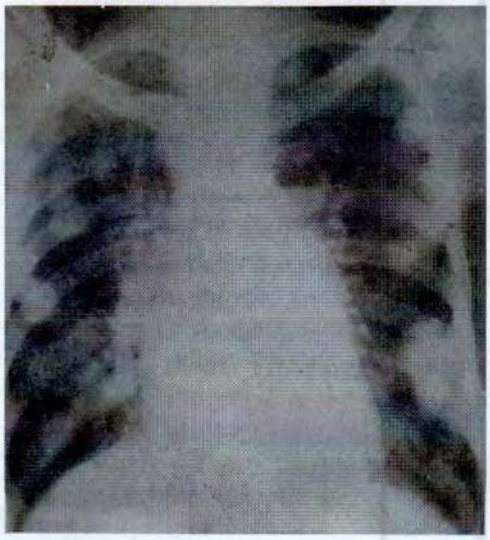

Fig.11.21.— Secondary deposits in the lungs (Canon ball metastasis) in a case of osteosarcoma.

CLASSIFICATION OF BONY SWELLINGS

A. **Traumatic.**— (i) Excess of callus formation from fractured bone; (ii) Malunited fracture; (iii) Myositis ossificans; (iv) Subperiosteal haematoma and its ossification.

B. **Inflammatory.**— (i) Acute osteomyelitis; (ii) Chronic osteomyelitis; (iii) Brodie's abscess; (iv) Typhoid osteomyelitis; (v) Tuberculous osteomyelitis; (vi) Syphilitic osteitis; (vii) Pneumococcal osteomyelitis.

C. **Developmental disorders.**— (i) Achondroplasia; (ii) Osteogenesis imperfecta (Brittle

bone); (iii) Mucopolysaccharide disorders : (a) Morquio-Brailford disease; (b) Hurler's disease; (c) Hunter's disease etc.; (iv) Diaphyseal aclasis (Multiple exostoses); (v) Multiple chondromas (Ollier's disease); (vi) Marble bones (Osteopetrosis); (vii) Candle bones, Spotted bones and striped bones; (viii) Cleido-cranial dysostosis; (ix) Fibrous dysplasia.

D. **Nutritional, metabolic and endocrinal disorders.**— (i) Rickets; (ii) Osteomalacia; (iii) Scurvy; (iv) Hyperparathyroidism (Von-Recklinghausen's disease); (v) Osteoporosis.

E. **Malformation syndromes.**— (i) Nail-Patella syndrome; (ii) Marfan's syndromes; (iii) Paget's disease (osteitis deformans).

F. **Cyst.**— (i) Solitary cyst; (ii) Cyst associated with generalized osteitis fibrosa; (iii) Hydatid cyst; (iv) Aneurysmal bone cyst.

G. **Tumours.**— (a) *Benign tumours.*— (i) Osteoma; (ii) Osteochondroma; (iii) Osteoblastoma; (iv) Osteoid osteoma; (v) Chondroma; (vi) Chondroblastoma; (vii) Periosteal fibroma; (viii) Fibroma; (ix) Chondromyxoid fibroma; (x) Haemangioma; (xi) Lipoma; (xii) Neurofibroma.

(b) *Locally malignant.*— Osteoclastoma (Giant cell tumour).

(c) *Malignant.*— *Primary* — (i) Osteosarcoma; (ii) Chondrosarcoma; (iii) Ewing's tumour; (iv) Multiple myeloma; (v) Reticulum cell sarcoma; (vi) Plasmacytoma; (vii) Fibrosarcoma; (viii) Liposarcoma; (ix) Angiosarcoma.

Secondary Carcinoma of bone by (i) primary carcinomas metastasis from thyroid, bronchus, breast prostate, kidney, uterus, gastrointestinal tract, testis etc.; or by (ii) direct infiltration from adjacent growth e.g. Carcinoma of the tongue involving the lower jaw.

DIFFERENTIAL DIAGNOSIS

Acute osteomyelitis.— The patients are usually children and the bones are affected mainly in the metaphyseal region. Generally the children of the first decade are involved by this disease and the incidence considerably comes down after the age of twelve. The symptoms and signs can be both local and general.

High pyrexia, intense toxaemia with high pulse rate and leucocytosis are the general signs found in acute fulminating type of osteomyelitis. In chronic type, which is commoner in the adult, there will be malaise, fever, headache and backache.

Locally there will be swelling, extreme tenderness, local erythema, limitation of joint movement and effusion of the nearest joint (10% of cases). Later on, subperiosteal pus may find its way superficially and then fluctuation test will be positive. In more chronic cases the pus will find its way out through a sinus and may lead to chronic osteomyelitis.

Polymorphonuclear leucocytosis is constant with raised E.S.R. Pus may be sent for culture and sensitivity tests. It must be emphasised that radiography, which plays an important role in the diagnosis of bone diseases, is practically valueless in the detection of early stage of this condition.

COMPLICATIONS.— A. *General.*— Toxaemia and Septicaemia. B. *Local.*— (i) Suppurative arthritis when the metaphysis is included partly or wholely within the joint; (ii) Deformity — either shortening or lengthening of the limb due to destruction or better nourishment to the epiphyseal cartilage; (iii) Pathological dislocation when the joint is very much involved and destroyed.

This condition is mainly diagnosed on clinical examination. Superficial oedema, localized swelling, temperature, extreme tenderness with general signs of toxaemia will tell the diagnosis by themselves.

The clinician must *differentiate this condition from* (i) *Rheumatic fever,* in which the joint pain

is flitting in nature and the tenderness is maximum at the joint line and (ii) *Acute suppurative arthritis* in which again tenderness is mostly found in the joint line with great effusion and tremendous pain affecting the joint.

Chronic osteomyelitis.— This condition is actually an aftermath of acute osteomyelitis. A piece of bone becomes dead (Sequestrum) and remains within the cavity which is formed by destruction of the bone due to the infection. This cavity is generally connected outside through a sinus. The cavity contains serous fluid and pus, which may be discharged through the sinus. The mouth of the sinus shows sprouting granulation tissue, which indicates presence of the sequestrum in the depth. On palpation, the bone becomes thick and irregular. X-ray shows areas of bony rarefaction surrounded by dense sclerosis and sometimes sequestrum within the cavity of the bone. In long standing cases amyloid degeneration may occur.

Brodie's abscess.— It is a localized form of infection, which is usually situated at the metaphysis of the long bone. This condition is usually caused by the staphylococcus of low virulence. The patients are usually between 10 to 20 years of age. The commonest sites are the upper end of the tibia, the lower end of the femur, the lower end of the tibia and the upper end of the humerus according to the frequency. This condition may remain silent for years or present with recurrent attacks of pain. During an attack the bone becomes tender with a little swelling. Typically the pain becomes worse at night, but in some instances it is worse on walking and relieved by rest. Skiagram shows translucent area with a well defined margin and surrounding sclerosis, beyond which the bone looks normal.

Typhoid or pneumococcal osteomyelitis.— This condition is very rare now-a-days. It may occur during the later period of prolonged suffering from this disease or may even occur months or years after one has suffered from this disease. The disease runs a mild course with poor bone formation which is observed in X-ray. Diagnosis is mainly confirmed by clinical observations, but discovery of causative organisms in the pus collected by aspiration wipes away any suspicion about the diagnosis.

Tuberculous osteomyelitis.— This condition is also becoming rare day by day. The ends of the long bones and short bones of the hand and foot are usually affected. The onset is insidious and may remain silent. Swelling and pain of the affected area of the bone, sympathetic effusion of the neighbouring joint, formation of the cold abscess and sinus with under-mining edge are the clinical features of the condition. X-ray shows rarefaction of the affected bone with bone destruction i.e. thinning and disappearance of the bony lamellae and cavity formation. Recalcification occurs at the healing stage.

Syphilitic osteomyelitis.— It is another rare condition and manifestation of the tertiary stage of syphilis. Mainly the subcutaneous bones are affected e.g. the tibia, sternum, clavicle, skull, ulna etc. The pathology may be either diffuse periostitis or localized gumma. The patient experiences a deep boring pain particularly at night. The gumma may soften and break down to form a typical syphilitic ulcer. X-ray shows periosteal thickening or punched out translucent areas in the midst of dense sclerosis. The lesions are often multiple. Positive W.R. and Kahn tests reiterate the diagnosis.

Achondroplasia.— This is an autosomal dominant inheritant disease. The cartilage cells produced by the epiphysis fail to line up properly and undergo degeneration. The individual becomes dwarf with normal intelligence and often with excellent muscles. The limbs are grossly short, particularly the proximal segments, so that the hands fail to reach the buttocks. The spinal canal becomes narrow. The X-ray shows relative shortness of the limb-bones. The metaphyses at the knee are splayed out. The pelvis is too small for normal delivery.

Osteogenesis Imperfecta (Brittle bones).— There are two types of this condition: (i) *Congenita*

(of recessive inheritance) — reveals itself soon after birth with dwarfism, deformities and multiple fractures. (ii) *Tarda* (of dominant inheritance) — reveals itself later in life nearing puberty. Both these conditions present with broad skull (with Wormian bone), blue sclera, scoliosis, ligament laxity, coxa vara, knock knee, bowing of the femur and the tibia etc. X-ray shows marked osteoporosis with cystic appearance. The shafts of the long bones are bent and slender. Multiple fractures are frequently associated with this condition which may lead to tremendous periosteal reaction with hyperplastic callus formation which may mimic a bone sarcoma.

Mucopolysaccharide disorders.— These include a group of conditions with in-born defects in mucopolysaccharide metabolism. Dwarfism is again the main feature of these conditions. The three common diseases which are included in these disorders are :

(i) Morquio-Brailsford disease, which is manifested by too flat vertebrae, grossly distorted hip, marked ligamentous laxity and presence of Keratan sulphate in urine.

(ii) Hurler's disease, which is manifested by early mental retardation, absence of ligament laxity, cardiopulmonary complications and presence of dermatan sulphate and heparan sulphate in urine.

(iii) Hunter's disease, which is a X-linked recessive inheritant disease, more or less similar to Hurler's disease in its manifestations.

Multiple exostoses (Diaphyseal aclasis).— This is an autosomal dominant inheritant disease with failure of bone remodelling, in which excess of the metaphyseal bone is not absorbed and forms irregular exostoses, Multiple lumps (Fig. 11.6) are found on the upper humerus, lower ends of the radius and ulna, around the knee joint, above the ankle and very occasionally on flat bones. Some deformities and complications may be expected from these exostoses. X-ray shows presence of sessile or pedunculated exostoses projecting from the surface.

Multiple Chondromas (Ollier's disease).— This rare disease is not familial like the previous conditions. The main defect is the ossification of cartilage at the growth discs. One limb or even one bone may be involved in this condition. The affected limb becomes short. The fingers and toes frequently contain multiple enchondromata, which are characteristics of this condition. Malignant change may be seen in 1% of these chondromata. X-ray shows multiple translucent islands mainly in the metaphyses of the long bones and diaphyses of the short bones.

Cleido-Cranial dysostosis.— This autosomal dominant inheritant condition mainly affects the membrane bones, chiefly the clavicles and the skull. The patient is somewhat short, with a large head and drooping shoulders. Because the clavicles are partly absent, the two shoulders of the patient can be brought in front of the chest (Fig. 11.22). X-ray shows non-development of outer half of each clavicle. Wormian bones may be present in the skull.



Fig. 11.22.— Shows a typical case of cleido-cranial dysostosis. The shoulders can be easily brought in front of the chest.

Fibrous dysplasias (fibrocystic disease).— It is the last and probably the most important in the group of developmental disorders. The condition may affect one bone (Monostotic), one limb

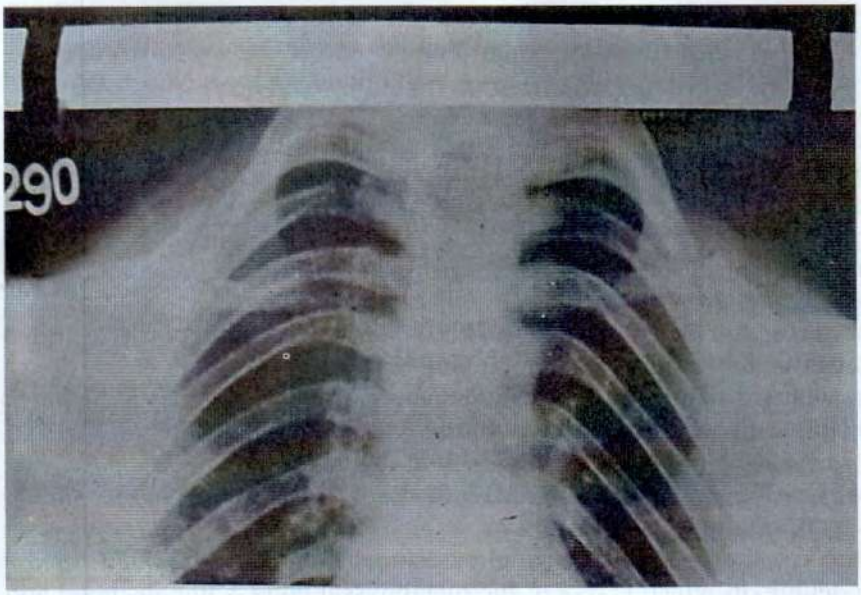

Fig.11.23.— X-ray picture of the patient shown in Fig.11.22. Note that the outer half of the clavicle has not been developed.

(Monomelic) or many bones (Polyostotic). A solitary bone cyst is the commonest. In all varieties the cellular fibrous tissue in the medullary cavity proliferates destroying the trabecullae; the bone may be expanded and the cortex may be eroded. The resulting cavities contain fluid or fibrous tissue and the walls contain giant cells.

Solitary cyst.— This usually affects the upper humerus, femur or tibia, but may occur in other bones. Usually the victims are children upto the age of puberty, after which this condition becomes increasingly rare. This disease presents with local pain, slight swelling with or without tenderness. Very rarely a

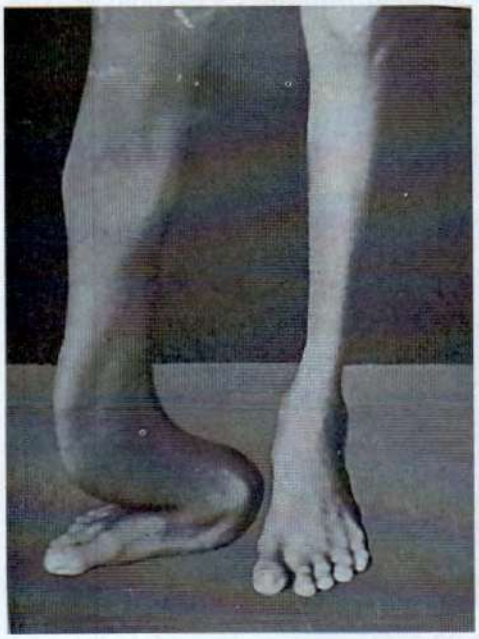



Figs.11.24 & 11.25.— A typical case of monostotic fibrous dysplasia. In Fig.11.25 note the presence of multiple cysts and fibrous bands to give the typical picture of bubbles and stripes.

pathological fracture may complicate this condition. X-ray shows a translucent area at the metaphysis. The bone becomes expanded and the cortex is thinned out. The cyst has a clear cut edge without any surrounding sclerosis.

Monostotic fibrous dysplasia.— This rare condition occurs chiefly in adolescents and remains symptomless until the bone breaks. The lamellar pattern of the affected bone is replaced by multiple cysts and fibrous bands which may be calcified to give the X-ray appearance a mixture of "bubbles and stripes" (See Figs. 11.24 & 11.25).

Polyostotic fibrous dysplasia.— The long bones are generally affected either in one limb or in one half of the body or scattered throughout the skeleton. The patients present with deformity, irregular bony swellings, pain or fracture. X-ray shows cystic areas with patches of calcification in the shaft of the bone. The short bones may show uniform ground-glass appearance. The skull may be irregularly thickened. Otherwise the bones are normal and not osteoporolic as seen in cases of hyperparathyroidism.

Albright's disease is a combination of polyostotic fibrous dysplasia, pigmentation in the skin and sexual precocity in girls.

Rickets.— This condition occurs due to insufficient Vitamin D, which results from inadequate diet or insufficient exposure to sun light. Because of lack of Vitamin D, calcium and phosphorus absorption is reduced. Compensatory parathyroid secretion increases, calcium is not deposited in bones and may even be withdrawn. The growth disc produces abandant cartilage but this is not converted to bone. Growth becomes retarded and the soft bones bend. There are various types of rickets, of which the infantile ricket is the commonest.

Infantile ricket.— This condition is common in infants below 4 years of age. The limbs show enlargement of the bone ends with deformities due to bending of the soft bones. The soft bones may crack by trivial injury. The skull is bossed ('Hot-cross-bun head'), dentition becomes delayed and the costochondral junctions are enlarged (rickety rosary). There may be kyphosis. X-ray shows general decalcification. The growth discs are too deep and the metaphyses are too wide.

Renal ricket.— In this condition the kidneys are unable to excrete phosphorus properly due to developmental defect of the renal tubules or some organic disease affecting the kidney. The blood phosphate level increases and the excess phosphorus is excreted in the gut where it combines with calcium, so the serum calcium level falls and consequently excess of parathormone is secreted resulting in the rickety condition. Again the children are more often affected. They become dwarf and anaemic. X-ray changes are similar to those of infantile rickets.

Renal tubule ricket.— In this condition the glomeruli excrete phosphorus, but the tubules fail to reabsorb resulting in a fall in serum phosphorus level. Consequently serum calcium increases, calcium being withdrawn from the bones. The children become dwarf with polyuria. Presence of sugar, aminoacid and cystine in the urine helps to make the diagnosis. X-ray changes are more or less similar to those of infantile ricket.

Osteomalacia.— This condition is the adult counterpart of the ricket. The bones lose calcium due to gross malnutrition either in pregnancy or after gastrectomy or after prolonged treatment with anticonvulsants. The patients present with general ache specially at the back. Muscle tenderness is common. Weakness is felt on walking for a distance and more so while climbing up the stairs. X-ray shows loss of bone density with characteristic bands of translucency, called Looser's Zones, particularly seen in the upper humerus, femoral neck, ribs, pubis etc. The serum alkaline phosphatase is increased and the serum phosphorus level becomes reduced. The sedimentation rate of the erythrocytes is also raised. Diagnosis becomes confirmed by generalized osteoporosis and may require bone biopsy which shows excessive uncalcified osteoid tissue.

Hyperparathyroidism (Von Recklinghausen's disease).— In this condition, oversecretion of the parathormone is the main pathology commonly associated with parathyroid adenoma. The kidneys excrete excess phosphorus which lowers the serum phosphorus level. To restore the calcium-phosphorus balance, calcium is withdrawn from the bone raising the serum calcium level. This may lead to formation of renal calculi. Adults are mainly affected and women outnumber men in this condition. The patients present with aches all over which may make the patient bed-ridden. The bones may bend and fractures are not uncommon. X-ray shows osteoporosis with cystic changes in the medulla and the trabecular pattern becomes coarse. The skull becomes granular and ground-glass. Sub-periosteal erosions of the cortex are common. In the hand, disappearance of the outline with presence of only longitudinal trabecullae in the phalanges, are the characteristic features.

Osteoporosis.— This is the response of the bony skeleton to a variety of factors — (i) *Mechanical factors* are those of prolonged immobilization of the part concerned, anterior poliomyelitis, rheumatoid arthritis and paraplegia. (ii) *Nutritional factors* in the form of severe protein deficiency resulting from malnutrition or failure in absorption or abnormal protein excretion may lead to osteoporosis. Senile osteoporosis may be included in this group. Scurvy due to vitamin C deficiency is also an example of this group. (iii) *Endocrinal factors* include Cushing's syndrome, hyperparathyroidism, ovarian insufficiency which leads to postmenopausal osteoporosis, thyrotoxicosis etc. (iv) *Miscellaneous* factors, which include myelomatosis, tumour invasion etc.

Most of the patients, who present with osteoporosis, are included in the senile or postmenopausal group. The main complaints are general aches which are aggravated by movement or jarring. Sudden onset of pain with localized tenderness is suggestive of pathological fracture. Thoracic kyphosis is a common accompaniment of this condition. X-ray shows ground glass appearance with loss of definition of the trabecullae in the different bones. The vertebral bodies become flattened with increase in the intervertebral spaces. Varying degrees of collapse and wedging may be seen. Healing of the pathological fracture is usually accompanied by little callus formation. Biopsy may be taken by trephining the iliac crests or the spinous processes. This is significant so far as the diagnosis is concerned. This shows a reduction in the number and size of the trabecullae and in the number of osteoblasts present.

Marfan's syndrome.— This is an autosomal dominant inheritant disorder with a defect in elastin or collagen formation or both. The patients are usually tall with scoliosis, the limbs are unduly long specially the distal segments. The fingers become long and narrow, which are called arachonodactyly (spider fingers). Other features include a high arched palate, presence of hernias, dislocation of ocular lens and aortic aneurysm. If this condition is associated with presence of homocystine in the urine a condition called *"homocystineuria"* should be thought of. This condition is more or less similar to Marfan's syndrome except for the fact that this condition is of autosomal recessive inheritance.

Paget's disease (Osteitis deformans).— The main pathology of this condition is high rates of bone resorption and formation. Resorption of the existing bone is brought about by the osteoclasts and bone formation is performed by the osteoblasts. The first stage is the vascular stage when the spaces left by bone absorption are filled with vascular fibrous tissue. On both sides of the cortex new osteoid tissue forms but this is not converted to mature bone, so the bone becomes thick but soft and bends under pressure. The second stage is the sclerotic stage in which the new lamellae are formed which become thick and sclerosed, so that the bone can be broken easily.

The disease is rare under the age of 40 and becomes progressively commoner as the age

advances. Males are more often affected and even the disease may be localized to a part or whole of one bone for many years. The pelvis and the tibia are the commonest sites. The femur, skull, spine and the clavicle are next involved. When a single bone is affected, the pain is the most important symptom. Its character is dull and constant ache, which becomes worse at night. The affected bone may be bent. Pain becomes severe when the condition is complicated by fracture or sarcoma. On palpation the bone feels thick and looks bent. The overlying skin becomes unduly warm. In case of generalized involvement, the patients present with headache, deafness, limb pain, pathological fractures, deformities and even heart failure. The skull enlarges and otosclerosis is the cause of deafness; occasionally pressure on the optic nerve may produce blindness. There is considerable kyphosis. Backache and root pain are not uncommon. A slight coxa vara may be expected with considerable anterolateral bowing of the legs.

X-ray shows that the bone involved becomes thick and bent. The normal clear line of demarcation between the cortex and the medullary cavity becomes blurred. The trabecullae are coarse and widely separated giving rise to a honeycomb appearance. In the vascular stage areas of osteoporosis may be expected in different parts of the cortex. Later on, the cortex becomes thick and the whole bone is bent. Fine sub-periosteal cracks may be seen if carefully noted. In the special investigations, very high alkaline phosphatase and hydroxyproline in the plasma are noted features. Hydroxyproline is also excreted in the urine in high quantity. But the serum calcium and phosphorus levels remain within normal limits.

COMPLICATIONS include general and local complications. Of the *general complications*, high rate of cardiac failure, deafness, optic atrophy and paraplegia are worth mentioning. Of the *local complications* pathological fracture and osteosarcoma are very important. The frequency of osteosarcoma may vary from 1 to 10% (average is 5%). This condition is suspected if the patient already suffering from Paget's disease, complains of more pain, tenderness and swelling of a particular region. Osteosarcoma complicating Paget's disease is extremely malignant and death is almost invariable once this complication has developed. Pathological fractures complicating Paget's disease are common in the femur, of which sub-trochanteric fracture is the commonest.

Aneurysmal bone cyst.— This is a lesion which contains cavities filled with blood. This condition is commonly seen in the ends of growing long bones. X-ray shows a rarefied area which may contain lamellae within it to give the appearance of a honeycomb. The lesion may expand to destroy the inner aspect of the cortex which becomes thin and may slightly bulge out. Pathological fracture may occasionally complicate this condition.

TUMOURS

Osteoma.— Two varieties of osteomas are commonly come across.

(i) *Cancellous osteoma (exostosis).*— This is nothing but a conical lump of bone with a cap of cartilage which arises from the metaphysis of a long bone. It stops enlarging when the bone growth ceases. This condition mainly affects the adolescents. The presenting feature is a painless bony lump which gradually increases in size. Occasionally it may interfere with the tendon action and may cause injury to a nerve giving rise to secondary symptoms. X-ray shows the exostosis obviously, whose medullary cavity and the cortex are continuous with those of the parent bone.

(ii) *Compact osteoma (ivory exostosis).*— Generally the membrane bones are affected and the tumour is sessile. The commonest site is the outer surface of the skull; very occasionally this tumour may originate from the inner surface of the skull when it may give rise to focal epilepsy. Adolescents or young adults are again the common victims. The presenting symptom is the hard painless lump. X-ray shows a dense sessile well-circumscribed bulge from the involved bone.

Osteoid osteoma.— Usually the boys of second decade are affected. Any bone except the skull may be affected, the commonest being the femur or the tibia. The only presenting symptom is the pain which is very rarely severe and is not relieved by rest. This boring pain may continue for many months before the patient comes to doctor. X-ray shows a small radiolucent area, which may or may not contain a tiny dense opacity (the nidus). There may be slight surrounding sclerosis which becomes obvious in lesions affecting the medullary cavity. This condition is difficult to differentiate from Brodie's abscess without biopsy.

Chondroma.— This tumour is nothing but a lobulated mass of cartilage. The tumour may affect any bone, but most frequently the short long bones e.g. the metacarpals, the phalanges and metatarsals. When this tumour remains entirely within the medullary cavity, the cortex is bulged out and thinned, it is called *enchondroma*. When this tumour protrudes on the surface it is called *ecchondroma*. The matrix of the tumour may be calcified or even ossified, when it is called *osteochondroma*. Enchondromas may be multiple but ecchondromas are generally solitary tumours. Malignant change, though rare, may be seen in multiple enchondromas.

Fibroma.— This tumour is an island of fibrous tissue in the bone. It is commonly seen in adolescents. X-ray shows an oval gap in the cortex of the metaphysis of a long bone.

Chondromyxoid fibroma.— The patients are usually between 10 to 30 years of age. Lower limbs are mostly involved. The patients present with chronic boring pain. X-ray shows a round or oval radiolucent area in the metaphysis. Malignant change, though rare, has been recorded.

Haemangioma.— This condition is very rare in bone but may occasionally involve the spine. The patients present with persistent backache. If it involves the long bones, it may cause elongation of the bone. X-ray shows radiolucent trabeculated tumours expanding the bone. Pathological fracture is not uncommon in this condition.

Osteoclastoma (Giant cell tumour).— This "treacherous" tumour mainly affects individuals between 20 and 40 years of age. It nearly always affects the very end of a long bone. The tumour probably originates from the metaphysis and very quickly destroys the epiphysis. This tumour most commonly affects the bones around the knee joint, but tumours of the radius, ulna, and humerus are not uncommon. The usual presenting symptom is vague discomfort with a swelling. A history of trauma is sometimes elicited, but this probably has only drawn attention of the patient towards the tumour. On palpation, egg-shell crackling may be elicited. X-ray shows a rarefied area towards the end of the long bone due to destruction of the bone by osteolytic process. The bone may be destroyed irregularly so that the tumour is traversed by remnants of the original bone which is heavily trabeculated. This gives rise to a typical 'soap-bubble' appearance in X-ray. So long the tumours remain benign, there is a sharp well-defined line of junction with the rest of the bone. As soon as the tumour becomes malignant, this delineation disappears. The cortex is sometimes destroyed or may be very thinned and ballooned. When becomes malignant this tumour shows a low grade malignancy. Metastasis may occur to the lungs via the blood stream. More common is the recurrence following local removal. Such recurrences are more malignant than the original tumour.

Osteosarcoma.— This is a highly malignant tumour. The tumour originates from the medulla of the metaphysis. Gradually the cortex is eroded and the periosteum is first pushed away from the shaft. At this time one may find "Codman's triangle" at the region where the periosteum is elevated from the bone and "Sun-ray spicules" due to new bone formation along the periosteal blood vessels. Eventually the periosteum is also penetrated and the soft tissues around the bone are involved. The tumour metastasises mainly through the blood stream to the lungs and also to other bones commonly to skull, femur, pelvis etc. The incidence of osteosarcoma is highest between the age of 10 to 20 years. Thereafter the incidence falls rapidly. The commonest site is

the metaphysis of the long bone and around the knee joint. A history of trauma may be present but this again has no relation with the aetiology of the condition. Pain is usually the first symptom which is followed very soon by a swelling. Pain is of constant boring nature, which becomes worse at night and gradually becomes severe as the tumour grows rapidly. The overlying skin becomes shiny with prominent veins. The lump feels warm and tender and lacks a definite edge. Varying consistency may be felt in different regions of the tumour. Sometimes the tumour may be pulsatile. This is called "telangiactatic osteosarcoma". X-ray shows area of rarefaction in the medulla with bone formation in the form of Sun-ray spicules, Codman's triangle etc. A definite opacity may be noticed along the extent of the tumour even in the soft tissues.

Old people may suffer from osteosarcoma but this is mostly a complication of Paget's disease.

Chondrosarcoma.— In this condition cartilage cells predominate. A true chondrosarcoma affects people between the ages of 35 and 50 years. It may arise in any bone with a predilection towards the flat bones, such as ilium and ribs etc. The presenting symptom is again a constant ache with a swelling which has very recently increased in size. X-ray appearances are variable but mostly osteolytic. This tumour is slightly less malignant than the previous one. It also metastasises mainly through blood vessels.

Fibrosarcoma.— This tumour contains spindle-shaped fibroblasts. It may originate in the medullary cavity or periosteally (when it is called periosteal fibrosarcoma). The patients are usually 30 to 50 years of age and present with pain, swelling and even pathological fractures. X-ray shows an osteolytic lesion which may be surrounded by reactive sub-periosteal new bone. This also produces blood-borne pulmonary metastasis.

Synovial-sarcoma.— This condition may affect individual of any age. This tumour usually arises close to a major joint either the knee or the ankle or the wrist. But it may occasionally occur in connective tissue or muscle. Metastasis occurs by blood, the lymphatics and by migration





Figs.11.26. & 11.27.— Shows a typical case of osteolytic lesion of secondary carcinoma affecting the shaft of femur. In the first figure the bone is not yet fractured and in the second figure after a few weeks shows that the femur is fractured.

of cells through the tissue planes. Microscopically it is a tumour, composed of both synovial cells and malignant fibroblasts. This tumour is extremely malignant.

Ewing's tumour.— This tumour arises from the reticulum cells of the medullary cavity of the diaphysis of the long bones. The tumour gradually lifts the periosteum, which appears to resist the spread of the tumour and may lay down layers of bone formation giving rise to an onion-like appearance in X-ray. Distant spread is mainly via the blood streams to the lungs also to other bones. Lymphatic spread is rare.

The tumour mainly affects the young between 10 and 20 years of age. Long bones are mainly affected of which the tibia is the commonest. The patients present with the pain, which is of throbbing nature and becomes worse at night. A history of trauma may be present. The patient is sometimes ill with fever which makes this tumour so often mistaken for osteomyelitis. The swelling is warm and tender and has an ill-defined margin. X-ray appearances are a rarefied area in the medulla, the cortex may be perforated and there may be the onion layers of calcification. That the tumour melts by radiotherapy as the snow in sun-shine is the pathognomonic feature of this condition.

Multiple myeloma.— The tumour arises from the plasma cells of the bone marrow. The tumours are found wherever there is red marrow in the bone e.g. the skull, the trunk bones and the ends of the longs bones. The tumour is usually multiple.

Mostly individuals between 45 to 65 years of age are affected. The patients present with bone pain, which is root pain from collapse of a vertebra and occasionally nephritis contribute to the general ill-health of the patient. X-ray shows multiple small areas of rarefaction in the affected bones which are usually osteoporotic.

Special investigations of the urine will show the presence of Bence Jones protein in 50% of cases. Electrophoretic analysis of the plasma and urine will show presence of excessive protein mostly albumin. Sternal marrow puncture will reveal typical myeloma cells. High erythrocyte sedimentation rate is also a feature of this condition. As the disease advances, general lymphadenopathy together with enlargement of the liver and spleen and bleeding tendency with epistaxis, haemoptysis or haematemesis may be found.

Plasmacytoma.— This is an example of solitary myeloma. The patient presents with pain, swelling or a pathological fracture. Radiologically an area of translucency at the tumour site may be observed.

Secondary carcinoma of bone.— Bony metastasis mainly occur by blood streams and the primary sites are mainly the thyroid, breast, the prostate, kidney, bronchus, uterus, G. I. tract and testis. About 2/3rd of cases of secondary bone deposits, the primary is seen either in the breast or in the prostate. The bones, commonly affected, are the vertebrae, ribs, sternum, pelvis and upper ends of the humerus and femur. The patients are usually more than 40 years of age. The patients present either with mild bony pain, backache or root pain or even pathological fracture. X-ray may show either osteolytic (when the primary carcinoma is in any viscus other than prostate) or osteoblastic (when the primary carcinoma is in the prostate) lesion. Bone scan shows the metastatic lesion much earlier than the skiagraphy.

Chapter

12 EXAMINATION OF BONE AND JOINT INJURIES

HISTORY.—

1. **Age.**— Epiphyseal separation is only seen in children before the epiphysis unites. Greenstick fracture is also common in children. Dislocation is common in adults. Fractures may occur at any age.

2. **The amount and nature of violence.**— The clinician must enquire about the details of the accident — 'how did it occur?' 'what was the mechanism of force?' and 'how forceful was the injury?' If the violence is not severe enough to cause fracture, one should suspect that the bone was diseased before and this type of fracture is called ***pathological fracture***. The causes which may lead to pathological fracture are discussed later in this chapter (page 170). At the present moment the students should remember that a trivial fall in old subjects may cause fracture of the femoral neck due to senile osteoporosis, similarly subtrochanteric fracture may result from Paget's disease or femoral shaft fracture may be due to secondary carcinoma.

The nature of violence, which may cause a fracture, may be of three types — direct, indirect and muscular. **Direct** violence may be of (i) *tapping* in nature which will cause a transverse fracture with minimum skin damage or (ii) *crushing* in nature in which there will be multiple fragments which is known as 'comminuted fracture' and a good amount of soft tissue injury. **Indirect** violence may be of (i) *twisting* in nature which will lead to a spiral fracture, (ii) *bending force* which will lead to a transverse or oblique fracture, (iii) *a bending force with axial compression* leading to double oblique fractures with separation of a 'butterfly' fragment and (iv) a combination of twisting, angulation and axial compression will cause a short oblique fracture. **Muscular** violence, in which the muscle contracts against resistance, may lead to a fracture which is come across in case of patella, olecranon and lesser trochanter of the femur.

Sometimes there is no history of one severe violence but the bone is fractured. This is most commonly seen in the neck of the second metatarsal bone and due to repeated stress as for example when a soldier marches for a long distance or unaccustomed repeated stress. This is known as 'march fracture'.

3. **Pain.**— It is interesting to note that in case of fracture pain is felt only during movement of the fractured site. In contradistinction to the common belief, a fracture is less painful than a sprain or a strain. Pain is the least in impacted and green stick fractures. In dislocation, pain is constant and unbearable till it is reduced.

4. **Loss of function.**— The patient will obviously be unable to move the fractured limb due to pain. He cannot put weight on it. In case of dislocation the patient is unable to move the joint even slightly.

5. **Deformity or swelling.**— A fracture or a dislocation often presents with a swelling or deformity. Sometimes a swelling from haematoma or callus may attract the attention of the patient, which may be the sequel of fracture. This is commonly seen in march fracture.

LOCAL EXAMINATION

The injured side should always be compared with the sound side.

A. **INSPECTION.—**

1. **Abnormal swelling and deformity.**— In fracture the first thing which attracts the clinician's eye is the deformity and/or swelling. The deformity is mostly due to displaced fractured segments and the swelling is mostly due to haematoma and oedema. If the fracture is very near a joint, effusion will lead to an obvious swelling.

In dislocation again the deformity is the main feature in inspection which often by itself indicates the diagnosis.

2. **Attitude.**— In certain fractures the patients adopt particular attitudes which are very diagnostic. As for example in fracture neck of femur the patient lies helpless with the lower limb externally rotated. In posterior dislocation of the hip the thigh assumes the attitude of flexion, adduction and internal rotation. These are elaborately described under 'Examination of injuries about individual joints'.

3. **Shortening.**— A little amount of shortening is almost always expected in fractures due to overlapping of the segments. This is more obvious in case of lower limb than in case of upper limb.

4. **Overlying skin.**— This is an important point in inspection of a case of fracture. If there is a wound which communicates with the fracture site, the fracture is said to be *compound* or *open* and it runs the risk of being infected. Wound must be carefully inspected to know its size and actual depth. In gas gangrene the muscle may peep out through the wound which will be brick red, green or black in colour, there will be serosanguineous discharge and the characteristic odour. In *simple* or *closed* fracture the skin is intact. Oedema, blebs and bullae are quite common due to interference with venous return. Ecchymosis also appears within a few days after a fracture or dislocation.

B. **PALPATION.**— Before palpation is actually started the patient should be asked to point out the site of injury. This will reduce beating about the bush, unnecessary discomfort to the patient and will definitely save time. It has got another greater advantage of not missing any injury.

1. **Tenderness.**— Local *bony* tenderness is a valuable sign of a fracture. This tenderness should be elicited in relation with the bone and not with the soft tissue. So palpation to elicit tenderness should be made through a healthy soft tissue, otherwise damaged soft tissue will mislead the clinician by its own tenderness. Bony tenderness due to fracture is called **local bony tenderness.** All throughout the length, the bone is palpated through comparatively healthy tissue.

In joint injuries a careful examination should be made to elicit the maximum point of tenderness to know which structure is affected. As for example tenderness on the medial side of the medial condyle of the femur means the upper attachment of the tibial collateral ligament of the knee joint has been sprained. Similarly tenderness on the attachment of the anterior horn of the medial meniscus of the knee joint along with other definite signs indicate torn medial semilunar cartilage. Sometime a joint has to be moved in different directions to elicit tenderness by passive stretching of the injured ligament. This is also a sign of sprain.

2. **Bony irregularity.**— The whole length of the injured bone should be palpated to note if there is any irregularity such as a sharp elevation, a gap etc. This is a definite sign of a fracture.

3. **Abnormal movements.**— This is also a definite sign of fracture and can be elicited by moving one fragment against the other. Utmost gentleness is expected from the clinician while eliciting this physical sign. In fact it should be used only to exclude the presence of a fracture.

This physical sign is however necessary in old fractures to know if they have been united or not.

4. **Crepitus.**— It is a sensation of grating which may be felt or heard, when the bone ends are moved against each other. It should never be sought deliberately since its demonstration adds nothing to the diagnosis and nearly always causes pain. The students should remember the other conditions which may produce crepitus to avoid fallacy. These are haematoma, surgical emphysema, gas gangrene, osteoarthritis, tenosynovitis and Charcot's joint.

5. **Pain elicited by manipulation from a distance.**— This is sometimes required to find out the possibility of a fracture. It may be done (a) by *rotating* the bone in case of humerus or the femur, (b) by *squeezing* both the bones of the leg or the forearm, which is popularly known as "springing" of the fibula or the radius, (c) by making *axial pressure* in the line of the bone as can be applied in case of metacarpals or metatarsals.

6. **Absence of transmitted movements.**— When the continuity of the bone is broken, transmitted movement will obviously be absent. This can be tested by rotating humerus or femur with flexed elbow or knee respectively and by palpating the tubercle of the humerus or the trochanter of the femur with another hand.

7. **Swelling.**— If there is a swelling its characteristic should be noted — whether it is a bony swelling or a swelling arises from the neighbouring joint. A bony swelling may be either a displaced fragment of a fracture or the callus or the articulate end of the bone of a dislocated joint. A swelling of the joint is mainly due to effusion.

8. **Wound.**— Under aseptic ritual the wound should be explored to note the position of the broken fragments, the presence of a foreign body and the colour of the muscles to exclude any possibility of gas gangrene. The neighbouring muscles and the subcutaneous tissue of the wound are also palpated to exclude the presence of surgical emphysema which is a sign of gas gangrene.

C. **MEASUREMENT.**— In examination of bone injuries two types of measurement should be taken — (i) longitudinal, to know if there is any shortening and (ii) circumferential, to know if there is any wasting due to injury.

(i) **Longitudinal.**— Before taking measurement of the affected limb, the clinician must make sure that there was no pre-existing shortening of the limb. *While taking measurement, the sound limb should be kept in the same position as the affected limb.* If this simple instruction is not remembered there may be a great difference in measurements in different positions of the limb. The bony points, which are considered in measurement, should be marked with skin pencil before the use of measuring tape. *It is always a good practice to measure the healthy limb first.*

(ii) *Measurement of the* **circumference** *of the limb.*— It takes sometimes for muscular wasting to develop after a bone or joint injury. While measuring the circumference of the limb two things should be borne in mind — (a) the healthy limb should be measured first and (b) the measurements should be made at the same level in both the limbs.

D. **MOVEMENTS.**— Both active and passive movements should be tested. When the diagnosis is already established this part of the examination should be omitted as this will not give any additional information but will simply hurt the patient. This examination is more essential to exclude any bone or joint injury than anything else. Good active and passive movements mean there is no bone or joint injury. In dislocation of a joint both active and passive movements become nil and an abnormal rigidity with elastic recoil is encountered with any attempt to passive movements.

Stiffness of the joint is a complication of the fracture and may be due to — (i) intra-articular and peri-articular adhesions, (ii) myositis ossificans, (iii) Sudeck's osteodystrophy and (iv) muscular adhesion which leads to inability of the muscle to lengthen during movement — as is

seen most commonly after fracture of the shaft of the femur where quadriceps muscles are affected by adhesion and prevent flexion of the knee joint.

E. **COMPLICATIONS.**— These are elaborately discussed in later part of this chapter. At this stage it will be sufficient to mention that one should exclude any other associated injury which may be accompanied with bone or joint injury. These are injury to the nerve, injury to the blood vessels and injury to the internal organs within the thorax or abdomen which is more dreadful and may be fatal.

GENERAL EXAMINATIONS

Look for evidence of shock. This is mainly due to good amount of blood loss in major fractures. Some amount of neurogenic shock may be associated with this.

It is of immense importance to exclude any other injury which may be associated with the bone or joint injury. In this context one must remember that thoracic and abdominal injuries, which tend to be overlooked, are more dangerous.

When a **pathological fracture** is suspected, an attempt should be made to know the cause of the pathological fracture. In this respect **age** of the patient is an important guide. *In infants,* multiple fractures may be seen in cases of osteogenesis imperfecta (brittle bones), which is characterized by dwarfism, broad skull, blue sclera, scoliosis, ligament laxity, otosclerosis (although deafness may not appear until adult life) and various deformities. Marble bones (osteopetrosis) are also brittle and fracture easily at this age. *In children,* acute osteomyelitis and solitary bone cysts are usually the causes. *In young adults,* osteoclastoma and osteosarcoma are responsible. *In adults* generalized fibrocystic disease (hyperparathyroidism) and multiple myeloma are the causes of multiple fractures. *In the elderly,* besides senile osteoporosis, Paget's disease and secondary carcinoma are the main causes. In case of secondary carcinoma a thorough search should be made to get at the primary focus either in the breast or thyroid or bronchus or kidney or prostate etc.

SPECIAL INVESTIGATIONS

1. **X-ray examination.**— This is by far the most important investigation so far as the bone and joint injuries are concerned. At least two views *antero-posterior* and *lateral* should be taken to determine which bone has been fractured, the line of fracture and the type of displacement. Two views are essential to note exactly the above points. The antero-posterior view shows sidewise displacement — external or internal whereas the lateral view reveals anterior or posterior displacement. The three points are mainly noted while reading X-ray plate: (i) *Situation* — which bone is broken and which part of it ? Whether any other bone has been fractured or not ? Has the fracture involved the joint surface? (ii) *Line of fracture.*— It may be transverse or small oblique or spiral or double oblique with a butterfly segment etc. A careful assessment of the line of fracture is very important to know the mechanism of the injury and the treatment to be instituted. *(iii) Displacement.*— It is best described by three components — (a) *shift* forwards, backwards or sideways. There may not be any shift as the fragments may be impacted or overlap each other. (b) *Tilt* — may be again forwards, backwards and sideways. (c) *Twist* (rotation) which may be in any direction.

Sometimes X-ray picture should be taken from different positions to locate the sites of fracture which are difficult to be revealed in classical antero-posterior and the lateral views. These are *oblique view* in scaphoid fracture, *stereoscopic views* in fracture of the skull and pelvis, *special axial radiograph* in fracture of the calcaneum.

In skiagram, one should look for any pathology in the bone which may be the cause of fracture.

In old fractures, one should look for the following points — (i) Signs of union — callus formation which appears in X-ray as early as on the tenth day after fracture. Consolidation and bone remodelling take quite a long time and one should not wait for these signs as the signs of union. In fact union occurs long before these signs develop and clinical test is better evidence of union than the radiological evidence. If there is no local tenderness at the site of fracture and attempt at abnormal movement between the fracture fragments fails to produce any pain or movement, it should be taken into granted that the fracture has been united (clinically) though X-ray shows a small gap between the fragments. (ii) *Sclerosis at the fractured ends with a gap in between them* indicates non-union and differentiates it from the delayed union. (iii) Myositis ossificans traumatica (Fig. 13.22). (iv) Avascular necrosis etc.





Figs. 12.1 & 12.2.— Showing the importance of taking two views. Note that there is hardly any evidence of fracture in the lateral view, but the anteroposterior view reveals fracture dislocation with considerable displacement.

2. **Serum.**— Calcium should be estimated when there is a slightest doubt about the possibility of hyperparathyroidism. Alkaline phosphatase will be high in Paget's disease. Acid-phosphatase is high in bony metastasis from carcinoma of prostate.

3. **Urine.**— In multiple myeloma, presence of Bence Jones proteose can be demonstrated by heating the urine. Hydroxyproline excretion in urine will be high in Paget's disease.

4. **Bone scan.** — Skeletal scanning with a variety of





Figs. 12.3 & 12.4.— Show the lateral and anteroposterior views of a typical Colles' fracture. Note that the lower fragment is shifted upwards, slightly laterally and tilted posteriorly.

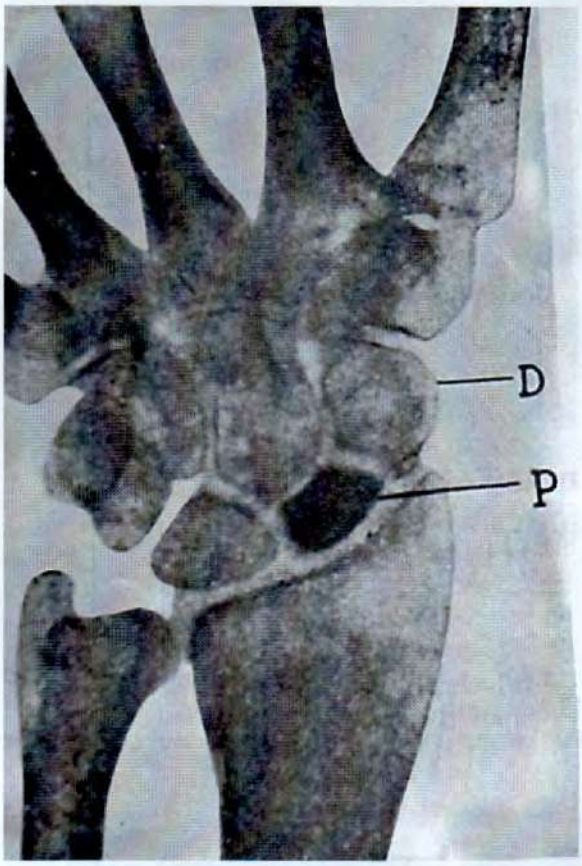

Fig.12.5.— Avascular necrosis of the proximal fragment 'P' of the scaphoid bone. The distal piece 'D' remains unaffected. This is a complication of fracture of the scaphoid which so commonly takes place through its waist.

bone-seeking isotopes has been used in clinical practice and it is now well established that when properly applied this technique is more effective than skeletal X-rays in delineating focal bone diseases, especially metastasis. The increased blood flow and increased osteoid tissue formation, which are the processes of tumour-cell invasion, can be demonstrated by locally increased concentration of the gamma-emitting radioisotope. The increased radioactivity is displayed either as a number of counts on a scaler or pictorially as a "hot-spot" on a scintiscan. Infrequently, in case of very anaplastic carcinoma, indolent tumours such as thyroid cancer or some cases of myeloma, there may be little or no "hot-spot" seen.

Many radioisotopes have been used for bone scanning. Of these strontium (85 Sr.), which is taken up by bone in a similar manner as calcium and which is a pure gamma emitter and more recently radio-active technitium ($^{99}Tc^{m}$) have become popular. Scanning is performed 1 to 4 hours after the intravenous injection of 5 to 10 mCi of $^{99}Tc^{m}$-phosphate complex. The bladder must be emptied before the pelvis is scanned as about 40% of the injected dose is excreted through the urine within first 4 hours after injection and pelvic lesions are liable to be obscured by overlying bladder activity.

It should be remembered that the simple radiograph shows no abnormality until more than 50% of bone mineral has been destroyed and obvious metastasis may be present even in the absence of X-ray changes. 24% of preoperative patients with clinically and radiologically early disease have metastases demonstrable by scanning. Bony metastasis from cancer of prostate may be present despite normal acid and alkaline phosphatase levels. Bone scan sometimes demonstrates "silent" metastasis which has produced fracture, which was initially thought to be simple.

Bone scan may be usefully employed in the study of non-malignant conditions e.g. abscesses, aseptic necrosis, Paget's disease and arthropathies.

5. **Arthroscopy** is extremely helpful to detect joint injuries and particularly the semilunar cartilage (meniscus) injuries of the knee.

6. **Arthrography** with opaque contrast medium (Conray, urografin etc.), gas or both (double contrast) is helpful to detect precisely the internal structure damage in injuries particularly of the knee joint.

DIAGNOSIS

Fracture.— Diagnosis is made by (i) history of trauma, (ii) localized pain, (iii) swelling and deformity, (iv) local bony tenderness, (v) local bony irregularity, (vi) crepitus and (vii) X-ray. Of the above symptoms and signs local bony tenderness, local bony irregularity, crepitus and X-ray are the most important points to be remembered.

Dislocation.— This is a condition in which one bony component loses its contact completely with the other bony component of the joint. If it retains partial contact, the term **subluxation** is applied. Dislocation is diagnosed by (i) the deformity, (ii) abnormal swelling near a joint, (iii) rigidity of the joint in passive movements and X-ray.

Sprain — means ligamentous injury. This condition gives rise to tremendous pain. Diagnosis is made (i) by presence of tenderness on the ligament particularly at its bony attachment, (ii) passive stretching of the ligament will cause excruciating pain, (iii) there is no local bony tenderness or local bony irregularity and (iv) X-ray shows no bony injury.

COMPLICATIONS OF FRACTURES AND DISLOCATIONS

GENERAL COMPLICATIONS.— Shock, venous thrombosis and pulmonary embolism, fat embolism, 'fracture fever', delirium tremens following alcoholism, accident neurosis, hypostatic pneumonia and tetanus in compound fracture.

LOCAL COMPLICATIONS.— These can be classified into (A) *recent complications* e.g. injury to the neighbouring joint, nerve, blood vessels, muscles or tendons, viscera of the abdomen or thorax and infections in compound fracture; and (B) *late complications* e.g. delayed union, non-union, mal-union, avascular necrosis. Volkmann's ischaemic contracture, myositis ossificans traumatica, joint instability and stiffness.

Joint injury.— Dislocation, subluxation and/or ligamentous injury of the neighbouring joint may be associated with the fracture.

Nerve injury.— This should be diagnosed at the time of injury to the bone. Usually the lesion is a neuropraxia which heals automatically. Sometimes severe traction on the nerve during injury or during overzealous manipulation may lead to axonotmesis. Neurotmesis is hardly associated with closed fractures.

Immediate nerve injuries which are seen with different bone and joint injuries are — (i) the spinal cord or cauda equina injury in fracture-dislocation of the spine, (ii) the axillary nerve in shoulder dislocation or fracture neck of the humerus, (iii) the radial nerve in fracture shaft of the humerus, (iv) ulnar, median and/or radial nerve in supracondylar fracture of the humerus, (v) sciatic nerve in posterior dislocation of the hip and subtrochanteric fracture of the femur and (vi) the common peroneal nerve in fracture of the neck of the fibula. Late nerve injury is sometimes seen as a late complication of fracture. The most common example is the "tardy ulnar palsy" in supracondylar fracture of the humerus which has been malunited with Cubitus Valgus deformity and in fracture of the medial epicondyle of the humerus where the ulnar nerve is involved in callus and gradual injury to the nerve by bony irregularity if anterior transposition of the ulnar nerve has not been performed.

Injury to blood vessels.— The blood vessels that are likely to be damaged in different fractures and dislocations are (i) the middle meningeal vessels in fracture of the skull, (ii) the brachial artery in supracondylar fracture of the humerus and (iii) the popliteal artery in supracondylar fracture of the femur. Mostly the vessels are either thrombosed or occluded by spasm or oedema. Sometimes they are pressed upon by the displaced fragment and very rarely they are completely divided. Impairment of circulation following fracture or dislocation should be diagnosed as early

as possible. If the impairment is due to displaced fragment, prompt reduction of the fracture or dislocation should be called for. Sometimes the impairment of circulation is due to incorrect application of plaster of Paris and these cases should be treated by immediate removal of the plaster and bandages till the pulsation of the artery comes back. If these procedures fail to bring about improvement in circulation, there is a place for immediate arteriography with a view to possible excision and grafting.

Vascular injury may lead to gangrene in severe cases and late ischaemic contracture of muscles in less severe cases.

Muscle Complications.— The adjoining muscle fibres are often *torn* in fracture. The torn fibres may become adherent to the intact fibres, fractured site or capsule of the neighbouring joint. This may lead to stiffness of the joint and may require lengthy rehabilitation after the fracture has been consolidated. So every attempt should be made to keep the muscles active when the fracture is kept immobilized.

Another complication of the muscle following fracture is *disuse atrophy.* Active movement is again the treatment of this condition.

Tendon Complications.— *A torn tendon* is rare in association with closed fracture. It is seen in fracture of patella where the tendinous expansion of the quadriceps tendon is torn.

Late rupture of tendon is sometimes seen in certain fractures e.g. the extensor pollicis longus tendon in fracture of the lower end of the radius and the long head of the biceps in fracture neck of the humerus.

Tendinitis is a very rare complication of a fracture and occasionally affect the tibialis posterior tendon following fracture of the medial malleolus.

Injury to viscera.— Injury to internal organs are often seen in various fractures of bones lying near to them. Such examples are injury to the urinary bladder and urethra in fracture of the pelvis, rectum in the fracture of the sacrum, lung, liver or spleen in fracture of the ribs and the brain in fracture of the skull.

Infection.— This is quite common in compound fracture and a dreadful complication of the fracture. It may give rise to osteomyelitis with formation of sequestrum and sometimes absorption of bone overwhelms leading to disappearance of some part of the bone. However simple may be the infection, non-union may be the sequel. The most dreadful complications of a compound fracture are the gas gangrene and tetanus.

Delayed union.— The students must have clear conception about what is meant by the term"delayed union". When a fracture takes an unduly longer time than is expected for union of the particular fracture, the term 'delayed union' is used.

The causes are (i) inadequate immobilization; (ii) internal fixation which always delays union as the haematoma between the fracture ends which acts as a scaffold for union is disturbed and because the periosteum is stripped off and (iii) intact fellow bone — when one bone of the forearm or the leg remains unbroken, the fractured bone always takes longer time for union.

Non-union.— The term "non-union" means bony union of the fracture is not possible without operative intervention. The fragments are joined by fibrous tissue. To know whether the fracture concerned is a case of delayed union or non-union, X-ray is very much essential. In non-union there will be presence *of sclerosis* at the bone ends and a gap between them.

Causes of non-union are (i) infection; (ii) interposition of soft tissue either periosteum or muscle between the bone ends; (iii) inadequate blood supply e.g. fracture of lower half of tibia; (iv) wide separation of fragments e.g. fracture of patella, fracture of the olecranon process or excessive traction; (v) inadequate treatment of delayed union that means adequate immobilization for a long period was not maintained in a case of delayed union.

Mal-union.— This means union of fragments in a defective position. The commonest deformity is angulation, besides this there may be overlapping with shortening and mal-rotation.

The causes of mal-union are (i) fracture was not reduced properly; (ii) after reduction redisplacement occurs within the plaster, for this a check X-ray after a week is advisable in certain fractures anticipating redisplacement, e.g. fracture of both bones of the forearm; (iii) growth disturbance due to injury to the epiphyseal cartilage may lead to mal-union. Fracture-separation of an epiphysis does not lead to growth disturbance as the fracture occurs through the metaphyseal plate keeping the epiphyseal cartilage intact.

Sites of mal-union are those where the bone is cancellous so union occurs as a rule, but mal-union complicates due to imperfect position of the bone ends. These sites are fracture neck and the supracondylar fracture of the humerus, Colles' fracture, fracture through the condyles of the tibia etc.

Avascular Necrosis.— It means necrosis of the bone due to inadequate blood supply. It complicates fracture when the blood supply of one fragment was derived from the other fragment when the bone was intact. So after fracture the blood supply of one fragment becomes completely deficient and undergoes avascular necrosis. This avascular necrosis will lead to non-union and osteoarthritis of the involved joint. Diagnosis is made by X-ray and the change takes about 1 to 3 months to develop. The avascular bone shows greater density due to the fact that it does not share in the general osteoporosis due to deficient blood supply.

The common sites of fracture which are liable to undergo this complication are the fracture neck of the femur, fracture of the scaphoid, fracture of the neck of the talus where the body undergoes avascular necrosis and dislocation of the lunate bone when the whole bone becomes necrosed.

Volkmann's ischaemic contracture.— This condition occurs when the arterial obstruction is not complete and not too long lasting otherwise gangrene would have developed. Though muscles can survive 6 to 8 hours ischaemia in contradistinction to the nerve tissue which can survive only a short period of ischaemia, yet the muscles cannot regenerate whereas the nerves can regenerate. So the damage to the muscle is replaced by fibrosis which leads to contracture.

This condition is commonly seen in the forearm following supracondylar fracture of the humerus which leads to occlusion of the brachial artery either by thrombosis or spasm or by the displaced lower end of the upper fragment. The flexor muscles of the forearm are more often affected. Nerves are also affected by ischaemia suggested by pain, weakness and numbness of the finger, but the nerves regenerate.

In the early stage *diagnosis* is made by impaired circulation of hand and fingers, absence of the radial pulse and inability of the patient to extend the fingers fully with complaint of pain in full passive extension. The treatment at this stage is relatively easy and the cure is guaranteed. In the established stage there will be obvious flexion deformity of the wrist and the fingers.

Myositis ossificans traumatica.— This term is rather confusing as by 'myositis' one may consider to be one of inflammation of the muscle. But it has got no connection with inflammatory condition of the muscle and it should better be called *'post-traumatic ossification'*. Actually this condition develops when the haematoma under the stripped periosteum is invaded by osteoblasts and becomes ossified. This condition is commoner in children and young adults in whom the periosteum is loosely attached to the bone. Diagnosis is made by X-ray.

This condition is more commonly seen in elbow after supra-condylar fracture or fracture of the head of the radius. It is also seen in some cases of fracture neck of the femur after operative fixation.

Joint Complications.— Stiffness of the neighbouring joint is one of the commonest

complications of fracture. The causes are : (i) *Adhesion.*— Intra-articular adhesion results from organization of blood poured into the joint. More commonly periarticular adhesions occur from effusion into the ligaments and the capsules. Stiffness following fracture occurs mostly in the knee joint, the elbow joint, the wrist joint and the finger joint. In the shoulder joint the synovial fold on the inferior aspect of the joint is redundant and becomes adherent causing limitation of abduction movement. Adhesions of the injured muscle can also cause stiffness of the joint. The commonest example is the stiffness of the knee following fracture of the shaft of the femur due to adhesion of the quadriceps muscles. In these cases quadriceps-plasty does a lot to increase the movement of the knee joint. (ii) *Myositis ossificans.*— This has already been discussed. (iii) *Mal-union.* (iv) *Osteoarthritis.*— This is a late complication of a fracture which has involved the joint surface. After union the joint surface becomes irregular and thus results in osteoarthritis. Mal-union may be the cause of osteoarthritis particularly in weight bearing joints where the direction of stress transmission becomes abnormal. Avascular necrosis is another potential factor which may lead to osteoarthritis. (v) *Unreduced dislocation.*— This will definitely cause stiffness of the joint and closed reduction often fails. The only treatment is open reduction or osteotomy. (vi) *Sudeck's osteodystrophy.* — Though this condition may affect the foot, yet it is more common in the hand and wrist injury. Pain and stiffness of the fingers, hyperaesthesia and moistness of the ankle is diagnostic of this condition. X-ray shows patchy rarefaction of the bones in the region of the fracture.

Chapter

13 EXAMINATION OF INJURIES ABOUT INDIVIDUAL JOINTS

The students must go through the previous chapter to make a clear conception about the general scheme of examination of injuries of bone and joint. In this chapter only those particular points of clinical examination are mentioned which will be required for a particular joint.

EXAMINATION OF INJURIES ABOUT THE SHOULDER

A. **INSPECTION.**— *The patient must be stripped up to his waist and must stand against good daylight before the examination is actually started.* One should always compare the injured side with the sound side.

1. **Attitude.**— By noting the attitude of the patient while he is entering the clinic one can diagnose certain fractures. *With fracture of the clavicle* the patient often supports the flexed elbow of the injured side with the other hand. Similarly with *anterior dislocation of the shoulder* the patient supports the flexed elbow of the injured side with the other hand.

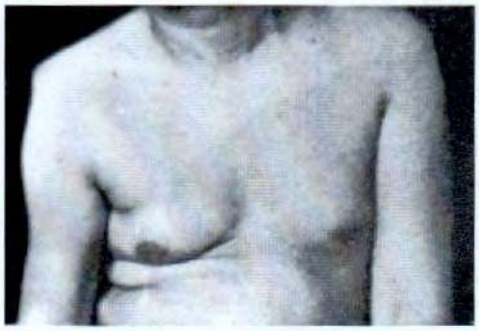

Fig. 13.1.— Note obvious flattening of the right shoulder which indicates dislocation of the shoulder joint.

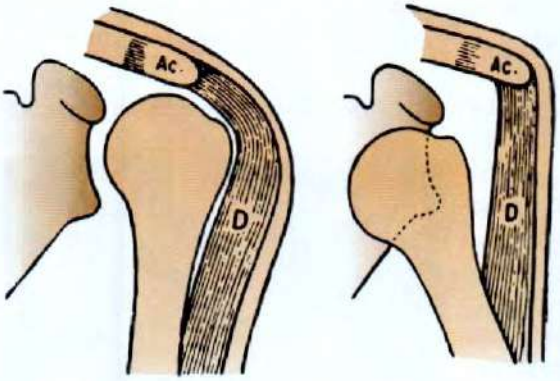

Figs. 13.3. & 13.4.— Roundness of the shoulder is mainly formed by the outward projection of the greater tuberosity beyond the acromion 'AC' and the thickness of the deltoid 'D'. Flattening in case of dislocation of the shoulder is due to inward displacement of the upper end of the humerus. It may also occur to certain extent in fracture of the neck of the scapula. Remember, apparent flattening of the shoulder is observed in wasting of the deltoid. Here, of course prominence of the greater tuberosity can be felt.



Fig. 13.2.— Another case of flattening of the right shoulder due to subcoracoid dislocation of the humerus.

2. **Deformity or swelling.**— An abnormal swelling on the line of the clavicle at its middle or more commonly at the junction of the lateral one third and medial two third should at once arouse the suspicion of *fracture clavicle* in the mind of the clinician. If there is any undue prominence at the acromial or the sternal end of the clavicle, the case is probably nothing but *dislocation of acromioclavicular or sternoclavicular* joint respectively. In *subcoracoid dislocation* of the shoulder an abnormal swelling can be seen in the deltopectoral groove, there will be undue prominence of the acromion process with flattening of the shoulder. There will be drooping of the shoulder with undue lengthening of the arm *in fracture neck of the scapula.*

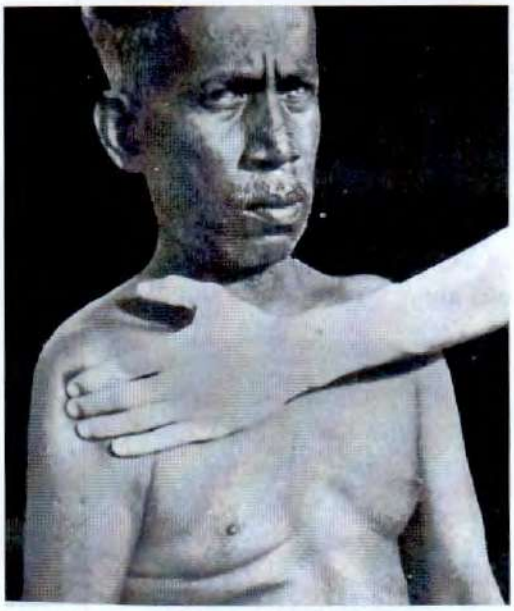

Fig.13.5.— Note loss of resistance by deeping the fingers below the acromion. This should be compared with the other side.

3. **Contour of the shoulder.**— Inspection of the shoulder must be performed from all aspects — anterior, posterior and lateral to know fully about any defect in the contour of the shoulder. Undue flattening and loss of roundness of the shoulder just below the acromion process occur in *dislocation of the shoulder.* The commonest type of dislocation of the shoulder is the *subcoracoid dislocation,* in which the head of the humerus lies below the coracoid process. In this condition there is also lowering of the anterior axillary fold. In contrast to this, considerable swelling of the shoulder just below the acromion process occurs in *fracture neck of the humerus,* without any loss of roundness of the shoulder.

4. **Bony arch** of the shoulder which is formed by the clavicle in front, the acromion process laterally and the spine of the scapula posteriorly, should be carefully inspected for any irregularity or abnormal swelling which may suggest fracture at that site.

B. **PALPATION.**— All the bones which take part in the formation of the shoulder girdle should be palpated systematically to know if there is any bone or joint injury.

1. **Clavicle.**— The surgeon stands behind the patient, who remains seated on the stool. The surgeon places his hands on the sternal ends of the clavicles of the both sides. Firstly, he palpates the sternoclavicular joints and then proceeds laterally on both sides to palpate the entire length of the two clavicles simultaneously. Any break in the line or abnormal prominence suggests fracture of this bone. The two joints on two sides of the clavicle are also examined in this process to exclude any dislocation there. The sternal end of the clavicle is mostly anteriorly displaced in sternoclavicular dislocation, whereas the acromial end of the clavicle is subluxated upwards in acromio-clavicular joint dislocation. It must be remembered that the conoid and trapezoid ligaments



Fig.13.6.— Bimanual palpation of the upper end of the humerus through the deltoid and axilla. It is better felt by the hand in the axilla.

are almost always torn in acromio-clavicular joint dislocation.

2. **Upper end of the humerus.**— At first, one must ascertain that the head of the humerus is in normal position within the glenoid socket. The surgeon again stands behind the patient, who remains seated on a stool. The surgeon first palpates the acromion processes of both sides with the fingers of his two hands. He now gradually slides his fingers downwards to palpate the greater tuberosity of the humerus on both sides. Disappearance of the greater tuberosity of the humerus and loss of resistance here indicate dislocation of the shoulder. He now gradually slides his fingers downwards along the line of the humerus on both sides. Local bony tenderness and bony irregularity at the surgical neck of the humerus suggest fracture neck of the humerus. Similarly if the surgeon goes down to palpate the shaft of the humerus, he may exclude the fracture at this site by absence of local bony tenderness and bony irregularity. It must be remembered that in an unbroken bone the medial epicondyle shows the direction of the head of the humerus, whereas the lateral epicondyle shows the direction of the greater tuberosity. If this relation is disturbed, one must suspect the possibility of fracture either at the neck of humerus or at the shaft. In case of dislocation of shoulder one can try to rotate the arm by rotating the flexed elbow. If there is no transmitted rotation of the head of the humerus and a crepitus and pain are felt at the neck of the humerus, the diagnosis of fracture-dislocation is established.

Marked tenderness just below the acromion process indicates *fracture of the greater tuberosity or rupture of the supraspinatus tendon.*

3. **Palpation of the scapula.**— At first the subcutaneous portions of the bone are palpated. These are the spine of the scapula and the acromion process. The vertebral border of the scapula and the inferior angle though covered by muscles can be easily palpated. The axillary border of the scapula is more difficult to palpate, yet localized bony tenderness and swelling on this border which suggest fracture of the scapula can be elicited. The coracoid process is situated ½ inch below the clavicle at its junction between the medial 2/3rd and lateral 1/3rd. This process can be felt easily though it remains under cover of the medial margin of the deltoid. Probably the most difficult fracture of scapula so far as the diagnosis is concerned is the fracture of the neck of the scapula. It is often confused with the fracture of the upper end of the humerus as diffuse swelling in the shoulder region is the common finding. Drooping of the shoulder with tenderness and crepitus by axial pressure upward through the flexed elbow remain the diagnostic feature of the fracture neck of the scapula. Very careful palpation of the upper end of the humerus will reveal no tenderness, whereas palpation medial to the glenoid cavity will elicit tenderness.

4. **Relative position of 3 bony points,** viz. the tip of the coracoid process, the acromial end of the clavicle and the greater tuberosity of the humerus are compared with those of the healthy side. Any deviation from the normal should be recorded. In acromio-clavicular dislocation the acromial end of the clavicle becomes prominent and comes closure to the greater tuberosity of the humerus. But the distance between the tip of the coracoid process and the acromial end of the clavicle becomes increased.



Fig. 13.7.— Showing how to measure the length of the arm from the angle of the acromion to the lateral epicondyle of the humerus. The former point is slightly posteriorly placed in comparison to the latter point.



Fig.13.8.— Hamilton's ruler test.

C. **MEASUREMENTS.**— **1. The length of the arm.**— This is measured from the angle of the acromion to the lateral epicondyle of the humerus. The angle of the acromion is the point where the spine of the scapula bends forward to become the acromion process. This angle lies more posteriorly than the longitudinal axis of the arm. So in subcoracoid dislocation of the shoulder as well as in fracture neck of the humerus and shaft of the humerus the *length of the arm will be shortened.* In subglenoid dislocation of the shoulder and fracture neck of the scapula the length of *the arm will be longer.*

It must be remembered that any damage to the upper epiphysis of the humerus will shorten the length of the arm.

2. Vertical circumference of the axilla.— This will be increased in any dislocation of the shoulder. But this measurement will also be increased in conditions like fracture of the upper end of the humerus and fracture neck of the scapula. The test to know lowering of anterior or posterior axillary fold is known as *Bryant's test.*

3. Hamilton's ruler test.— Normally a straight ruler cannot be made to touch the acromion process and the lateral epicondyle of the humerus. This is because of the presence of the greater tuberosity of the humerus which pushes the ruler away from the acromion process. But this becomes possible in dislocation of the shoulder where the greater tuberosity of the humerus is displaced medially.

D. **MOVEMENTS.**— *A full movement of the shoulder joint excludes the possibility of any bony injury near this joint.*

Dugas' test.— In dislocation of the shoulder the patient is unable to touch the opposite shoulder with the hand of the affected side while the arm is kept in contact by the side of the chest. After reduction of the dislocation in a muscular patient this test helps to be definite about the reduction and this position is maintained during the post-reduction period.

Complications.— In any injury around the shoulder joint examination cannot be complete without a search for any complication which might have been caused by such injury. The most important complication at this region is injury to the axillary nerve. This nerve besides supplying the deltoid muscle gives off a cutaneous twig which supplies the skin over the lower part of the deltoid muscle. Any injury at this region will limit the abduction of the shoulder joint by itself and it is of no use asking the patient to abduct the shoulder to test for the integrity of the axillary nerve. For this it is better to test the sensation of the skin supplied by the cutaneous branch of the axillary nerve.

SPECIAL INVESTIGATIONS

X-ray.— No doubt this is the only and most important investigation so far as the injury around the shoulder joint is concerned. Both antero-posterior and lateral views are essential. Even when the diagnosis is almost certain by clinical examination, X-ray is essential to know more precisely the line of fracture, the type of displacement (e.g. adduction or abduction type in case of fracture of the neck of the humerus) and the type of dislocation (e.g. whether subglenoid or subcoracoid or posterior dislocation of the shoulder). These are of utmost importance in treatment of the injury. In abduction type of fracture of the neck of the humerus the shaft is abducted in relation to the humeral head that means the outer half of the fracture is impacted.

In adduction type of fracture the shaft is adducted in relation to the head of the humerus that means the inner half of the fracture is impacted. In dislocation of the shoulder the position of the head of the humerus indicates the type of dislocation. When the head lies below the glenoid cavity the dislocation is said to be 'subglenoid' type; when the head of the humerus lies below the coracoid process the dislocation is called 'subcoracoid' type and when the head of the humerus lies posterior to the glenoid cavity in the infraspinatus fossa it is called the 'posterior' dislocation of the shoulder joint.

When the diagnosis is in doubt due to excessive swelling around the shoulder region, X-ray becomes the mode of diagnosis.



Fig.13.9.— Fracture of the upper end of the humerus.

Different conditions which may develop due to injury around the shoulder joint.—

1. Fracture of the clavicle.
2. Sternoclavicular dislocation.
3. Acromio-clavicular dislocation.
4. Fracture of the scapula.
5. Dislocation of the shoulder joint.
6. Fracture of the neck of the humerus and the greater tuberosity.
7. Dislocation of the shoulder joint with fracture of the upper end of the humerus.



Fig.13.10.— Fracture of the clavicle.

DIFFERENTIAL DIAGNOSIS

Fracture of the clavicle.— The history is usually a fall on the outstretched hand. The fracture usually takes place at the junction of the middle third and the outer third of the clavicle. Very often the lateral fragment is pulled down by the weight of the arm and the medial fragment is displaced upward by the pull of the sternomastoid muscle. On examination there is an obvious swelling by the displaced medial fragment and localized tenderness at the fracture site. The diagnosis is confirmed radiologically.

Sternoclavicular dislocation.— This is a rare injury and is caused by the fall on the shoulder which forces the inner end of the clavicle forwards and upwards. On examination an abnormal swelling becomes obvious at the inner end of the clavicle with localized tenderness at that region. Movements of the shoulder become painful and restricted. The diagnosis is confirmed by X-ray.

Acromioclavicular dislocation.— History of a sudden traction on the arm or a fall of a weight on the point of the shoulder is often elicited. It must be remembered that rupture of the acromio-clavicular ligaments will only cause subluxation of the acromio-clavicular joint. For complete dislocation to occur there must be rupture of the conoid and the trapezoid ligaments which constitute the coraco-clavicular ligament. On examination, an obvious prominence is present at

the outer end of the clavicle by the upward pull of the sternomastoid muscle and the acromion process is dislocated downwards by the weight of the arm. Movements of shoulder will be restricted. X-ray is confirmatory.

Fracture of the scapula.— This usually occurs by direct injury on this bone. Swelling, bruising, local tenderness and bony irregularity are elicited on examination. Movement of the shoulder will be very much restricted. A careful examination and radiological investigation will confirm the exact site of fracture.

Dislocation of the shoulder joint.— This is not uncommon injury caused by a fall on the outstretched hand. Forced extension along with lateral rotation will drive the head of the humerus forward tearing the capsule or avulsing the glenoid labrum. Nearly always the head takes the position just below the coracoid process and attains the name of *subcoracoid dislocation.* Rarely the head may lie below the glenoid cavity when it is called the *subglenoid dislocation.* It may so happen that the whole dislocation process occurs in the abducted position of the arm and the acromion process levers the head downwards to attain a position called *luxatio in erecta. Posterior dislocation* is a very rare occurrence and caused by a forced internal rotation on the abducted arm. Very occasionally is the dislocation complete and what is more common is subluxation with fracture of the head of the humerus.



Fig.13.11.— Anterior dislocation of the shoulder.

Of the four varieties of dislocation which have just been described the subcoracoid is by far the commonest. The patient enters the clinic by supporting the flexed elbow of the affected side with his sound hand. The round contour of the shoulder joint is lost and it becomes flattened due to absence of the greater tuberosity at its normal position. On careful inspection one may find a bulge at the deltopectoral groove caused by the head of the humerus which is easily confirmed by rotating the arm with flexed elbow. The patient would not be able to touch the opposite shoulder with the hand of the affected side. The tests of academic interest such as Dugas' test and Hamilton's ruler test will help to come to the diagnosis.

Recurrent dislocation of the shoulder.— Repeated dislocation of the shoulder by trifle injury is considered to be recurrent dislocation of the shoulder. When the anterior capsule is stripped from the anterior margin of the glenoid rim but attached to the neck of the scapula, there remains a chance of recurrent dislocation as the head of the humerus always remains within the capsule but outside the glenoid cavity. This condition may also occur when the glenoid labrum is detached along with the capsule and when there is a bony defect gouged out at the postero-lateral aspect of the humeral head.

The history is diagnostic. If the patient's arm is abducted to right angle and externally rotated the patient will show immediate resistance due to apprehension. This is the position of the arm in which a trifle force will result dislocation. This test is pathognomonic of this condition.

Fracture of the neck of the humerus and the greater tuberosity.— The mechanism is usually a fall on the outstretched hand. The surgical neck breaks and the upward thrust may shear off the greater tuberosity. A direct injury on the point of the shoulder may cause fracture at the anatomical neck of the humerus.

FRACTURE THROUGH THE SURGICAL NECK.— *This* fracture can be classified into abduction and adduction varieties. The greater tuberosity may be avulsed in abduction type of fracture. In adduction type of fracture the inner half of the fractured ends are impacted whereas in abduction

type of fracture the outer half of the fractured ends are impacted and the shaft remains abducted against the head of the humerus.

FRACTURE THROUGH THE ANATOMICAL NECK.— This condition is very difficult to diagnose from outside without X-ray. This may be in association with anterior dislocation of the shoulder.

FRACTURE OF THE GREATER TUBEROSITY.— This mostly occurs by direct injury on the greater tuberosity or by a fall on the abducted arm where the greater tuberosity impinges against the acromion process. It may occur in association with dislocation of the shoulder and fracture neck of the humerus.

EXAMINATION OF INJURIES AROUND THE ELBOW

A. **INSPECTION.**— A careful inspection of the patient when he enters the clinic gives to certain extent a clue to the diagnosis. A young child with swollen flexed elbow supported by his other hand is probably a case of supracondylar fracture of humerus.

1. **Attitude.**— Patients with injury to the elbow often present with swollen elbow in *flexed position*. Attitude of the elbow joint has to be observed from in front, behind and from side.

In FRONT, note : (i) *the position of the joint* — whether extended or flexed, pronated or supinated. In majority cases of injury to the elbow the joint is held in the position of flexion. (ii) *Carrying angle.*— This angle is the normal outward deviation of the extended and supinated forearm from the axis of the arm. This angle is normally 10° to 15°, but in case of females this angle is more. To note the carrying angle the patient is asked to stand in the anatomical position i.e. the forearm is extended and supinated. This angle should be noted on both the sides. The angle disappears on pronation or on full flexion of the forearm. When the carrying angle is abnormally increased the condition is called cubitus valgus and when it is abnormally decreased the condition is called cubitus varus (See Fig. 13.12).



Fig.13.12.— The normal carrying angle is seen on the right side whereas cubitus varus deformity is obvious on the left side.

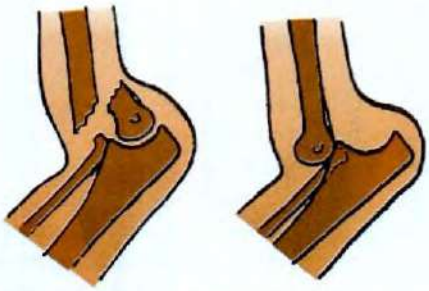

Figs.13.13. & 13.14.— Showing how olecranon becomes unduly prominent in supracondylar fracture and posterior dislocation of elbow.

From *BEHIND*, note the *position of the olecranon* — does it appear to be unduly prominent ? If it is so it does not always mean posterior dislocation of the elbow, to the contrary in children it is more likely due to supracondylar fracture of the humerus. Note also whether the olecranon is displaced sideways. In large number of supracondylar fractures, the lower fragment, besides being displaced backwards and upwards, is often shifted either laterally or medially. This will be evident by the position of the olecranon which moves along with the lower fragment.

From *THE SIDE*, note if *there is antero-posterior broadening of the elbow*. This is evident in posterior dislocation and supracondylar fracture.

2. **Swelling.**— Any injury to the elbow will give rise to tremendous amount of swelling. So much so that at times the diagnosis becomes difficult to make without X-ray examination. Sometimes localized swelling near the head of radius is probably due to fracture at this site. Similarly a swelling wholly confined to the posterior aspect of the elbow around the olecranon process is probably due to fracture of the olecranon process.

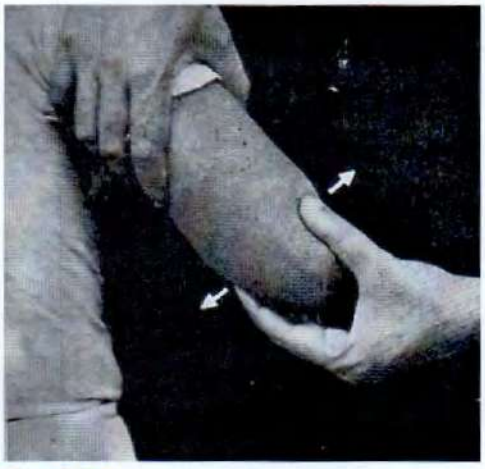

Fig. 13.15.— Showing how to test for abnormal mobility in a suspected case of supracondylar fracture. The arm is steadied with one hand while with the other hand two epicondyles are held and moved sideways with utmost gentleness.

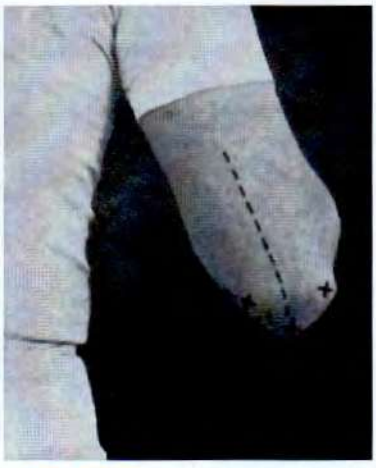

Fig. 13.16.— A midposterior line of the arm is drawn. This line passes through the olecranon process. Any deviation of the olecranon sideways can thus be demonstrated.

3. **Deformity.**— Sometimes an obvious deformity can diagnose the type of injury. An abnormal swelling in front of the upper part of the ulna with surrounding generalized swelling is probably due to Monteggia fracture. An abnormal protrusion of the olecranon process backwards in an adult is probably a case of posterior dislocation of the elbow. Similar deformity with an undue anterior prominence just above the elbow in children is probably caused by supracondylar fracture.

B. **PALPATION.**— Bones around the elbow are palpated systematically to look for any (i) **local bony tenderness;** (ii) **local bony irregularity;** (iii) **displacement** if any; (iv) **unnatural mobility;** (v) **crepitus;** (vi) **referred tenderness** etc. The bones to be palpated are the lower part of the humerus, the head of the radius, upper part of the ulna, the olecranon process and the relative positions of 3 bony points viz. the two epicondyles of the humerus and the olecranon process.

(1) **Lower third of the humerus.**— The most important fractures in this group are the supracondylar fracture in case of children and T — or Y— shaped supracondylar fracture in case of adult. Besides these there are fracture-separation of the lateral condylar epiphysis and separation of medial epicondylar epiphysis in case of children and fractured capitulum in case of adult which should also be kept in mind. While examining the lower end of the humerus first one should palpate both the epicondyles of the humerus with the thumb and the four fingers of the clinician. If it seems that there is no condylar fracture or separation, the clinician with his other hand should hold the upper part of the humerus and the lower fragment is made to move with the fingers of this hand. An abnormal mobility along with crepitus indicates supracondylar fracture. Utmost gentleness is expected from the clinician while examining this. Abnormal position of any epicondyle will suggest fracture separation of condylar epiphysis or fractured capitulum. Abnormal broadening of the lower end of the humerus with distortion of the condyles suggests T — or Y — shaped fracture.

(2) **Upper end of the radius.**— In the upper end of the radius two types of fractures are

commonly met with — fracture of the head of the radius (adults) and fracture of the neck of the radius (children). In both these circumstances there is no generalized swelling of the elbow, but there is localized swelling at the upper end of the radius.



Fig.13.17.— Note how to palpate the head of the radius. The forearm is pronated and supinated to feel that the head of the radius rotates.



Fig.13.18.— Springing the radius. The patient shows the site of pain.

The head of the radius can be best palpated in the lower part of the dimple just below the lateral condyle of the humerus when the forearm is pronated and supinated. This examination should be done in the flexed elbow (Fig. 13.17). In case of fracture of the radial head there will be tenderness and irregularity during rotation of the radius. Sometimes a referred pain can be elicited at the fracture site particularly at the neck and the upper part of the shaft of the radius *by springing the radius* (Fig. 13.18). This is done by squeezing the radius and ulna together at the lower part of the forearm, when the patient will complain of pain in the upper end of the radius.

While palpating the upper end of the radius one must also keep in mind the possibility of *dislocation of the head of the radius.* It may occur alone or may be associated with fracture-displacement of the upper third of the ulna either forwards (Monteggia fracture) or backwards (reversed Monteggia).

(3) **Upper part of the ulna.**— Palpation of ulna is rather easier as its one border is subcutaneous. The clinician should move his finger along the subcutaneous border of the ulna to detect any local bony irregularity or local bony tenderness to suggest a crack fracture of the ulna. Any obvious deformity in the ulna and an abnormal prominence of the displaced fragment suggest fracture of the upper end of the ulna with displacement. In these cases one must not forget to palpate the head of the radius as this is very often dislocated along with displaced fracture of the upper end of the ulna which is popularly known as Monteggia fracture if the displacement is anteriorly.

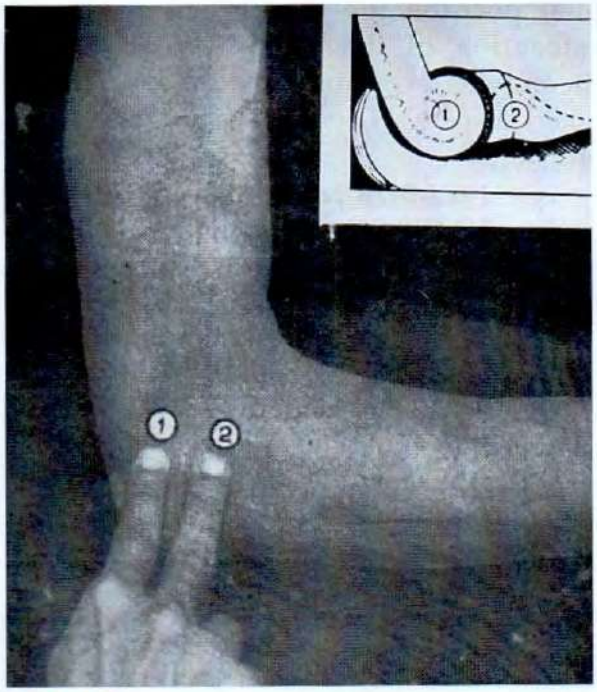

Fig.13.19.— By the index finger the lateral humeral epicondyle (1) is being felt and by the middle finger the head of the radius (2) is being felt. In the inset the relative position of these two bony points are being shown.

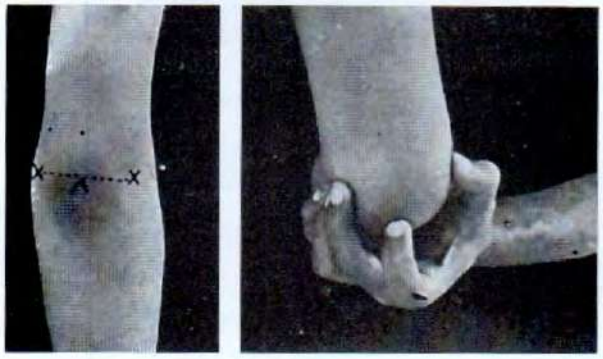

Figs. 13.20. & 13.21.— Show that the three bony points of the elbow viz. the two epicondyles and the olecranon lie in a line when the elbow is extended but form a triangle when the elbow is flexed.

(4) **Olecranon process.**— Importance of examining this process cannot be overemphasized. Local bony irregularity with bony tenderness suggests a crack fracture of the olecranon. When the fracture is associated with separation, there will be gap in between the two fragments. Abnormal projection of the olecranon process posteriorly suggests posterior dislocation of the elbow in adult and supracondylar fracture in children.

(5) **Relative positions of three bony points.**— The two epicondyles of the humerus are palpated with the thumb and the middle finger and the tip of the olecranon process is palpated with the index finger (Fig. 13.21). In extended elbow these three bony points lie on a straight horizontal line but in flexed elbow they form a triangle which is neither isosceles nor equilateral but has the shortest side between the medial epicondyle and the olecranon and the longest between the two epicondyles. *One should always compare the relative positions of these bony points with those of the sound side.* When the olecranon process is pushed more posteriorly and a little above its usual position the case is one of posterior dislocation of the elbow. When both the epicondyles are more widely separated one should suspect a T- or Y - shaped fracture of the condyles.

C. **MEASUREMENTS.**— While taking measurement, the forearm should be held at a right angle to the arm so that the epicondyles become prominent.

(1) The length of the arm is measured from the angle of the acromion to the lateral epicondyle of the humerus. The arm will be shortened in supracondylar fracture.

(2) The length of the forearm is measured from the lateral epicondyle of the humerus to the tip of the radial styloid process. The forearm will be shortened in posterior dislocation of the elbow.

(3) The three bony points i.e. the two epicondyles and the tip of the olecranon process are first marked with skin pencil before the three sides of the triangle are measured.

D. **MOVEMENTS.**— Unhindered movements of the elbow which include flexion, extension, pronation and supination suggest that there is no bony injury around the elbow joint.



Fig. 13.22.— Myositis ossificans traumatica.

Except injury to the upper end of the radius, which will only cause pain during pronation and supination movements, all other injuries around the elbow will cause pain and limitation of movements of flexion and extension. While testing the movements of pronation and supination, one should always keep the elbow of the patient flexed otherwise *in extended elbow rotation of the humerus will give a false impression of these movements.*

Complications.— Complications of fracture have already been dealt with generally. In injury around the elbow the fracture which causes maximum complications is the supracondylar fracture of the humerus. The complications are injury to the blood vessels, injury to the nerves, Volkmann's ischaemic contracture, Myositis ossificans traumatica etc.

(1) One should always *feel the radial pulse* while examining a case of an injury around the elbow joint.

(2) All the three main nerves which cross the elbow joint run the risk of being damaged by the supracondylar fracture. Even if there is no recent injury to any of these nerves, there remains a chance of late (tardy) ulnar palsy. *So one must examine for any neurological deficits* that might be caused by such injury around the elbow.

(3) *Volkmann's ischaemic contracture* is a sequel of inadequate blood supply to the forearm muscles. The brachial artery is commonly the victim either by thrombosis or spasm or kinking. This condition should be suspected if the patient complains of pain down the forearm after the fracture has been reduced and plastered. An attempt to extend the flexed fingers with extended wrist will cause pain.

(4) In no other condition is the *myositis ossificans traumatica so* common as after injury around the elbow. This is commonly seen in the brachialis muscle as a bony-hard mass. It is often a sequel of forcible massage and passive stretching of the elbow.

SPECIAL INVESTIGATIONS

X-ray examination.— Both antero-posterior and lateral views are essential to diagnose a bony injury around the elbow. Only antero-posterior view may not be able to detect such injuries as fracture of olecranon, posterior dislocation of the elbow and even the supracondylar fracture without lateral displacement. Similarly lateral view may fail to detect a fracture head or neck of the radius.

While interpreting a skiagram of the elbow joint after injury one must have a clear conception of time of appearance, the size, the shape, the position and time of fusion of all the epiphyses in the region of the elbow. Cases are not uncommon when epiphyseal line was erroneously diagnosed as fracture line and there was no real bony injury. The first centre of ossification appears in the capitulum in the first year and extends medially to form the chief part of the articular surface. In the fourth year in case of females and in the sixth year in case of males ossification begins in the medial epicondyle. At the same age the disc-like centre of ossification appears at the upper end of the radius. The centre for the medial part of the trochlea appears in the ninth year in females and tenth year in males. At about the same age or a year later a thin scale-like epiphysis appears on the top of the olecranon process. The centre of ossification in the lateral epicondyle appears at about the twelfth year in both sexes. The centres for the lateral epicondyle, capitulum and trochlea fuse around puberty and the large epiphysis thus formed unites with the shaft of the humerus in the fourteenth year in the females and the sixteenth year in the males. The upper epiphysis of the radius fuses with the shaft at the same age as the previous one (14th to 16th year). The upper epiphysis of the ulna also joins with the shaft at the same age. An additional centre sometimes appears in the tuberosity of the radius at about the fourteenth or fifteenth year. One more anatomical peculiarity has to be noted that the lower

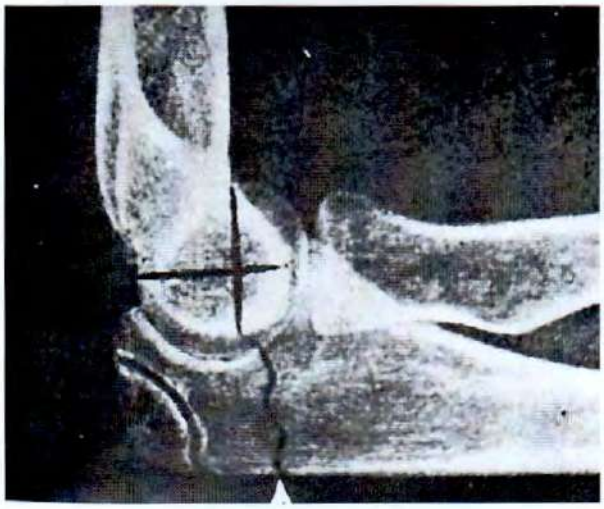

Fig.13.23.— Shows that a line drawn downwards along the anterior surface of the humerus divides the circular trochlea into anterior 1/3rd and posterior 2/3rd in the lateral X-ray film. This is due to the fact that the lower epiphysis of the humerus after it has fused with the shaft is bent anteriorly. Note also the position and shape of the epiphysis forming the olecranon. This must not be mistaken for a fracture which usually occurs at the base of the olecranon as shown by the arrow.

epiphysis of the humerus after it has fused with the shaft is bent anteriorly. This fact can be verified by drawing a line which is drawn downwards along the anterior surface of the humerus which divides the circular trochlea into anterior 1/3rd and posterior 2/3rd in the lateral X-ray film. This anterior bent is more prominent in case of females.

The following conditions are to be considered in injury around the elbow :—

1) Supracondylar fracture.
2) T-and Y-shaped fractures.
3) Fracture-separation of the lateral condylar epiphysis.
4) Fracture-separation of the medial epicondyle.
5) Fractured capitulum.
6) Fracture neck of the radius.
7) Fracture head of the radius.
8) Fracture of the olecranon process.
9) Posterior dislocation of the elbow with or without fracture of the coronoid process.
10) Subluxation of the head of the radius in children (Pulled elbow).
11) Monteggia fracture and reversed Monteggia.

DIFFERENTIAL DIAGNOSIS

Supracondylar fracture.— Though *backward supracondylar fracture* that means the lower fragment is displaced backward is much commoner, *yet forward supracondylar fracture* is occasionally seen with forward displacement of the lower fragment. The mechanism of backward supracondylar fracture is a fall on the hand with bent elbow, when the distal fragment is pushed backwards and twisted inwards as the forearm is usually full pronated. The displacement of the distal fragment is backwards, upwards, backward angulation with a slight internal rotation. The victims are usually children and present with a gross swelling at the elbow which is supported by the patient with his other hand. On examination there may be bruising and the posterior prominence of the elbow which requires differentiation from the posterior dislocation of the elbow. The possibility of an injury to the brachial artery as well as three main nerves should be foreseen and properly examined to exclude such possibility. An immediate reduction of the displaced fracture is essential and the elbow joint is kept flexed in collar and cuff in such a position as the radial pulse is well palpated.

The mechanism of forward supracondylar fracture which is very much rarer than its previous counterpart is caused by a fall on the stretched hand with fully extended elbow so that the lower fragment is tilted forward. The patient presents with a more extended elbow than its previous counterpart and swelling around the elbow. A careful palpation will reveal the forwardly tilted distal fragment.





Figs.13.24 & 13.25.— Supracondylar fracture of the humerus. The lower fragment is displaced laterally for a considerable distance which is obvious in anteroposterior film. It is also displaced backwards and upwards which is evident in the lateral film. The centre of ossifcation for the capitulum is likely to be mistaken for that of the head of the radius in anteroposterior view but not in the lateral view. In fact the centre of ossification for the head of the radius has not yet appeared.

Complications of supracondylar fracture are — (i) Malunion; (ii) Cubitus valgus or varus; (iii) Myositis ossificans traumatica; (iv) Injury to the brachial vessels; (v) Volkmann's ischaemic contracture; (vi) Injury to the nerves — ulna, median and/or radial.

T - and Y - shaped fractures.— These fractures are more commonly seen in adults and are caused by falls on the points of the elbows which drive the olecranon processes upwards splitting the two condyles apart. The patient presents with a grossly swollen elbow which is very much wide. The elbow remains slightly flexed supported by the other hand and movement is extremely painful and restricted. X-ray confirms the diagnosis.

Fracture-separation of the lateral condylar epiphysis.— The history is that the child has fallen on the hand and a large fragment including the lateral condylar epiphysis and a portion of the metaphysis break off. Swollen elbow and tenderness on the lateral condyle are the usual clinical features. X-ray is diagnostic.

Fracture-separation of the medial epicondyle.— The mechanism of injury is usually a severe abduction force and young children between ten and fifteen years of age are the usual victims (before the medial epicondylar epiphysis fuses with the shaft). The epiphysis is pulled distally by the attached flexor muscles. Sometimes it may be associated with lateral dislocation of the

elbow. The peculiar feature of this fracture is that besides slight rotational displacement the medial epicondyle may be included into the joint by the forced abduction which momentarily opens up the medial side of the joint and thus sucks in the fractured medial epicondyle. The possibility of injury to the ulnar nerve has already been emphasised. X-ray picture will detail the fracture and the displacement.

Fractured capitulum.— This is an adult injury and is caused by fall on the hand with the straight elbow. The anterior half of the capitulum and the trochlea are broken off and displaced proximally. The patient presents with fullness of rather an extended elbow. On examination, tenderness on the fracture site is without question. Flexion movement is extremely painful and limited. X-ray is diagnostic.

Fracture neck of the radius.— This commonly affects the children and is caused by a fall on the outstretched hand while the elbow is in slightly valgus position. It is actually an epiphyseal separation with a triangular metaphysis attached to it. The patient can usually flex and extend the elbow but rotation i.e. pronation and supination is painful and restricted. There is tenderness at the upper end of the radius with a lateral projection of the head of the radius which can be palpated. X-ray shows fracture of the neck of the radius with the head tilted forwards, outwards and distally.

Fracture head of the radius.— While the previous fracture is mainly a fracture of children, this fracture mostly affects the adults and the mechanism is more or less similar to that of the previous one that means a fall on the outstretched hand with the elbow on the valgus position so that the radial head is crushed against the capitulum. On examination there will be localized tenderness on the head of the radius and rotation of the forearm i.e. supination and pronation is painful and restricted though the patient may be able to flex or extend the elbow with a little pain. X-ray will confirm the diagnosis by showing either a vertical split in the radial head or a lateral major fragment of the head broken off and displaced laterally or a comminuted fracture with multiple fragments.

Fracture of the olecranon process.— A direct fall on the point of the elbow is probably the cause of fracture of olecranon. The fracture line is at the narrowest point of the olecranon almost where it joins with the shaft of the ulna and must not be confused with the epiphysial line which lies near the tip of the olecranon process. If the triceps muscle goes in action during the injury a gap is expected between the two fragments of the olecranon process.

If there is just a crack fracture, slight swelling, bruising, localized bony tenderness and bony irregularity will be the clinical features. The patient may be able to extend the elbow. Whereas in more severe injury with separation of fragments there will be more swelling, oedema and bruising at the fracture site. Palpation will reveal an obvious gap between the fragments. X-ray examination is obligatory not only to know the details of the fracture and displacement but also to assess the type of treatment which would be best suited for the particular case.

Dislocation of the elbow.— While there are possibilities of anterior and lateral dislocations yet the posterior dislocation is by far the commonest. The mechanism of posterior dislocation is a fall on the outstretched hand with the elbow in slightly flexed position. The coronoid process may pass posteriorly below the distal end of the humerus intact or may be fractured by the thrust against this part of the humerus. Very often the posterior dislocation is associated with lateral displacement of varying range.

Clinically this condition may mimic the supracondylar fracture and the *differentiating points between these two conditions* should be borne in mind. They are in dislocation of elbow (i) the patient is frequently an adult; (ii) palpation will reveal an abnormal posterior displacement of the olecranon process which will be obvious by palpating the three bony points; (iii) absence of

abnormal mobility and crepitus while an attempt is made to move the lower end of the humerus; (iv) there will be shortening of the forearm as measured from the lateral epicondyle of the humerus to the tip of the radial styloid process and (v) X-ray examination is probably the most important.

Subluxation of the head of the radius in children (pulled elbow).— Very often when a child is pulled suddenly by his forearm in the position of supination, there is a chance of the head of the radius being dislocated from the grip of the annular ligament. Generally such a history can be elicited and the patient presents with a complaint of pain at the elbow. The elbow is more or less fixed in slight flexion and pronation; more flexion of the elbow and supination become painful and limited. On palpation one may find the head of the radius a little below and lateral to its normal position.

Monteggia fracture and reversed Monteggia.— Fracture of the upper third of the ulna with displacement is often associated with dislocation of the head of the radius. When the displacement of the ulnar fracture is anteriorly and the head of the radius is dislocated anteriorly — this is known as *Monteggia fracture-dislocation.* When the displacement of the ulnar fracture is posteriorly and the head of the radius also dislocates backwards — this is known as *reversed Monteggia.*

Monteggia fracture is much commoner than reversed Monteggia. Mechanism is usually a fall on the hand and the body twists at the moment of impact thus forcibly pronating the forearm. The ulnar deformity is obvious on inspection. A careful palpation will reveal radial dislocation besides rather easy detection of ulnar fracture-displacement. Movement of the elbow joint is completely restricted — both extension and flexion as well as supination and pronation. X-ray is the final court of appeal to settle the diagnosis.

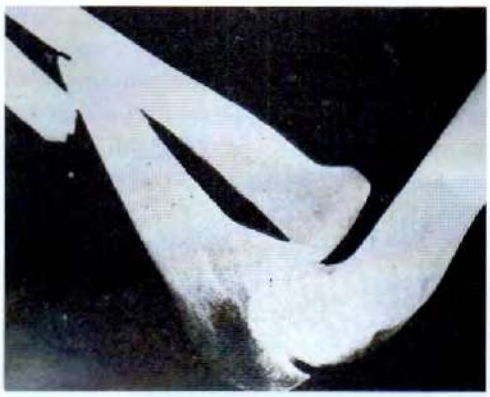

Fig.13.26.— Monteggia fracture.

EXAMINATION OF INJURIES AROUND THE WRIST AND HAND

A. **INSPECTION.**—

1. **Deformity.**— (a) The characteristic "dinner-fork" deformity of *Colles' fracture* do not require any detailed discussion. But two points deserve mentioning — (i) that the dorsal prominence is *not* at the level of the wrist but about one inch above it and (ii) that there is also a slight radial deviation which makes the head of the ulna more prominent.

(b) An abnormal slight anterior projection at the wrist following a fall on the dorsiflexed hand is due to *dislocation of the lunate bone.*

(c) Fracture of the lower third of the radius with inferior radio-ulnar dislocation which is

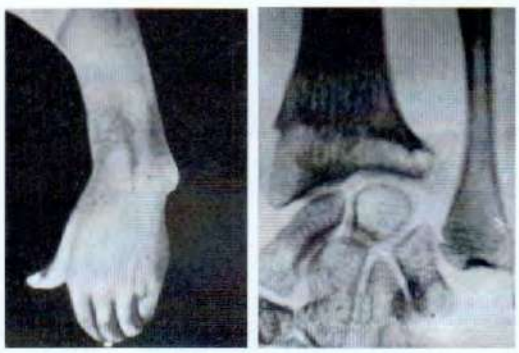

Figs.13.27. & 13.28.— Manus valgus (Madelung's deformity), resulting from injury to the lower radial epiphysis six years ago. The growth of the radius has been stopped and the normally growing ulna (shown in the skiagram) pushes the hand outwards.

known as *Galeazzi fracture* is sometimes quite obvious on inspection.

(d) In *Madelung's deformity* or *manus valgus* there is dorsal subluxation with prominence of the lower end of the ulna in an adolescent girl. The hand is deviated laterally.

(e) In *Bennett's fracture-dislocation* the typical abnormal lateral projection at the base of the first metacarpal bone is quite obvious.

(f) In *metacarpal fractures* abnormal bony projections almost make the diagnosis obvious. When the patient is asked to make a fist, the line of knuckles may not be on the normal line.

(g) In case of fracture of the phalanges the finger becomes unduly swollen and deformed. In *"mallet finger"*, which is caused by rupture of the extensor tendon at its insertion at the base of terminal phalanx, there is persistent flexion of the terminal phalanx.

(h) In dislocation of the interphalangeal and metacarpo-phalangeal joint anterior projection of the head of the phalanx or the head of the metacarpal as the case may be becomes obvious.

B. **PALPATION.**— In injury around the wrist one should palpate the neighbouring bones systematically to elicit (i) **Local bony tenderness;** (ii) **bony irregularity;** (iii) **displacement;** (iv) **unnatural mobility** and (v) **crepitus.**

1. **Lower third of the radius.**— In suspected fracture of the lower third of the radius, one should follow the outer border as well as the dorsal aspect of the bone for any irregularity and tenderness. It must be remembered that normally the lower third of the radius is smoothly concave in front. Feel whether this concavity is preserved or not. In Colles' fracture there is posterior displacement of the lower fragment which becomes obvious on palpation.

Springing the radius may be of help to diagnose fracture of the lower third of the radius above the typical site of Colles' fracture, which is surrounded by muscles and tendons and not so available for direct palpation. In this case squeezing of the upper part of the radius and ulna together will elicit pain at the site of fracture.



Fig.13.29.— Normally the tip of the radial styloid process is about 1 cm lower than the tip of the ulnar styloid process. The dotted line represents the horizontal level at the tip of the ulnar styloid process.

2. **Lower third of the ulna.**— It must be borne in mind that in Colles' fracture as well as in the fracture of lower third of the radius it is of immense importance to palpate the head of the ulna. In Colles' fracture very often the styloid process of the ulna is also fractured and in fracture of the lower third of the radius very often the head of the ulna is dislocated (Galeazzi).

Otherwise palpation of the ulna is easy being a subcutaneous bone. Fracture of the ulna as such will elicit tenderness and bony irregularity.

3. **Relative position of the two styloid processes** (Radial and ulnar).— Normally the radial styloid process is about half an inch lower than the ulnar styloid process. In order to demonstrate this, the clinician uses his two index fingers to locate the tips of the styloid processes in pronated forearm of the patient. In Colles' fracture the radial styloid process will remain at a higher level than normal, in fact they may remain on the same line. This is also a diagnostic feature of Colles' fracture.

4. **Carpal bones.**— Of the carpal bones palpation of the scaphoid bone is most important as very often fracture of the scaphoid is misdiagnosed as simple sprain and the patient continues to suffer from disability and painful wrist for a long

time. Moreover fracture of the scaphoid requires prolonged immobilization as this fracture is notorious for non-union and avascular necrosis of the proximal fragment. The scaphoid is palpated at the anatomical snuff-box with the wrist bent medially to expose the bone for palpation. If there is any fracture of the scaphoid bone, the patient will complain of pain as soon as a pressure is made over the anatomical snuff-box.

Another important carpal bone which should be considered here is the lunate bone. This bone may be dislocated anteriorly and requires careful palpation for the diagnosis of this condition.

5. **Metacarpals and phalanges.**— To feel for fracture or dislocation of the metacarpals and phalanges one should palpate the full length of the metacarpal bone or the phalanx. For this, the examiner should run his finger along the length of the said bone to find out any gap, bony irregularity, bony tenderness or abnormal projection. In Bennett's fracture i.e. fracture-dislocation of the base of the first metacarpal, a traction along the axis of the bone often elicits tenderness at the site of fracture.

A careful palpation of the metacarpo-phalangeal joints and inter phalangeal joints should be a must to exclude subluxation or dislocation of the said joints which are often missed.

C. **Movements.**— Movement of the affected part will obviously be painful and limited. As for example in Colles' fracture movement of the wrist will be restricted. In case of metacarpal fractures movement of the metacarpo-phalangeal joints will be restricted. Similarly in fractures of the phalanges movement of the interphalangeal joints will be painful and restricted.

D. **Complications.**— These have been discussed in details in the previous chapter. In differential diagnosis complications of the important fractures around the wrist will be discussed in nut-shell.

X-ray examination.— As in any other bony injury importance of X-ray examination cannot be re-emphasized here. In all fractures, not only the fracture is diagnosed but also a careful study of the displacement of the fractured fragments will help the clinician in reduction of the fracture concerned. As for example in Colles' fracture, the lower fragment is displaced backwards, upwards and laterally and is also tilted backwards so that the articular surface of the lower end of the radius looks more posteriorly than anteriorly (which is normal). In this case, to reduce the fracture a pull is directed downwards, slightly medially and anteriorly holding the thumb and the heads of the metacarpals of the patient simultaneously, while with the two thumbs of the clinician the upper edge of the lower fragment is pushed anteriorly so that the normal alignment of the radius is restored.

After discussing the general points, the peculiarity of the X-ray examination of the scaphoid requires special mention. Very often the orthodox antero-posterior and lateral views fail to detect a minor crack fracture of the scaphoid. For this *an oblique view* and views from different angles are very much essential to diagnose fracture of the scaphoid bone. Even a negative X-ray finding does not exclude the presence of fracture. If clinical findings go very much in favour of the diagnosis of fracture of the scaphoid, one should treat the case according to that and take another X-ray after ten days, as by that time the fracture line often delineates itself.

The following conditions are to be considered in injury around the wrist :

1. Colles' fracture with or without fracture of the ulnar styloid process.
2. Smith's fracture or reversed Colles'.
3. Chauffeur's fracture of the radius just above the radial styloid process, caused by the backward jerk of the starting handle of a car.
4. Galeazzi fracture.
5. Scaphoid fracture.

6. Lunate and peri-lunate dislocation.
7. Bennett's fracture-dislocation.
8. Fractures and dislocations of the metacarpals and phalanges.
9. Mallet finger.

DIFFERENTIAL DIAGNOSIS

Colles' fracture.— This injury is caused by a fall on the palm of the outstretched hand with a supination force. The victims are usually elderly ladies, which is attributed to the osteoporosis in post-menopausal women. The fracture line lies about 2 cm proximal to the distal articular surface of the radius. The distal fragment is displaced dorsally, proximally, slightly laterally and angulated backwards.



Fig. 13.30.— Colles' fracture.

The patients present with swelling and dinner-fork deformity of the wrist. On examination, there is tenderness and bony irregularity of the lower end of the radius. The normal anterior concavity of the radius is lost. The radial styloid process does not remain lower than the ulnar styloid process which is normal. On the contrary it remains at the same level or a little higher than the ulnar styloid process. Mal-union, manus valgus and stiffness of the wrist, are the usual complications. The complications which are peculiar to this fracture are Sudeck's osteodystrophy, causalgia and spontaneous rupture of the extensor pollicis longus tendon which may be due to friction over the ridge of the bone at the site of fracture or due to degeneration of the tendon following insufficient blood supply.

Smith's fracture (reversed Colles').— A true reversed Colles' fracture, that means a transverse fracture of the lower end of the radius with anterior displacement of the lower fragment is very rare. Again the usual victims are the elderly women and diagnosis both clinically by anterior projection of lower fragment and radiologically is not very difficult. The mechanism is due to a fall on the dorsum of the palmar-flexed wrist and not to a fall on the palm of the outstretched hand. A commoner injury at this region with anterior displacement is the fracture dislocation of the lower end of the radius. In this case the radial fracture is obliquely vertical extending upwards and forwards from the wrist joint and separated anterior fragment of the radius shifts proximally carrying the hand with it.

Chauffeur's fracture.— The typical history is that the patient wanted to start his vehicle with a starting handle and ultimately injured his wrist by the kick back. The fracture line is usually transverse extending laterally from the articular surface of the radius and the fracture is more often undisplaced.

Galeazzi fracture.— This is in fact a fracture-dislocation of the lower end of the radius with dislocation of the inferior radio-ulnar joint. The mechanism seems to be fall on the hand with a rotational force superimposed on it. On examination there is undue swelling of the lower end of the forearm



Fig. 13.31.— Diagrammatic representation of Galeazzi fracture.

due to displaced fracture of the radius and an abnormal prominence of the head of the ulna due to dislocation of the inferior radio-ulnar joint. The most important test which most clinicians forget to perform is to look for ulnar nerve lesion — a common associate with this condition. X-ray examination is confirmatory.

Madelung's deformity.— There is dorsal subluxation of the lower end of the ulna. The patient is usually an adolescent girl who complains of weakness of the wrist. On inspection there is a very prominent dorsal displacement of the lower end of the ulna. Palpation reveals a grossly unstable inferior radio-ulnar joint. Controversy still exists whether this condition is congenital or acquired. While majority favour congenital theory, yet the advocates of acquired theory postulate that repeated minor injuries may delay growth of the radius while the ulna continues to grow forcing the lower end of the ulna to subluxate.

Scaphoid fracture.— The history is usually a fall on the outstretched hand and the force is the combination of dorsiflexion and radial deviation in which the waist of the scaphoid is impacted against the radial styloid process. Young adults are usually the victims. The appearance of the wrist is deceptively normal most of the time with little impairment of the function of the wrist. Sometimes there may be slight fullness of the anatomical snuff box. The main help to the diagnosis is suspicion of such a fracture. Tenderness at the anatomical snuff box, while the wrist is deviated medially adds more to the suspicion. X-ray is confirmatory, but the first X-ray may not show any fracture and typical 'scaphoid views' are to be taken to exclude such fracture. Repeated X-ray after a week or so is essential when the suspicion still remains even after the negative first X-ray.

The importance of this fracture is mainly due to the fact that it is notorious for two complications — (i) non-union for which a prolonged immobilization is required and (ii) avascular necrosis of the proximal fragment which may later on cause osteoarthritis of the wrist joint.

Lunate and perilunate dislocations.— The mechanism is again a fall on the dorsiflexed hand which displaces the whole of the carpus backwards leaving only the lunate in contact with the radius (perilunar dislocation). Usually the hand immediately snaps forward again but while doing so the lunate is displaced forwards out of position (lunate dislocation). Sometimes the lunate bone may be dislocated without prior perilunar dislocation and this is probably due to forced dorsiflexion of the wrist which throws away the lunate bone forwards. These dislocations may be associated with fracture of the scaphoid.

On examination, the displacement of the lunate may be obscured by swelling of the wrist. A careful palpation may diagnose the condition. Median nerve compression in the carpal tunnel occurs almost always with this condition and a particular examination in this regard is very much essential. X-ray examination is again confirmatory and a lateral view is more essential for the diagnosis of this condition. The antero-posterior view is important to exclude the associated fracture of the scaphoid. The most important complication of lunate dislocation, besides the median nerve injury, is avascular necrosis *(Kienbock's disease)*.

Bennett's fracture-dislocation.— The usual history is an attempted punch to the point of the thumb. It is an oblique fracture at the base of the first metacarpal bone extending distally and medially from its articular surface. So a triangular piece of bone remains in its position whereas the main shaft dislocates proximally and laterally on the trapezium. On examination there is abnormal swelling at the base of the first metacarpal bone and if the clinician pushes the projection distally and medially with his thumb the dislocated shaft moves causing a great pain to the patient.

Fractures and dislocations of the metacarpals and phalanges.— The fractures of the shaft

and neck of the metacarpals are diagnosed by localized swelling, deformity, bony irregularity and bony tenderness. Fractures of phalanges are also diagnosed clinically in the same way. Dislocation of the metacarpo-phalangeal joint is diagnosed by careful palpation at the metacarpo-phalangeal joint where the head of the metacarpal bone is dislocated anteriorly most of the time. A careful palpation will also diagnose dislocation of the interphalangeal joint. X-ray is confirmatory in all these conditions.

Mallet finger.— This is due to rupture of the terminal slip of the extensor tendon to the distal phalanx or avulsion-fracture of a small piece of bone where the extensor tendon is inserted at the base of the distal phalanx. The cause is usually a forced flexion of the terminal phalanx when the extensor is contracting. On examination, the typical flexion deformity of the terminal phalanx to a position of 30° flexion is obvious. The patient is unable to extend the distal interphalangeal joint to the full extent. Of course passive extension is possible. Radiological investigation is of value in case of chip fracture of the terminal phalanx.

EXAMINATION OF INJURIES TO THE PELVIS

History of severe violence directly to the pelvis or indirectly through the thigh is usually obtained. Patient complains of severe pain in the region of the pelvis, which gets worse on moving the legs or the body.

On examination, bruising and swelling over the injured site can be easily revealed. A careful palpation of the whole pelvis is required to know the exact type of fracture. In multiple injuries one can exclude the possibility of any bony injury to the pelvis by pressing two iliac bones and the greater trochanters medially by the two hands of the clinician (See Fig. 13.32).



Fig. 13.32.— In case of injury to the pelvis patient complains of pain when the two iliac bones are pressed medially by two hands of the clinician.

Fracture of the pelvis can be classified into four groups.—

(a) *Isolated pelvic ring fractures,* i.e. the pelvic ring is broken at one place and the displacement is naturally slight. Chance of complication is rare. In this group are the fracture of the blade of the ilium, fracture of the floor of acetabulum with central dislocation of the hip and fracture of ischiopubic ramus.

(b) *Pelvic ring disruption* i.e. the pelvic ring is broken at two places with considerable displacement and disruption.

(c) *Avulsion fracture* commonly occurs at the anterior superior iliac spine (sartorius avulsion), anterior inferior iliac spine (rectus avulsion) and ischial tuberosity (hamstring avulsion).

(d) *Injuries to the sacrum and coccyx.* One must be very methodical in palpating the parts of the pelvis one by one to elicit the fracture which might have occurred.

X-ray examination is confirmatory and besides antero-posterior and lateral views, stereoscopic views are also required to diagnose fracture which may not be evident in these views.

Examination of visceral complications.— Fracture of the pelvis is notorious for visceral complications, of which damage to the urethra and/or bladder is important. Injury to both these

structures occurs commonly in fracture of the pubic bone.

Injury to the urethra is diagnosed by the three classical signs — blood per urethrum, perineal haematoma and distended bladder.

Injury to the bladder are of two varieties — *extraperitoneal* (commoner) and *intraperitoneal.* Extraperitoneal rupture is sometimes difficult to differentiate from the rupture of the posterior urethra. Of course the diagnosis of these conditions are discussed more elaborately in the chapter of "Examination of a urinary case", yet it is sufficient to narrate at this stage that a straight X-ray with ground glass appearance of fluid in the lower abdomen and intravenous pyelography with descending cystography may confirm a leak in the bladder.

EXAMINATION OF INJURIES AROUND THE HIP

History of severe violence e.g. motor car collision (dashboard dislocation), a fall from a height or falling of a heavy weight on the back of a stooping workman is usually obtained in dislocation of the hip. A direct impact on the greater trochanter medially may drive the head of the femur through the floor of the acetabulum into the pelvis causing central dislocation of the hip. Minor injuries such as stumbling or missing a step or a fall on slippery surface may cause fracture of the femoral neck in elderly persons. So adequate emphasis should be laid on elicitation of the history to come to a proper diagnosis. Even an enquiry should be made in a case of suspected fracture neck of femur. Whether the patient was able to get up after the fall (which indicates the fracture to be impacted) or he was on the floor helpless and was unable to move his leg (unimpacted fracture).



Fig. 13.33.— Note the typical attitude of external rotation of the left lower limb due to fracture of the femoral neck.



Fig. 13.34.— Posterior dislocation of right hip. Note the characteristic attitude of flexion, adduction and internal rotation of the thigh.

A. **INSPECTION.**— 1. **Attitude.**— The attitude of the patient on the bed after the injury will itself indicate the diagnosis. An elderly patient lying helplessly on the bed with *externally rotated,* lower limb indicates fracture of the neck of the femur. Young patient lying with similarly *externally rotated, slightly abducted and flexed* lower limb indicates anterior dislocation of the hip which is not very common in comparison to the posterior dislocation. In the latter condition young patient lies with *flexed, adducted and internally rotated lower limb.*

2. **Swelling.**— Abnormal swelling and bruising will be evident in the injured hip either due to haematoma in case of fracture neck of femur or due to abnormal position of the head of the femur.

3. A note should be made whether the injured limb appears to be shortened or lengthened (see under "Measurement").

B. **PALPATION.**— 1. **Greater trochanter.**— Palpation of the greater trochanter and its relation with other bony points are the key-stones for diagnosis of injuries around the hip.



Fig.13.35.— Showing the method of palpation of the greater trochanter and how to determine Bryant's triangle.

A triangle formed by the anterior superior iliac spine, the greater trochanter and a line drawn vertically downwards from the anterior superior iliac spine is called the *Bryant's triangle*. When the shortest side of the triangle i.e. the distance between the tip of the greater trochanter and a point on the imaginary line drawn vertically downwards from the anterior superior iliac spine, becomes shortened, it indicates a fracture of the femur, posterior dislocation of the hip and separation of the upper femoral epiphysis. This indicates upward displacement of the greater trochanter.

In posterior dislocation of the hip, the greater trochanter moves towards the anterior superior iliac spine due to internal rotation of the limb. In anterior dislocation or fracture of the neck of the femur the greater trochanter recedes from the anterior superior iliac spine due to external rotation of the femur.

If the greater trochanter lies in its normal position but the lower limb is externally rotated, the possibility of fracture below the greater trochanter (subtrochanteric fracture) should be kept in mind. This is confirmed by absence of transmitted movement i.e. the greater trochanter fails to move while the leg is rotated (Fig 13.36).

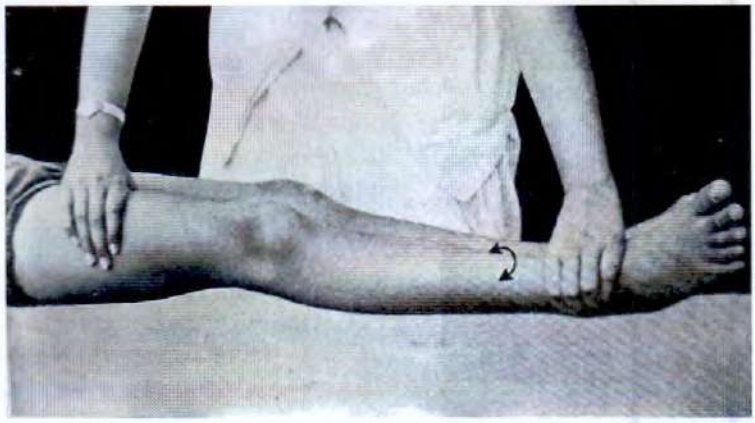

Fig.13.36.— In fracture below the trochanters, the greater trochanter will remain immobile while the shaft of the femur is being rotated.

2. **Head of the femur.**— A search should be made to find out the position of the head of the femur. In different types of dislocation the position of the head of the femur will vary. It may be on the dorsum ilii (posterior type), in the groin (pubic type) or rarely in the perineum (obturator type). Confirm the identity of the head by noting that it moves with rotation of the shaft. In this context one must remember that *medial surface of the medial condyle looks to the same direction as the head of the femur.*

Another important point in this regard is the palpation of the femoral artery at the base of the femoral triangle. Normally it is well palpated as the artery is being supported from behind by the head of the femur. In posterior dislocation due to the absence of the head of the femur in its normal position the artery cannot be palpated so easily.

3. **Tenderness.**— Bony tenderness on the site of fracture will be obvious particularly in trochanteric fracture. In transcervical and subcapital fractures, tenderness can only be elicited when an attempt is made to rotate the shaft of the femur.

C. **MEASUREMENTS.**— Various types of measurement can be tried in injuries around the hip.

1. **Bryant's triangle.**— The patient lies in the dorsal position. A line is drawn vertically downwards from the anterior superior illiac spine. Another from the tip of the same spine to the tip of the greater trochanter and lastly a horizontal line is drawn from the tip of the greater trochanter to the first line. Diminution in the length of the last line or the horizontal line in comparison to the other side denotes an upward elevation of the greater trochanter, the commonest cause of which being the transcervical or subcapital fracture of the neck of the femur or separation of the upper femoral epiphysis. Diminution or increase in the length of the second line indicates the anterior or posterior displacement of the greater trochanter accordingly (which occurs in posterior dislocation and anterior dislocation of the hip respectively).

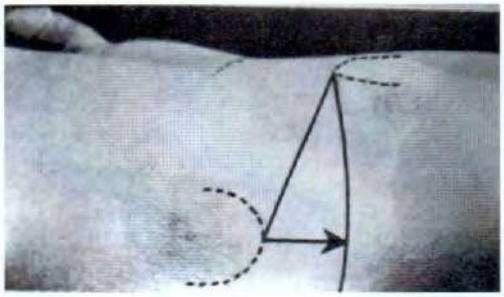

Fig.13.37.— Bryant's triangle. Elevation of the greater trochanter is determined by comparing the horizontal line (shown by arrow) with that of the normal side.

2. **Nelaton's line.**— The patient lies on his sound side. A line is drawn or a measuring tape is placed from the most prominent part of the ischial tuberosity to the tip of the anterior superior iliac spine. Normally, this line touches the tip of the greater trochanter and therefore any upward displacement of the trochanter can be easily demonstrated without comparing it with the other side.

3. **Schoemaker's line.**— The line from the tip of the greater trochanter to the anterior superior iliac spine if prolonged anteriorly will reach the umbilicus of the patient. This is called Schoemaker's line. If the greater trochanter is elevated the line will cross the midline below the umbilicus.



Fig.13.38.— Shows how to draw Nelaton's line with a measuring tape from the most prominent part of the ischial tuberosity to the tip of the anterior superior iliac spine. See that this line normally touches the tip of the greater trochanter.

4. **Morris' Bitrochanteric test.**— The distance between the outer border of the greater trochanter to the symphysis pubis is measured on both sides by means of a pair of calipers and is compared with the other side. It will reveal any medial (posterior and central dislocation) or lateral (anterior dislocation of hip) displacement of the trochanter.

5. **Chiene's test.**— Normally, a tape joining the tips of the greater trochanters is parallel to another joining the two anterior superior iliac spines. When a trochanter is raised, these two lines converge towards the affected side.

6. **Length of the lower limb.**— Before taking measurement of the affected limb, the normal limb must be placed in the identical position and there should not be tilting of the pelvis as determined by the line joining the two anterior superior iliac spines. The length of the lower limb is measured from the anterior superior iliac spine to the medial malleolus. The thigh alone

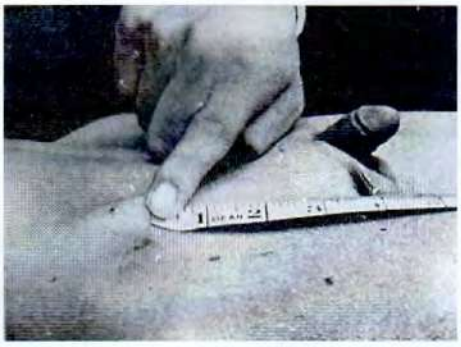

Fig.13.39.— Shows how to hold the metal end of the measuring tape against the anterior superior iliac spine.

is measured from the anterior superior iliac spine to the joint-line of the knee which can be easily felt in the flexed position of the knee. It was customary to make the upper border of the patella or more commonly the adductor tubercle as the lower landmark instead of the joint line. But the former is moveable and the latter is difficult to locate particularly in obese individuals. It is always advisable to mark the bony points first and then measured with the measuring tape. Shortening is expected in all the fractures and dislocation with the sole exception of the obturator type of anterior dislocation in which slight lengthening may be present.

D. **MOVEMENTS.**— All movements of the hip joint to the full extent exclude possibility of any bony injury. If the patient is able to lift his leg off the bed keeping the knee straight, it indicates no bony injury around the hip. It must be remembered that some use of limb is possible in an impacted fracture of the neck of femur. In posterior dislocation, there is complete limitation of abduction and lateral rotation whereas slight adduction and internal rotation may be possible.

Complications.— (a) Excessive bleeding at the fracture site and shock after fracture neck of femur is not unusual. Blood transfusion is often required at the time of operation. (b) Sciatic nerve injury may occur in posterior dislocation of the hip and subtrochanteric fracture. Femoral nerve may be rarely injured in pubic type of dislocation and the obturator nerve in the obturator type of dislocation.

Rectal examination is essential in central dislocation of the hip joint where the head of the femur lies within the pelvis. While doing rectal examination if the limb is rotated, the head of the femur can be felt rotating by the finger in the rectum. Central dislocation very much resembles fracture neck of femur. By the medial displacement of the greater trochanter, shortening and pain down the course of the obturator nerve this rare condition can be diagnosed.

X-RAY EXAMINATION.— This is again the most important investigation which will not only indicate the type of injury but also will give a clue to the line of fracture, the type of displacement, the type of treatment to be required for the particular case and the probable outcome of the treatment.

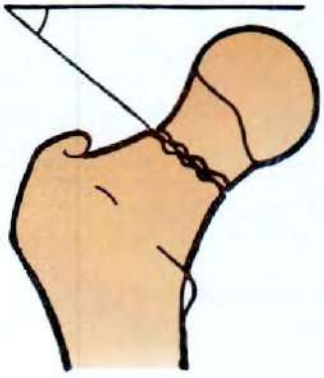

Fig.13.40.— Shows Pauwel's angle formed by the fracture-line with the horizontal plane.

So far as the **fracture neck of the femur** is concerned, there are five types of fractures according to the site of fracture which will be evident in skiagram. The fracture may be situated at (i) high in the neck (subcapital), (ii) low in the neck (basal), (iii) in the middle of the neck (transcervical), (iv) in the trochanteric region and (v) just below the trochanter (subtrochanteric). The angle of the fracture line is also important, as more vertical it is, the less favourable is the prognosis. In this context one may draw *Pauwel's angle* which is formed between the fracture line and an imaginary horizontal line. How much rotation the shaft has undergone after the fracture can be assessed by looking at the lesser trochanter. It is normally situated at the posteromedial aspect of the femur and is partly visible in X-ray. When the femur

is externally rotated it is clearly visualized and when the femur is internally rotated it becomes concealed by the superimposed shadow of the femur. In trochanteric fracture, it is often comminuted with three or four pieces and indicates difficulty in fixation (Fig. 13.41).

So far as the **dislocation of hip** is concerned, the orthodox anteroposterior and lateral views will give a clue to the position of the head of the femur — whether the dislocation is an anterior one or central or posterior one. There will be definite distortion of the Shenton's line.

In injuries about the hip the followings are important and worth mentioning :

1. Fracture of the neck of the femur.
2. Dislocation of the hip.
3. Avulsion fracture of the lesser trochanter.

FRACTURE OF THE NECK OF THE FEMUR.— Classically an old patient after trivial injury such as missing a step or falling down on the ground sustains an injury to the hip for which he neither moves his limb nor finds himself capable of getting up. On examination there will be swelling and bruising in the region of the greater trochanter. The limb will be seen externally rotated and there is definite shortening of the limb. There is tenderness near the greater trochanter. Relative elevation of the greater trochanter will be evident by Bryant's triangle and Nelaton's line. X-ray is confirmatory.



Fig.13.41.— Fracture neck of the right femur at its base (intertrochanteric).



Fig.13.42.— Central dislocation of the hip. Note that the head of the femur has been pushed through the broken acetabulum into the pelvis.

Complications are (i) Avascular necrosis of the head of the femur, (ii) malunion, (iii) non-union and (iv) late osteoarthritis.

DISLOCATION OF THE HIP.— The *posterior dislocation* is by far the commonest. This is diagnosed by (i) history (see above), (ii) the attitude of flexion, adduction and internal rotation of the limb, (iii) shortening, (iv) rigidity of the hip towards the movements of abduction and external rotation and (v) difficulty in feeling the pulsation of the femoral artery. X-ray will show the displaced head on the dorsum ilii.

Anterior dislocation, which results from a classical accident in which a man stands with one foot on the river bank and the other on a boat which is gradually moving away from him, so that the limb concerned is gradually abducted until it dislocates anteriorly. The lower limb takes an attitude of flexion, abduction and external rotation. The head of the femur is easily palpated by the side of the symphysis pubis in the pubic type and under the adductor muscles in the obturator type in which the limb appears to be lengthened.

Central dislocation is rare accident in which the femoral head is forced through the broken acetabulum. When this is suspected a finger in the rectum will feel the head of the femur in the pelvis and will be moving on rotation of the thigh. More often the condition is not recognized until an X-ray is taken.

Avulsion fracture of the lesser trochanter.— Classically it occurs at school boy age by a violent contraction of the iliopsoas muscles. The pathognomonic sign is inability to flex the stretched leg when the patient is seated (Ludloff 's sign).

EXAMINATION OF INJURIES IN THE THIGH

HISTORY.—

(i) **Age.**— Fracture of the shaft of the femur may occur at any age. An enquiry should be made regarding the severity of the injury. Though slightly oblique or transverse fracture of the shaft of the femur in young age is very common in motor cycle accident, yet this type of fracture in older age group with minor trauma should raise the suspicion of malignancy.

(ii) **Mechanism of injury.**— Direct injury of angulation force will cause slightly oblique or transverse fracture. When the foot is anchored to the ground a twisting force transmitted to the femur will cause a spiral fracture.

LOCAL EXAMINATION

A. **INSPECTION.**— **Abnormal swelling** and deformity in the thigh after an injury are probably due to fracture of the shaft of the femur. The **attitude** that the patient is lying helplessly also goes in favour of fracture of the shaft of the femur.

B. **PALPATION.**— **Bony irregularity, local tenderness** and **crepitus** are the diagnostic features, as in case of other fractures. So far as the **displacement** is concerned, it depends on the site of fracture. In fracture of the *upper third* of the femur, the proximal fragment is flexed by the iliopsoas muscle, abducted by the gluteal muscles and everted by the external rotators, but the lower fragment is adducted by the adductor muscles and overlapped proximally by the hamstrings and quadriceps and everted by the weight of the limb. In case of fracture of the *middle third and lower third of* the femur the deformity is the backward angulation and overlapping of the distal fragment by the action of the gastrocnemius and quadriceps respectively.

C. **MEASUREMENTS.**— Shortening of the length of the femur measured from the tip of the greater trochanter to the joint line of the knee joint is the marked feature of the fracture of the shaft of the femur.

X-ray is confirmatory.

EXAMINATION OF INJURIES AROUND THE KNEE JOINT

HISTORY.— To come to a diagnosis about the type of injury the knee has sustained one must take a thorough history. Most emphasis should be laid on the following points :—

Mechanism.— The details of the type of injury and the position of the knee joint in respect to the body as a whole at the time of injury should be considered. A blow on the lateral side of the knee when the patient is bearing weight on the leg will stress the medial collateral ligament. If the violence is relatively weak and only some fibres but not the whole of the ligament give way, it is called a simple *sprain*. If the violence is very severe, the ligament may be ruptured in its entirety usually at its femoral attachment. A blow on the medial side of the knee, which is very rare may cause injury to the lateral collateral ligament. When a backward thrust is given to the anterior aspect of the tibia with the knee joint flexed an injury to the posterior cruciate ligament may be expected. This may occur to the front-passenger in a motor car if he is thrown violently forwards against the dash board during sudden break or accident. Isolated injury to the anterior cruciate ligament is rather uncommon and only occurs when the knee is forcible hyperextended. *Injury to the menisci* is very important and peculiar to the knee joint. It occurs commonly to the footballers and coal miners. Tears of degenerated menisci also occur in the osteoarthritic knees. The medial meniscus is more often damaged than its lateral counterpart. The mechanism is rotation of the tibia on the femur when the knee is flexed and carrying weight of the body. The medial meniscus is damaged when the femur is internally rotated on the tibia and the lateral meniscus is damaged when the femur is externally rotated on the tibia. Just after injury the joint gives way and becomes swollen due to effusion. Sometimes the joint becomes 'locked' i.e. it cannot be extended after a limit. At times after a period of temporary inactivity the footballer stands up and continues the game for the rest of the period. But he gradually realizes that his knee is giving way in minor injuries and may be swollen and even 'locked'. Locking of the knee joint, unlike locking of the door, means the joint can be flexed freely but cannot be extended beyond certain degree.

Locking of the knee joint may also occur due to presence of loose bodies the causes of which are discussed later in this chapter. The bony injuries around the knee joint may occur from direct injuries or indirect injuries such as muscular violence which may cause fracture of the patella of the other knee joint when one leg slips.

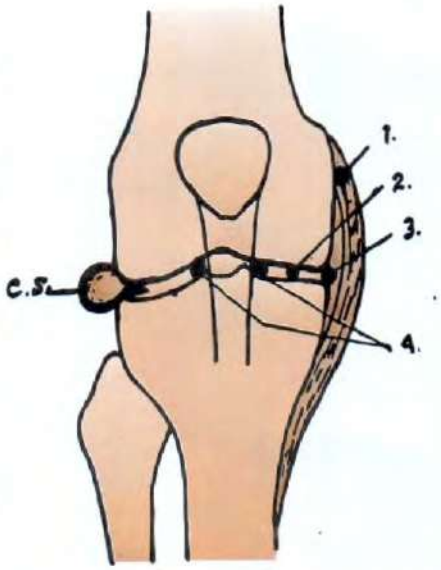

Fig.13.43.— Points of tenderness 1.— sprain of the medial collateral ligament, 2.— injury to the medial semilunar cartilage, 3.— sprain of deep fibres of the medial collateral ligament and injury to the semilunar cartilage, 4.— injury to the infra-patellar pad of fat. C.S.— cyst of the semilunar cartilage (common on the lateral side).

LOCAL EXAMINATION

A. **INSPECTION.**— The patient should lie down on the examining table with the two lower limbs *completely exposed* and placed in *identical position*. Inspection should be made from all aspects *including the popliteal fossa*.

(1) **Attitude.**— This is particularly important when the knee is locked in flexed position. The joint should be carefully inspected whether it is abducted or adducted, hyperextended or displaced backward.

(2) **Swelling.**— After many injuries the knee joint is effused. In ligamentous injuries the effusion is mostly serous or sero-sanguineous. In bony injuries affecting the articular surfaces the effusion is mostly haemorrhagic.

Any effusion of the knee joint will give rise to a characteristic horse-shoe shaped swelling around the superior and lateral aspects of the patella. Dislocation of the patella mostly occurs on the lateral condyle of the femur giving rise to an abnormal swelling at that region. Recurrent dislocation of patella after trifle injury to the knee joint is not uncommon.

(3) **Muscular wasting.**— It occurs in old injury to the knee joint leading to muscular wasting of quadriceps muscles. Very often it is seen after an old injury to the meniscus. But this may not occur if the patient continues quadriceps exercise after such injury.

B. **PALPATION.**— In palpation particular care is taken to elicit the exact point of tenderness around the knee joint. This will give a clue as to the diagnosis of the condition. Palpation of all the bones around the knee joint is also important. This includes palpation of the patella, lower part of the femur and upper ends of the tibia and the fibula. In case of effusion in the knee joint 'patellar tap' and fluctuation tests are important.

1. **Exact point of tenderness.**— In lesion of the medial collateral ligament tenderness is characteristically present at its femoral attachment. Tenderness over the ligament at the level of the joint without any tenderness at its bony attachments is suggestive more of an injury to the medial semilunar cartilage and less of the sprain of the deep fibres of the medial collateral ligament. Tenderness at the joint level midway between the ligamentum patellae and the tibial collateral ligament indicates torn anterior horn of the medial semilunar cartilage. Tenderness posterior to the tibial collateral ligament is diagnostic of a torn posterior horn. Tenderness just on both the sides of the ligamentum patellae indicates nipped infrapatellar pad of fat. *The best method of eliciting tenderness for the torn anterior horn of the medial meniscus is as follows:* — The knee is flexed at right angle. Gentle pressure is exerted by the tip of the thumb at the midpoint between ligamentum patellae and the tibial collateral ligament (Fig. 13.44). This often elicits tenderness. If not, the thumb is kept pressed over the same region while the knee joint is gradually extended. The patient will complain of pain which he has not done previously.

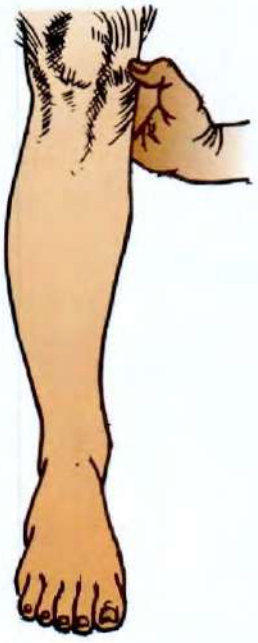

Fig. 13.44.— Method to elicit tenderness by pressure of clinician's thumb at the mid point between ligamentum patellae and the tibial collateral ligament when the anterior horn of the medial meniscus is torn.

2. **Palpation of the Patella.**— In any injury to the knee joint it is a good practice to palpate the patella as a whole as it is very vulnerable to fracture in injuries of the knee joint particularly with effusion. While palpating the patella the fingers should run along the borders of the patella to find out any gap therein. Various types of fracture of patella are come across in surgical practice. In case of a transverse fracture, a considerable gap is always felt between the two fragments. In case of comminuted fracture irregularity of the bone will be obvious. In case of simple crack fracture the diagnosis is sometimes difficult and may be missed. Local bony tenderness and slight bony irregularity are the diagnostic features. The diagnosis may only be unveiled by X-ray of the knee joint. Sometimes quadriceps tendon or the ligamentum patellae is torn from the patella. The diagnosis of this condition is also not very difficult by palpation. In any injury to the patella or the extensor mechanism of the knee joint viz. the quadriceps tendon and the ligamentum patellae, the patient will be unable to lift the extended limb from the bed.

3. **Palpation of the lower end of the femur.**— In supracondylar fracture, the lower fragment is tilted *backwards* by the pull of the gastrocnemius. So during palpation the lower end of the upper fragment becomes projected forwards and easily palpated In separation of the lower epiphysis, on the other hand, the epiphysis is displaced forwards over the lower part of the shaft. A word of caution will not be out of place here that the pulse in the foot should always be felt during this type of injury as the popliteal artery runs the risk of being damaged by the displaced fragment. Injury to the femoral condyles can be easily suspected by careful palpation which will elicit bony irregularity and local bony tenderness.

4. **Palpation of the upper ends of the tibia and fibula.**— Usually the lateral condyle of the tibia is more frequently fractured than the medial one. Palpate carefully the tibial tubercle and the upper end of the fibula for bony tenderness and irregularity.

Springing the fibula.— In fracture of the upper end of the fibula tenderness at the fracture site can be elicited by squeezing the lower parts of the tibia and fibula.



Fig.13.45.— Shows how springing the fibula is being performed.

5. **Swelling.**— Besides the fracture around the knee joint which will cause abnormal swelling, effusion of the knee joint is by far the commonest cause of swelling after injury to the knee. It must be borne in mind that besides fracture extending into the joint haemorrhage may be due to haemophilia in which the affection is often bilateral. The tests for fluctuation and "patellar tap" are discussed in Chapter 15.

MEASUREMENTS.— In injury to the knee joint the following measurements may be of necessity :

(i) Breadth of the lower end of the femur and upper end of the tibia can be measured with the help of a pair of calipers.

(ii) Circumference of the thigh and calf at fixed points from the joint-line of the knee will indicate if there is any muscular wasting following injury.

MOVEMENTS.— As has already been discussed derangement of the extensor mechanism of the knee joint which may be brought about by fracture of the patella or rupture of the quadriceps tendon or ligamentum patellae will make the patient unable to lift the extended lower limb above the bed. The clinician must not try to flex the knee joint in such type of injury as it will cause further damage to the extensor apparatus of the knee joint. When the joint cannot be fully extended (locked) the possibility of a bucket handle tear of the medial meniscus or presence of a loose body within the knee joint should be kept in mind.



Fig.13.46.— Demonstration of McMurray's test. See the text.

McMurray's test.— This is a very popular test to detect any tear either in the medial or lateral semilunar cartilage. In making the examination the patient must be recumbent and relaxed, the surgeon standing at the side of the injured limb. He grasps the foot firmly with one hand and the knee with the other hand. The knee

joint is completely flexed that means the heel touches the buttock. The foot is now rotated externally and the leg abducted at the knee. This twisting movement is done for a few times and then the joint is slowly extended keeping the foot externally rotated and abducted. If the posterior end of the medial semilunar cartilage is torn the patient will complain of pain at this stage as the torn cartilage will be caught between the femur and the tibia. At the same time a definite 'click' will be felt by the hand at the knee and the patient will experience a feeling of giving way of the knee joint simultaneously. The angle at which this occurs, indicates the position of the cartilaginous lesion. When middle of the cartilage is torn the click is felt at the middle of extension and when the anterior horn is torn click is felt almost at the end of extension.



Fig.13.47.— The knee is being abducted to detect any sprain or rupture of the medial collateral ligament.

Similar exercise with the foot rotated internally and the knee adducted, if elicits pain and a 'click' as discussed in the previous paragraph, indicates tear in the lateral semilunar cartilage. Similarly the angle of the knee at which the pain and 'click' will be experienced will give a clue as to the position of the tear.

Apley's Grinding test.— The patient lies prone on the table. The clinician places his knee on the patient's thigh in order to fix the femur. The knee joint is flexed to the right angle. Now the clinician applies compression and lateral rotation to the leg from the foot i.e. grinding. If the patient complains of pain by the manoeuvre, there is a tear in the medial semilunar cartilage. If the patient complains of pain while the clinician compresses and internally rotates the leg, there is a tear in lateral semilunar cartilage.

Apley's Distraction test.— If the patient complains of pain while the leg is pulled upwards and rotated laterally a tear of the medial collateral ligament is diagnosed. Similarly if the pain is elicited by pulling the leg upwards and rotating it internally, a tear of the lateral collateral ligament, which is very rare, is diagnosed.

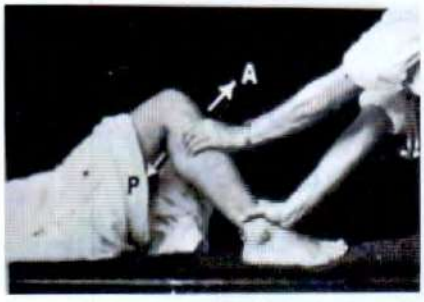

Fig.13.48.— Shows how to demonstrate Drawer sign. Excessive anterior 'A' or posterior 'P' mobility of the tibia indicates tear of the anterior or posterior cruciate ligament respectively.

Test of stability.— The two collateral ligaments and cruciate ligaments are mainly responsible for the stability of the knee joint. If any of these ligaments is ruptured the stability of the joint is jeopardized. The integrities of these ligaments are tested as follows :

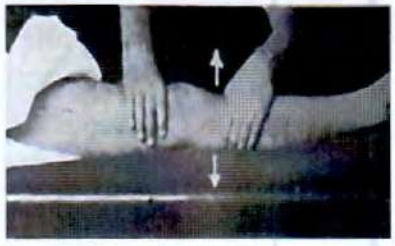

Fig.13.49.— Testing for integrity of the cruciate ligaments. An attempt is being made to move the upper end of the tibia on the femur.

1. *Abduction and adduction tests.*— The knee joint is held in full extension lifting the foot up with one hand from the bed and the other hand is kept at the knee. Using the hand at the side of the knee as the fulcrum the leg is first abducted to test the integrity of the medial collateral

ligament, which is more frequently injured than its lateral counterpart and next adducted to test the integrity of lateral ligament. If the ligament is torn the joint will be abnormally opened at that side. But if the ligament is sprained the joint will remain stable but the patient will complain of excruciating pain during the exercise.

2. *Drawer sign.*— This is diagnostic of injury to the cruciate ligaments. The patient lies in the supine position and the knee joint is flexed at right angle keeping the foot on the bed. The clinician sits on the foot of the patient to fix the lower limb. The upper part of the tibia is pulled forward and pushed backward. If the anterior cruciate ligament is ruptured there will be increased anterior mobility and if the posterior cruciate ligament is ruptured there will be increased posterior mobility of the joint.

Complications.— The lateral popliteal nerve is liable to be injured in fracture of the upper end of the fibula particularly the neck. The popliteal vessels are liable to be injured in supracondylar fracture of the femur and separation of the lower epiphysis of the femur. When the artery is pressed upon there will be diminution or absence of pulsation of the dorsalis pedis and the posterior tibial arteries. When the vein is pressed upon there will be oedema of the leg.

X-RAY EXAMINATION.— Besides the usual antero-posterior and lateral views, the knee joint should also be X-rayed in forced abduction and adduction positions. The latter skiagram will show the degree of joint laxity due to rupture of the ligaments concerned. Pneumo-arthrography, i.e. taking X-ray picture of the knee joint after injecting air may prove useful in detecting doubtful lesion of the meniscus.

In injuries about the knee joint the following conditions are to be remembered :

(1) Fracture and dislocation of the patella.
(2) Fracture and epiphyseal separation of the lower end of the femur.
(3) Fracture of the upper end of the fibula.
(4) Dislocation of the knee (Very rare).
(5) Injury to the collateral ligaments (the internal ligament is more often affected).
(6) Injury to the semilunar cartilage or the meniscus (Commonly medial).
(7) Injury to the cruciate ligaments.
(8) Injury to the infrapatellar pad of fat.
(9) Fracture of the tibial spine.
(10) Traumatic loose bodies.

DIFFERENTIAL DIAGNOSIS

Fracture of the patella.— While direct violence results in comminuted fracture of the patella, transverse fracture is caused by indirect muscular violence. In case of muscular violence the man slips on one leg, automatically the other knee gradually flexes until he falls down. In order to avert the fall, his quadriceps contracts violently when the patella is situated at its highest point on the femoral condyle. This results in transverse fracture of the patella which is forced against the femoral condyle by violent contraction of the quadriceps.

The diagnosis is made by the history of trauma (as discussed above), swelling of the knee joint due to effusion of blood, irregularity and bony tenderness which becomes obvious on careful palpation and grating sensation during movement of the knee joint.

Injury to the collateral ligaments.— The medial collateral ligament is more often injured than its lateral counterpart due to the fact that it is adherent to the capsule of the knee joint, whereas the lateral collateral ligament is free from the capsule being intervened by the tendon of the popliteus.



Fig.13.50.— Three types of tear of medial meniscus. 1.— Bucket handle tear. 2.— Anterior horn tear and 3.— Posterior horn tear.

The patient complains of pain on the medial side of the knee joint and points out the site of pain at the femoral attachment of the medial collateral ligament. Very occasionally the patient shows tenderness over the medial aspect of the joint line due to torn deep fibres of this ligament. But this type of tenderness is more often due to injury to the medial semilunar cartilage. Forced abduction of the extended leg will open out the joint at its medial aspect indicating complete rupture of the medial collateral ligament. This opening out of the medial aspect of the joint in the forced abduction position of the knee joint in X-ray confirms the diagnosis.

Injury to the semilunar cartilages.— This is by far the most important injury and peculiar to the knee joint. The medial semilunar cartilage is more often injured being fixed to the collateral ligament, whereas the lateral semilunar cartilage enjoys the advantage of being more mobile as it is not attached to the lateral collateral ligament and it gives origin to the tendon of popliteus which pulls it backwards and does not give any chance of being nipped between the two condyles of femur and the tibia. The **mechanism** of injury to the semilunar cartilage is that the knee joint must be primarily *flexed* since rotation cannot occur when the knee joint is extended. A *rotational strain* (either internal rotation of femur on the tibia or external rotation of the tibia on the femur) *and forceful abduction* are necessary as the latter tends to open up the inner side of the joint and exerts a suctional influence on the cartilage, which is drawn inwards and then nipped between the condyles of the femur and the tibia during the rotational strain causing longitudinal tear of the medial semilunar cartilage. There are three types of tear. (i) Anterior horn tear, (ii) Bucket-handle tear and (iii) Posterior horn tear. A transverse tear, if at all occurs, is always an artefact. Usually the footballers and the workers in mines are the victims of this type of injury. After injury to the knee joint, the mechanism of which has already been described, the joint becomes locked generally followed by sudden unlocking and giving way. The joint becomes effused. On examination a definite point of tenderness can be elicited at the joint-line between the patellar ligament and the medial collateral ligament in tear of the anterior horn. Very often this injury is ignored and the footballer continues to play. Similar injury even of a milder variety will cause locking and effusion of the knee joint. In "Bucket-handle" tear generally locking persists. In tear of the posterior horn, the joint may be locked, often gives way and effused. *McMurray's test* is of great help in diagnosing tear of the semilunar cartilages. In an old lesion, there will be marked wasting of quadriceps and laxity of the joint. X-ray pictures are mainly required to exclude any bony lesion particularly fracture of the tibial spine.

Though the lateral semilunar cartilage is rarely injured yet two distinct types of pathology — (i) congenital discoid cartilage and (ii) cyst of the cartilage are commonly met with this cartilage. These are discussed in the chapter of "Examination of Individual Joint Pathologies".

Injury to the cruciate ligaments.— This generally results from severe injury to the knee joint as the cruciate ligaments are placed interiorly and are very strong. The diagnosis of tear of the anterior or posterior ligament is made by Drawer's sign i.e. abnormal forward or backward mobility of the tibia on femur respectively. In case of torn anterior ligament the

knee joint can be hyperextended.

Injury to the infrapatellar pad of fat.— This injury is by far less common than the previous entities. When the infrapatellar pad of fat becomes hypertrophied, it may be nipped between the femur and tibia during extension of the knee joint. Diagnosis is made by the history of sudden pain with or without locking. On examination tenderness can be elicited on both sides of the ligamentum patellae. Signs and symptoms of osteoarthritis are frequently present.



Fig.13.51.— Skiagram of a typical case of loose body of the knee joint due to osteochondritis dissecans.

Fracture of the tibial spine.— After an injury to the knee joint there will be locking with a feel of bony block and effusion. There may or may not be any localized tenderness which can be elicited from outside. Only X-ray is confirmatory.

Loose bodies of the knee joint.— This itself forms a chapter and there are numerous causes of forming loose bodies inside the knee joint.

CLASSIFICATION OF LOOSE BODIES

A. *FIBROUS LOOSE BODIES.*— *Traumatic* i.e. organization from haemorrhage into villus and *pathological* — in association with (i) tuberculosis, (ii) syphilis and (iii) osteoarthritis.

B. *FIBRINOUS LOOSE BODIES.*— *Traumatic* — after haemorrhage and *pathological* in association with (i) tuberculosis and (ii) chronic synovitis.

C. *CARTILAGINOUS LOOSE BODIES.*— *Traumatic* — separation of whole or part of an intra-articular fibro-cartilage e.g. meniscus.

D. *OSTEO-CARTILAGINOUS LOOSE BODIES.*— *Pathological* — it may be from(i)osteochondritis dissecans, (ii) detachment of osteophytes in osteoarthritis, (iii) separation of sequestrum in acute osteomyelitis, (iv) synovial chondromata etc. *Traumatic* — fracture of the tibial spine.

E. *MISCELLANEOUS LOOSE BODIES* — (i) introduced foreign body, (ii) lipoma and (iii) secondary carcinoma.

Diagnosis of presence of loose body inside the knee joint is made by history of recurrent locking at different angles. There will be associated findings according to the cause of loose bodies. The most difficult part is to differentiate injury to the meniscus with the presence of loose bodies inside the joint. This difference is easier when the loose body is radio-opaque i.e. bony or osteo-cartilaginous or radio-opaque foreign bodies. This requires only X-ray for diagnosis. Two conditions should be kept in mind which are often misdiagnosed as bony loose bodies in the knee joint. They are (a) Fabella — a sesamoid bone in the lateral head of the gastrocnemius and (b) Pellegrini-Stieda's disease in which calcification occurs in the tibial collateral ligament after partial avulsion from the medial condyle of the femur.

EXAMINATION OF INJURIES ABOUT THE ANKLE AND FOOT

HISTORY.— The *mechanism* of injury around the ankle is usually violence. The foot is everted, externally rotated or internally rotated on the tibia. Actually the foot is anchored to the ground while the momentum of the body drives the tibia. This usually occurs when the foot is fixed by a hole in the ground or in a ski, while the body moves forwards. It may occur when the patient

stumbles over an unexpected obstacle or stair. To these may be added an upward thrust if the patient falls from a height. The injuries are generally of three types — (i) external rotation, (ii) internal rotation and (iii) vertical compression.

A. **INSPECTION.**— The **deformity** of the foot is carefully observed whether it is displaced laterally, medially or forwards or backwards in comparison to the tibia. Excessive broadening of the ankle suggests inferior tibio-fibular diastasis i.e. the inferior tibio-fibular ligament is torn and the talus is wedged between the tibia and fibula.

B. **PALPATION.**— 1. All the bones forming the ankle, i.e. the lower ends of the tibia and fibula including the two malleoli, the calcaneus and the talus are carefully palpated. Similarly in injury to the foot, the bones concerned i.e. the tarsal bones, the metatarsals, the phalanges etc. are examined. (i) **Local bony tenderness,** (ii) **local bony irregularity,** (iii) **displacement,** (iv) **unnatural mobility** and (v) **crepitus** are the findings which one should look for to diagnose if any bone concerned has been fractured or not.

Palpation of the lower end of the tibia and fibula and the two malleoli are not very difficult. The calcaneum is palpated from posterior aspect while the talus is palpated by deep pressure with the thumb in front and just below the ankle. To palpate the tarsal bones is not also very difficult. The metatarsals and the phalanges are palpated along their length.

2. Sprain of ankle is also very common. Tenderness just below a malleolus suggests *sprain of the ankle.* If the foot is turned to the opposite direction to stretch the ligament concerned the patient will complain of pain. This suggests sprain of the ankle.

3. *Springing the fibula.*— By squeezing the upper ends of the tibia and fibula pain will be elicited at the lower part of the fibula if it is fractured.

4. Lastly one must palpate tendo Achilles to find if there is any gap or tenderness at its attachment with the os calcis. Palpation of injuries around the ankle remains incomplete if this examination is missed.

C. **MOVEMENTS.**— In fracture around the ankle, obviously there will be restriction in movements of the ankle joint. By holding the ankle joint with one hand, slight active or passive movement of the ankle with the other hand will give an indication about the type of fracture that has probably occurred.

D. **MEASUREMENTS.**— (i) The length of the leg, which is not so vital has already been discussed in page no. 199. (ii) The distances between the medial malleolus to the head of the first metatarsal bone and the point of the heel are important. Similarly the distances between the lateral malleolus to the head of the 5th metatarsal bone and the point of the heel are important. These measurements should be compared with those of the sound side. In fracture of the calcaneus the distances between the malleoli and the point of the heel are shortened if there is upward displacement of the tuberosity. (iii) Broadening of the ankle as measured by means of calipers, is often seen in inferior tibio-fibular diastasis.

X-RAY EXAMINATION.— Usual antero-posterior and lateral views are quite useful in determining different fractures around the ankle and the foot. Only in cases of suspected fracture of the calcaneus axial X-ray may be needed to detect displacement in vertical fractures involving the joint. In case of a fracture of the calcaneus *tuber-joint angle* must be noted. This angle is formed at the back of the ankle by two lines — one passing over the non-articular surface of the calcaneus and the other along the articular surface of the same bone for the talus. Normally this angle is about 40°. In fractures when the tuberosity is displaced upwards lifting the posterior non-articular surface, *this angle is reduced* (Fig. 13.55).

In complete tear of any collateral ligament of the ankle joint an antero-posterior X-ray is taken with the foot forcibly tilted towards the opposite direction. Such *strained positional skiagram*

shows an unusual increased gap between the malleolus and the talus in complete tear of the collateral ligament.

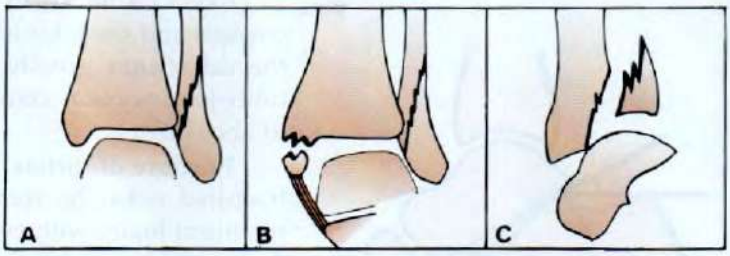

Fig.13.52.— Diagrammatic representation of the three stages of external rotation injury.

DIFFERENT FRACTURES AROUND THE ANKLE AND THE FOOT

1. **External rotation injury.**— This will cause a spiral fracture of the fibula. With continuing force the medial malleolus may be avulsed or fractured transversely. Further rotation will lead to avulsion of the posterior fragment of the tibia to which the tibio-fibular ligament is attached leading to tibio-fibular diastasis.

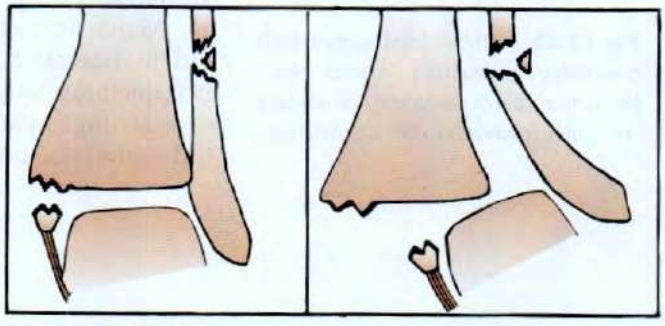

Fig.13.53.— Diagrammatic representation of abduction injury to the ankle.

2. **Abduction injury.**— Abduction force fractures the fibula transversely approximately 2 inches above the ankle joint. A continuing force may also avulse the medial malleolus and later on avulsion of the posterior fragment of the tibia with tibio-fibular diastasis.

3. **Adduction injury.**— This will cause a vertical fracture of the medial malleolus extending upwards along its lateral margin. This is the most important differentiating feature from the external rotation or abduction injury in which the medial malleolus is fractured transversely. A continuing adduction force will avulse the tip of the fibula.

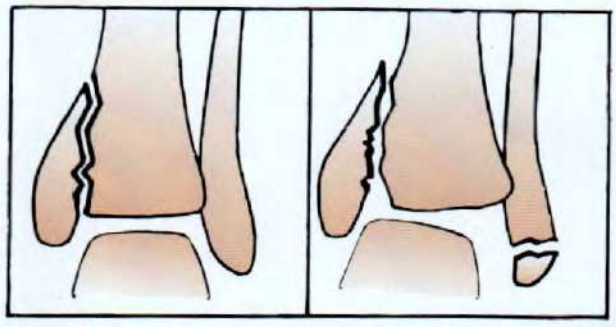

Fig.13.54.— Diagrammatic representation of adduction injury of ankle.

Vertical injury with an upward thrust will split the tibia vertically. It may shears off the anterior or posterior corner of the lower tibia. Sometimes this vertical fracture may join a transverse fracture of the lower end of the tibia about 2 to 3 inches above the ankle joint. In adolescents this type of injury will cause fracture-separation of the lower tibial epiphysis.

Fracture of the calcaneum.— This usually results from a fall from height. The calcaneum is driven up against the talus and subsequently split or crushed.

Split fracture.— The calcaneum is split into two segments by vertical fracture and usually extends from the medial aspect near the back of the bone to the lateral aspect in front. The larger lateral segment is usually shifted laterally and the smaller medial segment is displaced upwards. The fracture usually extends into the sub-talar joint.

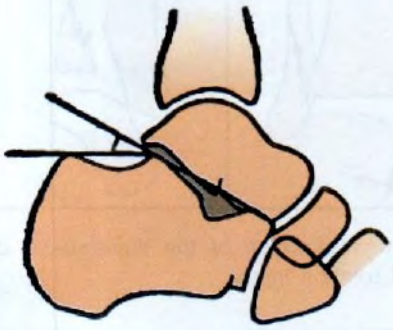

Fig.13.55.— Tuber-joint angle which normally measures about 40°. Reduction of this angle may be evident in crush fracture of the calcaneum.

Crush fracture.— In this type of injury the calcaneum is crushed and the talus is driven downwards into the body of the calcaneum grossly damaging the sub-talar joint. The tuber-joint angle is considerably reduced from 40° (normal) to about 20°.

Fracture of metatarsal bone.— Metatarsal bone may be fractured either by rotational injury or by crush injury. In rotational injury with eversion and plantar flexion commonly the first metatarsal bone is injured near its base. The typical rotational injury with forced inversion will avulse the base of the 5th metatarsal bone. Crush injury usually affects the metatarsal necks.

March fracture or stress injury is typically seen at the 2nd metatarsal bone due to unaccustomed overuse as for example after long march past. The patient will complain of a tender lump palpable at the neck or at the midshaft of the 2nd metatarsal bone.

Chapter

14 EXAMINATION OF PATHOLOGICAL JOINTS

HISTORY.—

1. **Age and sex.**— Rheumatoid arthritis occurs more commonly in young adult women and osteoarthritis is a disease of old age. Acute arthritis is commonly seen in young children. Tuberculous arthritis is commonly seen in children and adolescents.

2. **Occupation.**— Manual workers e.g. blacksmiths and coolies are more often the victims of osteoarthritis.

3. **Mode of onset and progress.**— Acute onset with constitutional disturbances is found in acute arthritis. This is more common in the hip or knee joint rather than the shoulder. Insidious onset is the feature of chronic arthritis including tuberculous variety, rheumatoid arthritis and osteoarthritis.

4. **Pain.**— This is the main complaint of a patient with arthritis. This is conspicuous by its absence in Charcot's joint (due to tabes dorsalis or syringomyelia) and Clutton's joint (due to congenital syphilis). The clinician should take a proper history of the pain regarding its site, its character, its relation to movements of the joint and its relation with the new and full moon.

(a) *Site.*— Whether the pain is localized to the affected joint or referred to some other joint e.g. to the knee in case of hip diseases or fleeting type from one joint to the other as seen in rheumatic fever.

(b) *Character.*— Whether the pain is of dull aching in nature which is commonly seen in chronic arthritis including the tuberculous variety or throbbing in nature which is a feature of acute arthritis. In tuberculous joint when the articular cartilages are destroyed the child often cries at night during sleep; commonly known as 'night cry'. This is due to the fact that when the patient is awake during the day the joint is kept immobilized by the muscles spasm, but during sleep the muscles relax and allow friction between the eroded articular surfaces giving rise to 'night-cry'.

(c) *Relation to movements.*— In any affection of a joint, movement aggravates the pain. But in osteoarthritis pain is first felt in the early morning when the patient gets up from the bed. With gradual movement of the joint the pain is eased off due to increase in synovial secretion.

(d) *Its relation to weather and new or full moon.*— The pain becomes aggravated during new or full moon in rheumatoid arthritis and gout. The pain also gets worse in rainy season.

5. **Locking.**— This is due to presence of loose bodies within the joint.

6. **Deformity.**— Sometimes a pathological joint may present with deformity of course at late stage, when its early stages have been ignored. Such deformity is seen in late stage of rheumatoid arthritis, osteoarthritis and tuberculous arthritis. These are discussed in the differential diagnosis in this chapter and in the next chapter 'Examination of Individual Joint Pathologies'.

7. **Past history.**— Enquire whether the patient suffered from tuberculosis, gonorrhoea, syphilis, typhoid fever or pneumonia in the past. This gives a clue to the diagnosis. Previous trauma is sometimes responsible for subsequent osteoarthritis. So careful history should be taken

to know the details of past injury, X-ray findings and any other investigations performed.

8. **Family history.**— Haemophilia, tuberculosis, gout, rheumatism etc. often run in families.

PHYSICAL EXAMINATION

GENERAL SURVEY.— In acute suppurative arthritis evidence of toxaemia is frequently present. Generalized wasting and cachectic features are noticed in tuberculosis of joints.

Fever.— High rise of temperature is an important diagnostic feature of acute suppurative arthritis. Evening rise of temperature is a feature of tuberculous arthritis.

LOCAL EXAMINATION

A. **INSPECTION.**— The affected joint and the corresponding healthy joint should be fully exposed and placed in the same position. The affected joint is compared with the sound side. The joint should be inspected from all sides, particularly the posterior aspect which is often overlooked. In the case of the lower limb the patient's *gait* must be watched.

1. **Swelling.**— Very often a pathological joint is swollen and can be noticed very easily. A careful watch must be made to differentiate between generalized swelling of the joint due to effusion and a localized swelling from a bursa or a ganglion. A bursa often communicates with the joint and may become prominent in presence of effusion in the joint. The best example of this condition is Baker's cyst which is often associated with effusion of the knee joint due to osteoarthritis or tuberculosis.

2. **Deformity and position of the joint.**— The joint is sometimes deformed in the position of abduction or adduction, popularly known as valgus or varus deformity respectively. This can be found in any joint which is pathologically involved to produce such deformity. After the Latin names they are called Coxa (hip) valgus or varus, Genu (knee) valgus or varus, Cubitus (forearm) valgus or varus and Manus (hand) valgus or varus. There may be rotational deformity which should also be noticed. When a joint is distended with fluid, it takes up an *'optimum position'* or *'position of ease'*, in which capacity within the joint is maximum. This position is adduction, slight flexion and internal rotation for the shoulder joint; slight flexion, abduction and external rotation for the hip joint; flexion and slight pronation for the elbow joint; slight flexion for knee joints; slight flexion for wrist joint and slight plantar flexion and inversion for the ankle joint. If the joint is not held in the 'optimum position' or in the 'position of rest', deformity is likely to develop.

3. **Skin over the joint.**— Red and glossy skin suggests acute inflammation of the joint. Scar, sinus, ulcer and deformities of the joint are the late features of tuberculous arthritis.

4. **Muscular wasting.**— When the joint is diseased the muscles concerned in movement of the joint will be wasting. In case of the knee joint the quadriceps muscles waste first, similarly in case of hip the glutei waste first.

B. **PALPATION.**—

1. **Local temperature.**— An acute inflamed joint will be warm. The backs of the fingers are mainly used to assess the temperature of the joint. The temperature of the diseased joint must be compared with that of the healthy joint. The teaching is that always feel the joint of the sound side first and then the diseased joint.

2. **Tenderness.**— An acutely inflamed joint will be highly tender. This tenderness will be present all round the joint line. The bones in the vicinity of the joint and the bony attachments of various ligaments are carefully palpated for tenderness, as the former will be tender in fracture and the latter will be tender in sprain.

3. **Bony components.**— This must be palpated to exclude the possibility of previous osteomyelitis or old fracture.

4. **Swelling.**— An effusion of the joint will make the fluctuation test positive. Moreover the swelling takes the form of the joint. An enlarged bursa will be soft and cystic and will correspond with the anatomical position of the bursa. Communicating bursa may be associated with effusion of the joint. Synovial thickening will feel elastic and spongy or 'boggy'. Occasionally a swelling at the joint may not be due to effusion but due to swelling like subcutaneous lipoma or cyst. Sometimes loose body may be felt within the joint.

5. **Muscular wasting.**— During palpation this is corroborated with the findings of inspection. Of course, measurement will follow.

C. **MOVEMENTS.**— Both active (the movements made by the patient's effort) and passive (the movements made by the surgeon and the patient remains passive) movements should be examined. The ranges of the movements are noted on both the sound and the affected sides. It is always advisable to examine the sound side first so that the patient knows what is to be done with the affected joint and his fear and muscle spasm can be greatly eliminated.

During the movement a few things should be noted.— (a) Does the movement cause pain to the patient? If so, when does the pain start and when does it disappear. (b) Is there any restriction of the movements? At what angle the movements become restricted? In certain diseases certain types of movements are restricted whereas the other movements remain normal. (c) Is there any protective muscular spasm? To demonstrate, a short sharp movement is made and the muscle will be seen to go into spasm. Muscular spasm is almost always associated with active stage of arthritis. (d) Is there any crepitus felt during movement of the joint? This suggests osteoarthritis. For this, the joint must be palpated during its movements. *Limitation of movements in all directions* is an important feature of acute arthritis.

One thing must be borne in mind during examination of movements of different joints that a few joints e.g. the shoulder, the hip and the ankle exhibit some range of movements even though the joints concerned are completely ankylosed. This is due to the movements of the neighbouring joints, as for example in case of shoulder joint the movement of the scapula, acromioclavicular and sternoclavicular joints; in case of the hip such movements occur at the lumbar spine; in case of the ankle movements may occur at the subtaloid and midtarsal joints.

D. **MEASUREMENTS.**— Though one can take the measurements of the length of the limbs and relation of the different bony points as has been described in the hip, elbow, shoulder etc. yet the most important measurement so far as the pathological joint is concerned is the *circumference of the limb* above the joint at the same level on both the sides to detect muscular wasting.

Auscultation.— As has already been discussed crepitus is the feature often accompanied by osteoarthritis. In early cases of osteoarthritis fine crepitation may be missed by the palpating fingers. Auscultation is of immense value in detecting these fine crepitations.

Examination of the lymph nodes.— The regional lymph nodes are often enlarged in different arthritis. But the clinicians often forget to examine these lymph nodes. In case of the hip joint the external iliac group of lymph nodes are affected, whereas in case of the knee joint the inguinal group of lymph nodes are affected.

GENERAL EXAMINATION

1. The lungs and the cervical lymph nodes should be examined in case of suspected tuberculous arthritis.



Fig.14.1.— Testing the ankle jerk. Note that this is lost earlier than the knee jerk in Charcot's joint.

2. Signs of syphilitic stigmas should be looked for in case of syphilitic affection of the joint (See Fig.4.15).

3. Gonococcal infection also involves the joints in chronic stage. History of urethral discharge and examination of the smear obtained from prostatic massage will help to diagnose the condition.

4. In rheumatic fever one should examine the heart.

5. Search for septic foci in teeth, tonsils, air sinuses and even cervix uteri in case of acute arthitis, rheumatic fever and rarely in rheumatoid arthritis.



Fig.14.2.— Testing for the Argyll Robertson pupil in Charcot's knee joint. The other eye is closed to prevent consensual light reflex.

6. **Neurological examination** is important in Charcot's joint, affected by tabes dorsalis and syringomyelia. Ask the patient if he had 'lightening' pain down the leg or 'girdle' pain around the trunk. The jerk will be gradually losing and the ankle jerk will be lost earlier than the knee jerk. Loss of sensation, Argyll Robertson pupil (i.e. presence of accommodation reflex but loss of light reflex), the Romberg's sign (i.e. the patient sways or even falls if he stands with his feet close together and the eyes shut) etc. are the features of Charcot's joint (neuropathic joint).

In the upper limb syringomyelia is the common lesion and this is diagnosed by dissociation of sensations (i.e. loss of pain and temperature sense but presence of tactile sensation), inequality of accommodation reflex etc.

7. **Examination of neighbouring joints** is of immense importance in case of certain joints. The patients may complain of knee joint when the pathology lies in the hip joint. This is referred pain due to common nerve supply of these two joints (femoral, obturator and sciatic nerves).

SPECIAL INVESTIGATIONS

1. **Blood.**— This is examined for (i) leucocytosis (suppurative arthritis), lymphocytosis (tuberculous arthritis); (ii) increased E.S.R. (tuberculosis and rheumatoid arthritis); (iii) W.R. and Kahn test (Clutton's joint); (iv) uric acid (gout); (v) Coagulation time and bleeding time (haemophilia) and (vi) Immunological tests — VDRL and Kahn test (syphilis), Widal (Typhoid), Rose-Waaler and latex (Rheumatoid).

2. **Aspiration.**— The aspirated fluid is examined for physical, microscopical and bacteriological characteristics.

3. **X-Ray Examination.**— This is the most useful special investigation so far as a pathological joint is concerned. Both the antero-posterior and the lateral views of the pathological joints are taken and may be compared with those of the sound side. The following findings should be noted : —

(i) *Bony components* of the joint should be carefully examined for any localized or generalized rarefaction (tuberculosis), gross destruction (Charcot's joint, tuberculosis and occasionally in septic arthritis) or pathological dislocation (commonly seen in late stages of tuberculous arthritis and rarely seen in septic and typhoid arthritis). In tuberculous arthritis appearance of sclerosis in the rarefied area is considered to be a definite sign of recovery.

(ii) *Articular Ends.*— Normally the articular ends are distinct and continuous in outline.

Haziness or loss of definition is a positive sign of any form of arthritis. Peripheral lipping of the articular surface is characteristic of osteoarthritis.

(iii) *Joint space.*— This is nothing but the space occupied by the articular cartilages and shows as a gap between the articular ends of the bones in X-ray. Increase in this space indicates effusion in the joint and denotes the first stage of arthritis. Diminution of this space indicates erosion of the articular cartilage and signifies the second stage of arthritis.

(iv) *Abnormal bone shadows.*— These may be loose bodies or disorganized bone in Charcot's joint.

(v) *Abnormal soft tissue shadow.*— This may be seen when an abscess is formed either in acute arthritis or a cold abscess in tuberculosis. Evidence of periostitis may be seen in neighbouring bones.

4. **Mantoux test.**— This is done in suspected cases of tuberculosis. Its negative result is more important as it excludes the presence of this disease.

5. **Biopsy** of the lymph nodes may be done, though occasionally practiced, in suspected cases of tuberculous arthritis. Biopsy of the synovial membrane besides its diagnostic value possesses a therapeutic advantage in rheumatoid arthritis particularly when it affects a single joint.

6. In gonococcal arthritis, demonstration of **gonococci in urethral discharge** after prostatic massage will confirm the diagnosis.

7. **Arthroscopy** — is particularly helpful in detecting the pathology of the joint.

8. **Arthrography** is more helpful in detecting internal derangement of joint due to injury than due to pathology. Both arthrography and arthroscopy are contraindicated in acute suppurative arthritis.

9. **Isotope scan** with ^{67}Ga or ^{99m}Tc is helpful in the diagnosis of inflammatory lesion of the joint due to high uptake.

DISEASES OF THE JOINT

1. **Acute suppurative arthritis.**— Though staphylococcal and streptococcal infections by far outnumber the other varieties of acute arthritis, yet pneumococcal, gonococcal and typhoid arthritis should be borne in mind under this heading.

2. **Chronic arthritis.**— Four main varieties are included under this heading. They are (a) tuberculous arthritis; (b) rheumatoid arthritis; (c) osteoarthritis and (d) gout.

3. **Neuropathic joints.**— In this group are included (a) Charcot's joint due to tabes dorsalis, syringomyelia and peripheral neuritis from diabetes and (b) hysterical joint.

4. **Osteochondritis.**— This is a separate entity and includes 3 distinct types — (a) crushing osteochondritis; (b) splitting osteochondritis (dissecans) and (c) pulling osteochondritis (traction).

5. **Haemophilic joints.**— These may present like acute arthritis, but presence of the history of bleeding tendency suggests the diagnosis.

6. **Loose bodies.**

7. **Miscellaneous group.**— This group includes Clutton's joint, a manifestation of congenital syphilis and subacute arthritis which occasionally complicates bacillary dysentery and brucellosis.

DIFFERENTIAL DIAGNOSIS

Acute suppurative arthritis.— The causative organisms are usually staphylococcus and occasionally streptococcus. The joint is affected either by penetrating wound or secondary to acute osteomyelitis when the metaphysis is included within the joint or by blood spread from a

distant site. Infection affects the articular cartilage and the synovial membrane in the beginning. Pus is formed which may burst out of the joint to form abscesses and sinuses. Later on, with healing, the opposing bony surfaces may adhere by fibrosis (fibrous ankylosis) and sometimes bony trabeculae grow between the opposing bones to form 'bony ankylosis'.



Fig.14.3.— Acute pyogenic arthritis. Note that the joint space is absolutely diminished due to erosion of the articular cartilages.

The patients are usually children and the condition reveals itself with severe throbbing pain, swelling and redness of the affected joint, high temperature, rapid pulse and a very toxic outlook. The patient often does not allow to touch the affected joint. On inspection the joint is held slightly flexed, swollen and red. On palpation, the joint is warm with diffuse tenderness and fluctuation. Active movement is absolutely nil and passive movement is very painful.When the articular cartilages are affected, the patient gets 'night pain' as the muscles become relaxed and allow movement between the eroded articular cartilages. Without treatment the end result is fibrous or bony ankylosis according as the articular cartilage is partially or completely destroyed.

X-ray shows normal appearance with increased joint space for the first two weeks. Gradually the joint space becomes narrowed indicating erosion of the articular cartilages with widespread patchy rarefaction of the neighbouring bones. With healing the bone recalcifies and may show trabeculae across the joint indicating bony ankylosis.

Pneumococcal arthritis.— As the name suggests, arthritis is secondary to pneumococcal infection of the throat, ear or lung. The common victims are the children and the knee joints are mainly affected. Arthritis is characterized by painless purulent effusion. Aspiration will bring out creamy greenish pus containing pneumococci, which clinches the diagnosis.

Gonococcal arthritis.— The joint is involved after about 3 weeks of primary infection and when the urethral discharge has ceased. The infection is mainly blood-borne. The condition is manifestated by joint pain and acute arthritis. It may affect one large joint as for example the elbow or the knee or many joints — both small and large (polyarticular). The outstanding features of gonococcal arthritis are (i) sudden onset with fever, (ii) severity of pain, (iii) redness and oedema of the joint, (iv) haemorrhagic vesico-pustular rash and (v) demonstration of gonococci in urethral discharge after prostatic massage.

Reiter's disease.— This is characterized by multiple arthritis commonly affecting the knee, the ankle, the foot and sacroiliac joints. The joints are hot, red, swollen, tender and painful. *This condition is associated with nonspecific urethritis and conjunctivitis.*

Typhoid arthritis.— This is a rare disease now-a-days. Joints are affected, if at all, at the 3rd week of the typhoid fever.

Tuberculous arthritis.— Tuberculosis of the joint is merely the local manifestation of the generalized disease. The onset is insidious with a history of poor appetite, loss of weight, slight evening pyrexia, malar flush etc. Generally the children are affected and the lower limbs are more often involved than the upper limbs. The diagnostic features are: (i) Indication of presence of tuberculosis by the history has already been mentioned. Tuberculosis of the urogenital tract

may be the presenting feature. (ii) Pain is not so prominent as in acute arthritis. 'Night pain' wakes the child with a cry when the articular cartilages are involved and when the protective muscular spasm becomes nil during sleep. (iii) Muscular wasting. (iv) Restriction of movements *in all directions* with protective muscular spasm. (v) Formation of cold abscess and sinus. (vi) X-ray shows diminution of the joint space due to erosion of the articular cartilages, recalcification with or without bony focus and at the last stage pathological dislocation. Recalcification indicates beginning of the healing process. (vii) Special investigation like Mantoux test, culture of M. Tuberculosis from the aspirated fluid and biopsy, positive guinea-pig inoculation test are all suggestive of this condition. If the condition remains untreated end result is fibrous ankylosis. Bony ankylosis is possible only when the joint is secondarily infected. In tuberculous spine osseous ankylosis can occcur spontaneously without secondary infection.

Rheumatoid arthritis.— The usual victims are the women between the ages of 30 and 50 yrs. The disease is gradual in onset affecting small joints of the hand and foot. Pain is the main symptom followed by stiffness, swelling and deformity. The tendency is to spread slowly and symmetrically up the limbs involving the larger joints. Occasionally the onset of the course is rapid and rarely a single large joint may be affected (monoarticular).

Sometimes the condition is associated with fever and loss of weight. Sedimentation rate is raised, anaemia is common and lymph nodes may be enlarged. Sometimes this disease is seen in children and is called Still's disease. It is a polyarticular rheumatoid arthritis. The joint changes are similar to those of the adult disease but are usually preceded by severe general illness, skin rashes, lymphadenopathy, splenomegaly and pericarditis.

On examination the skin overlying the joint is shiny and atrophic. The joint is swollen and muscle wasting becomes obvious. Various deformities in different joints are characteristic features of this disease e.g. *ulnar drift* is common at the metacarpophalangeal joints, *swan-neck deformity* (hyperextension at the proximal interphalangeal joint and the flexion at the distal joint), *boutonniere deformity* (flexion at the proximal interphalangeal joint and hyperextension at the distal), *finger drop* following rupture of the extensor tendon at the level of the wrist etc.

Movements are restricted by pain and spasm. During quiescent period a good range may return. Gradually stiffness due to fibrous ankylosis may result.

X-ray shows diffuse rarefaction of the neighbouring bones as an early feature. Cysts may be seen in the bones. Later on the joint space becomes decreased and may completely disappear. At the last stage some sort of deformity may become obvious. In most patients with rheumatoid arthritis the Rose-Waaler and latex serum tests for rheumatoid factor are positive, but some 25% of patients are sero-negative and the prognosis in them is better.

Osteoarthritis.— The nomenclature does produce some confusion as this condition has got no relation with inflammation of the joint and should bettter be called "osteoarthrosis". The aetiology of this condition remains still in doubt. Probably increased mucopolysaccharide in articular cartilage and diminished hyaluronic acid in the synovial fluid which develops with increasing age may be the causative factor. Of the **general causes** (a) a *genetic background* seems to play its role as it is often seen in a few members of the same family and (b) *metabolic disorders* like alkaptonuria and gout may lead to premature cartilage degeneration. Of the **local factors** — (a) injury in the form of *repeated minor injuries* as seen in certain occupations, recurrent subluxation of the patella, undue joint laxity, torn meniscus and loose bodies are examples; (b) *incongruent joint surfaces* as seen in congential subluxation of the hip, pseudocoxalgia etc; (c) *mal-alignment* of the joints such as coxa vara, genu valgum, genu varum etc; (d) *inflammatory diseases* such as rheumatoid arthritis, septic arthritis etc. and (e) *inadequate blood supply* with avascular necrosis of the bone ends are important.

The changes start in the articular cartilage, which becomes soft, irregular and pitted. Minute flecks of cartilage are set into the joint. In the non-stress area, the subchondral vessels become hypertrophied and invade the cartilage which calcifies and later ossifies forming osteophytes. The hyperaemia spreads into the bone underneath the stress area. The cartilage continues to be rubbed away and the bone becomes exposed and dense. Subchondral Cysts may develop as the sinusoidal distension damages the trabeculae and also because the synovial fluid is forced into the bone through minute cracks in the cartilage.

Generally the patients are men above 50 years of age. One joint, occasionally two or even three may be involved. But this is not a true poly-articular disease like rheumatoid arthritis. The main symptom is the pain. In the beginning the pain is felt particularly in the early morning when the patient gets up. There may be some stiffness associated with it. Pain and stiffness gradually pass off on continued use of the limb owing to increased synovial secretion. This is the pathognomonic feature. Deformity is the late feature due to capsular shrinkage and muscular imbalance e.g. flexion and adduction deformity at the hip joint. On examination some limitation of the movements and grating sensation are frequently obtained. Restriction of movements is characteristically asymmetrical, thus at the hip extension, abduction and internal rotation are more limited than their opposites.

X-ray shows diminution of the joint space at the pressure areas only and presence of osteophytes i.e. peripheral lipping of the articular ends. Sclerosis and presence of cysts are noticed in subjacent bones.

Gout.— It is a metabolic disorder with abnormal high level of serum uric acid due to excessive production or inadequate excretion or both. The joints mainly affected are the toe joints (especially the metatarso-phalangeal joint of the hallux), the finger joints, the wrists and the ankles. The victims are usually the middle aged and elderly people. Urate crystals are actually irritating and this results in acute painful arthritis. The skin overlying the joint becomes red, warm, oedematous. Crystals of sodium biurate may be deposited in the bone, in cartilage and in joints. X-ray shows normal features in early stages but in late cases bone deposits are revealed as punched-out translucent areas under the cartilage. Later on the joint becomes osteoarthritic.

The diagnosis is confirmed by the family history, a history of previous similar attacks, the raised uric acid level (this level may be increased in non-gouty patients who are taking aspirin), X-ray appearance and probably the most important is the presence of "tophi" (i.e. chalky deposits in different parts of the body and around the joints).

Pseudo-gout.— In this condition the attacks are similar to those of the gout. The only difference is that this condition affects the spinal joints and the proximal joints. The condition is associated with chondrocalcinosis i.e. calcification in hyaline and in fibrocartilage.

Charcot's joint.— Tabes dorsalis, syringomyelia and peripheral neuritis are the common causes. Tabes affects the inferior extremity whereas syringomyelia affects the superior extremity. The condition is characterized by little pain and marked destruction of bone leading to abnormal mobility of the joint associated with coarse crepitus.

Hysterical gout.— The common victims are the women. The affected joint is kept rigid in some deformed position. Any attempt to move the joint is resisted. Clinical examination fails to reveal any organic disease of the joint and the joint assumes normal attitude when the muscles are made relaxed.

Osteochondritis.— Three distinct varieties are included under this heading.

(a) ***Crushing osteochondritis.***— The examples of this condition are Perthes' disease in the hip joint, Freiberg's disease in the second metatarsal, Kohler's disease in the navicular bone, Kienbock's disease in the lunate bone and Scheuermann's disease in the thoracic spine. Mostly

children between 5 and 15 years are affected. Of these Freiberg's disease is commoner between the ages of 15 and 25 years and Scheuermann's disease is a disease of the adolescents. The common problem is the pain of the affected joint with irritability and some deformity i.e. adduction and internal rotation in Perthes' disease of the hip, kyphosis in Scheuermann's disease etc. The main problem is avascular necrosis of the epiphysis of unknown aetiology which makes the bone dense on X-ray. The nomenclature suggests that the affected bones are under pressure and may be the cause of avascular necrosis.

(b) ***Splitting osteochondritis (Dissecans).***— In this condition trauma seems to play a major role and gradually leads to formation of an avascular fragment which split off. On X-ray a line of demarcation first appears and avascular segment becomes gradually detached and forms a loose body inside the joint. This will ultimately lead to osteoarthritis.





Figs. 14.4 & 14.5.— Osteochondritis dissecans affecting the medial condyle of the right femur shown by arrow. In the second figure axial skiagram is taken in extreme flexion of the knee joint.

The affected individuals are generally adolescents. The knee is the commonest joint to be affected followed by the elbow and rarely the ankle. In the *knee joint* generally the articular surface of the medial femoral condyle is involved and the patient complains of vague aching, swelling and tenderness in the affected area. The patient may present with locking and giving way, which are features of loose body in the joint. *In the elbow* generally the capitulum or radial head is affected, and the signs and symptoms are similar to the knee joint. *In the ankle* commonly one corner of the upper surface of the talus is affected. The symptoms are again similar to those of the knee joint.

(c) ***Traction osteochondritis.***— This condition occurs only in those places where the tendon is attached to an epiphysis or apophysis. The possible exception is probably Johansson-Larsen's disease in which this condition affects the lower pole of the patella (a sesamoid bone) at the attachment of ligamentum patella.

In this condition also the adolescents are affected and the two places are notoriously involved

by this condition. These are the *knee joint* where the ligamentum patellae is attached to the tibial (Osgood-Schlatter's disease) tubercle and at the heel where the tendo-achillis is attached to the calcaneum (Sever's disease). In both these conditions the patient presents with swollen and tender spots. When the tendons are made taut against resistance the pain increases. On X-ray the affected bone looks more dense and fragmented.

Haemophilic joint.— Haemophilic patients sometimes present with sudden bilateral effusion of the knee joints, without very suggestive cause. That the patient is a bleeder will confirm the diagnosis.

Loose bodies.— They may arise (1) *from the synovial fluid*, e.g. fibrinous loose bodies resulting from haemorrhagic or inflammatory effusion — 'melon-seed' bodies found in tuberculous joints belong to this group, (2) *from the synovial membrane* numerous cartilaginous loose bodies developing within villous synovial processes (osteochondromatosis), (3) *from the bone* resulting from injury, e.g. fracture of the tibial spine, detached osteophytes in the case of osteoarthritis, sequestra from acute arthritis secondary to acute osteomyelitis, but most important in this group is loose body from osteochondritis dissecans.

Clutton's joint.— This is a manifestation of the congenital syphilis. Symptomless and symmetrical synovitis with boggy fluid distension of both the knee joints suggests this condition. Moreover there will be wasting of muscles of the thighs and this associated with interstitial keratitis will confirm the diagnosis. This condition often commences in one joint and at this stage it is very difficult to differentiate this condition from tuberculous arthritis.

ANKYLOSIS

This condition means stiffness of a joint either by intra-articular lesions (True ankylosis) or by extra-articular involvement (False Ankylosis).

A. **True ankylosis.**— (i) *Fibrous variety.*— Fibrous ankylosis is commonly seen as a sequel of tuberculous arthritis, acute arthritis, gonococcal arthritis and rarely rheumatoid arthritis. As the name suggests this condition signifies fibrosis between the two articular surfaces following damage to the cartilages leading to limitation of movements.

(ii) *Bony variety.*— Bony ankylosis occurs following suppurative arthritis and occasionally after tuberculous arthritis becomes secondarily infected. This condition signifies formation of bony trabeculae between the two articular ends following severe destruction of the articular cartilages.

B. **False ankylosis.**— This means extra-articular structures are involved in such a way as to cause limitation of movements of the joint. From superficial to deep, the causes are :—

(i) *Skin and subcutaneous tissue* — in burns following contracture.

(ii) *Muscles and tendons* — due to adhesion to the bone following fracture (e.g. commonly seen after fracture of the shaft of the femur when quadriceps adhere to the fractured site resulting in limitation of extension of the knee joint), Volkmann's ischaemic contracture, etc.

(iii) *Fascia* — in Dupuytren's contracture and occasionally in gonococcal fibrofascitis, ankylosis of the joints will result.

(iv) *Capsules and ligaments* — in prolonged immobilization, which is a common cause of limitation of movements following trauma. Contracture of these structures are held responsible.

(v) *Bone.*— Myositis ossificans traumatica is probably the commonest condition of this group. Rarely excessive callus formation and displaced fragments may be responsible for the false ankylosis.

Chapter

15 EXAMINATION OF INDIVIDUAL JOINT PATHOLOGIES

SHOULDER JOINT & SHOULDER GIRDLE

HISTORY.— In diseases of the shoulder joint the patients usually complain of pain — either localized in the shoulder joint or radiating from the acromion process down the outer side of the arm upto its middle. The students must remember a fallacy in this respect that pain in the shoulder joint may be referred from the neck, chest or the abdomen (from irritation of the diaphragm which is supplied by the same segments i.e. C3, 4 & 5).

LOCAL EXAMINATION

INSPECTION.— The patient must be stripped upto the waist and stand in front of the surgeon for proper inspection not only of the affected joint but also to compare with the sound side.

1. **Position.**— In affection of the shoulder joint the arm is held by the side of the chest, medially rotated and slightly flexed. Very often the arm is being supported by the other hand and kept slightly raised.

2. **Contour.**— This is important. It may be *flattened* due to wasting of the deltoid muscles from tuberculous arthritis, rheumatoid arthritis, osteoarthritis, rotator cuff* lesions etc. It may be *prominent* with rounded fullness seen in subdeltoid bursitis or effusion of the joint. In effusion of the shoulder joint, which is not very common, the swelling extends beyond the anterior and posterior margins of the deltoid and along the long tendon of the biceps due to existence of synovial sac. But in subdeltoid bursitis fullness is only seen just beneath the deltoid muscle and does not go beyond the margins of this muscle.

PALPATION.— 1) **Tenderness.**— The shoulder joint is best palpated by keeping the arm by the chest wall with one hand and with the other hand to palpate the shoulder joint from all aspects. In supraspinatus tendinitis pressure just below the acromion process will elicit tenderness. In painful arc syndrome pressure just below the acromion will elicit tenderness if the arm is adducted, but not if the arm is abducted as the tender spot will disappear under the acromion process. Similarly in front just below the coracoid process one can feel the anterior aspect of the joint and note if there is any tenderness. Posteriorly also the joint is palpated similarly. In osteoarthritis if the arm is made to sway a little the palpating hand at the shoulder joint will feel the crepitus. Three bony joints are important to palpate in the shoulder joint — (a) Tip of coracoid, below which is the anterior aspect of the shoulder, (b) Tip of the acromion, below

---

* 'Rotator cuff' is a cuff comprised of tendons of the four muscles which fuse with the capsule of the shoulder joint to give additional strength to it. These four muscles are — anteriorly subscapularis, superiorly supraspinatus and posteriorly infraspinatus and teres minor.



Fig.15.1.— Note that the plane of the scapula is not in the coronal plane of the body but is slightly inclined forwards (about 30°). Abduction and adduction take place in the plane of the body of the scapula (A-A) whereas flexion and extension occur at right angles to that plane.

which lies the superior aspect of shoulder and (c) Greater tuberosity, its prominence.

It is a good practice to feel the acromioclavicular as well as the sternoclavicular joints to exclude any organic disease there.

2) **Codman's method.**— This is another method of palpating the shoulder joint. The left hand is used to palpate the right shoulder of the patient. The thumb lies along the depression below the spine of the scapula to palpate the posterior aspect of the shoulder joint. The tip of the index finger is placed just anterior to the acromion to feel the superior aspect (at the insertion of the supraspinatus) and slightly anterior aspect of the joint and other three fingers are placed on the clavicle to hold it. Examiner's right hand grasps the patient's flexed elbow and the patient's arm is moved gently backwards (extension) and forwards (flexion) and the shoulder joint is carefully palpated. The examiner's right hand is used to palpate patient's left shoulder.

3) **Swelling.**— Effusion in the joint is difficult to palpate through the deltoid. Fullness, however, can be discovered in the axilla. Subdeltoid bursitis may give rise to swelling and tenderness just beneath the acromion process.

The corresponding axilla should be always palpated while examining the affected shoulder. This palpation should be deep high in the axilla to detect any fullness there to indicate joint effusion. As the inferior aspect of the joint is lax and redundant accumulation of fluid starts here in case of joint effusion.

MOVEMENTS.— The shoulder joint is a very mobile joint and the bony configuration is such as to sacrifice the stability of the joint to certain extent to compromise with greater ranges of movement.

While examining for the ranges of different movements of shoulder joint, *firstly* the patient must be stripped upto the waist and these movements should be examined not only from in front but also from behind (particularly during abducton to see the scapular movement). This is because of the fact that an ankylosed gleno-humeral joint will show some range of movement due to the movement of the scapula as also the acromioclavicular and sternoclavicular joints. *Secondly* the different movements must be compared with those of the normal side to exactly assess the differences. *Thirdly* the clinician must have a clear idea about the plane of the body of the scapula along which the abduction and adduction movements occur. This is not in the coronal plane of the body but is slightly inclined forwards about 30° with this plane (Fig.15.1).



Fig.15.2.— Codman's method of palpation of the shoulder joint. Note the placement of the clinician's fingers on the shoulder joint. See the text.

So during abduction the arm is carried forwards and outwards while during adduction the arm is carried backwards and inwards. Flexion and extension take place at right angle to this plane i.e. in flexion the arm is carried forwards and medially and in extension backwards and laterally. *Fourthly* in the movement of abduction the shoulder joint itself moves for 100°-120°, the additional 60°-80° is obtained by the forward rotation of the scapula and some movement of the clavicle. But these movements occur almost simultaneously except in the initial 25°-30° when the whole of the movement takes place at the shoulder joint. For every subsequent 15° of elevation of the arm, the gleno-humeral joint contributes 10° and the scapular movement 5°. To note exactly how much movement is contributed by the gleno-humeral joint, the scapula is fixed by the clinician from behind and the patient is asked to abduct the shoulder.

The range permitted in each movement is as follows :

Abduction — 180°; flexion — 90°; extension — 45°; rotations — both medial and lateral — one quarter of a circle about a vertical axis; circumduction — results from succession of the foregoing movements.

ACTIVE MOVEMENTS.— The patient is asked to carry out all the movements simultaneously on both sides (for comparison) one after another and the difference from the normal side is noted. The important movements are abduction and external rotation which are often affected in different diseases of the shoulder joint.

During abduction it is noted whether the patient shrugs his shoulder at the beginning of the act or not. This indicates complete rupture of supraspinatus tendon. This muscle is concerned in starting the movement of abduction. In chronic supraspinatus tendinitis (painful arc syndrome), pain is felt at the mid-range of abduction (60°-120°), the extremes of the range are painless. The whole range of abduction is painful in acute supraspinatus tendinitis and any arthritis of the shoulder joint. In arthritis of acromioclavicular joint sharp pain is felt when the arm is raised above right angle. Determine how much of the shoulder movement occurs at the shoulder joint proper (gleno-humeral joint) and how much is contributed by rotation of the scapula and the clavicle. In frozen shoulder proper abduction is very much limited and this is practically nil in bony ankylosis. Yet a good range of abduction is possible because of the rotation of the scapula and the clavicle.

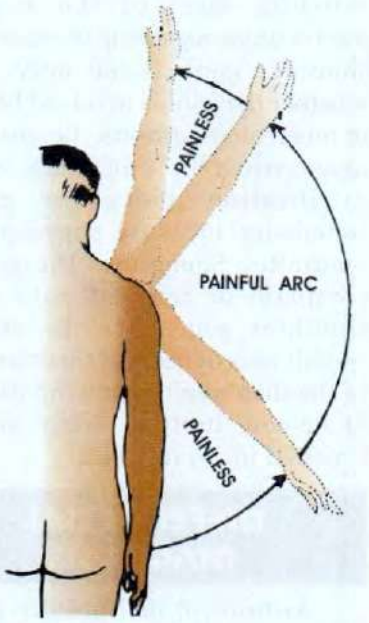

Fig. 15.3.— In painful arc syndrome, the midrange abduction is painful, the extremes are painless.

Rotation of the shoulder joint is restricted, particularly the external rotation in different arthritis of the joint and in frozen shoulder.

PASSIVE MOVEMENT.— The importance of this movement is not much except in complete rupture of supraspinatus tendon. In this condition if the patient is made to abduct his shoulder for the initial 30°, he will be able to complete the whole range of abduction with the help of the deltoid muscle.

Acromioclavicular and sternoclavicular joints.— These joints are best examined from the front. The patient must be stripped upto the waist. The joints are inspected for any redness, swelling and deformity. The joints are palpated for local tenderness, temperature and to assess the swelling. The patient is asked if the joints become painful in different movements of the shoulder joint. It is useful to note that the movements of these joints occur during elevation of the arm

and when the shoulders are braced backwards or drawn forwards.

SPECIAL INVESTIGATIONS

1. **Blood** — is examined for haemoglobin, total count, differential count and E.S.R. in acute arthritis and tuberculous arthritis of the joint.

2. **X-ray examination** — provides most of the required informations regarding diseases of the shoulder joint. It not only shows whether the joint is involved by acute or tuberculous arthritis, rheumatoid or osteoarthritis, but also shows calcification above the greater tuberosity in acute supraspinatus tendinitis. Sometimes the patients complain of referred pain in the shoulder joint due to cervical spondylosis or cervical rib or irritation of the diaphragm following gallstone or splenic rupture. These are also revealed in X-ray.

DIFFERENTIAL DIAGNOSIS

Arthritis of the shoulder joint.— *Acute arthritis* rarely affects a shoulder joint, but occasionally seen in children. *Rheumatoid arthritis* is also occasionally seen in shoulder joint and ususally the young adult females are the victims. Similarly, *osteoarthritis* is also not commonly seen in the shoulder joint. *Tuberculous affection* of the joint is occasionally seen and the disease starts as a synovitis or osteomyelitis. In this condition cold abscess and sinus formations (florid type) are not uncommon, but "Caries Sicca" i.e. without abscess formation is often confused with "frozen shoulder". Previously many cases which were diagnosed as "Caries Sicca" were nothing but "frozen shoulders". X-ray examination is

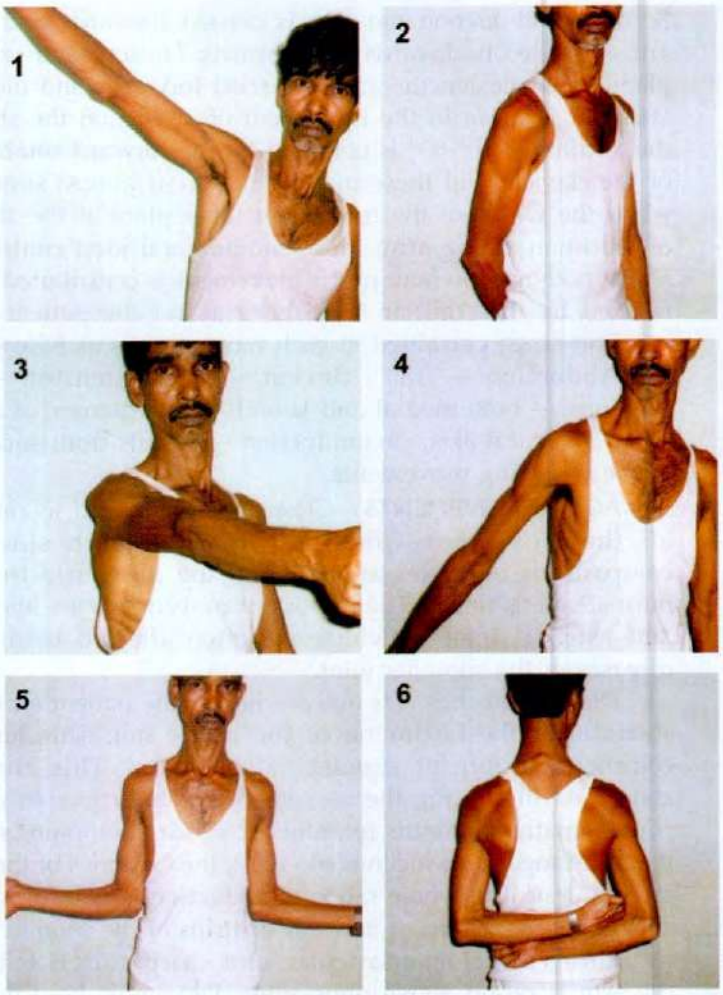

Figs.15.4 to 15.9.— Showing movements of the shoulder joint : (1) Abduction, (2) Adduction, (3) Flexion, (4) Extension, (5) External rotation and (6) Internal rotation.



Fig.15.10.— Testing passive movements of the shoulder joint. Note that the scapula is fixed with one hand.

confirmatory as destructive lesions of tuberculosis will be obvious in "Caries Sicca".

Acute supraspinatus tendinitis.— Localized degeneration of the supraspinatus tendon with or without deposition of calcium is the main underlying pathology of this condition. Degeneration leads to rapid swelling and tension with often calcium deposition which leads to tremendous pain. Young individuals between 25-45 years are the common victims. The first complaint is obviously a dull ache which quickly gets worse leading to agonizing pain and practically all movements — especially abduction are limited. After a few days pain subsides once the calcified substance has erupted into the subdeltoid bursa.



Fig.15.11.— Shows calcification in the tendon of supraspinatus following degeneration. This is a case of acute supraspinatus tendinitis.

On examination there is tenderness at the point of insertion of the supraspinatus on greater tuberosity just beneath the acromion process. Skiagram will reveal calcification of supraspinatus tendon which later on bursts into the subdeltoid bursa relieving pain.

Chronic supraspinatus tendinitis (painful arc syndrome).— This condition is also due to a process of degeneration of the supraspinatus tendon which is probably triggered by an injury or by over-use. The swelling of the tendon is again the underlying pathology and is so situated that on abduction (during the middle of the range) it impinges upon the under surface of the acromion process. Commonly older men in the age group of 45-60 years are the victims. The most important finding is that the mid-abduction (60° - 120°) is painful. This is the range of abduction in which there is very little space between the greater tuberosity and the acromion and the thickened supraspinatus tendon becomes nipped between these two bones. The beginning and the end of abduction remain painless.

The painful arc syndrome is definitely the pathognomonic feature of chronic supraspinatus tendinitis but is sometimes come across in conditions like (a) subdeltoid bursitis, (b) incomplete rupture of the supraspinatus tendon and (c) crack fracture of the greater tuberosity of the humerus.

Frozen shoulder.— The underlying pathology is that an exudate causes the layers of the infra-articular synovial membrane (inferior aspect of the synovial membrane) and the capsule to adhere to one another. Patients between 45-60 years are commonly affected. Females seem to outnumber the male patients. The patient sometimes gives a history of trauma. The patient first experiences a pain which becomes worse at night and prevents the patient from sleeping on the affected side. Gradual stiffness of shoulder follows. In a matter of months all movements especially abduction and external rotation are restricted. As the process continues the pain abates. By this time the muscles around the shoulder show signs of disuse atrophy. Months later stiffness gradually lessens and the disease recovers spontaneously. Thus there are three phases of this disease: (i) increasing pain and increasing stiffness, (ii) decreasing pain with persistent stiffness and (iii) disappearance of stiffness with return of all the movements. Each phase lasts from 4 to 8 months and the whole process takes about 2 years.

X-ray appearance is widely *accepted as normal*, which differentiates this condition from others.

Rupture of the supraspinatus tendon.— Degeneration of the supraspinatus tendon is again the cause of this condition. The injury which causes tear is rather trifle in that way. Usually elderly men between 45-65 years are affected. The patient usually gives a history of trauma in the way of lifting weight or protecting himself from falling. The pain is felt immediately radiating from the shoulder to the middle of the outer side of the arm. The patient soon discovers that he

is unable to lift the arm or abduct his shoulder. But if he bends to the affected side a little to make an angle of 20° to 30° when the deltoid muscle takes over the process of abduction and completes the full range of abduction. The supraspinatus muscle is concerned to begin the process of abduction which is later carried on by the deltoid muscle. Palpation will reveal a gap just beneath the acromion process. Straight X-ray will not give much information, but arthrography will reveal the tear.

Subdeltoid (Subacromial) bursitis.— Fluid in the subdeltoid bursa will present as cystic and fluctuating swelling beneath the acromion process. In this condition the humeral head can be distinctly palpated below the acromion process which differentiates this condition from the effusion of the shoulder joint.

Brachial Neuralgia.— This term signifies pain extending over a large part of the upper limb. There are numerous causes of this condition and careful examination will reveal the exact cause in a particular case. The common causes are — A. *In the neck.*— (i) Disc prolapse commonly seen at the level between C6 & C7. Patient will complain of pain radiating from the neck towards the shoulder and down the arm with painful and restricted neck movements. X-ray will show diminished disc space. (ii) Tuberculosis of the cervical vertebrae. (iii) Vertebral body tumour. (iv) Cord or root tumour. B. *In the neck-arm junction.*— (i) Cervical rib, (ii) Pancoast's syndrome i.e. Bronchial carcinoma affecting the apical lobe of the lung giving rise to Horner's syndrome and a hard lump at the root of the neck. C. *In the shoulder*— (i) Musculo-tendinous cuff lesions. (ii) Arthritis — any arthritis of the joint, be it rheumatoid, osteoarthritis, tuberculosis etc.

Rupture of the biceps tendon.— This condition is a sequel of avascular degeneration of the biceps tendon or may be due to rubbing against osteophytes in an osteoarthritic shoulder. The patients are usually over 50 years of age. A history of trauma is almost inevitable in the form of lifting weight or saving himself from a fall. The clinical picture is unmistakable — i.e. whenever the bicep muscle is made to contract, belly of the biceps looks prominent and rounder with a gap proximal to it.

THE ELBOW JOINT

HISTORY.— Patients with elbow disorders mostly complain of pain, stiffness, deformity and occasionally locking. One thing must be noted that pain in the elbow may be referred from the neck or shoulder disorders.

INSPECTION.— 1) **Position.**— The patient is asked to stand straight with his arm at the side of the body with the palms looking forwards that means in anatomical position. Observe the carrying angle (normally it is 10° in case of males and 20° in case of females) and compare it with that of the sound limb. This angle is the outward deviation of the extended and supinated forearm from the axis of the arm. This angle disappears when the forearm is flexed or pronated. It must be noted that varus or valgus deformity of the elbow is only obvious when this joint remains straight. This deformity disappears when the joint is flexed. In case of effusion of the elbow joint, this joint is held in semiflexion position — the position of ease or greatest capacity.

2) **Swelling.**— Any swelling near about the elbow joint is noted. Normal hollows on either side of the olecranon and obliterated in effusion of the joint. Olecranon bursitis (miner's or student's elbow) will give rise to swelling over the olecranon process. Great effusion of the elbow joint will also show fullness in the antecubital fossa. Sometimes a bursa beneath the tendon of the biceps near its insertion may become inflamed giving rise to a condition known as bicipitoradial bursitis. This condition also gives rise to a slight swelling in front of the elbow joint which may be missed.

3) **Muscular wasting.**— This will be obvious in any affection of the elbow joint which will limit its function.

PALPATION.— 1) **Local temperature.**— This will be increased in acute arthritis, olecranon bursitis and bicipitoradial bursitis.

2) **Localized tenderness.**— This is an important part of examination which will often indicate the diagnosis by itself. In tennis elbow a localized tenderness will be elicited in the region of origin of the common extensor muscles at the lateral epicondyle. In Golfer's elbow the tenderness is situated on the common flexor origin from the medial epicondyle.

3) **Bony components** of the joint viz. the lower part of the humerus and the upper parts of the ulna and the radius are carefully palpated for any thickening or irregularity — the evidence of previous osteomyelitis. The three bony points — the tip of the olecranon, the medial epicondyle and the lateral epicondyle — form a triangle when the elbow is flexed. But these three bony points come to a straight horizontal line when the elbow is extended.

4) **Swelling.**— Swellings around the elbow joint are palpated along the usual lines of the examination. Fluctuant swelling will be seen in effusion of the elbow and in all bursitis. In case of *effusion of the elbow joint* first there is filling up of the concavity on each side of the olecranon, as the synovial cavity is nearest to the surface at this region and the posterior ligament is thin and lax. When more fluid accumulates, a swelling is noticed on the posterolateral aspect of the elbow joint over the radiohumeral joint. Crossed fluctuation can be elicited between this area and swelling over the medial aspect of the olecranon. This sign distinguishes an effusion of the elbow joint from enlargement of bursa beneath the triceps tendon.

5) **Examination of the supratrochlear lymph node.**— To examine for enlarged supratrochlear or epitrochlear lymph nodes one must flex the elbow to the right angle to relax the surrounding structures. The node will be palpated on the anterior surface of the medial intermuscular septum one cm above the base of the medial epicondyle. When enlarged, the node will be found slipping beneath the finger and thumb. If the elbow is kept extended the enlarged lymph node may not be palpated. While unilateral enlargement of this lymph node indicates some infective lesions of the hand, wrist and forearm, but bilateral enlargement suggests a generalized disease e.g. syphilis and calls for biopsy of the gland.

MOVEMENTS.— The elbow joint has got two components — humero-ulnar and superior radio-ulnar joints. The humero-ulnar joint permits flexion and extension. The full range of extension means when the elbow joint becomes straight. The full range of flexion is 180° from this position that means when the soft tissues of the anterior aspect of the joint come to approximation. The radio-ulnar joint permits pronation and supination movements and *these movements are best examined when the elbow joint is kept flexed at 90°* and the arm is kept by the side of the chest. When the elbow joint is extended these movements will be mixed with rotation of the humerus.

DIFFERENTIAL DIAGNOSIS

Acute Arthritis.— Acute arthritis often leads to effusion of the elbow joint. The joint becomes very painful and is always held in semi-flexion position (optimum position). On both sides of the olecranon normal concavity will disappear. Effusion of the elbow joint will elicit transmitted fluid impulse between the two sides of olecranon posteriorly and at the bent of the elbow anteriorly.

Chronic arthritis.— All the usual forms of chronic arthritis may be seen in the elbow joint. But these are uncommon. Tuberculosis occurs in adults more often than in children.



Fig.15.12.— Osteochondritis dissecans affecting the head of the radius. Note the dense epiphysis of the radial head.

Osteochondritis dissecans.— This condition, though more often seen in the knee joint, yet it does occasionally affect the elbow joint. The capitulum is generally involved. The head of the radius is also affected (Fig.15.12). The patient complains of aching pain and recurrent effusion. On X-ray there will be a dense spot in the capitulum affecting its articular surface. Later on this portion may be detached forming loose body in the joint.

Charcot's joint.— This condition occasionally affects the elbow.

Tennis elbow (Lateral epicondylitis).— This is more often seen among the tennis players and hence the name. But quite a number of the sufferers of this condition have never played tennis. Probably the common extensor origin is damaged and subsequent adhesion binds torn to untorn fibres and to the joint capsule. Tendinitis, nipping of a synovial fringe and entrapment of a branch of the radial nerve may be the other explanations which the students should keep in mind.

Patients complain of pain on the lateral aspect of the elbow, accentuated by dorsiflexion of the wrist when the extensor muscles are put in action, such as during pouring out tea in a cup or turning a door handle.

Palpation will reveal considerable tenderness over the lateral epicondyle of the humerus where the extensor muscles originate. *Cozen's test* i.e. when the patient is asked to extend his clenched fist against resistance, considerable pain is experienced at the lateral epicondyle. *Mill's manoeuvre* i.e. the patient's wrist is passively flexed when his forearm is pronated. This gives rise to tremendous pain on the attachment of the common extensor tendons.

Golfer's (or Baseballer's) elbow (Medial epicondylitis).— This condition is quite uncommon in comparison to the previous one. It is the medial counterpart of the previous condition i.e. the tenderness is situated in the common flexor origin at the medial epicondyle.



Fig.15.13.— *Cozen's test.* See the text.

Student's (or Miner's) elbow.— The bursa over the olecranon process sometimes gets infected and leads to effusion in it. This is nothing but olecranon bursitis and is caused by repeated movement of the skin over the olecranon bursa. This condition mainly affects the students and the friction is caused while writing between the skin over the olecranon and the table.



Fig.15.14.— *Mill's manoeuvre.* Note that the clinician's left thumb is palpating the origin of the common extensor tendons where the patient is experiencing severe pain due to the manoeuvre.

Bicipitoradial bursitis.— This is a very rare condition in which the bursa beneath the tendon of biceps becomes inflamed and effused. This is caused by repeated throwing of a ball. The patient complains of pain over the insertion of the biceps tendon which is accentuated by flexion and supination (movements caused by the biceps muscle at the elbow).

The elbow tunnel syndrome.— This condition is by far rarer than carpal tunnel syndrome. This condition affects the ulnar nerve whereas the latter condition affects the median nerve. The involvement of the ulnar nerve occurs when it passes between the two heads of the flexor carpi ulnaris. This condition may be due to osteoarthritis of the elbow joint and the ulnar nerve is injured by the osteophytes.

THE WRIST AND OTHER JOINTS OF THE HAND

HISTORY.— The patients with the problems of the wrist may present with either pain, swelling such as caused by ganglion or deformity such as tuberculous affection of the wrist or more commonly of the joints of the fingers.

INSPECTION.— 1) **Position.**— In all affections of the wrist joint this joint will remain in flexed position and characteristic ulnar deviation is noticed in wrist and the finger joints particularly in rheumatoid arthritis.

2) **Swelling.**— Swelling may be due to effusion of the wrist joint which is rather uncommon and should be differentiated from effusion of the tendon sheaths. In the latter condition the effusion extends upwards and downwards beyond the extent of the joint and along the corresponding tendon sheath, while the former is limited within the extent of the joint and is seen both anteriorly and posteriorly. In *rheumatoid arthritis* the metacarpophalangeal joints become swollen with prominent knuckles. *In tuberculous tenosynovitis of the ulnar bursa* (compound palmar

ganglion), a swelling is present on the palmar aspect and extends both proximally and distally beyond the flexor retinaculum. A small circumscribed swelling either on the dorsal (more common) or on the ventral aspect of the wrist is nothing but a *ganglion.*



Fig.15.15.— The ganglion on the dorsal aspect of the wrist (the commonest site).

3) **Deformity.**— Obvious deformities of the wrist are rare and barring rheumatoid arthritis they are mostly congenital deformities e.g. radial club hand, Madelung's deformity etc.

4) **Sinus.**— In tuberculosis of the wrist joint sinus formation is not uncommon.

PALPATION.— 1) **Swelling.**— Is the swelling fluctuant? Effusion of the wrist, ganglion and the compound palmar ganglion are all fluctuant swellings. In *effusion* of the wrist joint cross fluctuation on both anterior and posterior aspects of the joint can be elicited. Similarly in *compound palmar ganglion* cross fluctuation can be elicited above and below the flexor retinaculum. In *ganglion,* which is often a tense swelling fluctuation can be seldom elicited. Sometimes it is felt as hard as a bone. The ganglion becomes fixed as soon as the concerned tendon is made taut due to its intimate connection with the tendon sheath.

2) **Tenderness.**— Tenderness exactly on the joint line indicates arthritis. Tenderness along the tendon sheath indicates tenosynovitis.

3) **Deformity.**— By palpation the actual deformity is noted.

MOVEMENTS.— The wrist joint, like the elbow has got two components : (i) the radiocarpal and (ii) the inferior radioulnar joint. Pronation and supination movements occur at the inferior radioulnar joint. All other movements i.e. flexion, extension, adduction and abduction occur in both the radiocarpal and the midcarpal joints. Extension and adduction mostly occur in radiocarpal joint, whereas flexion and abduction take place in midcarpal joint. Normal range of flexion is about 60°, that of extension is about 70°, adduction about 35° and abduction about 25°.





Figs.15.16 & 15.17.— Showing the methods of testing the ranges of extension and flexion of the wrist joint. Note that there is restriction of both the movements on the affected left side.

Flexion and extension can be tested in the following way : to determine *the range of extension* the patient is asked to place his palms and fingers of both the hands in contact (Indian method of salutation). Now he is asked to lift both the elbows gradually as far as he can keeping the hands firmly in apposition. The angle formed by the hand and the forearm of the affected side is compared with that of the sound side. This angle is the range of extension movement. To determine the *range of flexion* the backs of the hands are placed in contact and the elbows are lowered as far as possible. The angle between the hand and forearm is the range of flexion movement.

In arthritis of the wrist joint all the movements of the wrist are painful and limited.

DIFFERENTIAL DIAGNOSIS

Acute arthritis.— This will lead to pain, tenderness and effusion of the joint.

Tuberculosis.— This is rarely seen in the wrist. The patient complains of gradual aching, stiffness and the hands feel weak. The wrist becomes swollen with wasting of the forearm, thenar and hypothenar muscles. The joint is kept flexed a little, later on cold abscess and sinus formation may result. X-ray shows narrowing and irregularity of the radiocarpal and midcarpal joints with rarefaction of the adjacent bones.

Ganglion.— This is a cystic swelling caused by mucoid or myxomatous degeneration of the connective tissue of the joint capsule or the tendon sheath. Usually young adults are affected. The patients present with painless lump which may give rise to slight ache and weakness. This is commonly seen at the back (dorsal aspect) of the wrist but may occur in front of the joint, when it may compress the median nerve leading to symptoms simulating carpal tunnel syndrome. The cyst contains crystal-clear gelatinous fluid. When on dorsal aspect of the wrist, the swelling becomes tense and prominent when the wrist is flexed. The gelatinous fluid is filled so tight that it feels solid.

Compound palmar ganglion.— This is nothing but chronic inflammation of the common sheath of the flexor tendons leading to swelling of this sheath (ulnar bursa) above and below the flexor retinaculum. Rheumatoid arthritis and tuberculosis are incriminated for this condition. The synovial membrane becomes thick and villous. The fluid contains fibrin particles and melon seeds. The patient presents with the swelling mostly without pain but with some wasting of the thenar and the hypothenar muscles. There may be some interfering with the movements of the fingers. Paraesthesia due to median nerve compression may occur. The swelling shows cross fluctuation above and below the flexor retinaculum.

De-Quervain's disease (Stenosing tenosynovitis).— This is a condition in which the common sheath of the tendons of abductor pollicis longus and extensor pollicis brevis becomes chronically inflamed, thickened and later on stenosed as a result of degenerative changes or unaccustomed over use. The patients are usually women in their forties. The main complaint is pain on the radial styloid process where the sheath enclosing the said two tendons exists. On examination there is local tenderness and a localized swelling may or may not be present. The pain is aggravated when the patient extends her thumb against resistance. If the wrist is passively adducted or the thumb is ulnar deviated, the patient winces with pain. With the thumb in the palm, the patient is asked to make a fist by superimposing the fingers over the thumb. The hand is then pushed passively to the medial (ulnar) side. Pain is experienced at the radial styloid process which shoots down to the thumb or upwards towards the elbow (Finkelstein's test).

Carpal tunnel syndrome.— This is nothing but a type of compression neuropathy of the

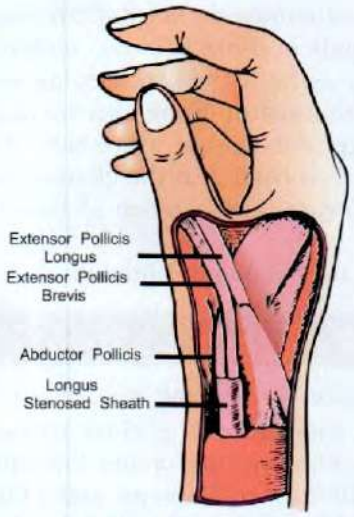

Fig. 15.18.— Diagrammatic representation of the positions of the tendons of the abductor pollicis longus and extensor pollicis brevis alongwith their common sheath which becomes thickened and stenosed in stenosing tenosynovitis (De Quervain's disease).

median nerve as it passes beneath the flexor retinaculum. This is due to narrowing of the osseo-fibrous tunnel (Carpal tunnel) either due to rheumatoid arthritis or pregnancy or as a complication of Colles' fracture or idiopathic (which by far outnumbers the other conditions). The majority of the patients are women between the ages of 40-60 years. This condition may be bilateral but more often the more active side is affected. The main complaint is progressive weakness and impairment of fine movements. Pain, tingling and numbness along the sensory distribution of the median nerve are also the presenting features. Occasionally the pain may shoot upwards and may mislead the clinician. On examination there will be some sensory changes and motor impairment of the nerve (median nerve) concerned. In late cases there may be wasting of the thenar eminence. When the patient is asked to flex the wrist there will be exacerbation of the symptoms particularly paraesthesia within 1 minute and the symptoms will disappear as soon as the wrist is straightened. This is known as the *'Wrist flexion Test' (Phalen's sign).* Electrical nerve conduction study will elicit a delay in motor conduction of the median nerve at the wrist.

THE HIP JOINT

HISTORY.— The most common symptom of the hip disorders is *pain,* which is mostly felt in front rather than in the buttock. The pain often radiates to the knee thus misleading the clinician. This is because of the fact that both the hip and the knee joints are supplied by the common nerves viz. the femoral, obturator and the sciatic. With destruction of the articular cartilages pain becomes worse at night due to disappearance of the protective muscular spasm. This is called "night pain".

Limp is the second complaint and this is more often discovered by the clinician or the relatives of the patient than the patient himself. The gait of the patient must be noticed very carefully. If a patient with a painful hip is using stick, he usually holds it in the opposite hand. Is he lurching on to the sound side or to the affected side? In arthritis the patient lurches on the sound side because he tries to take the weight off the affected side as quickly as possible to avoid pain. On the other hand the patient lurches on the affected side (Trendelenburg's gait) in unilateral congenital dislocation and coxa vara. This is to counteract the tendency of the pelvis to sink on the sound side when the leg of that side is raised off the ground. In bilateral congenital dislocation and bilateral coxa vara the characteristic *waddling gait* is seen.

Age of onset of symptom often suggests the diagnosis. From birth to 5 years — congenital dislocation; 5 to 10 years — Perthes' disease; 10 to 15 years — slipped epiphysis (adolescent coxa vara); 20 to 40 years — osteoarthritis due to previous disorders; over 40 years — osteoarthritis (idiopathic). Tuberculosis of the hip may occur at any age.

Preparation for examination.— A child is completely stripped for examination of hip joints. A man can only keep his shirts on. In case of females some cover for genitals is provided with.

INSPECTION.— *The patient is first inspected in the standing posture* both from front and behind.

Observe the gait carefully.

1. **Attitude.**— The clinician must not concentrate on the hip joint alone so far as the attitude of the patient is concerned. Any fixity of the hip joint either by muscular spasm or by fibrosis is made good by the mobility of the lumbar spine and the pelvis as a whole. In standing position it should be noted that the patient with arthritis of the hip joint tends to bear most of his weight on the sound leg. Thus the patient lurches on the sound side with slight flexion of the affected hip joint. A good look is made to detect any muscular atrophy which may result from long standing disease of the hip. Lastly one should look for any scar or sinus near the hip joint.



Figs.15.19 & 15.20.— Trendelenburg's test. Normally when the weight of the body is taken on one leg the pelvis rises on the other side. The test is positive if the pelvis drops on the other side. N & D indicate normal and diseased sides respectively.

Trendelenburg's test.— Normally each leg bears half of the body weight. When one leg is lifted, the other leg takes the entire weight and the trunk inclines towards the weight bearing leg and the pelvis tilts raising that side of the pelvis which is not taking the weight. This is due to the pull exerted by the abductors of the hip. When the mechanism fails, Trendelenburg's sign becomes positive. The test is performed in the following way: The patient stands on the unaffected lower limb first, the buttock on the affected side automatically rises. Next the patient stands on the affected side, the pelvis on the opposite (normal) side sinks as shown by gluteal folds and iliac crest. It indicates a defect in the osseo-muscular mechanism between the pelvis and the femur. This test becomes positive (i) when the abductors are weak as in poliomyelitis, muscle dystrophies or motor neurone disease; (ii) in congenital or pathological dislocation of the hip where the muscles do not have stable fulcrum to act on; (iii) in fracture neck of femur, coxa vara, Perthes' disease etc. when the lever system loses its intactness; (iv) when it hurts the patient as in different arthritis of the hip. Presence of fixed deformities are usually demonstrated with the patient lying on the bed.

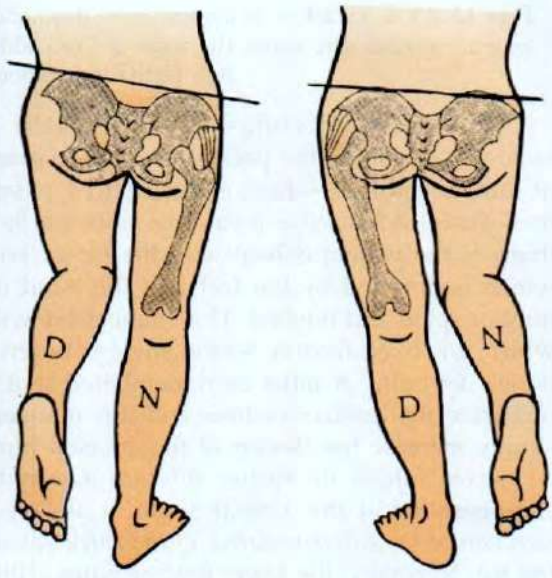

Figs.15.21 & 15.22.— Diagrammatic representation of Trendelenburg's test.

Fixed abduction or adduction deformity.— A limb when fixed in abduction position is brought to the ground by lateral flexion of the lumbar spine i.e. scoliosis with convexity towards the affected side, the pelvis being tilted down causing apparent lengthening of the limb. Similarly a fixed adducted limb is brought parallel to its fellow by scoliosis with convexity towards the sound side, the pelvis being tilted up causing apparent shortening of the limb. *To ascertain the nature of the deformity,* a line is drawn connecting the two anterior superior iliac spines. This line is normally horizontal and at right angles to the midline of the body. In presence of abduction and adduction deformities it will no longer be horizontal. In the former, the anterior superior iliac spine on the affected side will be at a lower level, whereas in the latter it will be found at a higher level. Now the *angle of deformity* is estimated in the following way :—

The affected limb is held just above the ankle and is gradually adducted or abducted according to the existing deformity till the interspinous line becomes horizontal. Now the *angle of deformity* is estimated by the amount of abduction or adduction made in relation to the normal vertical to bring interspinous line horizontal.

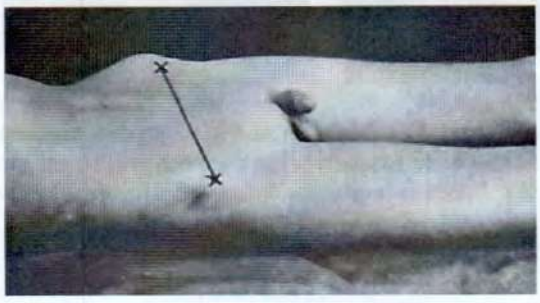

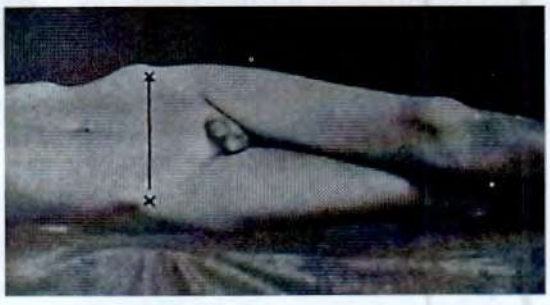

Figs.15.23 & 15.24.— In the first figure fixed adduction deformity has been concealed by raising the left anterior superior iliac spine. The angle of fixed adduction deformity is measured by adducting the affected limb till the interspinous line becomes horizontal.

Fixed flexion deformity.— This is usually made good by lordosis of the lumbar spine. In recumbent position the patient is asked to extend the limbs. He will be able to do so in expense of lumbar lordosis, which is detected by passing a hand behind the lumbar spine. *The angle of fixed flexion deformity is accurately measured by Hugh Owen* **Thomas' test.** In this test the sound thigh of the patient is bent with the flexed knee till the lumbar lordosis completely disappears, which is detected by the fact that the hand of the clinician cannot be insinuated between the lumbar spine and the bed. This manoeuvre will automatically bend up the hip upto the angle in which it is fixed flexion. So the angle between the affected thigh and the bed is *the angle of fixed flexion deformity.* It must be remembered that the sound thigh is flexed only upto the point to obliterate the lumbar lordosis and this manoeuvre should not be forcibly continued as this will simply increase the flexion of the affected hip showing an exacerbated deformity.

Fixed lateral or medial rotation deformity.— This deformity cannot conceal itself by compensation at the lumbar spine. It always remains revealed and *is determined by noting the direction of the anterior surface of the patella or* of the toes when the foot is held at right angle to the leg. Normally, the lower limb remains with a slight lateral rotation. So in recumbent position if the patella or the toes point up to the ceiling, it indicates slight medial rotation. In presence of marked rotation deformities there will be corresponding change in the direction of the anterior

surface of the patella or the tips of the toes.

Is the affected limb shortened? This is easily demonstrated in case of children by flexing both the hip joints as well as the knees. The levels of the knees are compared (Fig. 15.27). The details of taking measurements of the limbs are discussed later in this chapter.



Fig.15.25.— It is shown that even with the 'fixed flexion' deformity the patient can extend his hip joint fully by bending the lumbar spine forwards.

In tuberculous arthritis of the hip joint, the attitude is typical and differs according to the stage of the disease. *IN STAGE 1* (Synovitis) — there is effusion into the joint which demands maximum capacity within the joint and is obtained by the optimum position i.e. slight flexion, slight abduction and lateral rotation (Fig. 15.28). Flexion is concealed by lumbar lordosis and by tilting the pelvis forwards. Abduction is corrected by tilting the pelvis downwards and scoliosis of the lumbar spine with convexity towards the affected side. This is called *the stage of apparent lengthening*, as the pelvis is tilted downwards and the affected limb looks longer than its fellow. *IN STAGE 2* (Arthritis) — the effusion subsides and the articular cartilage is involved. This leads to spasm of the powerful adductors and flexors of the hip to protect its movements, which is very painful. So the attitude becomes one of the slight flexion, slight adduction and medial rotation (Fig. 15.29). Flexion is concealed as discussed earlier. Adduction is corrected by tilting the pelvis upwards resulting in scoliosis of the lumbar spine with convexity towards the sound side. This is called the *stage of apparent shortening*, as the pelvis is tilted upwards and the affected limb looks shorter than its fellow. *IN STAGE 3* (Erosion) — there will be erosion of the upper part of the acetabulum and the femoral head becomes dislocated by the spasm of the adductors (Wandering acetabulum or pathological dislocation). This is the *stage of real shortening*. The attitude is more or less similar to that of stage 2 except for the fact that deformities are exacerbated at this stage. In this context one should remember the *various causes of pathological dislocation*. Besides tuberculosis which is by

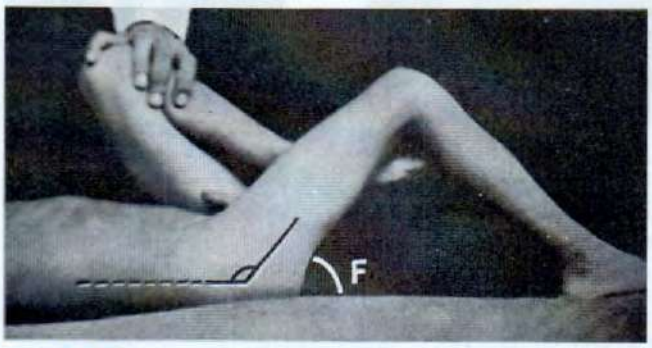

Fig.15.26.— Thomas' test is demonstrated. The normal hip is flexed to the limit to obliterate the compensatory lordosis. This will flex the affected thigh to the extent of 'fixed flexion' deformity. 'F' shows the angle of fixed flexion deformity.

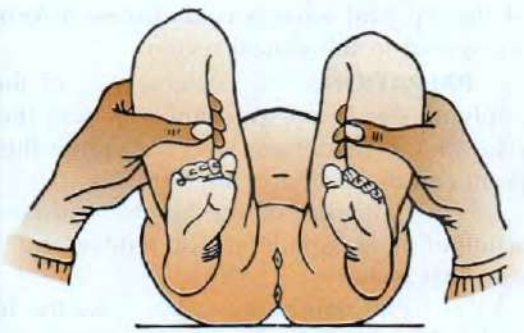

Fig.15.27.— Demonstration of how shortening of the affected limb is measured in case of children.



Fig.15.28.— First stage of tuberculosis of the left hip joint. The deformity is one of flexion, abduction and external rotation with apparent lengthening.



Fig.15.29.— Second stage of tuberculosis of the left hip joint. Note the deformity of flexion, adduction and internal rotation with apparent shortening.

far the commonest cause, septic arthritis and very occasionally typhoid arthritis may sometimes give rise to this type of dislocation.

In adolescent coxa vara, the attitude is one of marked external rotation with slight adduction possibly due to eversion of the femur resulting from upper epiphyseal separation.

In congenital dislocation of the hip, the attitude is one of lordosis, which is particularly marked in bilateral cases with undue protrusion of the abdomen anteriorly and the buttock posteriorly. The space just below the perineum is broadened. In unilateral cases the grooves between the labia (girls are more often affected) and the thigh are asymmetrical and an additional skin crease on the medial side of the thigh can be noticed.

2. **Muscular wasting.**— In any long standing disease of the hip joint there will be obvious muscular wasting mainly affecting the glutei and adductors. This becomes obvious in tuberculosis. Circumference of the thigh should be measured to know about wasting. It must be remembered that flattening of the buttock and loss of gluteal fold may be brought about by flexion of the limb besides muscular wasting.

3. **Swelling.**— This is occasionally seen in tuberculous arthritis of the hip joint when a cold abscess is formed either in the femoral triangle or in the gluteal region.

PALPATION.— 1. **Tenderness** — of the hip joint is elicited by applying steady pressure inwards over the two greater trochanters (Fig. 15.31). Tenderness over the joint a little below the midinguinal point can be elicited in any arthritis.

2. Palpation of the **greater trochanter** is important to note whether it is broadened or tender and whether it is displaced upwards or not.

3. **Palpation of hip joint.**— As the hip joint lies in its socket and is heavily clothed with strong muscles all around, this joint is almost inaccessible. Only a small part of the neck which lies outside the socket but inside the capsule may be palpated to know if the joint is diseased or not. To palpate this part a finger is placed just below the inguinal ligament and lateral to the femoral artery. The finger is pressed deep to detect if there is any tenderness or not. Tenderness indicates arthritis of the joint.



Fig.15.30.— Note the characteristic attitude of adolescent coxa vara. The deformity is one of marked external rotation with slight adduction.

4. **Swelling.**— Effusion of the hip joint, when considerable, as in suppurative arthritis in children, presents itself as a fluctuating swelling just below the midinguinal point. For *cold abscess* one should search the following regions : (a) in front of and medial of the greater trochanter, (b) on the medial side of the femoral vessels, (c) posteriorly in the gluteal region and (d) rarely in the pelvis from perforation of acetabulum. Such abscess may gravitate towards the ischio-rectal fossa and may burst to form fistula-in-ano.

5. **The femoral artery** is felt particularly in congenital dislocation of the hip. This artery passes over the head of the femur and this bony support helps its palpation. In congenital dislocation the head of the femur is dislocated and this bony support is missing. So there will be great difficulty in feeling this artery. This is known as 'Vascular sign' of Narath (Fig. 15.32).

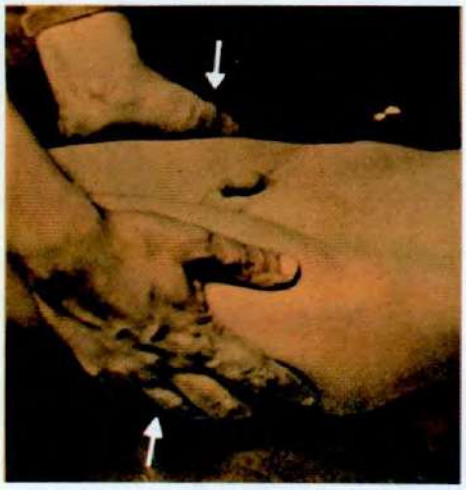

Fig.15.31.— Method of eliciting tenderness in the hip joint. Simultaneous steady pressure inwards over the two greater trochanters elicits pain on the affected side.

MOVEMENTS.— Flexion, extension, abduction, adduction, rotations and circumduction are the different movements of the hip joint. During examination the clinician must always compare the range of a certain movement of the affected joint with that of the sound counterpart. This is because of the fact that the range of each movement varies according to the individuals. The average ranges of movements are as follows :

Flexion — with the knee extended cannot be done more than 90° due to the tension of the hamstring muscles which prevents full flexion; but with the bent knee the hip joint can be flexed upto 120° or more till the front of the thigh comes in contact with the front of the abdomen.

Extension — is permitted to about 15°; *Abduction* — to about 40°; *Adduction* — to about 30°, that means the limb can be made to cross the middle third of the other thigh. *Internal rotation* — is possible to about 30° and *external rotation* — to about 45°.



Fig.15.32.— Femoral artery is difficult to feel in congenital dislocation of hip because of loss of bony support.

During **testing the movements** (both active and passive movements) one must make sure that the pelvis does not move. For this, the pelvis is steadied by the clinician.

1. **Flexion.**— Firstly the pelvis is grasped and the patient is asked to flex the hip as far as possible. The amount of flexion possible without causing any movement of the pelvis is noted. When there is a *"fixed flexion deformity"*, the exact range of free flexion present can be demonstrated in the following way : The Thomas test is first performed. The thigh of the sound side is held and the patient is asked to make an attempt to flex the affected hip. Any bending of the thigh beyond the position of "fixed flexion" is the range of free flexion permissible to the joint.

2. **Extension.**— In fixed flexion deformity, extension of the joint is not possible at all. This is demonstrated by applying a downward pressure on the thigh after the affected limb has been kept in the position of fixed flexion deformity by Thomas' test. When there is no fixed flexion deformity, extension of the hip joint is best tested by lying the patient in prone position on the table and asking him to lift affected limb (Fig. 15.33). The range of extension is not more than 15° and is first restricted in arthritis of the hip joint.

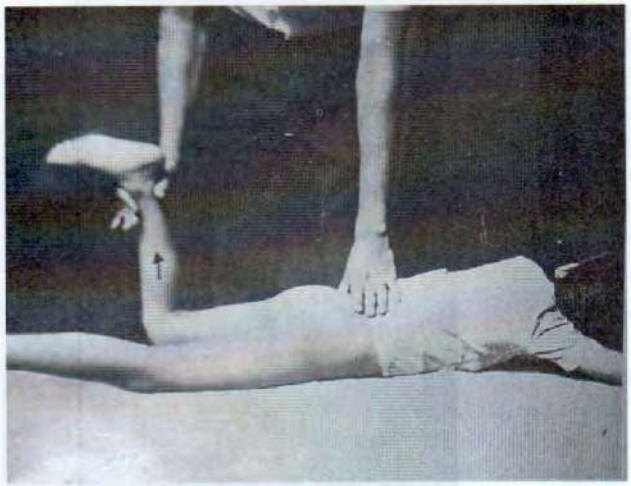

Fig.15.33.— Method of testing extension when there is no 'fixed flexion' deformity.

3. **Abduction.**— The range of abduction can be tested in two ways. *In the first method* the patient lies supine on the table. The pelvis is steadied by holding the iliac crest of the affected side. In case of children the thumb and the middle finger of the left hand of the clinician are used to touch the two anterior superior iliac spines so that any movement of the pelvis will be detected at once (Fig. 15.34). Keeping the pelvis at right angle to the limbs the patient is asked to abduct the affected limb. It can be compared with that of the sound side. The *second method* is to make the patient lying on the table in supine position. Flexing his both hips and the knees the soles of the feet are placed together. The knees are now bent outwards simultaneously on both sides. The range of abduction on both the sides can be measured. It may be noted that the abduction is the first movement to be restricted in tuberculous arthritis.



Fig.15.34.— Shows the method of testing abduction and adduction of the hip with the knee extended. Note that the clinician touches the two anterior superior iliac spines to detect any movement of the pelvis.

4. **Adduction.**— The pelvis is first steadied and the patient is asked to lift the affected limb and then cross it over its fellow. It is noted whether the limb crosses the sound thigh at its upper third or middle third or lower third.

5. **Rotation.**— The patient lies supine on the table. The clinician places the flat of his hand upon the thigh and moves the limb to and fro observing the foot as an index of the degree of rotation. Rotatory movement can also be tested by flexing both the hip and the knee joints of the affected side to the right angles and then rotating the thigh internally and externally by holding the foot (Fig. 15.37). These movements are also tested by asking the patient to lie on his face to flex the



Fig.15.35.— Shows the second method of testing the abduction movement with acutely flexed knees.

knee to the right angle and moving the whole leg sidewise (Fig. 15.38).

The restriction of different movements depends upon the nature of affection of the hip joint. *In any arthritis,* including tuberculous variety, restriction of all the movements is the characteristic feature. *In adolescent coxa vara,* there will be limitation of abduction and internal rotation, but adduction and external rotation are not only be free but often exaggerated. *In Perthes' disease,* again abduction and internal rotation are restricted. *In congenital dislocation of the hip,* abduction and rotations are limited to varying degree, flexion and extension are free whereas adduction is excessive.



Fig.15.36.— Easiest method of testing rotations of the hip joint keeping both the hip and knee joints extended.

Examination for stability.— Stability of the hip joint is mainly jeopardized in congenital dislocation of the hip. So the following three tests are performed when this condition is suspected.

(1) *Telescopic test.*— The pelvis is fixed with one hand touching the greater trochanter. The hip is now flexed to 90° and the knee is grasped with the other hand of the clinician, who pushes the thigh downwards along the axis of the thigh with this hand, while the other hand notes whether the greater trochanter is moving downwards. This "positive telescopic test" is seen in congenital as well as pathological dislocations of the hip and in Charcot's joint.

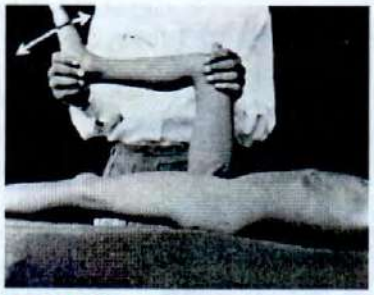

Fig.15.37.— Shows the method of testing the rotation movement of the hip joint keeping the hip and knee flexed. This test can be performed in 'fixed flexion' deformity of the hip.

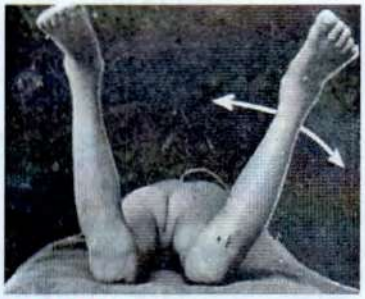

Fig.15.38.— Shows another method of testing rotations of the hip. Note that this test cannot be performed in 'fixed flexion' deformity of the hip.

(2) *Ortolani's test.*— Both the hips and knees are flexed by holding the limbs. Now the thigh of the affected side is gradually abducted. A 'click of entrance' will be felt as the femoral head slips into the acetabulum and a 'click of exit' as it quits the acetabulum when the pressure is released.

(3) *Barlow's test.*— The surgeon holds both the lower extremities in such a way that the hips are flexed at 90° and the knees are fully flexed. The lower limbs are now completely adducted and pressure is exerted downwards along the bony axis of the femur while the little fingers of both the hands are placed on the greater trochanters. If the hip is dislocatable, the femoral head will be heard to roll over the posterior rim of the acetabulum as a distinct 'cluck'. The hip is dislocated. The second phase of the test is



Fig.15.39.— Telescopic test. The femur can be moved on to the dorsum ilii in congenital and pathological dislocation of the hip.



Fig.15.40.— Ortolani's test.

started. The hip is now gradually abducted from the position of full adduction. The little fingers on the greater trochanter are now pushed inwards simultaneously. The head can now be felt to reduce with a soft cluck into the acetabulum.

MEASUREMENTS.— (1) **Length.**— The length of the whole limb is measured from the anterior superior iliac spine to the tip of the medial malleolus. When only length of the thigh is measured, measurement is taken from anterior superior iliac spine to the joint line of the knee. It must be remembered before taking the measurement that the interspinous line is brought to the horizontal level by abducting or adducting the affected limb. While comparing the length of the affected limb with that of the sound limb, the sound limb must be placed in the same position as the affected one. That means, if there is adduction deformity of the affected limb, the normal limb must also be adducted *to the similar extent* before the measurements. The bony points which are considered for measurement must be marked with skin pencil first before taking the measurements.

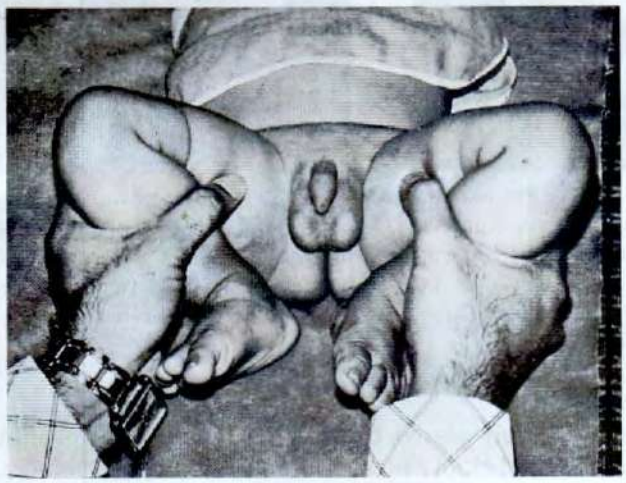

Fig.15.41.— Barlow's test. See the text.

(2) **Girth of the limb.**— This is measured to find out the presence or absence of muscular wasting. When there is considerable muscular wasting, it can be assessed by inspection only. The importance of this measurement remains only in cases of slight muscular wasting which may not be obvious on inspection. A mark is made on the affected limb at a convenient distance from the anterior superior iliac spine. This mark is made on both the limbs and circumferences of the limbs at that level are compared.

(3) **Shortening above the greater trochanter.**— This is determined by drawing the Bryant's triangle, Nelaton's line etc., as discussed in 'Injuries around the hip' (See page 199). The greater trochanter is raised in dislocation of the hip, separation of the upper femoral epiphysis (adolescent coxa vara) and to a slight extent when the head of the femur eroded e.g. in Perthes' disease, suppurative arthritis etc.

Lymph nodes.— Palpation of lymph nodes is important in inflammatory conditions, be it acute or chronic of the hip joint. The external iliac group of lymph nodes are palpated by deep palpation.

Other joints.— Examination of the hip joint remains incomplete until other major joints

like lumbosacral spine, sacroiliac joints and especially the knee joints are examined.

Rectal examination should be undertaken in tuberculous arthritis if an intrapelvic abscess is suspected.

SKIAGRAPHY

The general points discussed in Chapter 12 should be borne in mind. In pathology of the hip *Shenton's line* which extends from the upper curved border of the obturator foramen on to the lower border of the neck of the femur is important and is a continuous arched line. In Perthes' disease or in tuberculous arthritis where destruction of the head of the femur becomes obvious this line will be slightly distorted; but in pathological dislocation this line will be grossly distorted.

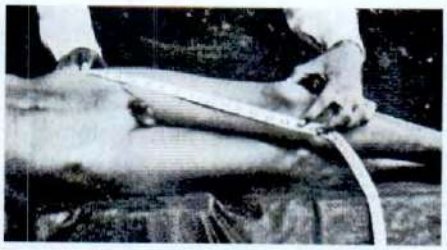

Fig.15.43.— Shows the method of taking measurement of the thigh from the anterior superior iliac spine to the joint-line of the knee. The thigh of the normal side has been adducted the affected hip is deformed in adduction.

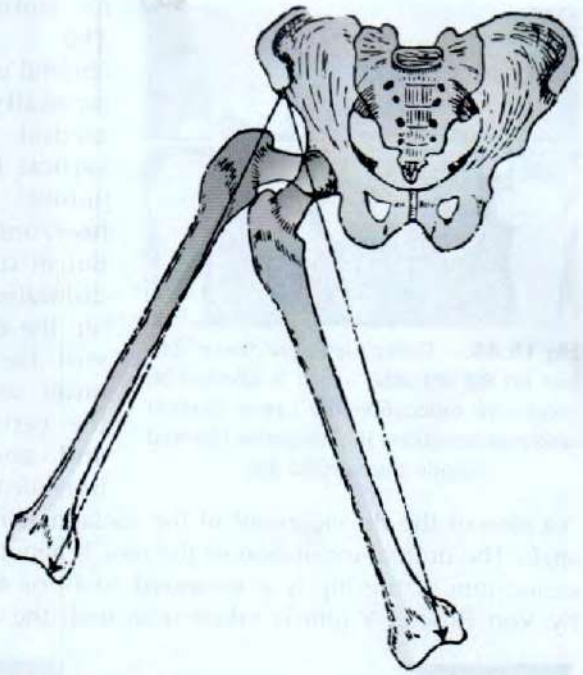

Fig.15.42.— Shows that the distance from the anterior superior iliac spine to the joint line of the knee is shorter when the limb is abducted and longer when adducted.

In congenital dislocation of the hip X-ray picture will show that the upper epiphysis of the femur of the affected side is usually smaller than the normal side. The neck is anteverted and is not properly seen in X-ray due to superimposition. There will be distortion of the Shenton's line. When the dislocation is of mild nature, the following lines are drawn to detect the pathology. These lines are known as *Perkin's lines*. A horizontal line is drawn through the triradiate cartilage and a vertical line is drawn down from the outer edge of the acetabulum

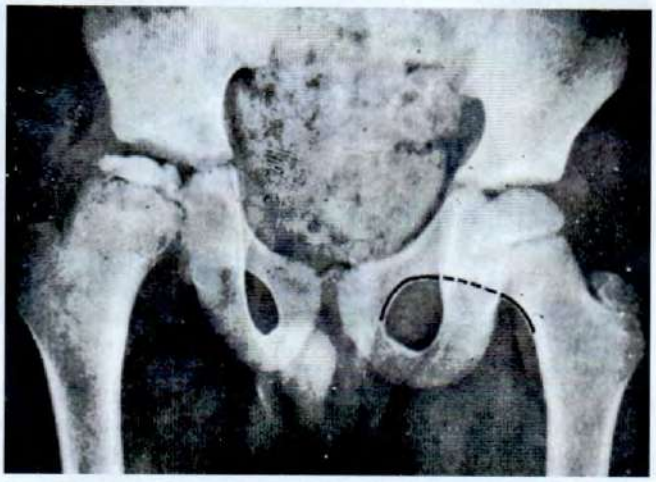

Fig.15.44.— Shenton's line has been drawn on the normal left side. On the right side which is affected by Perthes' disease, if this line is drawn it will not correspond with the upper curved border of the obturator foramen.



Fig.15.45.— Perkin's lines are drawn. See that on the left side, which is affected by congenital dislocation the upper femoral epiphysis lies above the horizontal line and outside the vertical line.

on both sides. The upper femoral epiphysis normally lies medial to the vertical line and below the horizontal line. But in congenital dislocation of the hip the epiphysis will lie on the outer aspect of the vertical line and above the horizontal line.

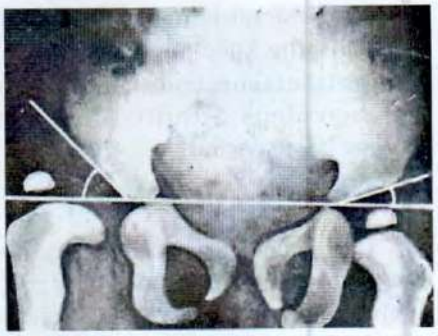

Fig.15.46.— Normal inclination of the acetabular roof is about 22° from the horizontal plane, but in congenital dislocation of the hip it is increased to 40° to 45°.

An idea of the development of the acetabular roof may be obtained by drawing the *acetabular angle.* The normal inclination of the roof is about 22° from the horizontal plane, but in congenital dislocation of the hip it is increased to 40 or 45 degrees. Another manoeuvre was advocated by Von Rosen. A film is taken with both the hips abducted to 45° and internally rotated. If the line of the femoral shaft is extended upwards, it will touch the acetabular roof on the normal side; on the dislocated side it will strike the pelvis above the top of the acetabulum. An *arthrogram* is essential before advocating the type of treatment required for the particular case. Lateral views may be taken to measure anteversion of the neck.



Fig.15.47.— Perthes' disease. See the text.

In Perthes' disease early stage will be evident in X-ray, with increased joint space (this is a differentiating point from tuberculous arthritis) and the head of the femur will stand away a little laterally. With the onset of ischaemia the femoral head will show increased density — at first granular and later on uniform. As the condition advances flattening of the head with patchy fragmentation becomes obvious. The neck of the femur becomes wide with a band of rarefaction and even a cystic appearance with surrounding sclerosis will be seen at the metaphysis.

In slipped epiphysis (adolescent coxa vara) even a trivial change becomes apparent in antero-posterior film. The epiphyseal cartilage becomes wider and "wooly" on its metaphyseal side. A line drawn along the upper surface of the neck of the femur normally passes through the superior part of the head of the femur. In slipped epiphysis this line passes superior to the head



Fig.15.48.— X-ray of a typical case of Perthes' disease involving left hip.



Fig.15.49.— X-ray of a case of adolescent coxa vara showing the typical displacement of capital epiphysis.

(Trethowan's sign). The posterior acetabular margin normally cuts across the medial corner of metaphysis. But in slipped epiphysis the entire metaphysis remains lateral to the posterior acetabular margin (Capener's sign). In the lateral view the deformity is usually obvious from the beginning. The upper epiphysis of the femur is displaced backwards and downwards. The neck-shaft angle is reduced to a varying extent from the normal (about 150° in a child and 127° in an adult). The neck is pushed up and externally rotated causing the lesser trochanter to be more prominent.



Fig.15.50.— Tuberculous arthritis showing destruction of the femoral head. Triangle at the inferior aspect of the femoral neck indicates the position of Babcock's triangle.



Fig.15.51.— Shows the typical wandering acetabulum on the left side.

In **tuberculosis of the hip joint** the earliest sign is general haziness of the bones as seen in a bad film, with or without an area of rarefaction in the Babcock's triangle (Fig.15.50) or in the upper part of aceta-



Fig.15.52.— X-ray of an advanced case of tuberculosis of hip. Note the wandering acetabulum.

bulum. The joint space may be increased due to effusion. In the next stage, destruction of the articular surfaces will lead to loss of distinct outline of the articular ends with diminution of the joint space. In the final stage further destruction of the upper part of the acetabulum allows the deformed head to be dislocated on to the eroded dorsum ilii, which is then called the "travelling or wandering acetabulum". Such dislocation can be easily demonstrated in X-ray and by drawing the Shenton's line.

Ultrasound.— It can confirm clinical suspicion, may be used as a screening tool and also to monitor early treatment.

DIFFERENTIAL DIAGNOSIS

Congenital dislocation of the hip or Developmental dysplasia of the hip (DDH).— This condition is commonly seen among girls and about 4 times more frequently seen than the boys. This is more commonly seen in European countries and in Japan, but a rare occurrence in Chinese and Negro races probably due to the fact that the latters carry their babies on their backs with the hips abducted. The earlier the diagnosis is made, the easier will be the treatment and more will be the chance of cure.

In *the neonate and the infant* this condition is diagnosed firstly by Barlow's test, Ortolani's test and telescopic test. Limited abduction in flexion of the hip indicates actual dislocation. Extra skin crease along the medial aspect of the thigh in unilateral case and widening of the perineum in bilateral case will be noticed by an observant mother. Lastly delayed walking and a limp when the child begins to walk should arouse suspicion of this condition.

In childhood, that means when weight bearing has already been started, typical Trendelenburg's gait i.e. the patient lurches on the affected side becomes obvious. In bilateral cases typical waddling gait may be missed by the clinician but will not be missed by an observant mother. There will be obvious lordosis and prominence of the hips. Movements are painless, but abduction and rotations are limited in completely dislocated hip. The "vascular sign" of Narath becomes positive. The findings in X-ray have already been discussed in the earlier section. Arthrography, i.e. injection of diodone (3 ml) into the joint is helpful in determining the presence of limbus or hour-glass constriction of the capsule. Ultrasound helps in diagnosis.

Perthes' disease (Pseudocoxalgia, osteochondritis juvenilis).— The underlying pathology is deficient blood supply to the head of the femur, which undergoes aseptic necrosis resulting in collapse. The cause is still to be known. Unlike the previous condition the boys are more affected by this condition and about 4 times commoner than the girls. The boys are mainly between the ages of 5 to 10 years. The most constant early sign is a comparatively painless limp. In the beginning, when the joint becomes rather irritable, more or less all movements are slightly restricted. Later on in the established stage *there is limitation of abduction and internal rotation.* Other movements are full and painless. Muscular wasting of the limb becomes obvious and there may be moderate flexion and adduction deformity. In established cases there may be a little real shortening of the limb. In 10% of cases the condition may be bilateral. Trendelenburg's sign may or may not be positive. The diagnosis cannot be confirmed without skiagraphy, the findings of which have been discussed in the earlier section.

Slipped epiphysis (adolescent coxa vara).— Boys and girls are affected by this condition in the ratio of 3 : 2 with the average age of onset is 15 in case of boys and 12 (rarely seen after menstruation has started) in case of girls. The majority of the patients are overweight and sexually underdeveloped. There may be a history of trauma in which case this condition suddenly appears, otherwise the majority of cases are gradual in onset. The earliest symptom is a painful limp and pain may be referred to the knee joint. Continued weight bearing will lead to more pain and limp with shortening and external rotation of the limb. Trendelenburg's sign is mostly positive. The patient stands with leg adducted and externally rotated limb. As regards movements the

most constant and diagnostic are *limitations of abduction and internal rotation.*

On examination the greater trochanter is higher and more posteriorly placed than the unaffected side. Muscular wasting is little present. X-ray is confirmatory and discussed earlier.

Tuberculosis of the hip.— No sex or age is exempt from this disease. The hip joint is second only to the vertebral column so far as the sites of tuberculosis of the bones and the joints are concerned. The disease starts as synovitis or as a bony focus in the acetabulum or in the femoral head (more frequently in Babcock's triangle). The earliest sign is the *limp*, which in the beginning comes on after the patient has walked some distance. Later on it becomes evident even in the early morning. *Pain* is probably the first symptom which is more often referred to the thigh or

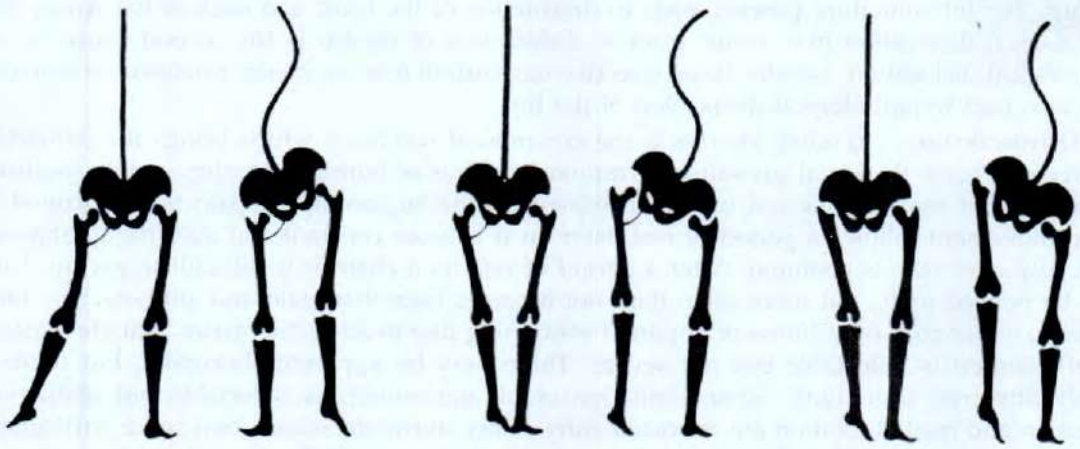

Fig.15.53.— Diagrammatic representation of the various stages of tuberculosis of the hip.
See Page 238 and figures 15.28 and 15.29.

to the knee than to the hip. The general signs and symptoms such as malaise, pallor, loss of weight, evening rise of temperature, night sweat etc. may be noticed. Muscular wasting becomes obvious very soon. "Night cry", i.e. pain starting at night is very important and this indicates the movement between the inflamed joint surfaces allowed by disappearance of protective muscular spasm during sleep. On examination, the characteristic deformities of different stages have already been discussed in details under the heading of "attitude". Limitation of movements occurs *in all directions.* X-ray is confirmatory.

Acute suppurative arthritis.— This condition is more common in children. A child with high pyrexia, a limp, pain in the hip with redness and brawny oedematous swelling, should be considered as suffering from acute suppurative arthritis. The hip joint is kept in position of flexion, slight abduction and external rotation — 'optimum position' to accommodate more fluid. Gentle pressure over the joint will cause the child to scream. Diagnosis is confirmed by aspirating the hip joint with a needle under anaesthesia.

Irritable hip.— The patient usually presents with pain and limp. Both become evident following activity. The pain is felt in the groin and may be referred to the knee joint. There will be slight wasting, but the cardinal sign is the *limitation of all movements at their extremes.* The patient is immediately put to bed and a skin traction is applied to the affected leg. Investigations like examination of the blood and X-ray are essential to come to a diagnosis. The followings are the causes of this condition.

(i) *Transient synovitis.*— Minor trauma is the presumed cause and there will be effusion

of the hip joint. The symptoms may mimic acute suppurative arthritis, but absence of toxaemia, high pyrexia, localized redness and oedema will differentiate this condition from acute suppurative arthritis. X-ray will reveal a normal joint and the investigations will be normal. A few days' bed rest will absorb the effusion and normal ranges of movement will be restored.

(ii) *Chronic synovitis.*— A chronic synovitis from rheumatoid arthritis is very difficult to distinguish and sometimes indistinguishable from tuberculosis in the early stage.

Besides these conditions, (iii) Perthes' disease, (iv) slipped epiphysis and (v) tuberculosis are sometimes the causes of irritable hip.

Pathological dislocation of hip.— *Acute arthritis following* acute osteomyelitis of the femoral head or neck seems to be the commonest condition which leads to pathological dislocation of the hip. The inflammatory process leads to destruction of the head and neck of the femur and pathological dislocation may result from it. *Tuberculosis of the hip* is the second cause of the pathological dislocation. Besides these infective destructive lesions, *spastic paralysis, poliomyelitis* may also lead to pathological dislocation of the hip.

Osteoarthritis.— In adult life this is the commonest condition which brings the patient to a surgeon. *Pain* is the usual presenting symptom which is of boring character, mainly localized to the hip but may be referred to the knee joint. In the beginning the pain is complained of when movement follows a period of rest, later on it is more constant and disturbing. *Stiffness,* especially after rest, is common. After a period of rest on a chair, it is difficult to get up. *Limp* may be noticed early, but more often than not it comes later than pain and stiffness. The limp is due to either pain or stiffness or apparent shortening due to adductor spasm. Muscle wasting (chiefly glutei) is detectable but not severe. There may be apparent shortening but there is hardly any true shortening. Some limitation of all movements is detectable but abduction, extension and medial rotation are restricted early. X-ray shows decreased joint space particularly at the pressure areas. Elsewhere the joint space is not decreased. The bone becomes sclerosed with lipping and osteophytes at the margins of the joint. There may be cyst in the femoral head.

THE KNEE JOINT

HISTORY.— The common symptoms, with which a patient generally presents, are pain, swelling, stiffness, mechanical disorders (e.g. locking, giving way, click etc.) and limp.



Fig.15.54.— Tuberculous arthritis of right knee. Note the wasting of the muscles (compare with the left thigh). There are flexion, lateral rotation and posterior subluxation (triple displacement) of the affected knee.

INSPECTION.— Both the lower limbs are fully exposed for proper inspection. The patient is first examined in the standing position both from front and behind, secondly in the seated position, thirdly in the supine position and lastly in the prone position. During these examinations the hip is also examined, as very often a patient with the pathology in the hip will complain of pain in the knee. In the conclusion the students must not forget to examine the *popliteal fossa* both in the standing position and in the prone position.

1. **Gait.**— The patient is carefully observed while he enters the clinic. With the stiff knee the affected leg will swing outwards during walking.

In other conditions the patient will limp mostly lurching on the sound side to avoid weight bearing through the affected knee.

2. **Attitude.**— In arthritic joint, be it the first stage of tuberculous arthritis or acute arthritis, the joint will assume a position of moderate flexion — the 'optimum position' of the knee joint to accommodate maximum fluid within the joint cavity. As the arthritic process continues, the joint surfaces are destroyed so are the ligaments resulting in "triple displacement" i.e. flexion, posterior subluxation and lateral rotation of the tibia due to the contraction of the hamstring muscles. This indicates destruction of the cruciate and collateral ligaments. Abnormal abduction (genu valgum), abnormal adduction (genu varum) or abnormal hyperextension (genu recurvatum) are carefully noted. In case of locking the patient fails to extend the joint beyond a certain angle and the knee is kept in flexed position with limping. *Always note the anterior surface and the position of patella.* This often gives some idea about the nature of existing deformity.



Fig.15.55.— Genu valgum.

3. **Swelling.**— An *effusion* of the knee joint gives rise to a horse-shoe swelling above the patella and on both sides of the patella and the ligamentum patellae obliterating the normal depressions. This condition may be confused with superficial cellulitis, but the latter will extend over the patella and its ligament which is never the case in effusion of the joint. Bilateral effusion of the joint is uncommon and may occur in bilateral injury to the knee, in syphilitic affection (Clutton's joints) or in haemophilia.



Fig.15.56.— Genu recurvatum.

Extra-articular swellings are quite common around the knee due to enlargement of the different *bursae* around the joint. The semimembranosus bursa is seen behind the knee on its medial aspect and slightly above the joint line. It becomes more prominent and tense on extension of the knee. Prepatellar bursa which is situated just in front of the lower part of the patella and ligamentum patellae may be inflamed and enlarged in prepatellar bursitis (housemaid's knee). Infrapatellar bursa (lying deep to the ligamentum patellae), bicipital bursa (lying under the biceps tendon) may occasionally be enlarged. The suprapatellar bursa almost always communicates with the knee joint and becomes swollen in effusion of the joint. Morrant Baker's cyst which is a herniation of the synovial membrane posteriorly through the fibres of the oblique popliteal ligament forms a swelling in the middle of the posterior aspect of the knee slightly below the joint line (See Fig. 15.66). This condition also gives rise to a swelling on the posterior aspect of the knee joint in its middle and becomes prominent on extension and disappears on flexion of the joint. This condition is often associated with tuberculosis or osteoarthritis of the joint.

4. **Muscular wasting.**— This should be looked for both above and below the joint. But in affections of the knee joint if there be any muscular wasting, it is more obvious in the thigh.

PALPATION.— (1) Firstly one should examine for **local temperature** with the back of the hand and compare it with that of the other side. Look for **local tenderness.**

(2) **Swelling.**— So far as the effusion of the joint is concerned, two important tests may be performed — fluctuation and "patellar tap".



Fig.15.57.— Showing how to demonstrate fluctuation test in effusion of the knee joint.

Fluctuation is demonstrated by pressing the suprapatellar pouch with one hand and feeling the impulse with the thumb and the fingers of the other hand placed on either side of the patella or the ligamentum patellae.

"Patellar tap" which is a pathognomonic sign of effusion of the knee joint, is elicited by pressing the suprapatellar pouch with one hand driving whole of its fluid into the joint proper so as to float the patella in front of the joint. With the index finger of other hand the patella is pushed backwards towards the femoral condyles with a sharp and jerky movement. The patella can be felt to strike on the femur, which is known as "patellar tap". A moderate amount of fluid must be present in the joint to make this test positive.



Fig.15.58.— Showing how to demonstrate 'patellar tap' in effusion of the knee joint.

For demonstration of small amount of fluid in the knee joint two tests can be performed. The patient keeps standing and gentle pressure is applied over one of the obliterated hollows on either side of the ligamentum patellae (in order to displace fluid) and now the pressure is released. The hollow will be refilled slowly. The second method is to elicit 'patellar tap' with the patient standing.

A thickened synovial membrane may also present a fluctuating swelling in the joint line, on either side of the patella and just above the patella. Its "spongy" or "boggy" feel and absence of patellar tap differentiate it from effusion of the joint. The edge of the thickened synovial membrane can be rolled under the finger as in a lipoma, but there is no edge felt in effusion as in a cyst.

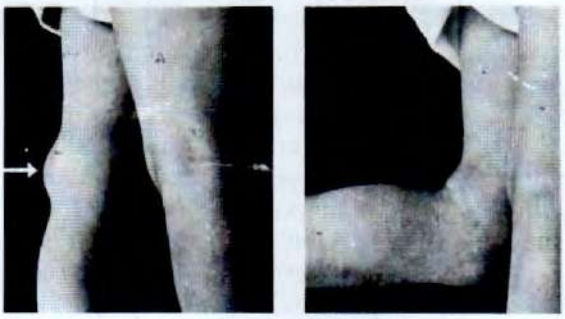

Figs.15.59. & 15.60.— Enlarged semimembranosus bursa which becomes obvious on extension and disappears in flexion of the knee joint.

When a swelling appears to be an *enlarged bursa*, its relation with the tendon (by making the appropriate tendon taut), its consistency, its mobility and translucency are ascertained. Whether the bursa communicates with the joint or not is also assessed. In case of bursae in the popliteal fossa, these are examined in the prone position keeping the knee joint flexed for proper palpation.

A swelling in the joint line on the lateral

side of the ligamentum patellae is probably a *cyst of the lateral semilunar cartilage.*

Any swelling in the popliteal fossa (particularly in the midline) should be examined for expansile pulsation. *Popliteal aneurysm* is not uncommon.

Transillumination test should always be performed in case of swellings around the knee joint. This test will be positive when swelling is an enlarged bursa or any cystic swelling e.g. Morrant-Baker cyst (See Fig.15.68, page 255). In case of swellings containing blood (aneurysm) or pus, this test will be negative.

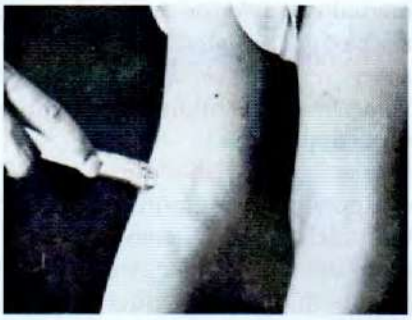

Fig.15.61.— Demonstration of translucency test in an enlarged semimembranosus bursa.

Examine whether the swelling is *compressible* or not. For this uniform gentle pressure is applied over the swelling and the reduction in size of the swelling is noted. This is due to displacement of fluid. This test is positive in case of Morrant-Baker cyst or popliteal aneurysm.

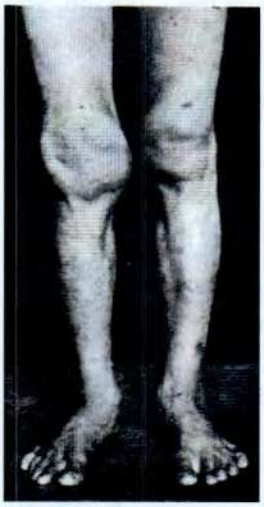

Fig.15.62.— Clutton's joint — bilateral serous syphilitic synovitis of the knee joints.

(3) **Palpation of popliteal fossa.**— It must be remembered that examination of the knee joint is incomplete without examination of the popliteal fossa. The patient lies down prone on the table. The knee joint is flexed and the popliteal fossa is palpated (Fig. 15.63). The knee joint, the popliteal artery, the areolar tissue, the vein and nerves and the tendons in and around the popliteal fossa are all palpated carefully to detect any pathology there.



Fig.15.63.— *It must be remembered that examination of the knee joint is incomplete without examination of popliteal fossa.* Flexion of the knee greatly facilitates palpation of the popliteal fossa.

(4) **Bony components.**— The femoral condyles above the joint and the tibial condyles below the joint are very carefully palpated for any tenderness, irregularity and swelling. The patella is also carefully palpated and crepitus during movement of patella indicates osteoarthritis. Bones are also examined for any pathology or tumour there.

(5) Patients may sometimes point out the presence of a loose body. This should be palpated properly, but X-ray is more informative in this respect.

(6) Lastly the muscles are palpated for evidence of **wasting** or adhesion to the bone.

(7) **Significance of a click.**— Often patients present with a click in the knee joint. If the click is painless, it has hardly any significance. If the click is associated with discomfort or pain, one should carefully examine to detect pathology. The patella is examined, particularly its margins and its mobility — whether this is giving rise to pain to the patients or not. An intra-articular click may simulate extra-articular sounds e.g. the sound of a snapping tendon such as produced by the semitendinosus slipping around and becoming hitched over the

medial condyle, or the tendon of biceps over the head of the fibula,or the edge of the iliotibial tract over the lateral condyle, or any tendon becoming hooked over an exostosis. Such extra-articular sound is a dull thud. The commonest cause of intra-articular click is osteoarthritis. Sometimes in childhood a painless click may occur as the patella moves over the condyle in a normal joint.

(8) **Palpation of the joint.**— The knee joint is comprised of 2 components — patello-femoral component and femoro-tibial component. Often the clinicians forget to examine the patella and the patello-femoral component of the knee joint and thus miss cardinal informations regarding intra-articular pathology and also the pathologies like chondromalacia patellae. Palpate the patella and its margin for tenderness. Next, push the patella medially and laterally. This may produce crepitus in case of chondromalacia patellae. For tibiofemoral component the joint line is thoroughly palpated to detect any tenderness or irregularity or swelling.

MOVEMENTS.— The movements permitted in the knee joint are mainly flexion and extension. Minor degrees of abduction, adduction and rotations may be permitted when the joint is partly flexed. Both active and passive movements should be examined.

Flexion and extension.— Normally the knee can be flexed until the calf touches the back of the thigh and can be extended till the thigh and leg form a straight line.

Abduction and adduction.— These movements are virtually absent with the knee straight, but slight degrees of abduction and adduction are possible when the knee is semiflexed.

Rotation.— This movement is also not possible when the knee is straight. When the hip and knee are flexed to 90° some degree of rotation is possible.

During active or passive movement the palm of one hand is placed over the patella, crepitus will be felt if osteoarthritis has involved the patello-femoral joint. Abnormal passive movement in any direction is possible in Charcot's joint.

MEASUREMENTS.— In any affection of the knee joint there will be wasting of the quadriceps. Though many a time it becomes obvious on inspection, yet measurement of the thigh along its circumference at a level same distance from the anterior superior iliac spine should be considered. Length of the limb is not so important in affection of the knee joint. But the students must remember that a line from the anterior superior iliac spine to the middle of the patella if extended downwards, strikes the medial malleolus. This of course cannot be the fact in case of genu valgum (abnormal abduction of the knee joint) or genu varum (abnormal adduction of the knee joint). In case of genu valgum or knock knee, the degree of deformity can be estimated by the intermalleolar separation present when the inner sides of the knees are kept in apposition.

Lymph nodes.— In arthritis of the knee joint the popliteal group of lymph nodes will be enlarged in the beginning and later on the inguinal group of lymph nodes. The popliteal lymph nodes are not very accessible to the examining fingers and may often be missed. So it is wiser to palpate the inguinal lymph nodes to detect arthritis of the knee joint.

General examination.— In Charcot's joint neurological examination is carried out.

X-Ray Examination.— *Tuberculosis of the knee joint.*— General or localized decalcification of the bones becomes obvious. There may be increased joint space due to effusion. When the articular cartilages are damaged the joint space will be diminished and the joint line becomes irregular. In late cases, a triple deformity with flexion, posterior subluxation and lateral rotation of the tibia becomes evident with practically no joint space in between. In most of the pathologies of the knee joint X-ray fail to show any abnormality, as the cartilaginous pathologies out number the bony pathologies.

In *chondromalacia patellae* the patello-femoral joint space becomes narrowed and tomograms may reveal small patellar cysts. Later on osteoarthritic changes appear. Yet in all affections of the knee joint one should advise X-ray to exclude a minor fracture or loose bodies. Osteochondritis dissecans affecting the medial condyle of the femur becomes very much obvious in X-ray as a dense spot with a clear demarcating margin.

Arthrography with contrast medium (Conray or Urografin) or air is particularly helpful in the knee joint to detect any internal derangement here.

Arthroscopy — is of particular help in diagnosing tear in the meniscus as also chondromalacia patellae.

The students are again reminded that in *every case of pain in the knee joint,* if there is no evidence of pathology in the joint, the *hip joint of that side must be examined thoroughly,* as pain may be referred to the knee from the hip.





Figs.15.64 & 15.65.— Skiagram of a case of tuberculosis of knee joint. See the triple displacement. The backward displacement is seen by drawing dotted line along the posterior surface of the femoral condyles.

DIFFERENTIAL DIAGNOSIS

Acute pyogenic arthritis.— This condition commonly affects the children. The knee becomes swollen, the overlying skin becomes red and warm compared to the opposite side. The joint is kept in flexed position and even a slight movement will be very much painful. The joint is very much tender. The general signs are more or less similar to those of acute arthritis of the hip.

Tuberculosis of the knee.— This is a part of the generalized affection and infection is mainly blood-borne and settles in synovium or in the metaphysis or epiphysis of the femur or the tibia. Limp and aching are early symptoms. Soon there will be a swelling in the joint with a slight flexion deformity. At this stage one or more enlarged lymph nodes in the groin can be felt. Later on stiffness will be obvious. Without antitubercular treatment, cold abscess and sinuses are not uncommon. Muscular wasting will be obvious. In the early stage examination of the aspirated effusion or synovial biopsy will clinch the diagnosis. In the second stage (Arthritis), the patient will complain of 'night pain'. In the last stage 'triple deformity' may be noticed. X-ray findings have already been discussed.

Osteoarthritis of the knee.— This is a disease of old age. The knee and hip joints are very often affected. An old bony injury, a long standing internal derangement, recurrent dislocation of the patella, genu valgum or varum are the predisposing factors.

Pain is the leading symptom, which becomes worse after use. The joint feels stiff after rest and it hurts the patient to 'get going'. Swelling is not uncommon and the joint may 'give way' or be 'locked'. Crepitus may be easily elicited if the clinician puts his hand on the sides of the patella during movement of the knee joint. X-ray shows diminution of the joint space at the pressure areas, osteosclerosis, small cysts near the articular surfaces and osteophytes at the margins of the joints.

Recurrent dislocation of the patella.— There are various causes which may be incriminated for recurrent dislocation of the patella. Of these *anatomical abnormalities* such as genu valgum

and poor development of the ridge on the lateral femoral condyle should be cited first. Of the other causes, weakness of the vastus medialis and lax ligaments may lead to recurrent dislocation of the patella. The most important clinical feature is the "apprehension test", in which the patient resists the manoeuvre of displacing the patella laterally with the knee joint flexed for fear of pain and dislocation of the patella.

Chondromalacia patellae.— This is characterized by fissures and softening of the articular surface of the patella. Not infrequently a "kissing" lesion may be found on the femoral condyle opposite the affected area of the patella. Young adults, especially females, are affected. The main complaint is the pain particularly at the time of climbing the stairs. Occasional swelling is also complained of. The knee tends to give way. True locking is only possible when there is a loose body within the joint. Tenderness at the patellar margin and that the patient complains of pain when the patella is pressed and moved against the femoral condyles are the main diagnostic features. X-ray findings have already been discussed.

Osteochondritis dissecans.— Repeated trauma has been incriminated as the likeliest cause of this condition. Possibly impingement of the spine of the tibia against the femoral condyle is the type of trauma in this condition. Young adult males are mostly affected. The convex lower aspect of the medial femoral condyle is the commonest region, the lateral condyle is the second and the patella is very occasionally affected. Ischaemic necrosis and partial detachment are the main pathological processes. This is the commonest source of the loose bodies in the knee joint in young persons.

This condition sometimes runs in families and may be bilateral. The main complaint is intermittent ache and swelling. The knee becomes unreliable and often gives way. Locking may occur when the ischaemic area has been detached to form a loose body. After an attack of giving way and locking, there may be haemarthrosis. The most pathognomonic sign is the localized tenderness on the medial aspect of the medial femoral condyle. X-ray shows a dense area on the medial condyle of the femur which is separated from the rest of the femur by a clear zone. Later on the fragment may be hinged on one side and projected into the joint on the other side. Still later a loose body will be seen in the joint whose site of origin will be obvious.

Pellegrini-Stieda's disease.— Due to incomplete rupture of the medial collateral ligament calcification near its femoral attachment is the main pathology of this condition. The patient complains of pain on the medial aspect of the joint. On examination there is localized tenderness at the femoral attachment of the ligament and thickening at this region. Full extension of the joint is resisted and is extremely painful. After a year a bony prominence can be felt on the medial aspect of the femoral condyle, but by this time pain has very much subsided. Radiography confirms the diagnosis.

Cysts about the knee.— The clinical features of these swellings are similar to those of cyst anywhere in the body. These can be classified according to their positions.

ANTERIORLY.— (i) *Prepatellar bursitis* (Housemaid's knee) — results from friction between the skin and the patella while cleaning the floor in kneeling posture. This cyst covers the lower half of patella and upper half of the ligamentum patellae, (ii) *Infra patellar bursitis* (Clergyman's knee) also results from repeated kneeling and the bursa lies on the lower half of the ligamentum patellae.

MEDIALLY.— (i) The *bursa anserina* is interposed between the tendons of the sartorius, gracilis and semitendinosus superficially and the medial ligament deep to it. (ii) *Cyst of the medial meniscus* is rarer than its lateral counterpart and the most important finding is that it disappears on acute flexion of the joint and reappears on extension till the knee joint is nearly fully extended.

LATERALLY.— (i) *Cyst of the lateral meniscus* is commoner than that of the medial meniscus. The cyst is quite tense and its tendency towards disappearance on flexion is more or less similar to that of the cyst of the medial meniscus.



Fig.15.67.— Morrant-Baker's cyst affecting the left knee.

POSTERIORLY.— (i) *Semimembranosus bursitis* is the commonest and lies between the medial head of the gastrocnemius and the semimembranosus tendon i.e. slightly more medial and higher than the Baker's cyst. The cyst becomes tense and prominent when the knee is extended and becomes flaccid when the joint is flexed. It hardly communicates with the knee joint. The patient is usually young or middle aged. The skin over the swelling and the knee joint are normal. It fluctuates and transilluminates. (ii) *Morrant Baker's cyst* lies centrally in the popliteal space and is often bilateral. The victims are usually over 40 years of age. It is nothing but a pressure (pulsion) diverticulum of the synovial membrane so that it can be compressed. It also stands out with extension of the knee and tends to disappear with flexion. It is usually secondary to osteoarthritis or rheumatoid arthritis of the knee joint. The swelling is soft and fluctuant, but does not transilluminate due to density of muscles covering it. It is a compressible swelling. Arthritis of the joint is evident by crepitus, limited movement and effusion.

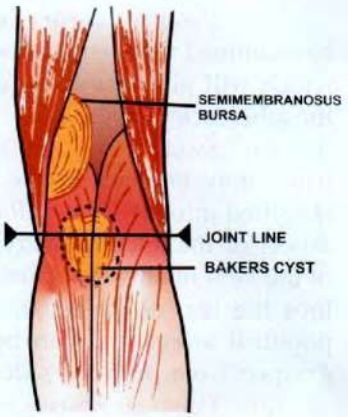

Fig.15.66.— The figure shows typical positions of the semimembranosus bursa and Baker's cyst. Note that the semimembranosus bursa lies above the knee joint line whereas the Baker's cyst lies in or slightly below the joint line.



Fig.15.68.— Morrant Baker's cyst in the left knee. Note that it is being better seen with extended knee.

SWELLINGS IN THE POPLITEAL FOSSA

In the beginning it must be emphasized that examination of the knee joint remains incomplete if the popliteal fossa on the posterior aspect of the knee is not properly examined. The swellings which deserve mention in this region are (i) popliteal aneurysm, (ii) subcutaneous and nerve tumours which may occur anywhere in the body and (iii) the popliteal abscess, (iv) Of course one must remember the different bursae which may be noticed in this region (these are discussed in the earlier section).

(i) **Popliteal aneurysm.**— A swelling in the midline of the popliteal space should always be examined whether it is pulsatile or not. In elderly person popliteal aneurysm is not uncommon which will give rise to an expansile pulsating swelling. One should examine the other arteries for atherosclerotic lesion.

(ii) **Swelling arising from the skin, subcutaneous tissue, popliteal lymph nodes, nerves and bones** may be seen in the popliteal fossa as anywhere in the body. These swellings can be classified into (a) *solid swellings;* (b) *cystic swellings* e.g. in connection with bursae on the posterior aspect of the knee (already been discussed), lymphangiectasis (from lymph vessels), varicosity of the vein mainly the short saphenous etc. and (c) *pulsatile swellings* in which popliteal aneurysm tops the list, of course transmitted pulsation may be present in any swelling lying over the popliteal artery and can be differentiated from an aneurysm by the fact that when they are grasped from both the sides and lifted up from the popliteal artery the pulsation ceases.

(iii) **Popliteal abscess.**— This is an acute condition with redness and brawny oedematous swelling on the posterior aspect of the knee. A careful search should be made in the foot and the same leg for presence of an infected focus, as the commonest cause of a popliteal abscess is infection of the popliteal lymph nodes. Infection of cellular tissue from a small abrasion in that region and acute osteomyelitis of the lower end of the femur or upper end of the tibia are the other causes of inflammatory condition in this region. The knee joint is kept flexed and slightest effort to extend the knee will give rise to tremendous pain. Before making an incision on the abscess one must exclude the presence of popliteal aneurysm otherwise disaster will be imminent.

EXAMINATION OF THE ANKLE AND OTHER JOINTS OF THE FOOT

INSPECTION.— (1) **Attitude.**— In arthritis of ankle joint a position of plantar flexion is assumed.

(2) **Swelling.**— In effusion of the ankle joint there will be fullness on either side of the tendo Achilles and a bulge across the front of the joint. An effusion of the tendon sheath will produce a swelling which extends along the long axis of the leg and foot far beyond the joint-level.

(3) **Muscular wasting** will be obvious in tuberculous affection of the ankle joint.

PALPATION.— (1) One should look for **local temperature** and **tenderness** in arthritis of the ankle joint.

(2) **Swelling.**— Fluctuation between the swelling on either side of the tendo Achilles may be obtained in effusion of the joint. With the other hand an impulse can be felt in front of the joint simultaneously.



Fig.15.69.— Testing the passive movements of the ankle joint. See the text.

(3) Palpation of the **bones** for tenderness and irregularity is important. The two malleoli are the most obvious landmarks in the body. The lateral is less prominent and descends 1 cm lower and behind the medial malleolus.

MOVEMENTS.— The ankle joint, being a hinge joint, permits movements in one plane i.e. dorsiflexion and plantarflexion. In the position of plantarflexion slight rotational rocking movements are possible owing to the narrower posterior part of the talus being then engaged with the tibiofibular mortice. The range of dorsiflexion is about 25° and

that of plantarflexion is 35°. *Inversion and eversion take place at the subtaloid joint and abduction and adduction occur at the midtarsal joints.* The normal ranges of inversion and eversion or abduction and adduction are about 20° from the normal position.

In testing the passive movements of the ankle joint the leg is held with one hand and the foot is grasped with the other hand in such a manner as to include the head of the talus in the grip. This will exclude the possibility of any movement at the subtaloid and the midtarsal joints. In ankylosis of the ankle joint, movements of the subtaloid and midtarsal joints may give a false impression as the movements being occurred at the ankle joint.

The movement at the subtaloid joint can be tested by holding the leg with one hand and everting and inverting the foot by grasping the calcaneous with the other hand. The movements of the midtarsal joint are tested by holding the calcaneous with one hand and adducting and abducting the forefoot with the other hand.

It is always advisable to feel for the popliteal and inguinal groups of lymph nodes.

DIFFERENTIAL DIAGNOSIS

Tuberculosis of the ankle joint.— This is a rare condition. In the early stage the pain is slight, limping is a little and there is some wasting of the calf muscles. When the bones are affected, the pain increases. The patient tends to avoid weight bearing. The flexion and extension, the only movements of the ankle joint are greatly restricted. In the late stage there may be formation of cold abscess and sinus formation. X-ray shows rarefaction of the bone with narrowed joint space with irregularity of the articular surfaces. Primary focus may be detected in the lower end of the tibia or the talus.

Swollen ankle.— This is a very common condition which the general practitioners often confront. Bilateral ankle swelling is mainly due to systemic causes e.g. cardiac or renal insufficiency, endocrine diseases or lymphatic origin.

Unilateral oedema of the ankle is more of a surgical problem and recent bony or ligamentous injury must be excluded first. Instances of phlebothrombosis are not uncommon and Sudeck's atrophy resulting from injury should be borne in mind as a possible cause of this condition.

Tailor's bursa.— On the lateral surface of the lateral malleolus an adventitious bursa may become enlarged rarely in tailors or others who work with sitting cross-legged.

Chronic stenosing tenosynovitis of the peroneal tendon sheath may present itself with tenderness and localized swelling in the course of this tendon below and behind the lateral malleolus. This condition very much mimics the De Quervain's disease. The patient will complain of pain on inversion of the foot.

Chapter

16 EXAMINATION OF HEAD INJURIES

HISTORY.— As the patients with head injuries are frequently unconscious, detailed history of the accident can only be obtained from one who was present during the accident. So only in these cases outsiders should be allowed at the time of taking the history.

1. **Type of accident.**— Elaborate history should be taken regarding the type of accident — whether road accident or fall from a height, whether acceleration injury or deceleration injury during driving a motor car. If injured with a weapon, the type of weapon used should be noted — whether sharp or blunt (lathi). The exact *site* of head injury should be noted.

2. **Level of consciousness.**— When the patient was brought to the hospital, what was his level of consciousness? Was he conscious or semi-conscious or fully unconscious? If the patient is conscious he can give a history of the type of accident occurred, the site of head injury and the sites of other injuries in the body. If the patient is unconscious, a careful history should be taken from the attendant that whether the patient became unconscious as soon as the accident occurred or he was conscious at the time of accident, but became unconscious afterwards. *The time of onset of unconsciousness* should be noted — whether appeared with the accident or a little later. *The duration of unconsciousness* should be noted. When unconsciousness appears immediately after the injury and is maintained, it is primarily due to injury to the brain and may be perpetuated by a secondary cerebral compression (as occurs in subdural haemorrhage). If the patient becomes unconscious with the accident, but regains consciousness for a while (lucid interval) and again becomes comatose, it indicates injury to the middle meningeal vessel (extra-dural haemorrhage). *Lucid interval* is the short period of consciousness between initial unconsciousness which occurs immediately after accident and unconsciousness at later stage after the lucid interval. It must be remembered that if the patient remains conscious following head injury (absence of unconsciousness) does not always exclude a serious head injury.

3. **Post-Traumatic Amnesia (PTA) and Retrograde-Traumatic Amnesia (RTA).**— ***Post-Traumatic Amnesia (PTA)*** is the time between the head injury and return of continuous memory. PTA commonly persists for a while after return of consciousness. This can conveniently be assessed by asking the patient how long he was 'out' since the accident. If it is less than an hour, the injury can be regarded as slight. If it is between 1- 24 hours, the injury is moderate. If it is between 1 to 7 days, the injury is severe and if it is more than 1 week, the injury is almost fatal. So PTA is a good guide to assess the severity of head injury.

Retrograde-Traumatic Amnesia (RTA) means loss of memory for events before the occurrence of the accidents. So far as severity of head injury is concerned, it is less reliable than PTA.

4. **Vomiting.**— Enquire whether the patient vomited since the accident or not. If the patient has vomited, note the usual points including the type of vomitus. If it is blood mixed it may indicate fracture of the middle cranial fossa of the skull. It should be realized that *vomiting is often a sign of recovery* from cerebral concussion. But persistent vomiting may indicate increased intracranial pressure.

5. **Epileptic fits or seizures.**— Patient may have epileptic fits earlier. Epileptic fit however may occur following head injury and its nature may give a clue to localization of the site of trauma. It is usually bilateral in case of haemorrhage from the superior longitudinal sinus. Jacksonian epilepsy (unilateral fit) may be due to middle meningeal haemorrhage. Occasionally convulsive seizure or fit may be the first sign that something more serious than simple concussion is present. It is hardly to be fortunate enough to observe a 'fit'. Usually clinician may have to rely on description given by a relative or a nurse.

6. **Swelling and pain in the head.**— Following head injury the patient may complain of a swelling in the head due to haematoma or fracture of the skull. Pain in the head (headache) is a very common symptom following head injury when the patient is conscious. Ask about the nature of headache. Persistent and localized headache following head injury may be due to a slowly progressive extradural haematoma or subdural haematoma or a post-confusional state.

7. **Other complaints.**— Bleeding with or without watery discharge from ear, nose and mouth indicates injury to the base of the skull. For detailed description see later part of this chapter.

8. **Past history.**— Enquiry must be made whether the patient had fits or similar type of head injury in the past. It should also be noted whether the patient is suffering from high blood pressure, renal disease or diabetes.

9. **Personal history.**— When an unconscious or comatose patient is brought in, the clinician has to decide whether the unconsciousness is the result of head injury or the patient became unconscious due to some other cause (e.g. alcohol, apoplexy, uraemia, diabetic coma, opium poisoning etc.) and then sustained head injury. So enquiry must be made whether the patient is alcoholic or opium addicted or having epileptic fits earlier.

10. **Family history.**— It should be noted that epilepsy, diabetes, hypertension often run in families.

PHYSICAL EXAMINATION

The patient should be completely stripped. If the patient is bleeding from the scalp, this must be immediately controlled since scalp bleeding seldom stops by itself. The vessels of the scalp are prevented from normal contraction by fixation of their walls to the fibrous stroma of the scalp. It must be assured that an *adequate airway* is maintained. If the patient is vomiting, his face should be turned to one side to prevent aspiration of blood or vomitus. Jacksonian epilepsy (unilateral fit) is sometimes seen in cases of middle meningeal haemorrhage. It starts in the fingers or toes, one forearm or leg or one side of the face depending on the site of irritation of the cerebral cortex. In haemorrhage from the superior longitudinal sinus, the fits are usually bilateral. The following points should be carefully noted to come to a diagnosis :

1. **Head.**— The patient must be shaved fully. The area of injury should be examined thoroughly to know if there is any fracture of the skull. If present, the type of fracture should be noted. Depressed fracture is invariably compound in case of adults but may remain simple in case of children. Sometimes a haematoma simulates a depressed fracture owing to its softened centre and hard periphery (due to clotted blood). If an indentation can be produced by applying steady pressure on the rim it is a haematoma. When there is a wound in the scalp its extent and depth are carefully examined. When a wound gapes, it indicates division of the galea aponeurotica.

When a haematoma is present, it is ascertained whether (i) it is confined to an area over one cranial bone and fixed (subpericranial), or (ii) it extends beyond such limits but remains confined within the attachments of the galea aponeurotica (subaponeurotica), or (iii) it is situated superficially and moves with the scalp (subcutaneous).

It must be remembered that a boggy swelling at the temporal region often indicates a fracture affecting the temporal bone which has probably caused extradural haemorrhage from the anterior or the posterior branch of the middle meningeal artery. These cases, even if they remain conscious, should be admitted to the hospital and observed for no less than 24 hours. The cases are on record that these patients, during the lucid period of consciousness, may drink and may be arrested, only to be found dead in the next morning in the cell. The site of injury often gives a valuable indication about the diagnosis of the condition. Injury to the front or back of the head, particularly in an old man, with signs of cerebral compression, should immediately rouse the suspicion of subdural haemorrhage.

2. **Position of the patient.**— Note whether the patient is lying flaccid with his jaw relaxed (a serious condition) or is curled up on his side and resents all interferences (cerebral irritation, a favourable sign).

3. **Depth of unconsciousness.**— It must be assessed by applying pressure on the supraorbital nerve or pushing the angle of the jaw forcibly forwards and noting the facial expression. In complete unconsciousness, the patient cannot be roused by any kind of painful stimuli such as pricking the finger tips. There will be absence of corneal reflex and presence of incontinence of urine and faeces. Level of consciousness is very important. In this respect, vague words like 'semicoma' or 'stupor' should be avoided and simple description of the responses should be noted. Is he oriented with time and place, does he answer the questions accurately or obey the command appropriately? There are different grades in responding to painful stimulus. First grade is to repel the stimulus with coordinated attempt. Second grade is a simple grunt and third grade is reflex decerebrate posturing. A baseline must be drawn so far as the consciousness of the patient is concerned. This will help to find out subsequent changes. Further deterioration of the state of consciousness may be due to cerebral compression.



Fig.16.1.— A case of head injury showing bleeding from the nose indicating probable fracture of the anterior cranial fossa. One can also find ecchymosis and oedema of the eyelids.

4. **Bleeding from the nose, ear or mouth.**— This is a sign of fracture of the base of the skull. It should be remembered that it may be due to laceration of soft tissues concerned. If the bleeding is profuse and the blood is more watery due to dilution with the cerebrospinal fluid or is mixed with brain matter, a diagnosis of fracture becomes unquestionable. *Bleeding from the nose occurs in fracture of the anterior fossa, whereas bleeding from the ear or mouth indicates fracture of the middle cranial fossa.* The importance of this sign lies in the fact that it indicates that the fracture, particularly in the anterior and middle cranial fossa, has become compound. The question of possibility of meningitis comes in. Very occasionally it may so happen that the ear drum remains intact with a middle cranial fossa

fracture in which cases escaping CSF may trickle down the Eustachian tube and present as cerebrospinal rhinorrhoea. Fracture of the middle cranial fossa may give rise to facial palsy and/or deafness.

In fracture of the posterior fossa behind the foramen magnum, a patch of ecchymosis appears within 3 or 4 days near the tip of the mastoid process (Battle's sign). The patient may vomit a quantity of swallowed blood.





Figs.16.2. & 16.3.— Showing signs of fracture of the anterior cranial fossa. The first figure shows subconjunctional haemorrhage and the second figure shows bleeding from the nose.

Fracture of the posterior cranial fossa is more dangerous as the venous sinuses on the occipital bone may be torn. So the coma persists and soon the pupils become dilated and do not react to light. Normal respiratory rhythm is lost culminating in Cheyne-Stokes' respiration. Pulse may be irregular which indicates a lesion in the brain-stem and is more dangerous.

5. Eyes.— In the eyes two things are to be noted — (i) If there is any evidence of haemorrhage in and around the eyes and (ii) the condition of the pupil.

(i) In case of fracture of the anterior cranial fossa, a few signs of haemorrhage will be noted in the eye. Similarly in case of local injury a 'black eye' will be noticed.

In fracture of the anterior cranial fossa, (a) ecchymosis due to extravasated blood is seen later, usually after 24 hours. (b) It appears first in the lower eye-lid due to gravitation and then in the upper. (c) It cannot go beyond the orbital margin due to attachment of the palpebral fascia to the orbital margin. (d) If the conjunctiva is examined, it will be evident that the haemorrhage is sub-conjunctival and does not move with the conjunctiva. (e) This sub-conjunctival haemorrhage will point towards the cornea and its posterior limit cannot be seen as it is coming from the back of the eye. (f) There will be oedema of the conjunctiva. (g) If there is excessive bleeding, the eye-ball will be pushed forwards and will lose its mobility.

In local injury or 'black-eye', (a) the ecchymosis appears early. (b) It may spread beyond the eyes, on to the cheek, forehead or side of the nose. (c) There will be signs of local injury around the orbit. (d) If the conjunctiva is examined, there may be conjunctival haemorrhage which will be moved with the conjunctiva. Its posterior limit will always be seen as it is a superficial haemorrhage.



Fig. 16.4.— Shows the pupillary changes in cerebral compression. See the text.

(ii) The examination of pupils is very important in a case of head injury. In case of *cerebral concussion*, the pupils will be slightly dilated, equal and react to light. In case of *cerebral compression*, Hutchinson's pupils will be seen — (a) In the first stage, the pupil on the side of injury contracts due to irritation of the oculomotor nerve, the pupil of the other side remains normal. (b) In the second stage, the pupil of the injured side becomes dilated due to paralysis of the oculomotor nerve, whilst the pupil of the other side contracts since the nerve of that side becomes irritated. (c) Finally the pupils of both sides become dilated and fixed, not reacting to light. This is a grave sign.

Pin-Point and fixed pupils, pyrexia and paralysis (i.e. three 'P's) are the characteristic features of pontine haemorrhage. If the pupil was dilated when the patient was first seen, the possibility of either injury to the optic nerve or traumatic mydriasis should be considered.

6. **Pulse and blood pressure.**— In case of *cerebral concussion*, the pulse will be rapid, thready and the blood pressure falls down. With the appearance of *cerebral compression*, the pulse becomes slow and bounding and the blood pressure rises. This is an attempt to maintain the essential cerebral circulation. Finally when this compensation fails, the cerebral circulation becomes inadequate, the pulse becomes rapid and the blood pressure falls for the last time. So a rapid pulse in one who is deeply unconscious heralds impending death. In *cerebral contusion*, in the beginning, the pulse will be rapid and when cerebral compression will be added on it, the pulse will be slow and bounding. But in the last stage again the pulse becomes low in volume and rapid. In *cerebral irritation*, an irregular pulse may indicate a serious prognostic sign.

7. **Respiration.**— In *concussion*, respiration becomes slow and shallow. With the advent of *cerebral compression* the respiration becomes slow and deep. Later on Cheyne-Stokes' respiration will indicate grave prognosis. Stertorous breathing in which the lips and cheeks blow in and out with each breathing and there is loud snoring noise (caused by obstruction to airway by the relaxed soft palate and falling back of the tongue) is of grave prognosis as it indicates increasing medullary compression.

8. **Temperature.**— In cerebral concussion and contusion in the initial stage, the temperature remains subnormal. With the appearance of cerebral compression, the temperature may rise upto 100°F. Occasionally a difference of 1° to 2° F of temperature between the two sides of the body may be found, being higher on the paralysed side (Victor Horsley's sign). In pontine haemorrhage a very high pyrexia is expected. In case of intraventricular haemorrhage again a high temperature may be noted.

9. **Presence of neurological deficits.**— It must be noted whether the limbs are paralysed or not. A thorough examination of the whole nervous system should be carried out to know if there is any loss of power or reflexes which may be a localizing sign and indicates the area of cerebral

compression. This is of great importance since Burr-hole will be made at that region to relieve compression.

10. **Rigidity of the neck.**— This is seen in case of irritation of the meninges by blood in subarachnoid haemorrhage. It must be remembered that this is also present in case of fracture-dislocation of the cervical spine. But in the first condition, there will be presence of pyrexia, but in the second condition there will be no fever. This condition must not be confused with decerebrate rigidity which may be noted in case of cerebral contusion or cerebral laceration at the midbrain.

11. **Cranial nerves.**— These should be examined one after the other to know if there is any neurological deficit in one of the nerves. In an unconscious patient only a few of them can be examined. Of these the most important is the third nerve, i.e. the oculomotor nerve. In the early stage of cerebral compression the medial aspect of the temporal lobe presses upon the oculomotor nerve and this becomes irritated causing constriction of the same side of the pupil. Further pressure against the tentorium cerebelli will cause paralysis of this nerve leading to dilatation of the pupil. Different cranial nerves are injured in fracture of the different cranial fossae of the skull. These are discussed under the heading of the 'Injury to the base of the skull' in Differential Diagnosis. Supraorbital nerve is sometimes pressed very hard to know the reaction of the patient. In deeply unconscious patient, he will not react to this pressure.

12. **Other CNS manifestations.**— Jacksonian epilepsy is evident in lesion of the cerebral hemisphere. Ataxia and nystagmus are features of cerebellar lesion and these focus the attention to the posterior fossa. Primary midbrain damage, which may occur from even cerebral compression due to herniation of the medial aspect of the temporal lobe through the hiatus of the tentorium cerebelli and inflict trauma to the contralateral crus of the mid brain, will produce decerebrate rigidity and pupillary dilatation. In case of hemiplegia in unconscious patients, one should look for absent abdominal reflexes, increased knee jerk, biceps jerk, triceps jerk and a positive Babinski's sign on the side of hemiplegia.

GENERAL EXAMINATION

It is extremely important to search for other injuries of the body since an unconscious patient will not indicate their presence. Examine : (1) The **chest** for fracture of the ribs, surgical emphysema, haemothorax and pneumothorax; (2) The **spine,** the **pelvis** and the **limbs** for presence of fracture; (3) The **abdomen** to exclude rupture of any hollow viscus and internal haemorrhage from injury to any solid viscus e.g. the liver, the spleen, etc. So one should look for rigidity, sluggish or absent bowel sound, obliteration of the liver dullness, shifting dullness, presence of extravasation of urine to exclude such injuries.

REPEATED EXAMINATION

It cannot be emphasised too strongly that repeated examination of the patient is essential to know the clinical stage of the patient. In this, the level of unconsciousness must be carefully assessed, as deepening unconsciousness is a very valuable sign of cerebral compression, which requires immediate operation to save the patient from impending danger.

SPECIAL INVESTIGATIONS

Blood.— Blood should be examined for diabetes and grouping and cross-matching.

X-ray pictures are taken to know if there is any fracture of the skull. It should be borne in mind that it is harmful to move the head in different positions for the purpose of taking plates. In

case of middle meningeal haemorrhage it gives useful information by indicating the fracture line crossing the arterial groove. Besides the traditional anteroposterior and lateral views, stereoscopic pictures of the skull are of great value in exact localization of a fracture. In case of depressed fracture skiagram should be taken tangentially to show the amount of depression. One may find air in the subdural space or in the brain substance (aerocele).

Lumbar puncture.— In the beginning, the students are cautioned to carry out this examination very carefully, as in cerebral compression there is always a risk of pressure-cone being formed by the impaction of the medulla into the foramen magnum while draining the cerebrospinal fluid. The pressure of the CSF is measured by means of a manometer. In cerebral compression the pressure will be raised and the fluid will be crystal clear in case of haemorrhages outside the membranes. In case of cerebral contusion or laceration, the fluid will be blood stained and the pressure will be high. The pressure may be normal or low with high protein content in case of chronic subdural haematoma. In serious brain stem lesion the pressure is abnormally low.

Carotid angiography.— This also plays an important role to demonstrate the site of the lesion. The technique consists of an injection of the dye (10 ml of 35 % diodone) into the common carotid artery followed by skiagraphy immediately. Carotid angiography can only be performed when the patient's condition is not so acute as it takes no less than two hours to complete taking pictures. This will indicate the presence of subdural haematoma by displacement of the cortical vessels away from the inner table of the skull. In case of extradural haemorrhage the middle cerebral artery will be displaced inward and the anterior cerebral artery will also be displaced across the middle line. While there is subtemporal haematoma or subcortical bleeding in the temporal lobe, the middle cerebral artery will be displaced upward.

E.E.G. (Electro-Encephalography).— This investigation will show areas of suppressed activity of the cortex due to injury or pressure by haemorrhage.

Echo-encephalography.— This will indicate the presence of haematoma by indicating a shift of the midline structure. It is not of much help in subdural haematoma as half of the cases are bilateral with no midline shift.

Ultrasonography — is also useful in locating the site of haemorrhage.

Brain scan.— This has now occupied a very important position so far as the investigations of the head injury and space occupying lesions are concerned. It has almost replaced the air studies and even arteriography. The head is scanned in a very systemic manner from above downwards in a series of transverse planes. The information is fed to a computer and produces a record in which the brain substance appears grey, the ventricular fluids black and the blood clot or the tumour appears white. This is particularly important in chronic subdural haematoma.

M.R.I. (Magnetic Resonance Imaging).— This has superseded all previous investigations in accuracy. It gives a clear picture of brain injury and injury of the skull, subdural and extradural haematoma.

Ventriculography — is not very often used but may be of value in diagnosing chronic subdural haematoma.

Inspection holes — are often made in the skull to establish the diagnosis in doubtful cases. These holes are placed at points determined by neurological signs and are made with a trephine so that the disc of bone may be replaced if nothing abnormal is found.

CLASSIFICATION OF HEAD INJURIES

1. **Injury to the scalp.**— Mostly this is an open injury whose depth may vary involving various layers of the scalp. When the wound gapes it is obvious that the injury has involved the

galea aponeurotica. Sometimes, though rare, scalp injury may be closed. This may lead to haematoma which may be subcutaneous, subaponeurotic and subpericranial. Osteomyelitis may develop after closed injury following infection of a sub-pericranial blood clot. This is *Pott's Puffy tumour.*

2. **Injury to the vault of the skull.**— This may lead to fracture of the skull and is often associated with wound of the sclap. Fracture of the skull may be broadly classified into two varieties — *simple* fracture i.e. the fracture is not exposed outside through a wound and *compound,* i.e. the fracture is exposed outside through the wound of the scalp. According to the type of the fracture it can be classified into linear, fissure, depressed fracture, comminuted fracture or avulsion fracture.

3. **Injury to base of the skull.**— This may affect either the anterior cranial fossa or middle cranial fossa or posterior cranial fossa.

4. **Injury to the duramater.**— This is often associated with injury to the scalp and skull. The type of fracture of the skull which causes laceration of the duramater is the depressed compound fracture.

5. **Injury to the brain.**— This is by far the most important part so far as head injury is concerned. Of course very little can be done by a surgeon to improve the condition of the patient or treat the patient with such injuries. Mainly three types of injury to the brain are come across in head injury. They are cerebral concussion, cerebral contusion and cerebral laceration. All these injuries to the brain are produced by one mechanism namely displacement and distortion of the cerebral tissues occurring at the moment of impact. Brain is slightly capable of anteroposterior riding movement within the spaces of the cerebrospinal fluid. Blows on the front or back of the head lead to the maximum displacement of the cerebral hemisphere in relation to the brain stem and hypothalamic region. One hemisphere may be distorted in relation to the other with the resulting stretch and strain on the junctional tissues. So this type of injury may inflict trauma to the midbrain and is often very fatal. The different types of injury which have been discussed in the name of cerebral concussion, contusion or laceration may not be limited to the cerebral hemispheres, on the contrary they may involve midbrain, cerebellum or very rarely medulla. When the neurones of the reticular activating system in the midbrain are sufficiently damaged, consciousness is lost. Neuronal damage may be minor and transient and is often followed by recovery. To the contrary the damage may be severe and permanent. The remaining neurones may take over the function of the destroyed ones, which depends upon the quantity of cells remaining, the age of the patient and the previous intellectual capabilities of the patient. So primary brain damage will be followed by a steady improvement towards normality which depends on the amount of normal remaining brain tissue.

Concussion, contusion and laceration of the brain occur directly beneath the blow. The other type of brain injury occurs by mass movement of the cerebral hemispheres allowing shearing forces to be generated within the brain and is focussed mainly to the relatively fixed midbrain. *Contre-coup injury* to the surface of the brain opposite to the side of the blow may be seen in odd cases.

6. **Injury to the blood vessels.**— This is important due to the fact that injury to the blood vessels will cause cerebral compression leading to deterioration in level of consciousness and impending danger of death. The detection and treatment of which will considerably reduce the mortality rate of head injuries. Three types of intracranial haemorrhages are seen — (i) Subcortical, (ii) Extradural and (iii) Subdural.

7. **Escape of cerebrospinal fluid.**— Cerebrospinal fluid may be drained due to open fracture of the anterior and middle cranial fossae through the nose, mouth and ear. From the treatment

point of view the importance of this condition lies in the fact that there remains the chance of intracranial infection from these open injuries, which should be treated prophylactically with high dose of broad spectrum antibiotic. Very rarely CSF may be leaked into the subdural space producing subdural hygroma.

8. **Injury to the cranial nerves.**— Head injury may be associated with the injuries to different cranial nerves, of which the 3rd cranial nerve is the most important as it is involved even by cerebral compression besides direct injury. The different cranial nerves are injured in fracture of the different parts of the base of the skull. This is discussed later in this chapter.

DIFFERENTIAL DIAGNOSIS

INJURY TO THE VAULT OF THE SKULL

Whenever a patient comes with head injury, the patient must be shaved completely and thorough examination of the injury must be made to know if it is associated with the fracture of the skull or not. Fractures of the vaults of the skull are mainly caused by (i) compression of the sphere, (ii) by local indentation and (iii) by tangential injury. When the head is compressed against a hard flat surface, it renders the spherical skull more ovoid and a *linear fracture* starts from the point of maximum convexity through the thin areas of the bone. The fracture line often deflects from the bony buttresses towards the base of the skull. So it must be remembered that many fractures of the base are produced by extension of fissures starting in the vault. Local indentation may produce *closed pond depressed fracture* caused by a large round object in which the scalp may be bruised but remains intact and the skull becomes indented but not indriven so the underlying dura remains intact. There may be bruising of the underlying brain surface but is not penetrated. Local indentation of the skull may also be produced by small round object which produces *compound depressed fracture.* The scalp is lacerated, the fractured bone is depressed and indriven, lacerating both the dura and the subjacent brain. There is immediate risk of infection and a later risk of epilepsy resulting from the contracting fibrous scar of the healing brain. Fracture of the vault of the skull by tangential injury is rare and is caused by tangentially directed violence which may secure a grip on the skull and lift it up producing a *horse-shoe shaped fracture* surrounding the calvarium.

INJURY TO THE BASE OF THE SKULL

(a) **FRACTURE OF THE ANTERIOR CRANIAL FOSSA.**— In this fracture there will be haemorrhage from the nose (epistaxis) and/or escape of cerebrospinal fluid (traumatic rhinorrhoea) and even brain matter through the nose. There will be evidence of haemorrhage in the orbital cavity by the presence of ecchymosis starting in the lower eye-lid and gradually involving the upper eye-lid, subconjunctival haemorrhage the posterior limit of which cannot be seen and excessive haemorrhage will push the eye forwards. The olfactory nerve (first cranial nerve) is frequently torn and unless its fellow of the other side is also damaged, partial anosmia may pass unrecognized. The optic nerve usually escapes injury. The 3rd, 4th, the 1st division of the 5th and 6th cranial nerves may be injured at the sphenoidal fissure. 3rd nerve palsy produces a dilated pupil in a conscious patient.

(b) **FRACTURE OF THE MIDDLE CRANIAL FOSSA.**— Haemorrhage and escape of cranial contents (including CSF and brain matter) may be expected from the ear and mouth only. Occasionally there may be epistaxis when the nasal sinuses are affected. Of the cranial nerves the 7th nerve (facial), the 8th nerve and occasionally the 6th nerve may be injured. Facial nerve

injury will cause paralysis of the facial muscles which may occur late due to compression by blood clot or pressure from fibrous tissue or callus. Injury to the 8th nerve will cause deafness and injury to the 6th nerve will result in internal strabismus.

(c) **FRACTURE OF THE POSTERIOR CRANIAL FOSSA.**— Extravasation of blood may be seen in the suboccipital region producing a swelling at the back of the upper part of the neck and ecchymosis posterior to the mastoid process. The 9th, 10th, and 11th cranial nerves are occasionally injured at the jugular foramen. The 12th nerve usually escapes as it is protected by strong bony buttresses.

INJURY TO THE BRAIN

CEREBRAL CONCUSSION.— This is a temporary physiological paralysis of function without any organic structural damage. The patient becomes unconscious for a short period, followed by complete and perfect recovery. It is a condition of shock and develops immediately after the injury. The pulse becomes rapid and is of low volume. The blood pressure is reduced slightly. The respiration is quick and shallow. The temperature remains subnormal. The muscles become flaccid. A deep or prolonged stupor means something more than pure concussion.

CEREBRAL CONTUSION.— In this condition there will be rupture of white fibres of the brain causing peticheal haemorrhages. Ring haemorrhages are produced by bleeding into the perivascular spaces of Robin-Virchow. Some haemorrhages are also noticed in the corpus callosum in the 3rd ventricle and in the substantia nigra of the brain stem. A low intracranial pressure is noticed. Unconsciousness is more prolonged. The initial recovery is imperfect as degeneration following rupture of axons leads to a post-contusional state associated with defective memory and change of personality. So the patient recovers with confusion, irritability, delirium etc. When the patient remains unconscious, the pulse rate is increased and it is of low volume. The blood pressure is reduced, respiration remains shallow. The muscles remain relaxed. This is followed by recovery when the patient survives. At this stage the respiration becomes deeper, the pulse increases in volume and the face becomes flushed from the previous condition of pallor. The patient complains of headache and photophobia, becomes irritable and often vomits.

CEREBRAL IRRITATION.— It develops about 2 to 3 days after head injury and is mainly caused by cerebral oedema. The patient is not unconscious but takes no interest in the surroundings. He remains curled up with knees drawn up and arms flexed *(an attitude of flexion)* and interference of any kind is resisted. Recovery is apparently complete, but in majority of cases headache, irritability, depression, lack of concentration, defective memory and a change of personality are expected.

CEREBRAL LACERATION.— In this condition the brain surface is torn with effusion of blood into the cerebrospinal fluid leading to subarachnoid haemorrhage. This is mainly caused by injury of the brain surface against bony ridges and the edges of the dural septa. So lacerations are common on the inner aspect of the hemisphere under surface of the frontal lobe and tip of the temporal lobe. These may lead to anosmia and change of personality. Lacerations may occur on the opposite side to the site of impact. This is known as contra-coup injury. Signs and symptoms are more or less similar to those of cerebral contusion.

INJURY TO THE BLOOD VESSELS

Haemorrhage from any intracranial vessel may occur above or below the tentorium cerebelli and will be responsible for causing brain compression. It requires sometime to develop cerebral compression. In this period the patient remains conscious and is typically known as the 'lucid

interval'. Of course this time varies according to the type of the vessel (whether artery or vein) and the calibre of the vessel injured.

The haemorrhage may be *supratentorial* or *infratentorial*. Of these, **SUPRATENTORIAL HAEMORRHAGE** is by far much commoner and includes subcortical haemorrhage, subdural haemorrhage and extradural haemorrhage.

Subcortical haemorrhage is produced by arterial bleeding from an area of surface laceration or from rupture of a central artery. This bleeding becomes fatal when it ruptures into the ventricle causing *intraventricular haemorrhage*, the main symptom of which is hyperthermia. Epileptic fits may be seen with localized paralysis. The symptoms and signs develop from 1 to 10 days time after head injury. Old blood clots in the brain may produce the signs and symptoms which may mimic those of cerebral tumours.

Subdural haemorrhage.— This condition is about 6 times commoner than extradural haemorrhage and is mainly caused by the rupture of the superior cerebral vein within the subdural space. Injury to the front or back of the head, particularly in elderly individuals, may lead to subdural haemorrhage. The cerebral hemispheres move while the superior cerebral veins draining from the cerebral hemispheres to the lower part of the superior sagittal sinus remain fixed (See Fig.31.1 in author's 'A Concise Textbook of Surgery'). About 50% of cases are bilateral. The acute form of this condition produces cerebral compression which is fatal and demands immediate surgical interference. In subacute or chronic varieties, the symptoms are less dramatic and consist of headache which is unduly severe and prolonged, mental apathy, slowness to respond to questions; the patient may go into coma when the midbrain pressure-cone is developed.

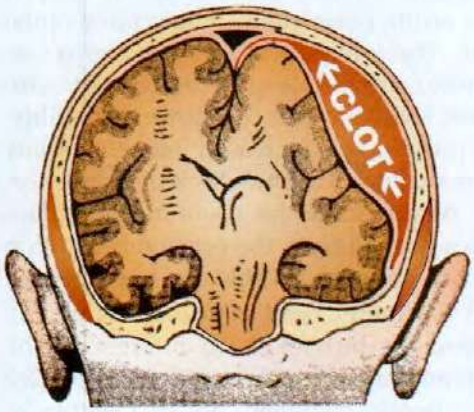

Fig.16.5.— Shows clot at the extradural space in extradural haemorrhage. Middle meningeal haemorrhage usually takes place at the bony tunnel where the artery of the same name enters the skull. The arrow shows how the clot gradually spreads from below upwards involving successively the area for the face, arm and leg.

Extradural Haemorrhage.— The classical syndrome of extradural haemorrhage results from injury to the anterior or posterior branch of the middle meningeal artery. The injury in force is generally a blow from the lateral side which may cause fracture of the temporal bone and injury to the said artery. The anterior branch bleeding is more significant and occurs mostly at a point when it leaves the bony canal at the pterion. Immediately after the injury the patient goes into concussion and then a period of 'lucid interval' during which the haemorrhage collects. The next change is the level of consciousness. The patient becomes confused and irritable. Confusion changes to drowsiness and the haematoma gradually presses on the motor cortex causing twitching which is quickly followed by paralysis of the face, then the arm and then the leg on the opposite side of the body. At this time the temporal lobe is displaced medially and its inner portion presses on the 3rd nerve above the edge of the tentorium causing contraction, rapidly followed by dilatation of the pupil on the side of haemorrhage. Gradually the opposite crus of the brain stem is pressed against the opposite rim of the tentorium (See Fig.31.3 in author's 'A Concise Textbook of Surgery') leading to hemiplegia and this time on the side of the haemorrhage. Finally impaction of the mid-brain cone leads to decerebrate rigidity and fixed dilatation of both the pupils. The side of the middle meningeal

haemorrhage is diagnosed by :

(i) The side of skull fracture; (ii) The side of boggy swelling under the temporal muscle and (iii) The side of the initial dilatation of the pupil.

Extradural haemorrhage can also occur from internal maxillary or anterior meningeal vessels by fracture of the anterior fossa.

Supratentorial haemorrhage produces its effect partly by local pressure on the brain underlying the haematoma, but more importantly by herniation of the uncus of the temporal lobe through the tentorial hiatus causing mid-brain compression. The mid-brain compression leads to (i) deterioration in the level of consciousness by damaging the reticular activating system; (ii) pupillary changes due to the effect of pressure on the oculomotor nerves and lastly (iii) hemiplegia due to compression on the opposite crus of the mid-brain with continuing pressure. *Signs of damage to the pons* may develop, which are (i) elevation of the blood pressure, (ii) slowing of the pulse and (iii) irregular respiration. The cerebral compression as a whole is discussed below :

Cerebral Compression.— The patient after being conscious or irritable for a while, passes into profound unconsciousness. Progressive deterioration in level of unconsciousness is the main feature. The pulse becomes slow and bounding (of high volume). Respiration remains slow and deep, frequently stertorous. The patient's cheeks flap with respiration. His face becomes flushed. The temperature may be unequal, being higher on the paralysed side. The pupil on the side of the lesion dilates after initial contraction with poor reaction to light. In the last stage both the pupils become dilated and fixed without reacting to light.

Cerebral compression mainly results from haemorrhage from intracranial vessels or oedema from local injury to the brain.

INFRATENTORIAL HAEMORRHAGE causes compression to the cerebellum, pons and the medulla. The mid-brain is not initially compressed, therefore consciousness is not impaired. The effects of this haemorrhage are: (i) elevation of blood pressure, (ii) slowing of the pulse, (iii) irregular respiration, (iv) ataxia, (v) nystagmus and (vi) lower cranial nerve palsies. It must be remembered that infratentorial haemorrhage is by far less common than its supratentorial counterpart.

DIFFERENTIATION BETWEEN EXTRADURAL AND SUBDURAL HAEMORRHAGES

1. *Incidence.*— Subdural haemorrhage is about 6 times commoner than extradural haemorrhage.

2. *Onset.*— In extradural haemorrhage signs of compression appear later than those of subdural haemorrhage.

3. *Lucid interval.*— In extradural haemorrhage after a period of initial unconsciousness (stage of cerebral concussion), there will be a stage of consciousness in which the patient behaves normally (lucid interval). During this lucid interval the duramater is slowly stripped off the skull by the accumulating blood, but the intracranial pressure continues to be normal by displacement of the cerebrospinal fluid into the spinal canal. When this compensation fails, intracranial pressure increases and the medial aspect of the temporal lobe herniates through the tentorial hiatus to compress on the mid-brain. This damages the activating reticular system in the brain stem with deterioration in the level of consciousness. Gradually the patient passes into deep coma. In subdural haemorrhage, on the other hand, blood accumulates more quickly and does not allow much time for compensation to take place. Therefore lucid interval is much less or even absent in subdural haemorrhage.

4. *Paralysis.*— In case of haemorrhage from the anterior branch of the middle meningeal

artery, the extradural haematoma will press on the motor cortex from below upwards. This causes paralysis on the other side of the body starting from the face, then the arm, trunk and gradually towards the leg. When the medial aspect of the temporal lobe herniates through the tentorial hiatus by increasing intracranial pressure, the contralateral crus of the midbrain is pressed against the edge of the tentorial hiatus causing hemiplegia of the same side as the lesion. This occurs late in extradural haemorrhage but occurs earlier in cases of unilateral subdural haemorrhage.

5. *X-ray of the skull* — may reveal fracture line in the temporal bone across the groove for middle meningeal vessels in case of extradural haemorrhage. This may not be evident in case of subdural haemorrhage.

6. *Echo-encephalography* will indicate a shift of the midline structures towards the opposite side in case of extradural haemorrhage and unilateral subdural haemorrhage. 50% of the subdural haemorrhage is bilateral. *Brain scan* will also reveal extradural or subdural haemorrhage.

COMPLICATIONS OF HEAD INJURIES

Post traumatic headache, insomnia, infection like osteomyelitis, meningitis, encephalitis etc., post traumatic epilepsy, hydrocephalus, metabolic disorders like uraemia, diabetes insipidus etc., caroticocavernous fistula, fat embolism are the various complications which may occur after head injury.

Of these complications, post traumatic headache and epilepsy deserve special mention. One thing must be remembered that headache may be due to injury to upper cervical vertebrae pressing on the great occipital and posterior auricular nerves supplying the vertex, the temple and the forehead. In this condition the patient will complain of pain during flexion of the cervical spine and tenderness can be revealed at the upper cervical spines.

A type of early post traumatic epilepsy may be seen in the first 24 hours and is mainly caused by bruising and oedema of the brain near the site of injury. True post traumatic epilepsy due to the scar tissue formation in the brain or between the brain and the membranes will take no less than 6 months to develop. Post traumatic epilepsy is mainly Jacksonian type, uncontrollable twitching may affect the thumb or the hand in the beginning. Gradually the muscles of the arm, shoulder or even face will be affected. The convulsion may become generalized. Typical aura may be seen before a generalized fit.

Chapter

17 INVESTIGATION OF INTRACRANIAL SPACE-OCCUPYING LESIONS

Chronic space-occupying lesions include the tumours, chronic haematomas and intracranial abscesses.

HISTORY.—

Age & Sex.— *Medulloblastoma* is a tumour of childhood (between the ages of 5 and 15 years), boys outnumber the girls. *Spongioblastoma polare* usually affects young subjects. *Glioblastoma multiforme* occurs in adult males. *Astrocytomas* occur at any age — in the frontal lobes in adults and at other sites of the hemispheres in young subjects. *Acoustic neurofibroma* is uncommon before the age of 30.

Previous history of trauma.— In presence of history of head injury, one should always consider the possibilities of intracranial abscess and chronic subdural haematoma.

Infected frontal air sinus and otitis media.— Previous history of these conditions should make the surgeon to think in the line of intracranial abscesses. The patient may forget that he once suffered from these conditions.

Complaints.— A chronic space-occupying lesion produces symptoms after an initial period of silent growth. These are of the following types:— Focal or localizing symptoms, symptoms due to raised intracranial pressure and due to cone formation.

(a) **Focal or localizing symptoms are :**

(i) *Epileptic fits* arising for the first time in adults should always be suspected as being due to tumours unless proved otherwise. Tumours commencing in the cerebral hemisphere will produce this symptom. When this symptom is associated with hallucination of taste or smell, the uncinate process is probably involved with the tumour.

(ii) *Attacks of twitching,* paresis and/or loss of sensation commencing in both the feet and lower limbs, subsequently spreading to one side of the body is suggestive of parasagittal meningioma of the opposite side. In cerebellar hemisphere tumours there will be in co-ordination of the corresponding side of the body (deviation to the affected side on walking). Nystagmus may or may not be present in case of such tumours.

(iii) *Mental symptoms* such as change of personality, loss of memory, loss of power of concentration etc. are commonly associated with tumours affecting the frontal lobe.

(b) **Symptoms due to raised intracranial pressure** vary in their appearance according to the situation of the tumour. These symptoms appear earliest in cases of tumours arising from the midline and posterior fossa and later on in temporal and parietal lobe tumours as these tumours partially obstruct the outflow of the CSF from the ventricles and produce internal hydrocephalus. Tumours of the frontal lobe generally push the ventricles back and the symptoms of raised intracranial pressure appear late. Intracranial tumours increase the intracranial pressure due to their own bulk and due to retained ventricular fluid. These symptoms are :

(i) *Headache.*— This is the most constant of all the symptoms in this group. It is most marked in the early morning on getting out of the bed. Of course, in the terminal stage it becomes

continuous and intense. Headache on one side of the head may indicate tumour of that side of the head. Occipital headache with a tendency towards radiation down the neck is commonly encountered in subtentorial growth. Bitemporal headache is often a feature of pituitary tumour.

(ii) *Vomiting.*— This is also mostly experienced in the early morning, usually before breakfast. This type of vomiting is usually not preceded by nausea and may sometimes become aggravated by coughing and straining which increase cerebral congestion.

(iii) *Deamness of vision.*— This is due to papilloedema. It occurs early in the subtentorial growth and growth affecting the inferior aspect of the frontal lobe or temporal lobe.

(iv) *Slow pulse rate* and retarded cerebration with loss of concentration, loss of memory and even stupidity are also features of increased intracranial pressure.

(c) **Symptoms due to cone formation** appear as the last stage of an intracranial tumour when the temporal lobe is forced down through the tentorial hiatus or the cerebellar vermis is pushed up through the same opening or the cerebellar tonsil is forced downward through the foramen magnum. These symptoms are : (i) Drowsiness, (ii) Slow pulse rate, (iii) Neck stiffness, (iv) Paroxysmal headache and (v) Pupillary dilatation.

PHYSICAL EXAMINATION

General appearance.— Gigantism in the lower age group and acromegaly in adults are features of hyperpituitarism. Round face, excess of hair, purple striae are features of basophil adenoma of the pituitary (Cushing's syndrome).

Pulse and blood pressure.— Bradycardia is a common feature of raised intracranial pressure. Tachycardia may be seen in subtentorial growths. Blood pressure, contrary to expectation, is seldom high. In Cushing's syndrome blood pressure becomes raised.

LOCAL EXAMINATION OF THE HEAD

Local examination of the head is not much informatory so far as intracranial tumours are concerned. Occasionally localized tenderness may be present over the underlying tumour, particularly the meningiomas. In meningioma there may be local thickening in scalp with engorged veins. Sometimes a bruit may be heard over the tumour.

EXAMINATION OF THE NERVOUS SYSTEM

A general scheme of examination of the nervous system is set out below. This is not specific for intracranial tumours which may not show any neurological deficit. Special investigations are more helpful in diagnosing intracranial tumours. Examination of the whole nervous system is more carefully taught in the department of medicine. Yet a text book on clinical surgery cannot be made complete without describing in nut shell the points of examination of the nervous system.

1. **Mental State and Intellectual Functions.**— (a) Ascertain if the memory is good or impaired by asking questions about known events in the patient's past history. (b) Next investigate the speech functions. Is the patient right-handed or left-handed ? Speech functions are localized in the left cerebral hemisphere in the right-handed person and vice versa. Test for motor aphasia, i.e. loss of power of speech (without paralysis of muscles of speech); agraphia, i.e. loss of power of writing (without paralysis of muscles of writing); word-deafness, i.e. inability to understand spoken questions as evident by failure to touch the nose or to smile on being asked to do so (when there is no defect of hearing); and word-blindness, i.e. inability to understand written questions (with no defect of vision).

2. Examination of the Cranial Nerves :

Olfactory Nerve.— Can the patient smell? Anosmia or loss of sense of smell is due to meningioma in the olfactory groove or tumour at the base of the frontal lobe. Parosmia or perversion of sense of smell may be present in a lesion of the uncinate gyrus.

Optic Nerve.— The degree of loss of vision is tested by asking the patient to read different letter-types or to count fingers. In suitable cases ophthalmoscopic examination and perimetry for the visual field must be undertaken by an expert. The field of vision can be roughly estimated by asking the patient to gaze straight ahead at a fixed object and then moving a small object, e.g. a white pin head, from the periphery to the centre of the visual field first horizontally and then vertically.

Blindness in one-half of each visual field is known as hemianopia. If it affects the same half of each field, it is called homonymous hemianopia. This occurs in lesions of the optic tract and optic radiation. If the outer half of each field is affected, it is called bitemporal hemianopia, which indicates a chiasmal lesion, e.g. pituitary tumour, suprasellar cyst, etc. Since the pituitary tumour exerts pressure on the chiasma from below, the hemianopia is upper quadrantic at the beginning, whereas in the case of a suprasellar cyst the hemianopia starts as a lower quadrantic defect because the upper aspect of the chiasma is first pressed upon.

Oculomotor, Trochlear and Abducent Nerves.—

(a) Look at the pupils and note their size and shape — whether abnormally dilated (oculomotor paralysis) or contracted (pontine lesion); determine whether they react normally to light and accommodation. The reaction to light is tested by throwing light on to the pupil and the reaction to accommodation, by asking the patient to look first, at some distant object and then at the finger held in front of the eyes. Normally, the pupils contract in each case.

(b) Test the ocular movements.— The patient with his head held fixed is asked to move the eyes in turn to the right, to the left, upwards and downwards as far as possible in each direction. Any limitation of movement is noted. Ask the patient if he has seen double (diplopia) in any direction. Note also if there is squint, ptosis (drooping of the upper eyelid) of nystagmus (involuntary oscillation of the eyeball). Nystagmus indicates a lesion of the cerebellum or the vestibular apparatus. Is there conjugate deviation (i.e. eyes persistently turned towards one side)? If so, note the direction. In lesions of the cerebral hemisphere, the eyes are directed towards the side of a paralytic lesion but away from the side of an irritative lesion. In lesions of the pons, on the other hand, the eyes look towards the irritative lesion and away from the paralytic lesion. In some cerebellar lesions, skew deviation, i.e. one eye looking upwards and the other looking downwards, is often seen.

Oculomotor Nerve Paralysis.— Complete paralysis of this nerve leads to : (i) Ptosis — due to paralysis of the levator palpebrae superioris; (ii) externoinferior squint — due to unopposed action of the external rectus (abducent nerve) and inferior oblique (trochlear nerve); (iii) Inability to move the eye-ball inwards or upwards; (iv) Dilatation of the pupil with loss of light and accommodation reflexes; and (v) Diplopia.

Trochlear Nerve Paralysis.— Downward and outward movement of the eyeball is impaired and diplopia occurs when such movement is attempted.

Abducent Nerve Paralysis.— There is internal squint and inability to move the eye outwards. When such movement is attempted diplopia occurs.

Trigeminal Nerve.—

Motor Function.— (a) Feel the masseter and the temporalis muscles of both sides simultaneously while the patient clinches the teeth. (b) On asking the patient to open his mouth, the jaw will deviate towards the affected side owing to paralysis of the pterygoids.

Sensory Function.— (a) All sensations over the face supplied by the three divisions of the trigeminal nerve will be lost. The sensation of the conjunctiva, nasal mucosa and anterior two-thirds of the tongue will also be lost. The patient should not speak but write down what he tastes.

Reflexes.— Test for the reflex sneezing (by tickling the nasal mucosa) and the corneal reflex. These will be absent if the nerve is paralysed.

Facial Nerve.— Observe that the nasolabial fold and the furrows of the brow are less marked on the affected side. The angle of the mouth is drawn to the sound side.

Motor Function.— (1) Ask the patient to show his teeth when the angle of the mouth will be drawn to the healthy side. (2) Ask the patient to puff out the cheeks, the paralysed side bellows out more than the normal side. (3) Ask the patient to shut his eyes. He will not be able to close the eye on the affected side and on attempting to do so the eyeball will be seen to roll upwards. (4) Ask the patient to move his eyebrows upwards; the paralysis side remains immobile (Figs. 17.1 to 17.4).

In supranuclear paralysis (upper motor neurone lesions) the upper part of the face escapes owing to bilateral cortical representation.

Auditory Nerve.— Test the patient's power of hearing by means of a watch which is gradually brought to the ear with the eyes closed; note the distance at which he can hear. As the power of hearing may be lost due to affections other than involvement of the auditory nerve, Rinne's test should be employed.

Glossopharyngeal Nerve.— Test for the loss of sensation of the posterior third of the tongue and the back of the pharynx with a probe, first on one half, then on the other and note if there is any difference.



Figs. 17.1. to 17.4.— Testing for the facial nerve. The patient is asked (i) to show his teeth, (ii) to puff out the cheeks, (iii) to close his eyes and (iv) wrinkle the forehead. Note that the right side is paralysed.

Vagus Nerve.— Ask the patient to open the mouth, depress the tongue with a spatula and watch the movements of the palate as the patient says 'Aah'. In paralysis, the affected half of the palate will remain immobile.

Accessory Nerve.— The sternomastoid muscle should be tested for paralysis by asking the patient to turn his face to the other side, while resistance is offered to the act by the hand over the chin. The paralysed muscle will not stand out prominently (see 'Examination of the Neck').

Test also for paralysis of the trapezius (see "Examination of Peripheral Nerve Lesions").

Hypoglossal Nerve.— Ask the patient to put out his tongue. In paralysis the tip of the tongue at once points to the paralysed side. The patient is also unable to move the tongue to the other side. In long-standing cases atrophy of the affected half of the tongue becomes evident.

3. Investigation of Motor Functions :

(a) A patient, who can walk and move his upper limbs freely, is not suffering from any gross paralysis. Investigation for paralysis or weakness of different groups of muscles should be made, when necessary, as described under 'Examination of Peripheral Nerve Lesions.'

(b) The degree of coordination of muscular action is next determined : The patient is asked (i) to extend his arm and then to bring his forefinger to the tip of his nose keeping his eyes closed; in the presence of incoordination, he will not be able to do this. (ii) Walking along a straight line is difficult if there is incoordination. (iii) Rapid movements of pronation and supination of the forearm with the elbow at a right angle are either not possible or slow in cases of cerebellar lesions (adiadochokinesia). (iv) The patient is asked to stand with his feet close together and to shut the eyes. Note any tendency to fall (Romberg's sign). (v) The recumbent patient feels difficulty in placing his heel on the opposite knee with his eyes shut, if there is incoordination. Nystagmus is also a sign of incoordination.

(c) Estimate the muscle tone. Wasted and flabby muscles can be easily distinguished from the spastic muscles by noting the amount of resistance offered to passive movements. Rigidity of the neck muscles is present in cerebellar lesions, e.g. medulloblastoma.

(d) Note the presence of involuntary movements, e.g. tics, athetosis, tremor, etc.

4. Investigation of Sensory Functions :

(a) Cutaneous sensations are tested as described under "Examination of Peripheral Nerve Lesions" (Chapter 9).

(b) Joint Sense.— Can the patient, with the eyes carefully shut, say whether the joint is being flexed or extended? Or can he recognize the position in which the joint is finally kept after moving it in several directions?

(c) Absence of stereognostic sense, i.e. failure to recognize the size, shape and form of different objects in common use such as coin, a match box, knife, etc., is significant of lesions of the sensory cortex.

5. Reflexes :

(a) *Plantar Reflex* (S1).— The inner or the outer border of the foot is scratched with a pin. Normally, the great toe is flexed (flexor response) but in lesions of the pyramidal tract and in infants (in whom the tract is not yet myelinated) the great toe will be extended (Babinski's sign).



Fig.17.5.— Shows how to elicit ankle jerk.

(b) *Ankle Jerk* (S1, 2).— The foot is dorsiflexed slightly so as to put the tendo Achillis on the stretch. A gentle stroke on the back of the tendon leads to a momentary contraction of the calf muscles as evidenced by a sharp plantar flexion of the foot (Fig. 17.5).

(c) *Ankle Clonus* (S1, 2).— The patient's knee is slightly flexed and the leg is supported with one hand while the other hand over the sole of the forefoot makes sudden dorsiflexion of the foot. The foot will be set oscillating if slight pressure on the sole is maintained (Fig. 17.6). This is pathognomonic of lesions of pyramidal system.



Fig.17.6.— Shows how to elicit ankle clonus.

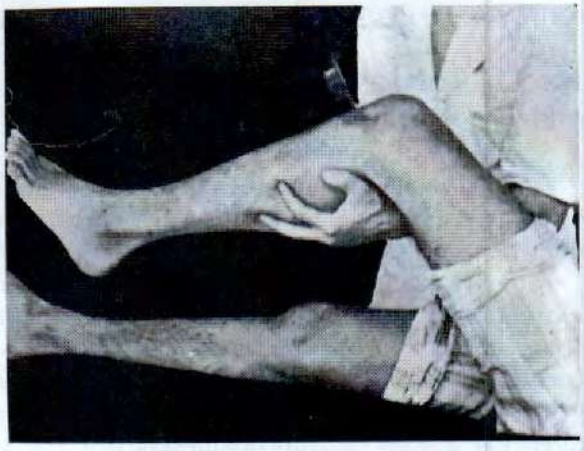

Fig.17.7.— Shows how to elicit knee jerk.

(d) *Patellar Clonus* (L2,3,4).— Keeping the knee straight the patella is suddenly pushed downwards with the clinician's thumb and the index finger from its upper border and the pressure is maintained. When the test is positive there will be clonic movement of the patella due to clonic contraction of the quadriceps.

(e) *Knee Jerk* (L2, 3, 4).— The patient should sit with one knee crossed over the other or if he is unable to sit, the flexed knee is allowed to rest on the clinician's hand. Now a sharp blow on the ligamentum patellae with the edge of the hand or with a percussion hammer will elicit a brisk contraction of the quadriceps, the leg being extended with a jerk. (Fig. 17.7).

(f) *Cremasteric Reflex* (T12).— This is elicited by scratching the skin at the upper and inner part of the thigh when the testis will be drawn upwards.

(g) *Abdominal reflexes* (T7 to 11) are elicited by stroking the abdominal wall parallel to the costal margins and iliac crests and observing the movements of the umbilicus which indicate contraction of the abdominal muscles. These reflexes are abolished in lesions of the pyramidal tract.

(h) *Triceps Jerk* (C7).— A tap just above the olecranon with the elbow flexed will bring about contraction of the triceps.

(i) *Biceps Jerk* (C5, 6).— Grasp the patient's elbow with the left hand so that the thumb rests on the biceps tendon. A tap on the examiner's thumb elicits contraction of the biceps.

It is useful to remember that in lesions of the pyramidal system, all deep or tendon reflexes are exaggerated, sometimes so much that a clonus can be elicited; the superficial or skin reflexes are diminished or absent (e.g. abdominal reflexes) or altered as in plantar reflex (Babinski's sign).

GENERAL EXAMINATION

1. Examine the **ears** and **nose**. Cerebral and Cerebellar abscesses may develop during the course of chronic otitis media.
2. Presence of cutaneous **naevi** on the face often indicates a similar affection in the brain.
3. **Chest.**— The lungs should be thoroughly examined for bronchiectasis, lung abscess, bronchial carcinoma, etc., since dissemination from the lungs into the brain is very common. An enquiry should also be made about haemoptysis, chronic cough and loss of weight.
4. **Abdomen** should also be examined for the presence of a primary growth, since the cerebral lesion may be secondary.

5. **Rectal examination** is necessary with particular attention to the condition of the prostate in the case of males.

SPECIAL INVESTIGATIONS

Besides examination of the **urine** and **blood** (including W.R., urea, N.P.N. and E.S.R.) the following special investigations are essential.

1. **Lumbar Puncture.**— One should not do lumbar puncture in case with papilloedema. This is mainly indicated to exclude non-tumourous conditions.

(a) *Pressure* should be measured by a manometer. Normally, it is about 120 mm of water. Any pressure above 160 mm would mean a raised intracranial pressure. If the pressure is high only a very small quantity of fluid should be drained since there is always the danger of herniation of the temporal lobe through the tentorium cerebelli and of the medulla through the foramen magnum. Although brain tumours are usually associated with increased pressure, yet a normal or even low pressure as measured by lumbar puncture is not unusual.

(b) *The cellular content is* not markedly increased in the majority of cases, but in 10% of cases it is raised. In glioma it is more seen. Generally less than 50 cells are found, but one may find up to 100 cells due to necrosis of malignant glioma close to the ventricle.

(c) *Protein content.*— Considerable increase in protein content is sometimes found in neurofibromas of the auditory nerve and in meningiomas; in the latter condition it may rise up to 500 mg or even more. Normally, the protein content of the cerebrospinal fluid is 20-30 mg percent. Protein content is generally increased in cases of tumours. Site of tumour is important in this respect and intraventricular or paraventricular tumours produce more protein level in CSF. Increase in number of cells and protein content (approximately 80 mg./100 ml.) are seen in acute stage of cerebral abscess. Gradually the number of cells is reduced but the protein content increases to even 120 mg/100 ml.

(d) *Wassermann reaction* of the cerebrospinal fluid should also be tested.

2. **Skiagraphy.**— Straight X-ray films of the skull reveal many facts :

(a) When the *intracranial tension is increased,* note the following points : (i) separation of all the sutures of the vault in children; (ii) hammer markings or 'beaten silver' appearance of the skull (Fig.17.8); (iii) simple dilatation of pituitary fossa with thinning of the posterior clinoid processes.

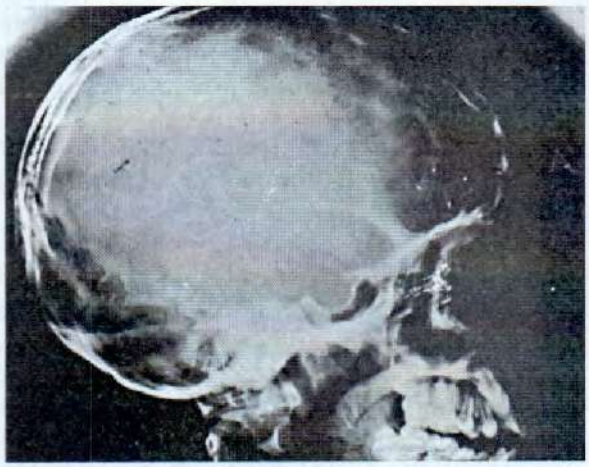

Fig.17.8.— Note the 'beaten silver' appearance of the skull suggesting increased intracranial pressure. Note also the thinning of the posterior clinoid processes.

(b) In *meningioma* (i) The skull shows three types of involvement : erosive, hypertrophic and sclerotic — the first type is frequently encountered in the vault and the last one at the base of the skull, whilst hyperostosis is found in either place: (ii) Enlarged vascular grooves caused by engorged meningeal veins; (iii) Calcification in the tumour.

(c) *Astrocytoma* also shows calcification. About 40% oligodendroglioma calcify.

(d) In *suprasellar cyst,* patchy calcification is characteristic. Widened but shallow sella

turcica with erosion of the clinoid processes is often evident.

(e) *Pituitary adenoma* causes enlargement of the pituitary fossa; the enlargement is great and rarely regular — a fact that differentiates extrapituitary causes of enlargement of the pituitary fossa (internal hydrocephalus, suprasellar cyst).

(f) Displacement of the calcified pineal body — *'pineal shift'* — is indicative of a large tumour in the opposite hemisphere.

(g) Over half of the cases of *craniopharyngioma* and some tuberculomas show *calcification.*

X-ray of the **chest** should be taken for primary focus in the lungs since 30 percent of bronchial carcinoma comes with cerebral symptoms before any chest symptoms.

3. **Ventriculography** is done by passing a brain cannula into each lateral ventricle through a hole bored in the skull 7 cm above the external occipital protuberance and 3 cm from the middle line. The direction of the cannula will be so guided as to aim at the pupil of the same side. The ventricle will be found at a depth of about 5 cm from the surface. 5 ml of fluid is slowly withdrawn and a little less than 5 ml (to allow expansion at body temperature) of air is introduced. Skiagrams are taken immediately after. By means of ventriculography any alteration of the size, shape and position of the ventricular system can be clearly visualized. Myodil ventriculography can be done by pushing 1.5 ml of myodil through anterior horn of the lateral ventricle.

4. **Encephalography** is the skiagraphy taken after replacing the cerebrospinal fluid by air or oxygen through a lumbar or cisternal puncture. First a lumbar puncture is performed and the operation table is tilted to about 45°, so that the head is uppermost, then for every 11 ml of fluid withdrawn 10 ml of oxygen is injected until about 45ml has been introduced. This is immediately followed by skiagraphy. X-ray pictures will show gas in the basal cisternae, over the cortex and in the ventricles. This investigation is dangerous in cerebral tumours and should be reserved for low pressure cases with symptoms of epilepsy.

5. **Carotid angiography** is the skiagraphy taken immediately after the injection of 8-12 ml of 45% Hypaque into the carotid artery. Three lateral films are exposed at intervals of two seconds. This is followed by further injection to obtain anteroposterior vessels. This method is helpful to demonstrate the presence or absence of an aneurysm or of an angiomatous tumour such as a meningioma.

6. **Vertebral angiography.**— 30 ml of 50% Hypaque is used for this. Either retrograde method through the brachial or femoral artery or horizontal approach just above the atlas is made.

7. **Electro-encephalography** (E.E.G.) is a modern method of localizing brain tumour. A cerebral tumour is electrically dead compared with the normal cortex. Tumours produce delta or theta waves on the surface. Occasionally it gives a clue as to which side carotid angiography is to be carried out.

8. **Cerebral Puncture.**— If secondary carcinoma or malignant glioma or cyst is suspected cerebral puncture is very valuable investigation. A burr-hole is made on the site of the cyst or a tumour and aspirating needle or ventricular cannula is introduced into the cyst or the tumour for aspiration. A cyst produced by astrocytoma contains golden yellow coloured fluid. A malignant cyst contains muddy non-clotting fluid. *Meningiomas* provide resistance to the aspirating cannula. After aspiration, air or thorotrast is injected into the cavity in order to produce a picture of the cyst.

9. **Biopsy.**— A sample of the tumour may be obtained by the brain cannula during ventriculography or by means of a special punch such as that designed by Jackson.

10. **Echoencephalography.**— Displacement of the midline structures above the tentorium

can be detected by reflecting the sound waves from both sides of the skull off those structures. A shift of more than 0.5 cm will be revealed by this technique.

11. **Scintillation-encephalography.**— Radioactive iodinated human serum albumin is used for this. On the third day after giving this isotope the scanning is done.

12. **Brain Scan.**— Intracranial tumour and other space-occupying lesions can now be diagnosed with no morbidity by brain scanning with a certainty of 80%-90%. A locally increased concentration of injected radioisotope substance may be found. It can be visualized by an external scanner or camera, which produces a map of the radioactive distribution in the head. Its usefulness is immense and to narrate in short the main points are : (i) detection and localization of primary brain tumours; (ii) detection of cerebral metastases; (iii) differentiation between diffuse and focal inflammatory diseases, i.e. between diffuse meningo-encephalitis and localized brain abscess; (iv) in the assessment of head injury, i.e. differentiation among simple concussion, contusion, extradural and subdural haemorrhages; (v) assessing the effect of carotid stenosis on cerebral blood flow and how it improves after endarterectomy.

In case of brain tumours, arteriography, ventriculography, pneumoencephalography can be used but they are complex and not without morbidity. Electroencephalography is not precise in localizing a brain tumour. Ultrasonic encephalography is more recent and quite safe, but indicates only lateral shift of the midline structure of the anterior half of the cranium. To the contrary radioisotope scanning is simple and free from risk. Even when angiography or ventriculography has revealed the site of lesion, scanning may give additional information which will be of great diagnostic value. The most commonly used isotopes are ^{131}I, ^{99m}Tc, etc. The optimum time for scanning in ^{131}I is about 24 to 48 hours whereas in ^{99m}Tc the optimum time for scanning is about 1 to 3 hours. Brain tumours are demonstrated as areas of increased activity on the scan or camera pictures. Intracranial non-malignant cystic lesions do not show significant uptake. The overall accuracy of detection of brain tumours by scanning varies between 65% to 93%.

13. **CT Scan.**— When available, this has become the major method of diagnosis of intracranial space-occupying lesions. It indicates presence of the tumour with or without ventricular displacement or distension. It is also possible to know the type of the tumour. Meningioma and pituitary adenomas appear dense white, whereas glioma shows variable pattern of enhancement but usually appears less dense. Astrocytoma with cyst formation shows dark shadow. Secondary metastasis appears as multiple shadows. But sometimes exact nature of the tumour cannot be assessed by this investigation.

14. **Magnetic resonance Imaging (MRI) or Nuclear Magnetic Resonance (NMR).**— It presents excellent anatomical details of the brain. It is more sensitive than CT in detecting cerebral space-occupying lesions. It also helps in early detection of cerebral metastasis. For more detail the students are referred to the author's 'A Concise Textbook Of Surgery', in the section of 'Intracranial Tumours', in the chapter of 'The Head'.

CLASSIFICATION OF INTRACRANIAL TUMOURS

This can be best classified under two headings — A. Extracerebral and B. Intracerebral.

A. **EXTRACEREBRAL TUMOURS** may be 1. Meningioma, 2. Acoustic neuroma, 3. Pituitary adenoma, 4. Craniopharyngioma, 5. Teratoma, 6. Cholesteatoma, 7. Pinealoma, 8. Chordoma and 9. Retinoblastoma.

B. **INTRACEREBRAL TUMOURS** may be 1. Glioma, 2. Metastatic carcinoma, 3. Haemangioma, 4. Colloid cyst, 5. Sarcoma and 6. Tuberculoma.

1. **Gliomas (43%).**— They are subdivided according to the stage of development of the glial cells into (a) *Astrocytoma.*— It is benign growth composed of star-shaped adult neuroglial

tissue. It may occur at any age. In children it affects the cerebellum, whereas in adults it affects the frontal lobe most commonly. (b) *Oligodendroglioma.*— It is also an adult cell tumour, the cells having short stunted processes. It affects the deep parts of the cerebrum in adults. (c) *Spongioblastoma Polare.*— It arises from primitive unipolar or bipolar cells. It usually affects the optic chiasma, third ventricle and hypothalamus in young subjects. (d) *Medulloblastoma.*— It is a highly malignant growth and affects the vermis of the cerebellum in children. It grows rapidly and gives rise to seeding metastases throughout the cerebral hemisphere and spinal meninges. (e) *Glioblastoma Multiforme.*— It arises as a result of malignant degeneration in a pre-existing astrocytoma and therefore occurs in the cerebrum of adult males. It contains all varieties of glial cells including giant cells. (f) *Ependymoma.*— It is an uncommon tumour found mostly in fourth ventricle. Age of predilection is 2nd and 3rd decades. These tumours are slow growing and of low malignancy.

2. **Meningiomas (18%).**— These tumours are essentially benign growths originating in the arachnoid villi. According to their situations, they are called *parasagittal,* when occurring along the superior longitudinal sinus; *frontobasal,* when occurring on the cribriform plate, sphenoid wing and tuberculum sellae; and *posterior,* when occurring at the cerebellopontine angle and jugular foramen.

3. **Pituitary Adenoma.**— There are three types : chromophobe, acidophil and basophil. (a) *Chromophobe adenoma* affects usually women between the ages of 20 and 50. Headache and bitemporal hemianopia are the characteristic features. (b) *Acidophil adenoma* gives rise to gigantism in children and acromegaly in adults, owing to excessive production of growth hormone by the acidophil cells and inhibition of basophil sex secretion. (c) *Basophil adenoma* gives rise to Cushing syndrome. Females are mostly affected. There is accumulation of fat on the trunk, neck and face.

4. **Acoustic Neurofibroma.**— It is the most frequent variety of subtentorial tumour occurring in adult life.

5. **Metastatic tumours.**— Commonest primary site is the lung. Breast cancer, adenocarcinoma of kidney, intestinal carcinoma, carcinoma of prostate, neuroblastoma, malignant melanoma etc. are known to metastasise in the brain.

6. **Tuberculoma.**— It is quite common in this country. It occurs usually in children and frequently it is multiple. It affects cerebellum more often than cerebrum. It forms a well defined firm, spherical mass producing signs and symptoms of a tumour.

DIAGNOSIS OF INTRACRANIAL TUMOURS

Clinically, the diagnosis is made by the general and localizing symptoms.

General symptoms due to increased intracranial pressure, are *headache, vomiting, dimness of vision, bradycardia* and *retarded cerebration.* They occur earliest in midline and posterior fossa tumours, early in temporal and parietal lobe tumours, and late in frontal lobe tumours. In a meningioma, their onset may be delayed for several years. *Hence the absence of these symptoms does not exclude an intracranial tumour.*

Localizing syndromes depend upon the site of the tumour.

In frontal lobe tumours, there may be (i) changes in personality, (ii) weakness of the opposite side of the face, and (iii) inability to count correctly due to involvement of Broca's area on the left side in right-handed persons.

In parietal lobe tumours, there are (i) astereognosis, i.e. failure to recognise the size, shape and form of different objects, (ii) exaggerated deep reflexes, (iii) weakness on the opposite side.

In temporal lobe tumours, there may occur (i) aphasia, (ii) hemianopia and (iii) uncinate fit with hallucination of smell in lesions of the uncinate gyrus.

In cerebellar tumours, there are (i) ataxic gait with Romberg's sign, (ii) asthenia with absence of tendon reflexes, (iii) strabismus, (iv) nystagmus, (v) stiffness of the neck etc.

DIAGNOSIS OF INTRACRANIAL ABSCESS

Acute stage presents with pyrexia and persistent headache. In the beginning there will be increased pulse rate, but with the advent of raised intracranial pressure the pulse rate will be gradually slowed down. Headache, irritability, drowsiness and tendency to vomiting are the usual features of this condition. CSF will show increased number of cells and high protein content.

Chronic state will be evident by fall in temperature and pulse rate, but appearance of a few particular physical signs. These physical signs will depend on the location of the abscess. In cerebellum — nystagmus, ataxia, inco-ordination and decreased tone will be evident on the affected side. In temporal lobe — upper motor neurone type of paralysis of the affected side, and in frontal lobe — contralateral facial weakness may be seen. Pallor, cachexia, intermittent headache are the general features accompanied with this condition. If the abscess continues to be enlarged any excess intracranial space will be utilised and gradually the clinical features of increased intracranial pressure will be evident.

Examinations of the ear and sinuses are very essential as intracranial infection often originates from infected condition of these regions.

Chapter

18 EXAMINATION OF SPINAL INJURIES

HISTORY.— The type of spinal injury depends on the severity of the violence. Sudden jolt as may occur in car or bus accident or at the time of lifting weight from bent position may cause injury to the spinal ligaments. Fractures and fracture-dislocation usually result from severe violence e.g. fall from a height or fall of a heavy weight on the back. Diving is shallow water may cause dislocation of the cervical vertebrae. Pure dislocation is not seen in thoracic or lumbar region. Car accident following a sudden break when the seat-belt is fastened may cause injury to the lumbar vertebrae. This is commonly known as 'seat-belt injury'. In civil life most injuries are due to indirect violence and the most common site of lesion is about C6. The second most frequent site is in the region of L1. The thoracic region is seldom involved. If there is paralysis, enquire into the time and mode of its onset. Immediate paralysis is due to compression or crushing of the spinal cord in fracture-dislocation. Paraplegia which has occurred late and is gradually extending upwards may be due to traumatic intra-spinal haemorrhage. Haemorrhage may occur within the cord itself (haematomyelia) or in the extramedullary region (haematorrachis). In the latter condition the blood will escape either into the extradural space or into the cerebrospinal fluid. The patient must be asked whether there is any sense of constriction around the trunk (girdle pain). If present, note its level.

EXAMINATION FOR SPINAL CORD INJURIES

This should be carried out before examination of the spinal column since in presence of cord lesion, patient should be disturbed as little as possible.





Figs.18.1 & 18.2.— Show the attitudes in lesions at the 6th and 7th cervical segments caused by irritation of the 5th and 6th segments respectively. The dotted line in the first figure represents the upper limit of the sensory loss obtained in both the lesions.

UPPER LIMBS.—

Attitude.— According to the level of fracture-dislocation of the cervical region, the upper extremities assume a characteristic attitude. If they lie immobile against the trunk and completely paralysed the level of *injury is at the 5th cervical*

segment, because any severe lesion above this level will cause paralysis of the phrenic nerve and will lead to immediate death. When the *lesion is at the 6th cervical segment* the patient lies helplessly on the back with the arm abducted and externally rotated and the forearm flexed and supinated. The attitude is caused by irritation of the 5th cervical segment which supplies Supraspinatus and Deltoid to cause abduction of the shoulder; Infraspinatus and Teres minor to cause lateral rotation of the shoulder; Biceps causes flexion and supination of forearm. In *lesion of the 7th cervical segment* the arm is partially abducted and internally rotated with the forearm flexed and pronated — possibly due to irritation of the 6th cervical segment which supplies Teres major, anterior fibres of Deltoid and Subscapularis to cause internal rotation of shoulder; Biceps and mainly Brachioradialis to cause midprone flexion of elbow. In case of *lesion of the 8th cervical and 1st dorsal segments* there will be paralysis of the intrinsic muscles of the hand and will lead to a deformity known as 'main-en-griffe'. Any *lesion below the 1st dorsal segment* will not cause any impairment of the movement of the upper extremities upto the finger tips.

Sensation.— Sensation of various parts of the upper limb is tested by pin prick, a wisp of cotton, a test tube with cold or hot water or with reverse of a tuning fork. Loss of sensation will be according to the level of cord lesion. There is a zone of hyperaesthesia between the normal and anaesthetic skin.

Muscle power.— This is tested of various muscles against resistance. According to the level of cord lesion, various muscles of the upper limb will lose power.

LOWER LIMBS.—

Attitude.— The whole of the lower limb will lie helplessly paralysed when the level of the spinal cord injury is at or above 10th thoracic vertebra. When the injury is below the 1st lumbar vertebra only the cauda equina will be injured and the lower limb below the knee will be affected and will lie flaccid paralysed.

Muscle Power.— If the patient walks about, it may be assumed that there is no injury to the cord. In the supine position the patient is asked to move his ankles and toes against resistance. The patient is also asked to raise the legs one after the other. By this one can assess the muscle power of the lower limb muscles. Similarly the patient is asked to move the upper limb against resistance.

Sensation.— This is tested by pin prick, a wisp of cotton or a test tube with hot or cold water. Loss of sensation will be according to the level of cord lesion or injury to the cauda equina. Run the point of a pin from anaesthetic to the normal area and note if there is a zone of hyperaesthesia intervening. In cauda equina lesion, the sacral roots may be involved producing anaesthesia in the back of the legs and a saddle area of the perineum with urinary retention.

Reflexes.— Initially all the reflexes may be lost during the stage of spinal shock. Gradually the reflexes reappear according to the level of the lesion. The time laps between disappearance and reappearance of the reflexes depends on the severity of the cord lesion. In severe cases it may take as long as 3 weeks for the return of reflexes. If the reflexes fail to return by this time complete transverse section of the cord may be suspected. The bladder centre is situated at the lumbar enlargement representing the 2nd to the 4th sacral segments. This centre is concerned in supplying the detrusor muscle of the bladder and injury to this level of cord will lead to paralysis of the detrusor muscle resulting in overflow incontinence. The patient however retains the nerve supply of the abdominal muscles which may be contracted voluntarily at a time interval to evacuate the bladder. This process may be assisted by suprapubic compression with the help of the patient's both hands. In case of lesion of the spinal cord above the lumbar enlargement, after an initial phase of retention due to spinal shock, the bladder reflexes reappear and become

uninhibited by the superior control resulting in an automatic bladder i.e. the bladder evacuates by itself as soon as the intravesical pressure rises to a certain extent. The patient has to wear a receptacle in these cases.

Note the nature of the **respiration.** It is abdominal in lesion above T_2 due to paralysis of the intercostal muscles.

Look for the **distended bladder, incontinence of urine** and **priapism** (persistent erection of the penis).

In long standing cases one may expect presence of **trophic ulcer** — bed sores over the pressure points.

EXAMINATION OF THE SPINAL COLUMN

When the patient is brought in with paralysis, utmost care has to be exerted during the examination of the spinal column. If the patient is rotated, the unstable fracture may increase damage to the spinal cord. Even without paralysis these cases should be handled with extreme care. The patient may be lifted by an assistant just sufficiently to permit the surgeon's hand to be introduced under the site of the lesion. The patient may be examined in a better way if he is very carefully turned by at least two, preferably by three persons on to one side.

Only in cases when the surgeon is absolutely confident that the patient does not suffer from any unstable injury to the spinal column that the patient may be examined in standing or sitting posture.

Inspection.— At first the skin of the back is inspected for presence of any abrasion or bruising to indicate the probable level of injury. One should also look for a swelling, which may indicate a haematoma or a prominent spinous process due to fracture-dislocation.

Palpation.— First of all the spinal column is palpated by running a finger along the spinous processes and transverse processes. *Holdswath test* is performed by running a finger along the spinous processes. Abnormal gap in the line of the spinous processes indicates tear in the interspinous ligament which indicates unstable fracture. Abnormal prominence of a spinous process indicates fracture-dislocation of the spine, the most prominent spinous process is the one below the displaced vertebra. But in compression fracture the most prominent spine is the one above the crushed vertebra. Swelling in this region usually indicates a haematoma which will elicit fluctuation.



Fig.18.3.— Shows how to examine for tenderness of the corresponding spinous process in injury to the vertebral column.

Pressure is exerted along the line of the spinous processes of the vertebrae with the thumb of the clinician. In case of sprain of the spinal column, there will be localized tenderness at the site of the ligamentous injury. If the muscle fibres are torn similar tender spot can be elicited. In fracture of the vertebra, however minor, will produce tenderness when pressure is exerted on the corresponding spinous process.

Sometimes abnormal mobility may be elicited which should not be routinely looked for as it may increase injury to the spinal cord.

Percussion — gently with finger tip over the spinous processes will elicit tenderness if there is fracture of the spinal column.

Movements of the spinal column are *not* tested at this stage until and unless the clinician is

sure that the patient is not having any fracture of the spinal column which may cause injury to the spinal cord due to such movement.

Rectal examination will help in detecting fracture of the coccyx.

GENERAL EXAMINATION

In case of spinal injury the patient must be examined generally to exclude any other associated injury. In this group the most important is the **abdominal injury** which is more fatal and requires immediate surgical intervention. Next comes the **head injury.** A careful watch must be made all throughout the scalp along with palpation to exclude such injury. Next comes the **thoracic injury.** Transverse pressure towards the midline from both sides of the thoracic cage will elicit tenderness if there is any fracture of the rib of sternum. To exclude sternal fracture the clinician should press along the sternum from above downwards for its whole extent, which is often missed. **Injury to the pelvis** is excluded by a transverse pressure on both the iliac crests with both hands towards the midline (See Fig.13.32). Fracture of the ilium will show tenderness. Lastly one should exclude any **injury to the limb** which may be associated with such type of injury.



Fig.18.4.— Wedge or compression fracture following flexion injury. Note that there is no narrowing of the intervertebral space above and below the affected vertebra.

SPECIAL INVESTIGATIONS

X-RAY EXAMINATION.— Two views antero-posterior and lateral must always be taken and compare the depths of the vertebrae. Slight diminution of the depth of one vertebra as seen in the lateral view is the only finding in wedge or compression fracture and may be easily overlooked. It may be emphasized here that there will be no narrowing of the intervertebral space (Fig.18.4) (cf. Pott's disease, see Fig. 19.30 page 299). In case of fracture-dislocation the line of the posterior surfaces of the bodies of the vertebrae is noted. If any vertebra has encroached on the spinal canal that vertebra is supposed to be fracture-dislocated. A fracture of the transverse process of the vertebra is best seen in the antero-posterior view.

DIAGNOSIS

FRACTURES OF THE SPINE.— As fracture of the spine is often associated with damage to the spinal cord, the fracture of the spine is best classified into *stable* and *unstable* fractures, STABLE fractures are those which are not associated with cord damage and movement of the spine is safe. Whereas UNSTABLE fractures are either associated with cord damage or if not, movement of the spine can damage the spinal cord.

Stability does not depend on the fracture itself only, but on the integrity of the ligaments, particularly the posterior ligament complex, being formed by the supraspinous, interspinous ligaments, the capsules of the facet joints and possibly the ligamentum flavum.

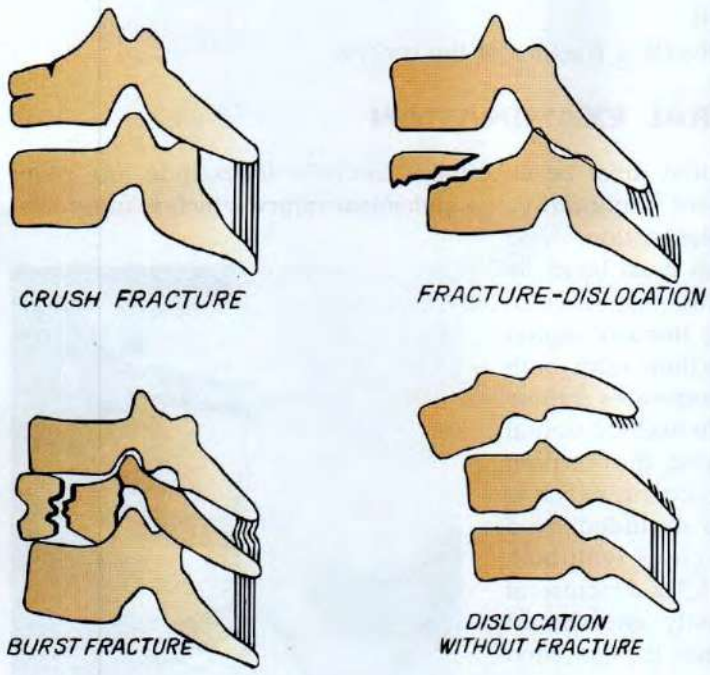

Fig.18.5.— Diagrammatic representation of various types of fractures of the spine.

Burst fracture.— Here the compression force acts on the straight position of the spine. The body of the vertebra fractures vertically. This is a stable injury.

Backward hinge (Extension injury).— In the cervical region it may fracture atlas or axis, anterior ligaments may tear. This is also stable injury. In the lumbar region it may result in fractured lamina. Young toddler, who falls on his buttock, may sustain such an injury and may be the starting point of spondylolisthesis.

Forward hinge (Flexion injury) — is common in lumbar vertebrae. The posterior ligaments will remain intact but the body of the vertebra crumples. This is stable. These injuries are rare in the neck as the chin touches the sternum before any fracture occurs.

Shearing force — causes instability. Rotation causes ligamentous damage. Usually rotation is associated with flexion. A slice of bone may be sheared off the top of one vertebra and the posterior facet is fractured.

Fractures of the spinous processes, transverse processes and laminae are grouped under the nomenclature of *'incomplete fractures'*. These are mostly due to direct violence. Spinous processes are most liable to fracture in the dorsal region, and Shoveller's fracture of the 7th cervical spine is really a stress fracture. Transverse processes are most prone to be fractured in the lumbar region as they are longer and rather unprotected.

Dislocation of the spine.— A dislocation without fracture occurs mostly in the cervical region. The oblique and vertical directions of the articular processes in the thoracic and lumbar regions, respectively, will not allow dislocation without a fracture. Barring dislocation following hanging, which occurs between the atlas and axis, dislocation of the cervical spine usually occurs between the 4th and 5th or 5th and 6th, caused by acute flexion resulting from fall on the head. In unilateral cases, the head is deviated to the opposite side with severe pain referred along the corresponding nerve root which is nipped in the intervertebral foramen. In the lumbar spine a comparable mechanism occurs in the so called 'seat-belt fracture', where following a car accident the body is thrown forward against the seat belt. The posterior ligaments are torn but there may be no fracture. The spine however is angulated and the upper facet may leap-frog over the lower.

Injury to the cord.— Typically four types of injury to the cord may be seen :

(a) **Cord concussion (shock).**— The disturbance is one of function without any demonstrable and anatomical lesion. Motor paralysis (flaccid), sensory loss and visceral paralysis — all occur below the level of the injury to the cord. Recovery begins within 6 hours and it is always complete.

(b) **Complete contusion of the Cord.**— This condition is produced by nipping of the cord between the lamina of the displaced vertebra above and the edge of the fractured vertebra below. It causes transverse contusion, above and below of which there will be minute peticheal haemorrhage. Immediately after injury there will be a stage of spinal shock. After this period, the cord below the transection recovers from the shock and acts as an independent structure. The plantar reflex becomes extensor, the anal and bladder reflexes return. The tendon reflexes will be exaggerated with presence of the clonus. Flexor spasms may develop and sensation never returns. There will be retention of urine and the bladder becomes 'automatic'.

(c) **Root transection.**— It occurs due to injury of the nerve roots. There will be motor paralysis, sensory loss and visceral paralysis along the distribution of the damaged roots. Root transection differs from cord transection in two ways : (i) Residual Motor paralysis is always flaccid in nature and (ii) Regeneration is theoretically possible (being peripheral nervous system). Cauda equina injury comes under this category.

(d) **Traumatic intra-spinal haemorrhage.**— Haemorrhage may occur either within the cord itself (haematomyelia) or in the extramedullary region (haematorrachis). In the latter condition blood escapes either into the extradural space or into the cerebrospinal fluid. Intradural haemorrhage leads to paralysis without causing prior spinal irritation. But in extramedullary haemorrhage there will be spinal irritation, hyperaesthesia, pain etc., which will precede paraplegia due to progressive compression of the cord from below upwards.

Chapter

19 EXAMINATION OF SPINAL ABNORMALITIES

HISTORY.— 1. **Age.**— Spina bifida is seen in new born babies. Spina bifida occulta may present late till adolescent or adult stage. It may be revealed accidentally later in life during X-ray examination for some other reason. Pott's disease is more often seen among children. Disc prolapse is seen commonly in middle aged persons. Idiopathic spondylolisthesis is commonly seen in individuals of 4th and 5th decades of life. Ankylosing spondylitis is a disease of young adult affecting usually individuals between the ages of 15 and 35 years. Majority of the primary carcinomas of the vertebral column occur in children and young adults, whereas secondary deposits in the vertebral column are common in aged people above 40 years of age.

2. **Sex.**— Ankylosing spondylitis, prolapsed intervertebral disc and osteoarthritis are common in males. Psychogenic backache, osteomalacia and ligamentous strain are more common in females.

3. **Trauma.**— An enquiry must be made whether trauma initiated the presenting complaints or it aggravates these. Very often the patient complains that while raising a weight from the floor he suddenly experienced a strain or catch or bursting pain in the spine. This history itself is very suggestive of lumbar disc prolapse.

4. **Pain.**— This is in fact the commonest symptom of spinal column abnormalities. An enquiry must be made about onset, exact site, its nature, any radiation or presence of any referred pain. Dull and continuous pain is a feature of inflammatory lesion of the spine which will be aggravated by movement. A sudden sharp pain may be complained of in case of prolapse of the intervertebral disc during lifting weight in the stooping position. In majority of pathological lesions of the spine movement aggravates the pain.

(a) *Site.*— While taking history, ask the patient to point out from where actually the backache started — in the cervical region, or in the dorsal region, in the lumbodorsal region or in the lumbar region, in the lumbosacral region or in the sacral region.

(b) *Mode of onset.*— Whether the pain started immediately after trauma or lifting weight or during strenuous exercises as seen in prolapsed intervertebral disc or whether the pain appears late only after the pathology is well established e.g. tuberculosis of the spine.

(c) *Nature of pain.*— Pain is sharp stabbing or of shooting in nature in case of prolapse of the intervertebral disc. It is of continuous and throbbing type in case of acute osteomyelitis. Pain is usually intermittent and dull, which gets worse after exercises in case of spondylolisthesis. Pain comes on suddenly and is very severe while the patient bends back in case of fibrositis or lumbago. Pain is usually mild in nature but is aggravated by movement of the spine in case of secondary carcinoma of the spine. It must be remembered that such pain is increased with the increase in intradural pressure e.g. coughing, sneezing or defaecation. Pain is of dull ache character in Pott's disease (spinal tuberculosis). In thoracolumbar tuberculous disease one may experience 'girdle pain'. Pain increases at night, which is known as 'night cry'. Pain of ankylosing spondylitis is usually intermittent and is mainly experienced

on getting up in the morning. This is often accompanied with stiffness of the spine.

(d) *Radiation.*— In majority of pathological conditions of the spinal column pain usually radiates along the course of the spinal nerves. A careful history must be taken about the precise nature of such radiation. In case of prolapsed intervertebral disc pain radiates along the root of the nerve affected. In case of spondylolisthesis sciatic pain along one or both lower limbs is sometimes complained of. In case of extramedullary tumours e.g. neurofibromas affecting posterior nerve roots, pain radiates along the nerve roots. In caries (tuberculosis) of the cervical spine pain is often referred over the occiput and to the arms. In caries of the thoracic spine, the pain is referred along the distribution of intercostal nerve. In case of caries of the lower lumbar region pain may be referred to the hip and legs. In thoracolumbar caries one may experience 'girdle pain' or epigastric pain. In ankylosing spondylitis pain is sometimes complained of along the distribution of the sciatic nerve (sciatica), but the peculiarity is that it alternates from one side to the other.

(e) *Aggravating factors.*— As mentioned above in majority of pathological lesions of the spine, movement aggravates the pain. In case of secondary carcinoma of the vertebral body, increase in intradural pressure e.g. coughing, sneezing or defaecation will cause increase in pain. In the initial stage of tuberculosis of spine the pain is of dull ache character, which gets worse during standing or jolting. In spondylolisthesis pain is usually intermittent and of dull ache nature which gets worse after exercise.

(f) *Relieving factors.*— In majority of spinal column pathologies pain is usually relieved by rest.

5. **Deformity.**— In a number of cases of spinal pathologies patients present with deformity of the spine. A swelling is seen in meningocele. In spina bifida occulta there may be a dimple or a tuft of hair or dilated vessels or fibrofatty tumour or a naevolipoma over the bony deficiency in the lumbosacral region. Scoliosis or kyphosis or lordosis is often noticed in pathologies of spine. These are discussed later in this chapter in the section of 'Differential Diagnosis'. A typical deformity is also seen in case of spondylolisthesis in which the sacrum becomes unduly prominent with deep transverse furrows seen on both sides of the trunk between the ribs and iliac crests (See Figs. 19.4 & 19.5).

6. **Stiffness of the back.**— This is occasionally complained of alongwith pain and definitely the latter symptom predominates. Only in ankylosing spondylitis stiffness of back is a prominent symptom, though this is sometimes complained of in cases of tuberculosis of the spine.

7. **Other symptoms.**— Enquiry must be made if there is any complaint of the abdomen or gynaecological problem or genitourinary problem or vascular disorders. These conditions may give rise to low back pain.

8. **Family history.**— Tuberculosis of the spine and ankylosing spondylitis sometime run in families. Even prolapsed intervertebral disc has been seen to involve more than one member in a family. So family history is important.

GENERAL SURVEY

The victims of tuberculosis of the spine are usually from low social class with malnutrition, anaemia and sometimes cachexia. In case of secondary carcinoma of the spine, patients often give history of quick loss of weight in near past. Spondylolisthesis is often seen among over weight individuals. In ankylosing spondylitis malaise, fatigue and loss of weight are often complained of.

Fever or rise of temperature is mainly come across in inflammatory conditions of the spine. Rise in night temperature is noticed in tuberculosis of the spine.

LOCAL EXAMINATION



Fig.19.1.— The attitude in caries on the dorsolumbar region. The arrow shows the gibbus.

A. **INSPECTION.**— For proper inspection exposure of the entire posterior aspect of the patient from head to foot is required, even the shoes are removed to avoid the effect of high heel. The arms should hang by the side.

1. **Attitude and deformity.**— In caries of the cervical spine the child often supports his head with both the hands under the chin and twists his whole body in order to look sideways. Later on the position of the head becomes similar to that in torticollis. In tuberculosis of the dorsolumbar region there will be a prominent gibbus and the spinal column becomes kyphosed. Its level must be determined.



Fig.19.2.— Scoliosis with convexity to the right side. The spinous processes are marked with dots. Note that the scapula of the right side is elevated.

The back of the patient is carefully observed. Starting from above note :— (i) Position of the head, whether bent or twisted to one side; (ii) the level of the shoulders; (iii) the position of the scapulae, whether one is elevated or displaced forward, backward, laterally or medially; (iv) the lateral margins of the body from axilla to the crest of the ilium — whether the affected side is flatter or more curved than the other; (v) the relative prominence of the iliac crest, e.g. spondylolisthesis; (vi) the curvature of the spine, whether there is kyphosis i.e. forward bending; lordosis i.e. backward bending; or scoliosis i.e. side-bending with rotational deformity. In each case the level of deformity is always estimated.

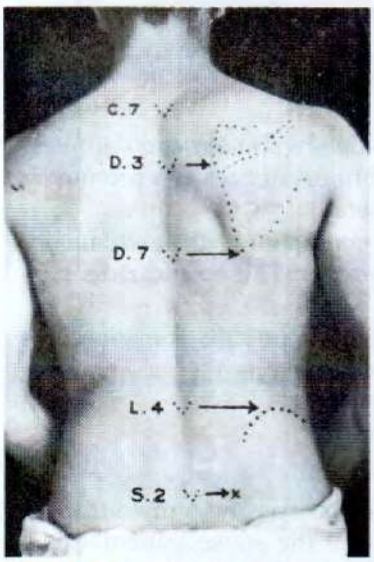

Fig.19.3.— Shows the landmarks which help to ascertain the various levels of the spine.

In case of *scoliosis*, ascertain the side of primary curve. To determine, the spinous processes are marked out with a skin pencil. It should be remembered that the bodies of the vertebrae are rotated towards the convexity of the curve and the spinous processes are rotated towards the concavity. Differentiation should immediately be made between mobile scoliosis (transient) and fixed scoliosis (structural). In case of scoliosis if the patient is asked to lean forward, postural scoliosis will disappear whereas structural scoliosis will be more prominent. In case of compensatory scoliosis, mostly due to short lower limb the patient is asked to sit down and this scoliosis disappears.

In case of *kyphosis* the type of deformity must be noted — whether of the "knuckle" type i.e. one spinous process becomes prominent indicating collapse of one vertebra as occurs in tuberculosis; or "angular" resulting from collapse of two or three vertebral bodies as occurs in late cases of tuberculosis and secondary carcinoma; or "round" where several vertebrae are affected as occurs in Scheuermann's disease and in senile kyphosis. It must be remembered that in kyphosis age of the patient is very important in determining the underlying disease (See differential diagnosis).

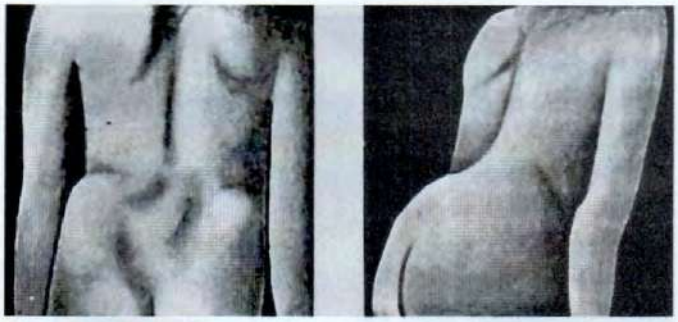

Figs.19.4 & 19.5.— Spondylolisthesis — showing a transverse furrow just above the iliac crest. Note that the upper edge of the sacrum is prominent.

Lordosis is mostly compensatory and may be due to flexion deformity of the hip, bilateral congenital dislocation of the hip or rarely due to kyphosis of the dorsal region.

In *spondylolisthesis*, a transverse furrow is seen encircling the body between the costal margin and the iliac crest with diminution of this space. The upper angle of the sacrum forms a distinct prominence with a depression just above it (Figs. 19.4 & 19.5).

Now the front of the patient is carefully observed. In scoliosis, the chest diagonally opposite to posterior convexity is more prominent. In advanced kyphosis, the sternum also becomes convex anteriorly to compensate for the diminished vertebral measurement of the thorax. The ribs are crowded together. The anterior superior iliac spines are noted whether they are in same level or not.



Fig.19.6.— A lipoma in spina bifida occulta.

2. **Gait.**— As soon as the patient enters the clinic one can come to a diagnosis by just looking at the gait. In caries of the spine the patient walks with short step and often on the toes to avoid jerking on the spine. In case of sciatica the patient accounts the typical gait. In case of sacro-iliac arthritis the patient may limp and if this condition is



Fig.19.7.— Gentle blows are made on either side of the spine to elicit tenderness.



Fig.19.8.— An attempt is being made to rotate the vertebra by pressing on the side of the spinous process. This will elicit tenderness in pathologies of the spinal column.



Fig.19.9.— Cold abscess at the lateral thoracic wall in Pott's disease.



Fig.19.10.— Cold abscess at the lower lumbar triangle (Petit's triangle) in Pott's disease. Fluctuation test is being performed.

bilateral a 'waddling gait' may be seen.

3. **Swelling.**— In spina bifida, a meningocele may be present in the sacral or in the occipital region. If this is detected one should look for talipes (See Fig. 21.1) which may be associated with it. In spina bifida occulta, there may be a swelling, a tuft of hair, dilated vessels, a fibrofatty tumour or even a dimple to show the point of attachment of membrana reuniens to the skin. Congenital sacrococcygeal teratoma is occasionally seen in the sacrococcygeal region. In Pott's disease abscess may be seen in various places — paravertebral abscess, psoas abscess, behind the sternomastoid muscle, abscess on the lateral chest wall following the lateral cutaneous nerve, at the Petit's triangle, abscess in the buttock etc.

4. **Paraplegia.**— In caries of the thoracic region the patient may present with paraplegia which is quite obvious on inspection.

B. **PALPATION.**—

This is carried out in the standing and prone positions :

1. **Tenderness.**— A thumb may be pressed along the spinous processes from above downwards along its whole extent. Note the level of maximum tenderness. Tenderness may be elicited by pressing upon the side of the spinous process in an attempt to rotate the vertebra (Fig. 19.8). This can also



Fig.19.11.— Method of eliciting tenderness by percussing on the spinous processes with a finger in case of pathology of the vertebrae.

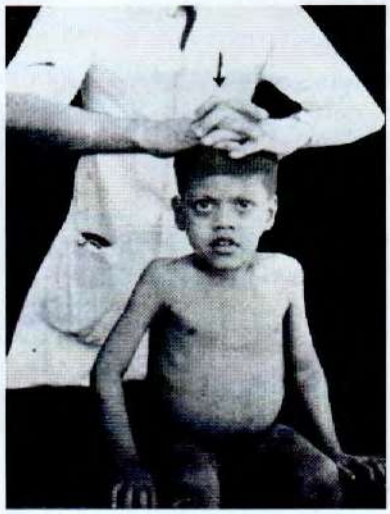

Fig.19.12.— Anvil test. See the text.

be elicited by applying gentle blows on either side of the spine (Fig. 19.7). Tenderness can also be elicited by percussing on the spinous processes with a finger (See Fig. 19.11). An exquisitely tender area may indicate torn muscle fibre or ligamentous tear. It must be remembered that at

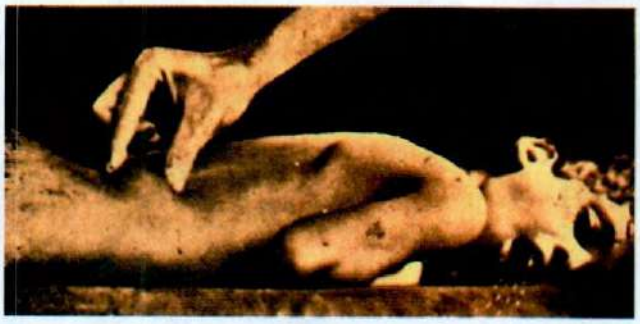

Fig.19.13.— A lumbar cold abscess — feeling for an impulse on coughing (which is more marked in a lumbar hernia).



Fig.19.14.— Iliac cold abscess extending into the thigh under the inguinal ligament. This is being determined by eliciting cross fluctuation.

times the patient may flinch with pain as soon as the skin is being touched. In such cases pinch up the skin to differentiate whether the pain is in the skin or in the spine. In hysterical spine there is always cutaneous hypersensitivity. It is not advisable to perform the *anvil test* always to elicit tenderness in the spine. In this test sudden jerk is applied over the head or the patient is asked to jump down from a chair. However this test should be reserved just to exclude any tenderness in the spine.

2. **Swelling.**— Swellings are of two types in relation with spinal pathology :



Fig.19.15.— Method of extension of spine in case of an adult.



Fig.19.16.— Method of lateral flexion in case of an adult.

(i) Cold abscess arising from the spinal column and may be seen in different places e.g. behind sternomastoid muscle (in cervical caries), in the mediastinum, in the lateral thoracic wall (in thoracic caries), psoas abscess, lumbar abscess, abscess in the buttock and pelvic abscess (in lumbar caries).

(ii) Meningocele — in case of spina bifida, mostly in the lumbosacral or occipital region.

In both these cases an *impulse on coughing* may be elicited. In case of children the meningocele may be pressed with one hand keeping the other hand on the anterior fontanelle to feel for the impulse (Fig. 19.18).



Fig.19.17.— Occipital meningocele.

3. **Wasting and rigidity** of the erector spinae muscle must be felt for.

C. **PERCUSSION** over the spine is sometimes performed to elicit tenderness in addition to the method already described.



Fig.19.18.— Feeling for an impulse at the anterior fontanelle while the meningocele is being compressed.

D. **MOVEMENTS** of the spine are flexion, extension, lateral flexion and rotations. Normally, *flexion* of the spine occurs mostly in the lumbar region and is possible to the extent of obliteration of the normal convexity. *Extension* is free in the lumbar and lumbo-dorsal regions. *Lateral flexion* is not possible without rotation of the vertebrae. This movement is permitted chiefly in the dorsal region. Rotations occur more often in the dorsal and cervical regions. *Nodding movement* of the head takes place at the atlanto-occipital joint whereas *rotation of the head* occurs mainly at the atlanto-axial joint.



Fig.19.19.— The boy with caries of the dorso-lumbar region is picking up a coin from the floor by bending the knees.

Movements of the **cervical spine** should be examined with great caution as sudden death may occur from dislocation of the atlanto-axial joint.

Mobility of the **costovertebral** joints is judged from the range of chest expansion. The normal difference of the chest girth between full expiration and full inspiration is about 2½ inches. This may be affected in conditions which may lead to rigidity of these joints e.g. ankylosing spondylitis.

Movements of **dorsal and lumbar spine.**— RIGIDITY OF THE SPINE is a constant feature of ankylosing spondylitis and Pott's disease. In the early stage it is due to reflex muscular spasm — a natural attempt to immobilize the painful part. Later on fibrous or bony ankylosis is the cause of rigidity. Presence of rigidity is determined by testing the different movements of the spine as follows:

(i) *Flexion.*— In an adult, flexion is tested by asking him to lean forward keeping the knees straight. The clinician places his hands over the spine to note the movements of the spinous processes. It must be noted how much of the movement occurs at the spine and how much by hip flexion. It may be possible to touch the toes by excessive flexion of the hips while the spine remains stiff.

In case of children, they may not act accordingly so it is better to ask them to pick up an object from the floor. When the spine is rigid the child will stoop bending his knees and hips keeping the spine straight. While raising the body he puts his hands successively on the legs, knees and thighs as if he is climbing up his own legs.

(ii) *Extension.*— The adult patient may be asked to lean backwards i.e. to look up at the ceiling. Note the range of extension movement. This movement mainly occurs in the lumbar region and will not be affected until this region of the spine is involved (Fig.19.15).

In case of children, the patient is laid on his face. The clinician lifts up his legs in an attempt to bend the lumbar spine whilst the other hand fixes the dorsal spine. If the lumbar spine is affected it cannot be bent but will be lifted as one piece (Fig.19.20).

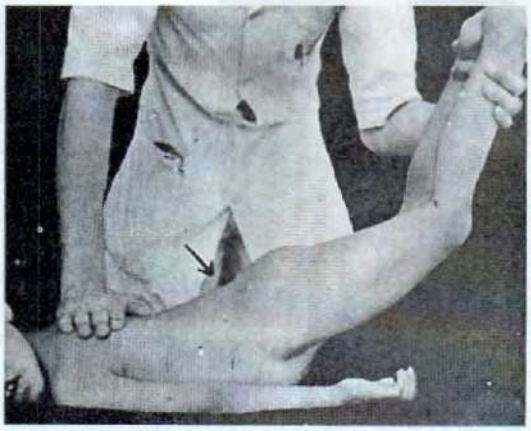

Fig.19.20.— Testing the extension of the spine. In a child the spine can normally be bent to about 60°.

(iii) *Lateral flexion.*— Adults are asked to bend sideways while standing i.e. to slide each hand down the thigh and leg whilst the clinician holds firmly his pelvis from his back (Fig.19.16).

In children these movements are demonstrated by lifting up the legs as in testing extension and then by carrying the legs first to one side and then to the other in order to bend the spine sideways. The other hand of the clinician is placed on the thoracic spine to detect the movement of the spine (Fig.19.21).

(iv) *Rotations.*— The patient is always asked to sit down so as to fix his pelvis. He is then instructed to rotate the trunk to the right and to the left (Fig.19.23). Passively these movements can be performed by moving the shoulders.

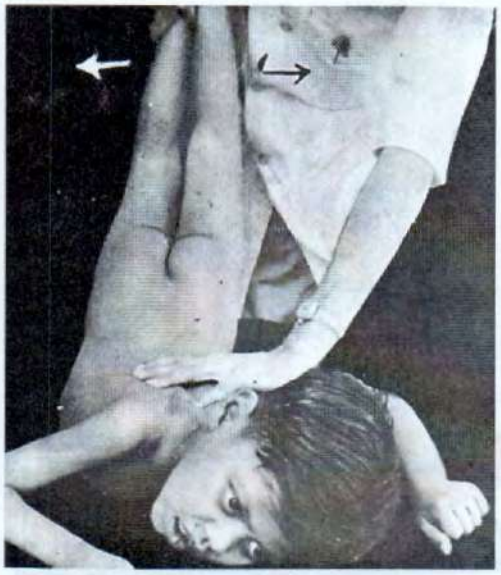

Fig.19.21.— Testing lateral flexion of the spine. In a child this is possible to the extent of 30° to 40° from the median line.

E. **Measurement.**— The lengths of the lower limbs must be measured to exclude shortening of any limb as the cause of scoliosis.

F. **Straight-leg raising test.**— The patient lies supine on the examining table. First exclude that there is no compensatory lordosis by insinuating a hand beneath the lumbar spine. The patient is now asked to raise one lower limb keeping knee straight. He should continue to raise the leg till he experiences pain as evidenced by watching his face. The angle at which the pain was experienced is recorded. To be sure the test is repeated and as the angle is approached additional care is exercised to note when the pain started. If the pain is evoked under 40° it suggests impingement of the protruding intervertebral disc on a nerve root. If the pain is evoked at an angle above 40° it



Fig.19.22.— Testing rotations of the spine. Note that the pelvis is being steadied by the clinician. The patient may be seated to fix the pelvis.

indicates tension on nerve root that is abnormally sensitive from a cause not necessarily an intervertebral disc protrusion.

At the angle when the patient experiences first twinge of pain, *the ankle is passively dorsiflexed* (Fig.19.25). This causes aggravation of the pain due to additional traction to the sciatic nerve *(LASSEGUE'S SIGN)*. It suggests irritation of one or more nerve roots either by disc protrusion or from some other space occupying lesion. This second part of the test is important to differentiate sciatica from diseases of the sacro-iliac joint. In the latter condition straight leg-raising test will be positive but there will be no aggravation of pain during passive dorsiflexion of the ankle.

G. **Femoral Nerve Stretch Test.**— Very rarely a patient with lumbar disc prolapse may complain of pain in front of the thigh. This indicate that probably the protruding disc is L2-3 which is irritating the femoral nerve. The patient is asked to lie on his abdomen and flex the knee of the affected side. If this manoeuvre reproduces the same pain the patient complained of, it is confirmatory that the L2-3 lumbar disc is protruded to cause stretching of the femoral nerve root.



Fig.19.25.— Passive straight-leg raising test. This is important to differentiate the sacro-iliac lesion from sciatica.



Fig.19.23.— Rotation of spine in case of adult. Note that the patient is sitting on a stool to fix his pelvis.



Fig.19.24.— Active straight-leg raising test. See the text.

H. **Naffziger's test.**— Pressure on the jugular vein if increases pain in prolapsed intervertebral disc, this test becomes positive.

I. **Lhermitte's sign.**— This sign detects protrusion of cervical intervertebral disc or an extradural spinal tumour irritating the spinal

duramater. The patient sits on an examining table. Now the head of the patient is bent down passively (flexing the cervical spine) and simultaneously the lower limbs are lifted (flexing the hip joints) keeping the knees straight. This will cause sharp pain radiating down the spine and to both the extremities.



Fig.19.26.— Lhermitte's sign. Neck and hip are simultaneously flexed keeping the knees in full extension. Sharp pain is experienced down the spine into the upper or lower extremity due to irritation of the spinal dura either by tumour or by protruded intervertebral disc.

SACRO-ILIAC JOINT

This joint deserves special mention as it requires different techniques of examination to elicit any pathology therein.

INSPECTION.— The patient is stripped and examined in standing, sitting and recumbent positions. The position of the sacro-iliac joint is determined by presence of a dimple situated just medial to the posterior superior iliac spine.

In standing position the patient is asked to point out the site of pain and the direction in which it radiates. In recumbent position it should be noted whether the hip and knee joints are slightly flexed or not.

PALPATION.— *Tenderness* is elicited by placing the thumb over the dimple and exerting pressure while the patient is asked to bend forward. It may also be elicited by compressing the two iliac crests together. A search for presence of a cold abscess should be made over the buttock, iliac fossa and pelvis (by rectal examination).

MOVEMENTS.— Any movement which throws strain upon this joint will cause pain. Forward bending in standing position becomes painful but in sitting position it will be painless as the pelvis becomes fixed (cf. prolapsed intervertebral disc, in which pain is also felt in sitting position). Rotatory movements are also painful (cf. prolapsed intervertebral disc, in which rotation is painless). There are certain tests to demonstrate movements of these joints.

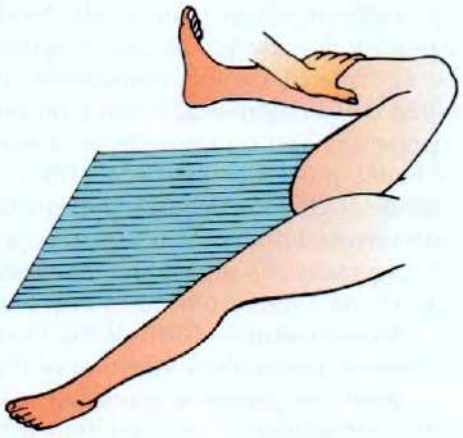

Fig.19.27.— Genslen's test. See the text.

GENSLEN'S TEST.— The hip and knee joints of the affected side are flexed to fix the pelvis and the hip joint of the unaffected side is hyperextended over the edge of the examining table. This will exert a rotational strain on the sacro-iliac joint and will cause sharp pain.

GILLIE'S TEST.— The patient lies prone on the bed. The pelvis of the patient is kept steadied by clinician's hand on the normal sacro-iliac joint. The thigh of the affected side is hyperextended

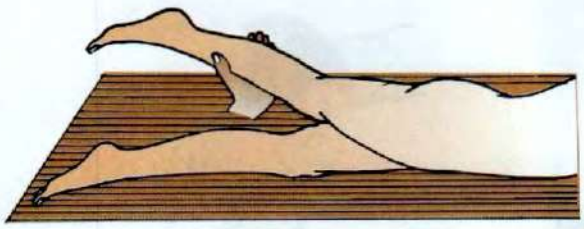

Fig.19.28.— Gillie's test. See the text.

passively with the other hand of the clinician. A sharp pain is felt by the patient when the concerned sacro-iliac joint is diseased.

PUMP-HANDLE TEST.— This test is performed with the patient supine on the examining table. First the normal side is examined. The patient is steadied on the table by grasping the shoulder of the side to be tested. The leg of that side is held with the other hand just below the knee. The knee and hip of that side are flexed and brought up towards the shoulder of the opposite side. In case of normal sacro-iliac joint no pain is felt. But when this test is performed on the affected side a severe pain is complained of in the affected sacro-iliac joint.

Straight-leg raising test.— The patient is asked to lift the thigh up with the knee extended as shown in Fig. 19.24. This will cause pain at the pathological sacro-iliac joint due to the rotational strain imposed on this joint.

Passive straight-leg raising test.— This test can differentiate sacro-iliac lesion from sciatica. The patient is asked to lie completely relaxed. There should be no compensatory lordosis. The ankle is held with one hand and the leg is gradually raised. Normally the leg can be raised to about 90°. Note the angle at which pain is felt. Next the foot is passively dorsiflexed. In case of sciatica, pain will be aggravated by this manoeuvre. It should be noted that in sacro-iliac lesion pain starts with the manoeuvre and continues to be worsen as the leg is being passively elevated. There is hardly a definite angle in which pain appears (cf. prolapsed intervertebral disc, in which pain appears at a certain angle, which is below 40° when it indicates impingement of a protruding intervertebral disc on a nerve root; and if it is above 40° it indicates tension on a nerve root from any cause).



Fig.19.29.— *Pump-handle test.* See the text. Note the placing of the two hands of the clinician.

Measurement.— Girth of the lower limb may give some indication of wasting which is so evident in tuberculous affection of this joint.

Rectal or Vaginal examination is sometimes required to exclude presence of pelvic abscess. This examination is also required if pathological condition of the prostate, seminal vesicles or uterine appendages is suspected.

GENERAL EXAMINATION

1. **Look for neurological signs** specially in the affection of the thoracic region where the spinal canal is very narrow. Different sensations, muscle powers and reflexes are tested to know

if there is any evidence of cord compression. Pott's paraplegia is not unusual in tuberculosis of the spine.

2. **Cold abscess** must be sought in cases of tuberculosis of the spine. It must be looked for in suboccipital region, posterior triangle of the neck, in the paravertebral region, the lateral aspect of the chest, the loin the Petit's triangle, the iliac fossa, the groin (psoas abscess), the pelvis and the ischiorectal region *Rectal examination* is very much essential to exclude pelvic extension of this abscess.

3. **The chest** should be carefully examined to exclude any previous operation as may be the cause of scoliosis.

4. **The primaries** should be looked for when secondary carcinoma of the spine is suspected. The lungs, the thyroid, prostate, breasts, kidneys should be examined to detect any primary lesion there.



Fig.19.30.— Pott's disease showing diminution of the intervertebral space and destruction of the opposing surfaces of the vertebrae.



Fig.19.31.— Skiagram of a case of caries spine. Note the diminution of the intervertebral space shown by arrow.

SPECIAL INVESTIGATIONS

X-RAY EXAMINATION.— This is by far the most important special investigation and most of the cases are diagnosed by this. Both anteroposterior and lateral views should be taken. In *tuberculosis of the spine* diminution of the intervertebral space with hazy outline of the adjoining vertebral surfaces seems to be the early manifestation. Later on one may find paravertebral abscess and even psoas abscess. Wedging and gross destruction of the adjoining vertebrae are late features. In *compression fracture* the vertebrae may be wedged but the intervertebral space remains normal. In *secondary carcinoma,* osteolytic changes are evident in the bodies of the vertebrae. Here also the intervertebral space remains unchanged. Osteosclerotic change

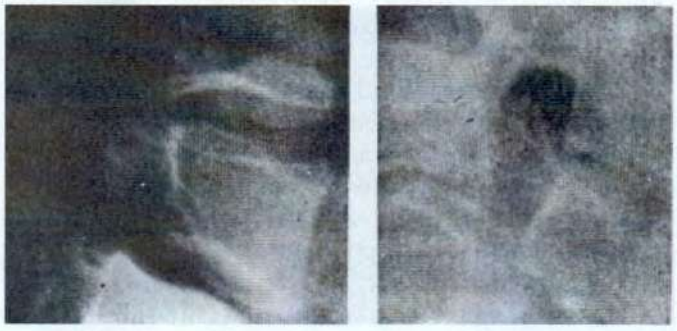

Figs.19.32 & 19.33.— Skiagram of spondylolisthesis. In the first figure the structural defect in the pars interarticularis can be seen. In the second figure there is forward displacement of the fifth lumbar over first sacral vertebra (congenital spondylolisthesis).



Fig.19.34.— A straight X-ray of ankylosing spondylitis (late stage).

may be seen in prostatic carcinoma. In *Scheuermann's disease* the vertebral epiphysis may be irregular, dense, similar to the osteochondritic changes. In *Paget's disease* coarse trabeculation with cystic changes may be seen. In *senile osteoporosis* the vertebrae are less dense than normal. In *osteoarthritis* characteristic peripheral lipping when present, leaves no doubt about the diagnosis. *Spina bifida* will be obvious when a gap in the laminae is seen in X-ray. In *prolapsed intervertebral* disc the affected intervertebral space becomes narrowed. In *spondylolisthesis* the lateral view is very important in which the 5th lumbar vertebra with the upper articular process slides forward over the sacrum and its lower articular process. This is due to the developmental defect of the pedicle of the 5th lumbar vertebra. In *tuberculous affection of the sacro-iliac joint,* the joint line becomes blurred with osteolysis of the neighbouring bones. In *ankylosing spondylitis* X-ray will reveal irregular marginal sclerosis with indistinct joint outline.

BONE SCAN.— See page 155.

MYELOGRAPHY.— Light lipiodol is introduced through the lumbar puncture needle or heavy lipiodol is injected by cisterna puncture into the subarachnoid space. X-ray picture is taken to find out if there is any filling defect by a protruding disc or any space occupying lesion in the subarachnoid space.

EPIDUROGRAPHY.— Injection of water soluble contrast medium is often preferred due to the risk of possible long term sequel of oily contrast medium. The most commonly used medium is Urograffin (sodium diatrizoate) 60%. Antero-posterior film will show central filling defect, peripheral filling defect or interruption of the nerve root out line. Lateral X-rays will reveal the filling defect from disc intrusion. Epidurography is found useful in the investigation of prolapsed intervertebral disc, epidural and periradicular lesions, spina bifida occulta, tumours arising from the intradural, vertebral and paravertebral tissues, spondylolisthesis, subdural haematoma etc.

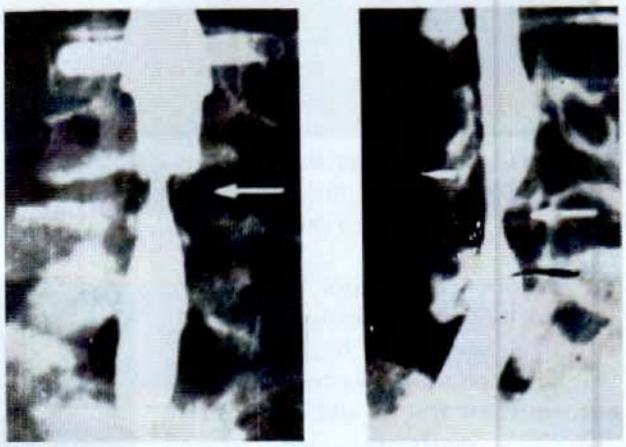

Fig.19.35.— Anteroposterior and lateral views with radio-opaque dye showing filling defect at the level between L4 and L5 shown by arrows due to lumbar disc protrusion.

DISCOGRAPHY.— Indications of lumbar discography are (i) clinically protruded intervertebral disc but a negative myelogram, (ii) uncertain clinical evidence of prolapse of a specific disc and (iii) when pain recurs following surgery as defects in myelogram may then be due to adhesions and postoperative distorsion of the theca. The main complication of discography is infection which of course can be minimised by strictly aseptic technique. The other potential

complication is prolapse of the punctured disc. Its incidence can also be reduced by using a very fine needle. It is usual to inject the lower three or sometimes four discs with water-soluble contrast medium after confirming that the needles appear to be in about the centre of the nucleus pulposus on lateral radiographs. Injection of a normal disc frequently causes some backache. Radiographs are then made in lateral and postero-anterior projections. A normal nucleus is well-circumscribed and is confined by annulus fibrosus. In degenerated discs the nucleus is usually narrowed and may bulge the annulus. A disc prolapse fills beyond the confines of the intervertebral space and if the annulus is torn the contrast may extravasate. Accentuation of symptoms, which may quickly recede again makes discography an unpleasant procedure even with adequate premedication. But it is preferred to negative surgical exploration.



Fig.19.36.— A normal discography.

ILIAC AND INFERIOR VENACAVOGRAPHY.— The venogram is simple, performed by percutaneous catheterisation of the femoral vein with simultaneous injection of suitable contrast medium on both sides. The patient is kept mobile to discourage thrombus formation. This investigation reveals a retroperitoneal mass which may cause backache.

LYMPHOGRAPHY.— Malignant lesions causing referred pain are usually sufficiently advanced to show obvious abnormalities in lymphogram. With this investigation one can confirm their positions and may give a good indication of their nature.

M.R.I.— This has revolutionized the investigation of these cases as soft tissue abnormalities can be detected by this method e.g. disc prolapse, spinal cord tumour, spinal column tumour are all detected in early stages. MRI with contrast medium (see Page 39) is particularly helpful to detect spinal cord tumour (Fig.3.48).

DIFFERENTIAL DIAGNOSIS

CONGENITAL ANOMALIES

Spina bifida.— This condition develops due to failure of fusion of the posterior part of the spine resulting in a defect through which the membranes and even the spinal cord may herniate. Usually it affects one vertebra most commonly in the lumbosacral region and less often in the cervico-occipital region. The different types of spina bifida are as follows :

(1) *Spina bifida occulta* is due to failure of the neural arches to unite posteriorly, but no protrusion of the cord or membrane is noticed. Almost always this condition is seen in the lumbosacral region and it is suspected by presence of a cicatricial thickening or a dimple or a tuft of hair or dilated vessels or a fibrofatty tumour or a naevo-lipoma over the bony deficiency. A fibrous band, the membrena reuniens, connects the skin to the spinal theca. As soon as the child grows older the theca is pulled down by membrena reuniens and symptoms like backache, enuresis, foot drop, weakness of the lower limbs and even paralysis may appear. A few cases may remain symptomless and are only diagnosed when X-ray is taken for some other reason.

(2) *Meningocele.*— When meninges protrude through the defect in the spine this condition develops. It contains only cerebrospinal fluid.

(3) *Meningo-myelocele.*— In this condition in addition to protrusion of the membrane, normally developed spinal cord and cauda equina lie within the sac and may be adherent to the posterior aspect of the sac. This condition is quite common in living children and is differentiated from the previous condition by presence of dark shadows of the cord or nerves on transillumination.

(4) *Syringo-myelocele.*— In this condition the central canal of the spinal cord becomes dilated and the cord lies within the sac and becomes adherent to the posterior part of the sac.

(5) *Myelocele.*— This is probably the commonest type of spina bifida but is incompatible with life. The central canal of the spinal cord opens out on the surface and discharges cerebrospinal fluid continuously. Paralytic deformities of foot and incontinence of urine and faeces are almost always accompanied with these conditions.

DEFORMITIES OF THE SPINE

Scoliosis.— This means deviation of the spine to one side. Normal spine is straight. Slight deviation is expected following fracture or infections like tuberculosis. But these are not considered in this section. Lateral curvature of scoliosis is almost always associated with the rotation of the spine. Mainly two types of scoliosis are noticed in surgical practice — mobile scoliosis (transient) and structural scoliosis (permanent).

MOBILE SCOLIOSIS is transient that means it is never transformed into fixed scoliosis and in this type the vertebrae are not rotated. In this group three types are noticed — (i) *Postural scoliosis,* particularly seen in adolescent girls and the curve is mild and convex to the left. The main diagnostic feature is that when the patient bends forward, the spine straightens completely (cf. structural scoliosis in which the curve becomes excessive on bending forward). (ii) *Compensatory scoliosis* is seen in patients with unilateral short legs, ocular disorders, torticollis etc. The diagnostic feature in case of short leg is that the curve disappears when the patient sits. (iii) *Sciatic-scoliosis* is usually accompanied by sciatica with prolapsed lumbar disc. The clinical features signify the underlying cause.

STRUCTURAL SCOLIOSIS is always associated with rotation of the vertebrae. The bodies rotate towards convexity of the curve and the spinous processes towards the concavity. Once the deformity develops, it is liable to be increased due to greater pressure on the epiphyses on the concave side which retards growth. The curvature ceases to be increased when the growth of the patient stops completely. An index to spinal maturity is the complete appearance of the iliac apophyses in X-ray (Risser's sign). In this type of scoliosis three curves are found. The middle one is primary and the compensatory curves lie above and below the primary curvature. The different causes of fixed scoliosis are as follows :—

(i) *Idiopathic* is the commonest. In this condition the primary curve is always thoracic and mental defect is a common accompaniment of this condition. This type is recognized by eliminating any identifiable cause. (ii) *Congenital* type is always associated with some form of radiologically demonstrable anomaly such as hemivertebrae, fused vertebrae, absent ribs or fused ribs, absent discs etc. Some obvious congenital abnormality may be found on the surface e.g. naevi, angioma, excess of hair, a dimple or a pad of fat. This type of scoliosis is usually mild. A careful neurological examination should always be carried out as spina bifida or other neurological deficits may be present along with this condition. (iii) *Paralytic* scoliosis is due to paralysis from poliomyelitis, cerebral palsy, muscular dystrophy etc. Unbalanced paralysis affecting intercostal and lateral abdominal muscles is the cause of this scoliosis. (iv)

About 1/3rd of the patients suffering from *multiple neurofibromatosis* develop scoliosis.

Generally the patients with scoliosis complain of the deformity only. A few of them may present with backache in whom lumbar curves or combined curves may pass unnoticed. In all cases of scoliosis one must not forget to examine the heart and lungs as congenital heart disease may be associated with this condition and an increasing thoracic scoliosis may lead to gradual respiratory embarrassment.

Kyphosis.— Excessive posterior convexity of the thoracic spine is defined as kyphosis. The different causes of kyphosis worth mentioning are (i) *Postural* kyphosis is usually associated with such defects as flat foot, is seen in girls approaching puberty, women after child birth or with obesity. (ii) *Compensatory* kyphosis is seen in lumbar lordosis, congenital dislocation of hip or fixed flexion deformity of the hip. (iii) *Scheuermann's disease* — is nothing but osteochondritis affecting the epiphyseal plates of the vertebrae. The victims are usually teen-agers and the usual complaint is the backache. Thoracic 6th to 10th vertebrae are usually involved and become wedge shaped, narrower in front. The epiphyseal plates appear fragmented especially anteriorly. They may contain small translucent areas (Schmorl's nodes). (iv) *Ankylosing spondylitis* is an autoimmune disease with a definite genetic background. Prostatitis probably plays a part. The underlying pathology is that the intervertebral discs are first replaced by vascular connective tissue and then undergo ossification affecting the periphery of the annulus fibrosus and the intervertebral ligaments. The disease often starts around the sacroiliac joint in the form of osteitis. Pain and stiffness of the lumbar spine and buttocks are the main presenting symptoms. Occasionally the pain may mimic that of sciatica, but in contra-distinction to the disc prolapse the pain alternates its side. The onset is insidious and only noticed during getting up of the bed. Malaise, fatigue, loss of weight are the general symptoms which the patient may complain of. The victims are usually men between the ages of 15 to 35 years. They are under-nourished and in half of the cases the process stops before significant deformity has occurred. In the other half of the cases the process continues for many years with phases of activity and it does not stop till the entire spine and the several large joints have stiffened. The general attitude of the patient is to stand with kyphosis and the knees are bent to maintain balance. The sarco-iliac joints may be painful particularly so when the two iliac crests are pressed inwards from both the sides. It must be noted that small joints are always exempted. Anaemia and raised sedimentation rate are the abnormalities found in routine blood examination. X-ray shows blurred and irregular joint lines with surrounding sclerosis, joint spaces are gradually diminished and may be obliterated. The vertebral bodies lose their normal anterior concavity and look square. Calcification of the intervertebral ligaments and well defined borders with sclerosis complete the classical picture of a 'bamboo' spine. (v) *Senile kyphosis* is the kyphosis seen in old people. Degeneration of intervertebral discs produce increasing stoop characteristic of the aged. The disc spaces become narrowed and the vertebrae slightly wedged. There is hardly any pain unless osteoarthritis affects the intervertebral joints. *Kyphosis may also be seen in cases of widespread osteoporosis, Paget's disease and secondary malignant deposits affecting the vertebrae.* (vi) Kyphosis may also follow a fracture of the vertebra, *tuberculosis* or *Calve's disease* which is a rare condition and is the sequel to an eosinophilic granuloma affecting one vertebra (the disc space remains normal).

Lordosis.— This is an increased anterior curvature of lumbar spine. It may be postural as compensatory to fixed flexion deformity or congenital dislocation of the hip. Tuberculosis of the hip and malunited fracture of the femur may lead to this condition. The deformity may also develop to correct the centre of gravity of the body as required in last trimester of the pregnancy, large uterine fibroid or a big fatty abdomen.

Spondylolisthesis.— This means forward shift of the spine. The shift nearly always takes place between L4 and L5 or between L5 and S1. The pathology lies either in the lamina which may be in two pieces or unduly elongated or in the facets which are poorly developed. The *Congenital* variety is by far the commoner and constitutes no less than 75% of the cases. *Degenerative* variety constitutes about 20% of cases and is due to the degenerative changes in the facet joints as also the discs, which permit the forward shift despite intact lamina. *Traumatic*

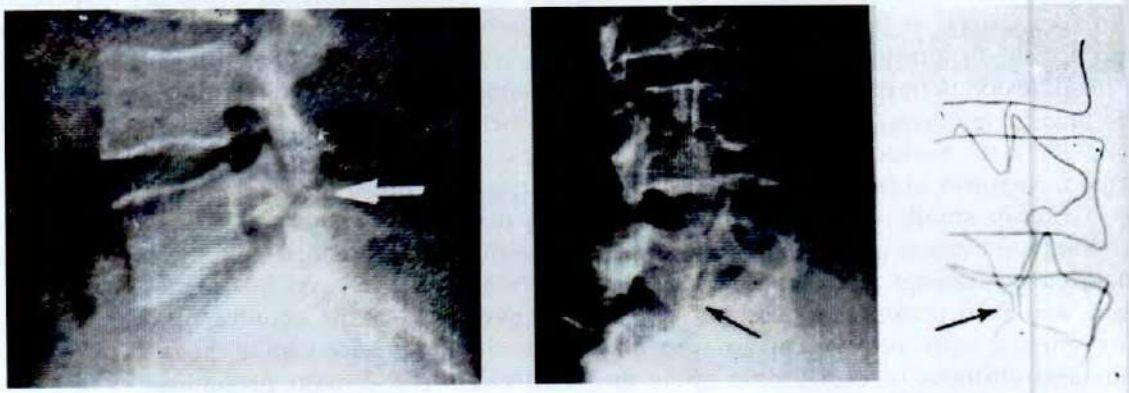

Figs.19.37 & 19.38.— In the first figure the lateral view is shown. It is a typical case of moderate spondylolisthesis of L5 and S1 is being shown with an obvious bony defect in the interarticularis zone. Spondylolisthesis is better diagnosed however in oblique view which is shown in the second figure. An outline of a 'Scot's terrier' can easily be seen in this view with the neck formed by the pars interarticularis. When there is a break, as shown by arrow, the terrier is decapitated and the lesion in the pars is seen.

variety constitutes about 5% of cases and may follow either a single major injury or repeated minor injuries. In the congenital variety there is developmental defect of the pedicle of the 5th lumbar vertebra. This part which is called 'Pars interarticular' is divided in two parts being connected by fibrous tissue which is shown as a gap in X-ray. The lower articular processes remain with the sacrum in situ whilst the upper articular processes along with the spinal column above move forward. The main complaint is the backache which becomes more obvious after exercise or strain. The pain may radiate down to the legs and there may be weakness of the lower extremities. This is due to the pressure on the cauda equina and the emerging nerve roots. Disc prolapse is liable to occur. This condition may affect any age but degenerative variety is obviously rare before the age of 40 years. On examination the trunk appears shorter, the buttocks look flat, the upper angle of the sacrum forms a distinct prominence on the back with depression just above it. The most important finding on inspection is a transverse furrow encircling the body between the ribs and the iliac crests. On palpation a definite prominence at the upper angle of the sacrum will be obvious when the clinician runs his fingers down along the spinous processes. X-ray shows the upper border of the 5th lumbar vertebra is too low in anteroposterior view, whereas lateral view demonstrates clearly the forward shift of the spinal column, a gap in the lamina, elongated lamina or defective facets if they are present. To demonstrate the gap in the lamina which may not be so obvious in lateral view, oblique views may be required.

INFLAMMATORY CONDITIONS

Tuberculosis of the spine (Pott's disease).— This is the most important disease that affects the spine in this country. It attacks children and adolescents more commonly than the adults. In prodromal stage, the patient gets tired, there are loss of weight and evening rise of temperature. Pain is usually the main complaint. It is slight in the beginning and dull ache in character. It becomes worse on walking or jolting. The pain may be localized or referred due to involvement of the nerve-roots. Rigidity is the next complaint. It restricts all movements. Deformity in the form of a hump or angular kyphos leading to hunchback is not uncommon. On palpation one can detect localized tenderness if pressed on the particular spine. Slight angular deformity also becomes obvious in palpation. The two common complications are *cold abscess formation* and *paraplegia.* Fluctuation test will be positive with the formation of the abscess. Movements become diminished in all directions. This becomes obvious in the involvement of the lumbar spine than that of the thoracic spine. Attempt to movement will provoke muscular spasm. "Coin test" gives a good indication as to the limitation of the flexion movement of the spine.

X-ray findings are important in which the adjacent bodies will show destruction with diminution of the intervertebral space (cf. secondary deposit in the spine will cause destruction of the bodies with intact intervertebral disc). Anteroposterior view may show the soft tissue shadow of paravertebral abscess. The legs must always be examined for presence of neurological deficits.

A summary of the clinical features according to the region affected is given below :—

(i) CERVICAL.— (a) Besides localized pain, it may be referred to the back of the head or arm depending on the nerve-root affected by pressure. (b) Attitude — The head being supported by the patient's hand. (c) Rigidity of the neck. (d) Deformity in the form of torticollis. (e) Abscess — In the retropharyngeal space (causing dysphagia and dyspnoea), in the posterior triangle of the neck whence it may travel down towards the mediastinum or along the brachial nerve to the axilla or in the suboccipital region.

(ii) THORACIC.— (a) Pain may be localized or referred to the chest, abdomen or sometimes girdle pain. (b) Rigidity is not so obvious in tuberculosis of this region of the spine. (c) Deformity in the form of kyphosis and gibbus. (d) Abscess formation in the paravertebral region and it may burrow following the cutaneous branches of the intercostal vessels and nerves to the anterior and lateral thoracic region. From the posterior mediastinum it may gravitate down beneath medial or lateral arcuate ligament to become psoas or lumbar abscess respectively. The psoas abscess comes out through the medial aspect of the upper part of the thigh; whereas the lumbar abscess becomes superficial in the Petit's triangle, formed by the iliac crest and the adjacent borders of the latissimus dorsi and the external oblique muscles. (e) *Nervous manifestations* are most frequently noticed in the affection of this region. *Paraplegia is quite common due to the fact that the spinal canal is narrowest in the region.*

(iii) LUMBAR.— (a) Pain is mostly localized in this region but may be referred to the lateral aspect of the thigh. (b) Limitation of movements is mostly noticed in this region. (c) Deformity is minimum. (d) Abscess formation is not uncommon mainly in the form of iliopsoas abscess which may burrow into the thigh under the inguinal ligament or into the pelvis and perineum where a fistula forms on bursting or it may travel to the buttock from the pelvis passing through the sciatic foramen. (e) Nervous symptoms are rare as the spinal canal is spacious.

Pott's paraplegia is due to compression of the spinal cord more frequently by soft inflammatory material (the abscess, a caseous mass and granulation tissue) or less frequently by solid material (a bony sequestrum, sequestrated disc or the ridge of the bone at the kyphos). Occasionally fibrous tissue is the compressing agent.

Acute osteomyelitis of the spine.— This condition is very rare. It is characterized by sudden onset of fever and severe local pain. There is hardly any collapse of the affected vertebrae owing to early recumbency by the patient, rapid new bone formation and paravertebral calcification. In late cases there will be pyogenic abscess and not a cold abscess. The condition culminates in bony ankylosis and not fibrous ankylosis (cf. tuberculosis of the spine). The prognosis is dismal as there always remains the chance for the infection to spread and involve the meninges.

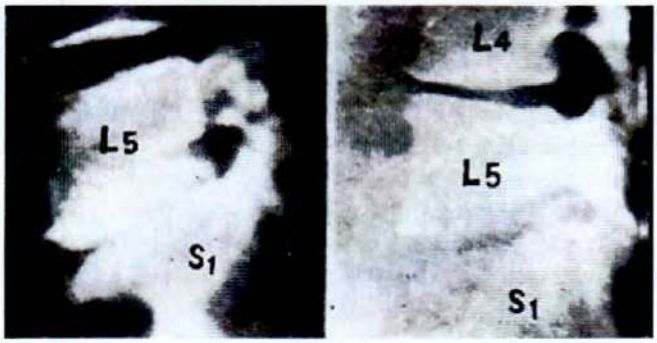

Fig.19.39.— Note considerable diminution of the intervertebral space between L5 & S1 in the first figure due to lumbar disc prolapse. In the second figure one can see the normal intervertebral space.

DISORDERS OF INTERVERTEBRAL DISCS

In this group the most important condition is the disc prolapse. Only other condition which deserves mention is protrusion of the disc into the vertebral bodies causing Schmorl's node. This is seen in Scheuermann's disease.

Lumbar disc prolapse.— The various factors which may cause this condition are : (i) *Injury.*— A lifting strain with the back bent may tear the posterior longitudinal ligament causing the tense disc to bulge backwards. The annulus fibrosus may also be torn and the nucleus pulposus may bulge out. If the tear does not heal properly further prolapse is likely to take place with trivial strain. (ii) *Increased tension* within the nucleus pulposus is sometimes seen in some physical illnesses and emotional stress. Extra fluid is absorbed, the nucleus swells and may even burst through the annulus. (iii) *Degeneration* is probably the commonest cause in which the fluid content of the disc decreases with changes in the character of the collagen fibres so that the disc loses elasticity and may liable to bulge with body weight.

Prolapsed disc may press on the duramater causing backache or on the nerve roots causing backache or sciatica or both. The prolapse of a disc occurs nearly always just above or below the 5th lumbar vertebra (i.e. between L4 and L5 or L5 and S1). As oedema subsides the prolapsed disc may shrink or slip back into place. Sometimes it may not be absorbed and becomes adherent to root sheaths. Long standing prolapse may disturb the mechanism of the intervertebral joints.

The first attack is often sudden in onset and occurs while lifting weight from bent position.

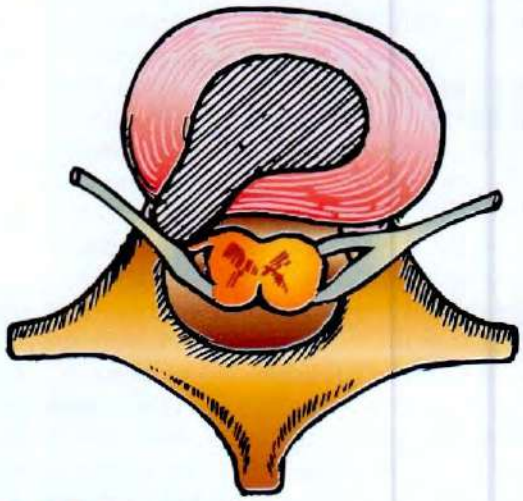

Fig.19.40.— Diagrammatic representation of lumbar disc prolapse in which the prolapsed disc is pressing on a spinal nerve root on the left side.

The patient complains of excruciating backache and sciatica may or may not follow soon after. The symptoms subside in a few days or weeks. Sciatica is at first located in the buttock but it soon spreads to the thigh, leg along the posterior aspect even upto the toes. Subsequent attacks are also sudden in onset but may follow trivial injury such as coughing etc. *On examination,* the patient is found to stand with a characteristic attitude — lumbar scoliosis with convexity to the affected side, kyphosis and slight flexion of the hips and knees. Local deep tenderness is elicited on or slightly lateral to the affected spine. Pressure on the jugular vein often induces pain over the lesion (Naffziger's test). Flexion and extension of the spine are greatly restricted. Lateral flexion on the side of the lesion is also very painful, but rotation may be free and painless. Knee jerk may be diminished (in case of lesion between L3 and L4), but tendo Achillis jerk is almost always absent. Extension of the great toe against resistance will show weakness of the extensor hallucis longus. This indicates nervous involvement.

After first attack there may not be any X-ray changes. But after many months or years with subsequent attacks there will be narrowing of the intervertebral space with lipping of the vertebral bodies, i.e. secondary osteoarthritic changes develop. Myelography is helpful in diagnosing this condition. Recently discography is often done to delineate the protrusion of the disc. Epidurography is also helpful so far as the diagnosis of this condition is concerned. MRI is probably the best method of investigation at the present (see. Fig.30.6 of the author's 'A Concise Textbook Of Surgery').

Lumbar Spondylosis.— This is a degenerative condition which involves not only the disc space but also the interarticular joints. The discs degenerate and lose the normal elasticity. There will be lipping of the vertebral bodies. Osteophytes will be seen around the interarticular joints. Sometimes the disc material may extrude with a pressure of the body and press on the duramater leading to backache. Osteophytes and protruded disc may also press on the nerve roots causing sciatica. Patients are invariably over 40 years of age. There will be tenderness of the affected vertebrae. All lumbar movements are limited and painful. Neurological examination may elicit some deficit in the lower extremities. X-ray will show diminution of the intervertebral space. The interarticular joints are narrowed and irregular. There will be lipping at the corners of the vertebral bodies and presence of osteophytes around the interarticular joints.

TUMOURS OF THE SPINAL COLUMN

The commonest tumour is the **secondary carcinoma,** the primary being in the breast, bronchus, suprarenal, kidney, prostate, thyroid etc. The main features are severe local pain with collapse of the vertebral column with or without symptoms of cord compression. X-ray shows osteolytic changes in the vertebral bodies, barring in case of secondaries from the prostate when the lesion will be osteoblastic. There may be collapse or wedging of the vertebra, *but the intervertebral space will remain normal* (cf. tuberculosis of the vertebra).

LOW BACK PAIN

The causes of low back pain can be classified in the following way :

(A) **In the back**

(i) CONGENITAL

(a) Spina bifida; (b) Spondylolisthesis; (c) Hemivertebra (when one of the two centres of ossification for the vertebral body fails to develop); (d) Split vertebra (when there is a definite gap between the two centres of ossification); (e) Abnormality in the articular processes (articular facets of the 5th lumbar vertebra may take the form like that of articular processes of the thoracic

vertebra); (f) Besides lack of fusion between the two halves of the neural arch which produces the condition of spina bifida, the lamina may fail to fuse with the body of vertebra; (g) Sacralisation of the transverse process of the 5th lumbar vertebra.

(ii) TRAUMATIC

(a) Lumbosacral strain;

(b) Injuries to the intervertebral joints, ligaments and muscles. These injuries are produced by external violence which may overstretch the spinal column. The pain is sudden and although increased by certain movements, it is a constant excruciating pain during the acute stage which is only partly relieved by rest. It is sometimes difficult to find out the exact sign of the lesion. In case of muscle strain the common site being the origin of the sacrospinalis from the back of sacrum or the origin of the gluteus maximus from the posterior superior iliac spine. The underlying pathology is simply the rupture of some fibres with consequent exudation and swelling. Novocaine injection abolishes the local pain. In ligamentous injury the pain is deep-seated and can be elicited both by pressure with the finger or by movement of the spine;

(c) Spondylolisthesis.— Many orthopaedic surgeons are of the opinion that trauma plays a significant role so far as the aetiology of this condition is concerned. Minor repeated trauma may lead to this condition which may be incriminated as a congenital lesion;

(d) Compression fracture;

(e) Vertebral process fracture (transverse or spinous processes);

(f) Ruptured disc.

(iii) FUNCTIONAL DEFECTS

(a) Anteroposterior imbalance (pregnancy, pot belly, fixed flexion deformity of the hip joints etc.);

(b) Lateral imbalance (scoliosis, leg length discrepancy etc.);

(iv) INFLAMMATORY

(a) Pyogenic osteomyelitis;

(b) Tuberculosis;

(c) Rheumatoid arthritis;

(d) Brucellosis;

(e) Ankylosing spondylitis;

(f) Myositis;

(g) Fibrositis.

(v) DEGENERATIVE

(a) Osteoarthritis (spondylosis);

(b) Senile osteoporosis;

(c) Degenerative disc disease.

(vi) NEOPLASTIC

(a) Primary tumours e.g. multiple myeloma, eosinophilic granuloma, haemangioma, osteoid osteoma;

(b) Metastatic tumours from breast, bronchus, kidney, suprarenal, prostate, thyroid, gastro-intestinal tract.

(B) **Other than the back**

(i) ABDOMINAL DISORDERS, e.g. pancreatitis (very important), cholecystitis, biliary calculus, peptic ulcer, hiatus hernia etc.;

(ii) PELVIC DISORDERS, e.g. inflammatory condition of the ovaries and tubes, any intrapelvic tumour etc.;

(iii) GENITO-URINARY CAUSES, e.g. renal infection, renal or ureteric calculus, prostatitis,

prostatic carcinoma, seminal vesiculitis etc.;

(iv) VASCULAR DISORDERS, e.g. ischaemic pain from occlusion of the aorta or iliac arteries and aneurysmal dilatation of the aorta may cause backache.

Lumbosacral strain.— This condition develops from mechanical stress and strain which the lumbosacral region renders itself. It is the site of great shearing strain and it is the junction between the mobile and the fixed part of the spinal column. It occurs in both acute and chronic forms. The acute form may be due to sudden blow forcing the joint into positions beyond the normal range of movement. The spinal muscles yield when they are off guard and thus the ligaments sustain the full force of injury. The chronic form is usually insidious in onset but may follow an acute strain which may or may not be recognized. It occurs mostly in individuals with poor musculature and an increase in the normal lumbar lordosis (usually a woman with a pendulous abdomen). Gradually the attacks become more and more frequent and the pain may become constant as the age advances. Sciatic pain may be present if there is root pressure.

Fibrositis (lumbago).— Fibrositis causing backache often reveals one or more tender nodules lying superficially in the erector spinae or its attachments. In the lumbar region it is called lumbago. This tender nodules may be found in the buttocks. The aetiology is not very clearly known. It may be rheumatic fibrositis or local muscular spasm due to nerve root irritation. The pain comes on suddenly when the patient bends his back and it is very severe. Recurrences are common and the condition may become chronic. If neurological signs are present, it is probable that a disc has been protruded.

Malingerer's low back pain.— In this condition though the patient constantly complains of low back pain, yet no organic cause can be found out. Patient is mostly psychic with depression and anxiety states. Two tests can be performed to detect such cases — (i) AIRD'S TEST.— The patient is first asked to flex forward to touch his toes in standing position keeping the knees straight. He usually fails and complains of pain. He is now asked to sit down on an examining table and advised to touch his toes by flexing the spine. This he is often able to do as there is no organic lesion of the spinal column.

(ii) MAGNUSON'S TEST.— The patient is asked to point the most painful area of the spine and this is pointed out with a skin pencil. Now the patient's attention is diverted by examining his throat, eyes, rectum, abdomen etc. and then asked to point again the most painful spot on his back. He shows a different spot as he has forgotten by that time which spot did he show earlier, as there is no organic lesion.

Sacro-iliac strain.— When there is definite pain on one sacro-iliac joint, but no definite cause can be detected the condition is called 'sacro-iliac strain'. Though the tests for the sacro-iliac joint are positive, yet the X-ray and other investigations are all negative.

Sacro-iliac arthritis.— This is quite rare. It may be a complication of Reiter's disease. This joint is almost always involved in ankylosing spondylitis. A few patients with ulcerative colitis suffer from this disease. Leading symptom is painful stiffness of the back as first thing in the morning. There may also be pain of band-like distribution across the sacrum and buttocks. Patient may limp, and if the condition is bilateral 'Waddling gait' may be seen.

Tuberculosis of the Sacro-iliac joint.— This is a rare disease. When in a patient with persistent low back pain no cause could be found out one must keep in mind this condition. It is a condition which usually affects young adults. Pain is often of central low back or groin pain or sciatica. Only in half the cases pain is localized to the joint. At the time of cold abscess formation pain is severe. Patient also complains of night pain. When pus erodes the ligamentous coverings of the joint, pus comes superficial and presents as fluctuating swelling. In 70% of cases the abscess appears over the joint and in the rest the abscess tracks down either to the groin or to the iliac fossa or in the femoral triangle.

Chapter

20 EXAMINATION OF THE HAND

HISTORY.— A careful history should be elicited as to what is the complaint and how is he suffering from it. The onset is very important. Whether it follows injury, a sequel of abrasion or a prick or of insidious onset.

INSPECTION.— Careful inspection often clinches the diagnosis. The typical *attitude* of mallet-finger, trigger-finger, clawhand, Volkmann's ischaemic contracture, Dupuytren's contracture diagnose by itself. *Deformity* is so characteristic of Dupuytren's contracture that nothing more could be asked from the patient. *Swelling* may be *localized* as in localized abscess (e.g. paronychia, subcuticular abscess, terminal pulp-space abscess, web-space abscess) or other local swellings as may be found anywhere in the body. *Diffuse* swelling and redness of lymphangitis, cellulitis and erysipelas are also not uncommon. *Always compare with the normal hand side by side.* Wasting of thenar or hypothenar eminence or interossei between the metacarpals can be best diagnosed by such comparison. Similarly ischaemic atrophy is also diagnosed in this way.

PALPATION.— Hand is carefully palpated to note if there is any change *of temperature* (warm or cold). In case of inflammatory lesions e.g. cellulitis, erysipelas, abscess, arthritis etc. there will be rise of temperature; whereas in case of ischaemic lesion (cervical rib syndrome, thoracic outlet syndrome, scalenus anticus syndrome, Raynaud's disease etc.) the hand will be cold. If there is any localized *swelling* e.g. implantation dermoid of finger, ganglion or compound ganglion such swelling should be examined according to the plans set out in Chapter 3 'Examination of a lump or a swelling'. In case of trigger-finger thickening of the fibrous sheath of the flexor tendon can be palpated. Similarly subcutaneous nodules may be palpated in Dupuytren's contracture. Hand is also carefully palpated to detect any point of *tenderness*. This is significant to diagnose both spreading and localized infections (see below) of the hand.

Feel **both pulses** (radial and ulnar) at the wrist. Sometimes the digital arteries can be felt on either side of the base of the fingers. A rough indication of the arterial flow to the fingers can be obtained by watching the rate of feeling of the vessels beneath the nail after emptying them by pressing down on the tip of the nail.

There are certain conditions which may involve the **nerves** which supply the muscles and the skin of the hand. These nerves are mainly the median nerve, the ulnar nerve and the radial nerve. These nerves may be involved singularly or plurally in various medical conditions and surgical conditions e.g. thoracic outlet syndrome, cervical rib syndrome, leprosy, Carpal-Tunnel syndrome (median nerve), elbow tunnel syndrome (ulnar nerve) and in various fractures and dislocations of the arm and forearm.

SENSATION.— Carefully palpate the hand to locate loss of sensation or paraesthesia. A few terms should be remembered in this regard — (i) *paraesthesia* means altered sensations felt in the form of pins and needles, tingling and numbness etc. (ii) *Hyparaesthesia* means the skin has become hypersensitive to normal stimuli. (iii) *Hypoaesthesia* means decreased feeling of sensation.

(iv) *Anaesthesia* means total loss of sensation of the affected part. With a fine pin, a wisp of cotton and a test-tube of warm and cold water one can test the various sensations of the hand and fingers to note which nerve has been affected. In Fig.9.21 the sensory distribution of these 3 nerves in the hand has been shown. One should also know the dermatomes of the hand means the sensory distribution of the spinal segment — the medial part of the hand, the whole of the little finger and a portion of the medial aspect of the ring finger are supplied by the segment C8. The lateral part of the hand, the whole of the thumb and a portion of the lateral aspect of the index finger are supplied by the segment C6. The middle portion of the hand, the whole of the middle finger, the major portion of the lateral aspect of the ring finger and the major portion of the medial aspect of the index finger are supplied by the segment C7 (Figs.9.25 & 9.26).

MOTOR SUPPLY.— The muscles that control the movement of the hand are either *intrinsic* (short muscles lying within the hand) or *extrinsic* (the long flexors and extensors of the fingers which take origins in the forearm). It is necessary to examine all the motor functions of the 3 principal nerves to know the level at which the nerve is damaged. This has been elaborately described in the chapter of 'Examination of the peripheral nerve'. In this chapter we shall only discuss the motor deficits of the hand which may occur due to affection of the individual nerve.

In case of *median nerve* palsy there will be (i) inability to abduct the thumb, (ii) inability of opposition of the thumb, (iii) inability of flexion of the terminal interphalangeal joints of the thumb and index finger, and (iv) wasting of the thenar eminence. In case of *ulnar nerve* palsy there will be (i) inability to flex the ring and the little fingers, (ii) inability of adduction and abduction of fingers and (iii) wasting of hypothenar eminence and hollows between the metacarpals. In case of *radial nerve* palsy there will be (i) inability to extend the wrist (wrist drop), (ii) inability to extend the metacarpophalangeal joints of all the fingers and (iii) inability to extend interphalangeal joint of the thumb.

MOVEMENTS.— Both active and passive movements of all the important joints of the hand should be performed to know of various affection of the joints. The following joints are important in the hand —

(i) WRIST JOINT.— The movements of the wrist joint or the radiocarpal joint occur in association with the movement of the midcarpal joints. The active movements of these joints are flexion, extension, adduction (ulnar deviation), abduction (radial deviation) and circumduction. When the wrist is *flexed* both the radiocarpal and midcarpal joints are implicated, though the range of movement is greater at the latter joint. In *extension* the reverse is the case and most of the movement takes place at the radiocarpal joint. The range of adduction is considerably more than that of abduction may be due to shortness of the styloid process of the ulna. In *adduction* most of the movement occurs at the radiocarpal joint. In *abduction* the movement takes place almost entirely at the midcarpal joints. *Circumduction* of the hand results from the movements of flexion, adduction, extension and abduction carried out in that order or in the reverse order.

(ii) CARPOMETACARPAL JOINT of the thumb permits flexion, extension, adduction, abduction and opposition.

(iii) METACARPOPHALANGEAL JOINTS of the fingers permit flexion, extension, adduction and abduction.

(iv) INTERPHALANGEAL JOINTS of the fingers permit only flexion and extension.

Inability of active movement of a joint may be due to involvement of motor nerve supplying the muscles concerned with the movement or due to injury to the tendons of the muscles concerned with the movement. Passive movement of the joint and both active and passive movements of joint will be interfered with in cases of intra-articular pathologies or extra-articular pathologies e.g. sprain of the ligaments, ligamentous adhesions, adhesions of the tendons etc.

INFECTION OF THE FINGERS AND HAND

Infection of the hand can be divided into two major headings — spreading infections and localized infections.

SPREADING INFECTIONS

Lymphangitis.— The organisms gain entrance through a minute abrasion which is often forgotten by the patient. Soon the hand becomes swollen with severe constitutional disturbances like high fever. Hand becomes painful, red, warm and tender. Considerable oedema is the characteristic feature. In fair-skinned person red streaks may be noticed along the lymph vessels. The regional lymph nodes become enlarged and tender. For the lateral half of the hand the axillary nodes become first involved whereas in the affection of the medial half of the hand, the supratrochlear group of lymph nodes will be enlarged.

Cellulitis.— See page 45.

LOCALIZED INFECTIONS

Intracutaneous abscess.— This can also be designated as septic blister. This is often seen on the palmar surface of the digits and the webs. Pus collects within the layers of the skin to elevate the epidermis from the dermis. Sometimes an intracutaneous abscess may communicate with subcutaneous abscess through a small hole and this is called a *Collar-stud abscess.* So during evacuation of pus care must be taken to lay open the deep abscess also.

Paronychia.— The inflammation commences beneath the eponychium. Suppuration usually follows which may burrow beneath the base of the nail. The infection is subcuticular since it is situated entirely within the dermis in which the nail is developed. The infection arises from careless nail paring or from manicurist's unsterile instrument. The diagnosis is obvious on inspection which shows redness and swelling of the nail fold. Excruciating pain on touch is the characteristic feature.

Chronic paronychia.— This condition affects women more often than men and those who do much washing. The onset is insidious (the condition has already existed for months). It seldom follows acute paronychia. On inspection the eponychium is glazed and faintly pink (cf. acute paronychia, where it is angry red). The nail may become cross-ridged and pigmented (cf. acute paronychia in which the nail remains absolutely normal but there may be subungual extension of pus). This condition may be multiple (cf. acute paronychia which is almost always a single lesion).

Apical space infection.— This is a tiny abscess at the tip of the finger just under the nail. Though this condition is exquisitely painful, there is comparatively little swelling. Sometimes this condition is associated with redness extending along one or both the lateral nail folds and to add to fallacy this may be prolonged even into the eponychium. Paronychia is excluded by finding out the area of greatest tenderness which is always just above the distal edge of nail in case of apical space infection. In advanced untreated cases there is likelihood of osteomyelitis of the end of the distal phalanx with possible sequestration and prolonged sinus formation.

SUBCUTANEOUS INFECTIONS

Pulp space infection (Felon).— The term denotes a subcutaneous infection of the terminal segment of a digit. This condition is quite common as the pulp of the finger is subjected to pricks and abrasions. The terminal pulp space of the finger is subdivided into 15-20 compartments

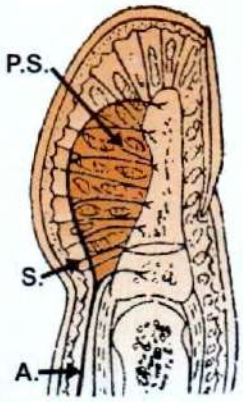

Fig.20.1.— Shows the pulp space 'P.S', which is a closed space bounded proximally by a fibrous septum 'S' at the level of the epiphyseal line of the terminal phalanx. The space is traversed by fibrous strands from the skin to the periosteum and carry blood vessels to the bone. In pulp space infection (Felon) the tension in this closed space becomes increased. The blood vessels are occluded causing necrosis to the distal four-fifths of the terminal phalanx. The proximal one-fifth (the epiphysis) gets the supply from a twig from below the septum and hence not affected by this affection and remains viable althrou-ghout.

by fibrous septa stretching between the periosteum of the phalanx and the skin. These compartments are limited proximally by a transverse septum of deep fascia, which is attached to the base of the distal phalanx at the level of the epiphyseal line. This arrangement has an important bearing on localization and spread of pulp infections. The strong proximal boundary of the fascial compartment acts as an effective barrier to infection spreading proximally up the finger. This leads to increase in tension within the closed compartments which may affect the blood supply of the distal 4/5th of the distal phalanx leading to necrosis of that part of the bone.

This condition starts with pain which increases in intensity very fast and swelling. Soon the pain becomes severe and throbbing in nature. Swelling is maximum at the centre where abscess develops. This condition should be recognized as early as possible and the pus should be drained before the disease has involved the bone. When following drainage of the space, the wound continues to discharge with sprouting granulation tissue at the mouth of the sinus, it is quite certain that necrosis of the terminal phalanx has occurred. X-ray will confirm the diagnosis.

Complications.— (i) Osteomyelitis of the terminal phalanx. (ii) Pyogenic arthritis of the distal interphalangeal joint. (iii) Spread of infection to the flexor-tendon sheath, probably due to the fact that the incision has been wrongly extended proximally to the sheath.

Infection of the middle and proximal volar spaces.— This condition is less common than the preceding one. The pus becomes localized above and below by flexion creases. There is tender induration of the affected space. The finger is held in semi-flexion position. In case of proximal volar space infection, the web space is frequently involved. Middle volar space infection is sometimes difficult to differentiate from suppurative tenosynovitis, the only differentiating feature being relatively pain-free movement of the fingers in case of the former.

Complications.— The infection in these spaces tend to spread to the (i) web space, (ii) interphalangeal joint and (iii) tendon sheath.

Web space infection.— There is only loose fat in the web space. Infection of the proximal volar space or the web space gives rise to considerable swelling with separation of the

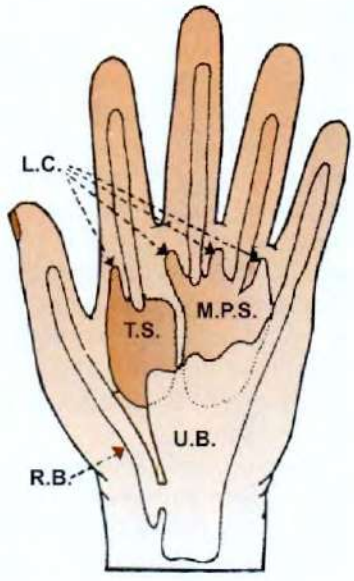

Fig.20.2.— Shows anatomical disposition of the tendon sheaths and fascial spaces. U.B.— Ulnar bursa; R.B.— Radial bursa; T.S.— Thenar space; M.P.S.— Middle palmar space; L.C.— Lumbrical canals.

adjacent fingers. The swelling also spreads to the dorsum of the hand. Maximum tenderness is found on the palmar aspect of the web and on the adjacent bases of the fingers. In untreated cases the pus tends to point under the thinner skin on the dorsal aspect. Gradually the adjacent webs may be involved.

SUPPURATIVE TENO-SYNOVITIS

(Intrathecal Whitlow)

This is an infection of the flexor tendon sheath. The infection is mainly a direct one from a prick of a needle, a thorn or a dorsal fin of a fish. The prick is obviously through the skin overlying the tendon sheath, mostly through a digital flexion crease as at this part the skin surface is remarkably nearer to the sheath. Sometimes this condition may develop from injudicious incision for drainage of the distal pulp space or from spread of infection from the middle and proximal volar spaces. The whole sheath is rapidly involved. The patient feels throbbing pain in the affected digit, the finger becomes red and swollen and the patient's temperature rises. Infection of the thumb or little finger spreads upto the palm to involve the radial or ulnar bursa respectively. The cardinal features of this condition are : (i) Uniform swelling of the whole finger except the terminal segment where there is no tendon sheath. (ii) Typically the finger is held in flexed position. This is an early sign. (iii) Tenderness over the anatomical disposition of the sheath. To determine the area of tenderness the end of a match stick serves the purpose admirably. Accurate localization of tenderness is not possible with the examiner's finger tip which covers too wide an area. Usually the tenderness is most marked at the proximal ends of the sheaths in case of the index, middle and ring fingers. In case of ulnar bursa, a point of maximum tenderness is obtained over the part of the bursa lying between the two transverse palmar creases — *Kanavel's sign.* (iv) The patient is asked to move the fingers. Slight movement of the metacarpophalangeal joint by contraction of the lumbrical and interosseous muscles may be possible but movement of the interphalangeal joint is completely restricted, (v) Any attempt to straighten the finger actively or passively causes exquisite pain.



Fig.20.3.— Infection of the ulnar bursa. See how the hypothenar eminence, the little and the ring fingers are swollen and red.

Complications.— (i) Necrosis of the tendon and adhesion of the tendon with the sheath result in permanent stiffness of the finger in flexed position. (ii) Spread of infection from one tendon sheath to another is not impossible since the ulnar and radial bursae inter-communicate in 80% of cases and occasionally the tendon sheath of the index or the middle or the ring finger communicates with the ulnar bursa.

Infection of the ulnar bursa.— This is probably the most serious of all infections in the hand. The infection may result from a direct spread from tenosynovitis of the 5th finger. The clinical features of this condition are : Flexion of mainly the little finger and other fingers if the sheaths of their tendons communicate with the ulnar bursa, but if the sheath has already ruptured this finding may not be possible. The features are — Fullness of the palm (Fig.20.3); Maximum tenderness towards the ulnar side between the two palmar creases (Kanavel's point) and Oedematous swelling



Fig.20.4.— Shows how to examine for Kanavel's sign. See the text.

of the dorsum of the hand.

Infection of the radial bursa.— In fact true synovitis of the flexor pollicis longus always brings about this condition. This is evident by the fact that swelling of the thumb is seen to extend into the thenar eminence. The thumb is held flexed. Swelling may be seen just proximal to the flexor retinaculum on the lateral side.

INFECTIONS OF THE FASCIAL SPACES

There are a few cellular spaces in the hand as shown in Fig.20.5. In the dorsum, where the importance of these cellular spaces is very much insignificant, there are only two spaces — (i) Subcutaneous (superficial to the aponeurosis extending between the extensor tendons) and (ii) Subaponeurotic (deep to the extensor expansion). In the palm, there are (i) Subaponeurotic space (just deep to the palmar fascia but superficial to the flexor tendon sheath). The space deep to the flexor tendon sheaths is the main cellular space which may becomes infected and is divided into two compartments — (ii) Thenar space (which lies deep to the thenar muscles and superficial to the adductor pollicis) and (iii) Middle palmar space (which is situated deep to the flexor tendons and superficial to the medial three metacarpals and the intervening interossei). These two compartments are separated by a septum which is attached to the 3rd metacarpal bone posteriorly and to the flexor tendon sheath anteriorly between the tendons for the index finger and the middle finger. The septum is obliquely placed. These two spaces are continuous proximally with the Parona's space, which lies in front of the pronator quadratus and behind the flexor tendons.

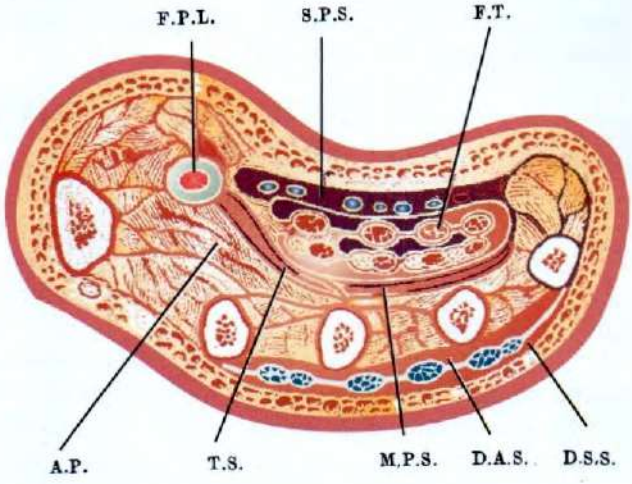

Fig.20.5.— Cross section of the palm showing : F.P.L. — tendon of flexor pollicis longus in radial bursa, S.P.S. — superficial palmar space, F.T. — flexor tendons to all fingers (except the thumb) in ulnar bursa, A.P. — adductor pollicis, T.S. — thenar space, M.P.S. — middle palmar space, D.A.S. — dorsal subaponeurotic space, D.S.S. — dorsal subcutaneous space.

Infection of the subaponeurotic space.— This may follow pricks. The palm looks swollen and tender. The pus often tracks through a point in the palmar fascia to be superficial, forming a Collar-stud abscess.

Infection of the thenar space.— The characteristic feature is the "ballooning" of thenar

eminence. The thumb is held abducted and flexed. The web space between the thumb and the index finger is swollen. This condition should be differentiated from tenosynovitis of the flexor pollicis longus. This can be done by passive extension of the thumb, which is very painful and not allowed in case of the latter.




Figs.20.6 & 20.7.— Showing swollen thenar eminence in thenar space infection. Note that passive extension of the thumb is possible and not painful. This excludes infection of the radial bursa.

Infection of the middle palmar space.— There may not be much swelling of the palm, but obliteration of the normal hollow of the palm is noticed. This is due to the fact that the pus is situated beneath the thick, strong and resistant palmar fascia. Fluctuation is difficult to elicit. The fingers are held in flexion. But their movement and passive extension are not so painful as in the case of tenosynovitis.

It must be remembered that in all infections of the palm there will be considerable swelling on the dorsum. This is because the lymphatics from the palm pass over to the dorsal aspect of the hand and also due to the fact that the skin and subcutaneous tissue on the dorsum are more loose and elastic.

Infection of the Parona's space.— Besides proximal extension of the infection from middle palmar and thenar spaces, this space may be infected in suppurative tenosynovitis. Deep-seated abscess may develop. Fluctuation is difficult to elicit. But brawny induration that pits on pressure suggests abscess formation.

OTHER INFECTIONS OF THE HAND

Carbuncle and **furuncle** may occur on the dorsum of the hand and finger. The clinical picture has been described in detail in page 46.

Verruca necrogenica (Butcher's wart) is caused by inoculation with *Mycobacterium tuberculosis* through an abrasion in the skin. It is seen mostly on the dorsum of the hand. It begins as bluish red patch, later on its surface becomes raised with warty projections. Small pustules surround this warty mass.

Hunterian Chancre of the finger.— This painless indurated ulcer, which is more often seen on the index finger, is a typical Hunterian chancre found anywhere in the body. The regional lymph node is enlarged, which may be supratrochlear lymph node or axillary lymph node.

Dactylitis.— This term denotes infection of the phalanges or metacarpals. Two types are commonly seen — tuberculous dactylitis and syphilitic dactylitis. In tuberculous dactylitis, the affected bone becomes enlarged, spindle-shaped and painful. There is a great tendency to soften, ulcerate or involve the neighbouring joint. X-ray shows osteolytic changes. In syphilitic dactylitis, there is also a swelling but it is painless. X-ray will show sclerosis of bone. Other syphilitic stigmas will confirm the diagnosis.

OTHER LESIONS OF THE HAND

(A) **CONGENITAL DEFORMITIES** include : **Polydactylism** i.e. supernumerary fingers; **Ectrodactylism** i.e. absence of digits; **Syndactylism** i.e. webbing of the fingers; **Macrodactylism** i.e. overgrowth of fingers; *congenital contracture of the little finger;* **Madelung's deformity** i.e. congenital



Fig.20.8.— Polydactylism.

subluxation of the lower end of the ulna.

(B) **ACQUIRED DEFORMITIES.**— **Dupuytren's contracture** — is an affection of the palmar aponeurosis which is thickened and contracted. Usually the ring finger is affected and this condition is more commonly seen in men. Usually a nodule is palpated in the subcutaneous tissue of the palm. Thickened palmar aponeurosis is also felt in certain cases. First the proximal phalanx and then the middle phalanx are flexed but the terminal phalanx remains unaffected since the palmar aponeurosis does not extend to that phalanx (cf. *congenital contracture of the little finger* in which the first phalanx is hyperextended and the 2nd and 3rd phalanges are flexed). The finger can neither be straightened actively nor passively even on flexing the wrist (cf. Volkmann's ischaemic contracture). Its incidence is curiously more in epileptic and cirrhotic individuals. Those, who work with vibratory machines, are more often the victims. It has got an unknown relationship with Paronie's disease of penis and Pellegrini Stieda's disease.



Fig.20.9.— Syndactylism.



Fig.20.10.— Madelung's deformity of the left hand.



Fig.20.11.— Showing Dupuytren's contracture affecting left hand. See the difference with the normal right hand. The little and the ring fingers are affected by contracture. The thickened nodule is shown by an arrow.

Volkmann's ischaemic contracture — is due to vascular injury which result in muscular infarction and subsequent contracture. *In the stage* of *ischaemia* the signs like *p*ain, *p*allor, *p*uffiness (oedema), *p*ulselessness and *p*aralysis {five 'p's) will be seen. Pain on passive extension of the fingers is probably the first sign to appear. The radial pulse is constantly absent and the skin temperature of the affected hand will definitely be lower than its healthy counterpart. *In the stage of contracture* the fingers become flexed but they can be, at least partially, extended when the wrist is flexed

(cf. Dupuytren's contracture in which the affected finger can never be extended).

Congenital contracture of the little finger — is commonly seen during early childhood. It is frequently bilateral. In many ways it mimics Dupuytren's contracture, but absence of thickening of the palmar fascia is the pathognomonic feature of this condition. Moreover the ring finger is rarely involved. The pathology is the contracture of the soft tissues.

Burns contracture can be diagnosed easily by the history itself.

Mallet finger is a typical deformity in which there is persistent flexion of the terminal phalanx. This is due to rupture of the extensor tendon either at its insertion or due to an avulsion fracture of the base of the terminal phalanx.



Fig.20.12.— Volkmann's ischaemic contracture. Fingers can be extended to some extent if the wrist is passively flexed.

Trigger finger is a condition in which the extension of the affected finger becomes difficult and unequal, so that the patient's initial effort does not produce any extension and later on the finger is extended suddenly with a click. This action is more or less like a trigger of a pistol and hence the nomenclature. The middle-aged women are frequently the victims and the most commonly affected finger is the middle or the ring finger. A palpable nodular thickening may develop in the long flexor tendon opposite the head of the metacarpal or there may be a constriction in the tendon sheath which is responsible for this condition. In children this condition may occasionally be seen and the thumb is the most affected finger and is often called 'Snapping Thumb'. An orange-pip like swelling can be felt over the head of the 1st metacarpal bone. Extension is brought about with a click.

Attrition rupture of the extensor pollicis longus is also a condition most commonly seen in middle-aged women. This is usually due to rheumatoid arthritis or occasionally may complicate a Colles' fracture. While working with the thumb suddenly the patient experiences a snap and the thumb falls adducted helplessly and the patient fails to extend the terminal interphalangeal joint of the thumb.

Rheumatoid arthritis of the hand.— The metacarpo-phalangeal joints are most commonly affected, the proximal interphalangeal joints are next to be involved. In the beginning there will be hypertrophy of the synovial membrane of the joints *(Pannus)*. Gradually the overlying skin becomes shiny and atrophic. The affected joints are swollen and become fusiform in shape. Muscle wasting is quite significant. Deformity is the most prominent feature in late cases — (i) *Ulnar drift* is common at the metacarpo-phalangeal joint as the normal line of the pull of the finger tendon is slightly towards the ulnar side, synovial swelling tends to push the extensor tendon medially and in the normal resting posture gravity favours ulnar deviation; (ii) *Swan-neck deformity*, i.e. hyperextension at the proximal interphalangeal joint and flexion at the distal interphalangeal joint, is due to forward subluxation at the proximal interphalangeal joint or attrition rupture of the sublimis tendon or impediment of action of flexor sublimis tendon by synovial swelling; (iii) *Boutonniere deformity*, i.e. flexion of the proximal interphalangeal joint and hyper-extension at the distal, occurs when the middle slip of the extensor tendon undergoes attrition rupture; (iv) *Dropped fingers* is a late feature following rupture of extensor tendons usually at the level of the wrist.

Heberden's Nodes.— These are small long swellings about the size of small peas which are seen at the terminal interphalangeal joints of all fingers except the thumb. It is felt as definite bony ridge across the palmar and dorsal surfaces of the affected joints. These nodes are due to osteoarthrosis, though these do not herald osteoarthrosis of other joints. Women near menopause are usually involved, though males are also rarely involved due to repeated trauma to the finger in games like cricket or baseball and the lesion is almost always solitary in males. Pain is conspicuous by its absence in this lesion.

Barber's Pilonidal Sinus.— Barbers may have interdigital pilonidal sinus at the web space often between the middle and ring fingers of the right hand. Clipped hairs usually have bevelled tips like those of hypodermic needles which may penetrate the skin of the web space which does not have hair follicles. The lesion looks like a black dot at the dorsum of the affected cleft. When palpated with the thumb and index finger, a nodule is palpated. This lesion is liable to be inflamed. In 80% of cases the lesion is multiple. In female hair dressers such lesion may be seen in interdigital clefts between the toes in those who are accustomed not to use stockings particularly in hot climate.



Fig.20.13.— Compound palmar ganglion. Note the swelling above and below the flexor retinaculum.

(C) **SWELLINGS OF THE HAND.**— (i) **Implantation dermoid** is caused by prick by different pointed objects such as needle, bone of a fish etc. The epithelium of the skin is driven in and causes such condition. A soft cystic swelling is found mostly in the finger and occasionally in the hand which is neither attached to the skin nor to the deeper structures. Fluctuation can be elicited.

(ii) **Ganglion.**— This is commonly seen on the dorsum of the wrist or even on its volar aspect. This has been discussed in page 145.

(iii) **Glomus tumour.**— This is a red or violet colour small tumour mostly seen beneath the nail. Considering its size it is an exquisitely tender tumour. The tumour is derived from a glomus body — an arteriovenous anastomosis incorporating nerve tissue. This is believed to help in regulating body temperature. A peculiar characteristic feature is that the tenderness is reduced considerably by applying a sphygmomanometer cuff and inflating it above the systolic blood pressure.

(iv) **Compound palmar ganglion.**— Probably this condition is still a feature of tuberculous tenosynovitis of the ulnar bursa in this country, but in western countries it is mostly associated with rheumatoid arthritis. The main feature is an hour-glass shaped swelling bulging above and below the flexor retinaculum. Cross fluctuation can be elicited from the swelling above and below the flexor retinaculum. With careful palpation one can feel movements of the melon-seed bodies within the bursa.

Chapter

21 EXAMINATION OF THE FOOT

HISTORY.— The patients with problems of the foot can present either with pain or deformity of the foot. When the patient complains of ***pain,*** a careful enquiry must be made as to the site of the pain, onset of the pain and duration of the pain. This is so typical at times that this history itself can give the diagnosis. Pain at the neck of the 2nd metatarsal bone after a long walking is probably due to march fracture (stress fracture). When a young girl complains of pain at the head of the 2nd metatarsal bone whose onset is rather insidious, the condition is probably one of Freiberg's disease. Pain between the heads of the 3rd and 4th metatarsals radiating to the adjacent sides of the toes indicates Morton's metatarsalgia. Plantar fasciitis gives rise to pain on the ball of the heel particularly on walking.

In case of ***deformity*** one should carefully note the type of deformity, its duration and whether it is associated with any other deformity in the body.

PHYSICAL EXAMINATION

INSPECTION.— The patient is asked to stand evenly on both feet and observe if there is any deformity. In talipes equinovarus the forefoot is adducted and points downwards. In pes planus the longitudinal arch is flattened so that the navicular region may be seen bulging. In pes cavus the longitudinal arch is higher than normal. In talipes calcaneovalgus the forefoot looks upwards and abducted. There may be swelling, ulcer or sinus in the foot, which is examined in the usual way as described in the respective chapters.

PALPATION.— When the main complaint is pain, the point of maximum tenderness must be noted carefully. Tenderness beneath the heel may be due to plantar fasciitis or a bony spur underneath the calcaneal tuberosity. Localized tenderness over the back of the calcaneal tuberosity, particularly in boys of about 10 years of age, is usually due to Sever's disease (apophysitis of the calcaneus); this may also be due to bursitis just above the insertion of the tendo Achillis. Tenderness at the neck of the 2nd metatarsal bone after a long march is due to march fracture. Tenderness between the heads of the 3rd and 4th metatarsal bones is due to Morton's metatarsalgia.

MOVEMENTS.— At the ankle joint (talocrural joint) the active movements are dorsiflexion and plantar flexion. In *dorsiflexion* the angle between the front of the leg and the dorsum of the foot is diminished. In *plantar flexion* this angle is increased, the heel is raised and the toes point downwards. A considerable range of rotatory movement is permitted at both talocalcanean (subtalar) joint and talocalcaneonavicular joint. The calcaneus and the navicular carrying the foot with them can be moved medially on the talus and this movement results in elevation of the medial border and corresponding depression of the lateral border of the foot so that the plantar aspect of the foot faces medially and this is called *inversion* of foot. The greater part of this movement occurs at the above-mentioned two joints. The axis of this rotation movement

runs from back of the calcaneus, through sinus tarsi to emerge at the superior and medial aspect of the neck of the talus. The obliquity of this axis accounts for the adduction and slight flexion of the foot that accompany inversion. The opposite movement of this is known as *eversion*, the range of which is much more limited due to tension of the Tibialis anterior and Tibialis posterior and the strong deltoid (medial) ligament of the ankle joint.

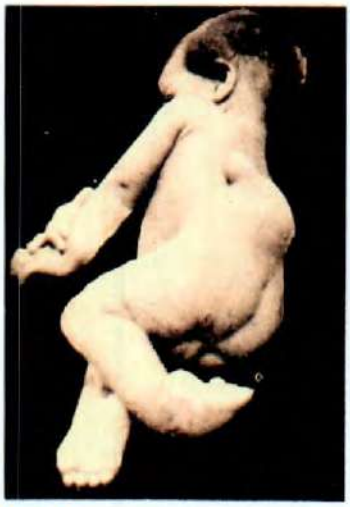

Fig.21.1.— Talipes equinovarus as an accompaniment of spina bifida.

Both active and passive movements of these should be carefully measured to know the excessive limitation of a particular movement. Since flexion and extension take place at the talocrural (ankle) joint, the passive movements of these can be tested by holding with one hand the lower end of the leg and with the other hand the proximal part of the foot so as to include the talus within the hand and both flexion and extension passive movements are tested. In case of *inversion* and *eversion* the passive movements are tested by holding the very lower end of the leg with one hand to fix the talus and then with other hand hold the heel of the foot and then twist the foot medially and laterally. *Adduction and abduction* movements mainly take place in the midtarsal joints and ranges of passive movements are tested by holding the heel with the lower part of the leg with one hand and the forefoot with the other hand and then by adducting and abducting the forefoot one can assess the ranges of passive movements.

NEUROLOGICAL EXAMINATIONS.— Muscle power, sensation and reflexes are examined carefully to note if there is any neurological deficit. Deformity of foot is sometimes due to abnormality affecting spinal column. Talipes equinovarus is often an accompaniment of spina bifida (Fig. 21.1).

EXAMINATIONS OF THE KNEE, HIP AND SPINE.— As has been mentioned earlier that the spinal column must be examined thoroughly to exclude any abnormality there in cases of deformities of the foot. Genu valgus is sometimes associated with pes planus. Limb rotation is also seen to be associated with pes planus. Coxa vara may be associated with some form of deformity of the foot.

SPECIAL INVESTIGATIONS

X-ray examination is quite helpful in the diagnosis of different deformities of the foot as well as to know a few pathologies involving the foot.

DIAGNOSIS

DEFORMITIES of the foot and toes are as follows :

Talipes.— The different types are : (i) *Talipes equinus* — the patient walks on toes. (ii) *Talipes calcaneus* — the patient walks on the heel. (iii) *Talipes varus* — the patient walks on the outer border of the foot (i.e. the sole of the foot looks medially). (iv) *Talipes valgus* — the patient walks on the medial border of the foot (i.e. opposite of talipes varus). (v) *Talipes equinovarus* and *talipes calcaneovalgus* are two common combinations and mixture of two different deformities stated above. Talipes equinovarus is the commoner of the two.

1. **Talipes equinovarus or club foot.**— It is a combination of three elements — equinus,

varus (i.e. inversion) and adduction. The talus points downwards (equinus), the calcaneum faces inwards (varus) and the forefoot is adducted. The *congenital* variety is by far the commoner. This type is recognized by the following points : (i) Present from birth. (ii) usually bilateral, and (iii) presence of a transverse crease across the sole of the medial side. Later on when the child has walked, callosities and bursae develop on the outer border. The *acquired* type is usually unilateral and shows trophic changes in the skin which may be cold and blue. There may be infantile paralysis (the muscles are flaccid and wasted) or spastic upper motor neurone type of paralysis.

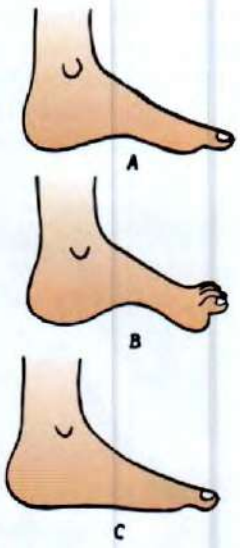

Fig.21.2.— Deformities of the arch of the foot. A. normal foot; B. Claw-foot; C. Flat foot.

2. **Pes planus or flat foot** — is flattening of the longitudinal arch of the foot. Flat foot may be of anatomical or physiological type. *Anatomically* it may be due to (1) External rotation of tibia; (2) Genu valgum; (3) Equinus position of the foot or (4) Varus position of the forefoot. *Physiologically* they are of (1) Congenital variety with vertical talus (boat shaped foot); (2) Infantile flat foot — before the child learns to walk; (3) Middle aged flat foot in case of flabby obese individual; (4) Postural flat foot with weak intrinsic muscles of the foot, with or without other postural defect like kyphosis etc.; (5) Temporary flat foot following long standing chronic illness when the patient first stands on his feet, the feet become flat and the patient complains of 'foot strain' i.e. strain of the inferior calcaneonavicular ligament.

Spasmodic flat foot is absolutely a separate entity due to spasm of peroneal muscles. This is found mostly in 12-16 years old boys. Often it is due to tarsal coalition i.e. presence of abnormal bony or cartilaginous bar extending from calcaneus to talus or navicular bone. Probably the spasm is due to faulty movement of the subtaloid and midtarsal joints.

The diagnosis is made by looking at the medial side of the foot. Instead of the normal concavity, there is flattening or even convexity with prominence of the tarsal navicular. Examine the shoes the patient is wearing. The sole and the heel are worn away more on the inner side and the inner side of the shoe often bulges medially and downwards. There are often two physical signs, viz. limitation of movements of the tarsal joints and localized tenderness over the 'spring' ligament (inferior calcaneonavicular ligament).

3. **Pes cavus or claw foot.**— The deformity consists of a high arched foot with dorsiflexion or even dorsal subluxation of the metatarsophalangeal joints and plantar flexion of interphalangeal joints. The intrinsic muscles of the foot, in this condition, become weak and are overpowered by the long toe muscles. This weakness may be due to neurological disease, myopathy, vascular lesion or idiopathic (probably the commonest). Idiopathic pes cavus is first noticed at the age of 8 to 10 years in an otherwise fit child.

4. **Talipes calcaneovalgus.**— This deformity is quite uncommon and it is important to exclude congenital dislocation of the hip in this condition.

Hallux valgus.— The great toe is abducted at the metatarsophalangeal joint. The inner portion of the head of the first metatarsal bone forms a marked prominence. An adventitious bursa which is liable to inflammation, suppuration and sinus formation may develop. The condition is usually bilateral. The other toes are crowded together and the 2nd toe may be a hammer toe. Metatarsus primus varus is the basic deformity which may be congenital or acquired. In the

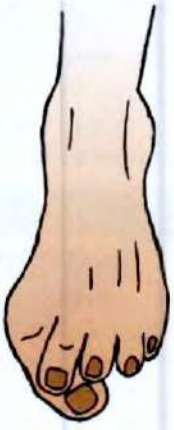

Fig.21.3.— Hallux valgus.

acquired variety generally the middle aged obese person with splayed forefoot may lead to varus deformity of the first metatarsal bone. Shoe, at times, is incriminated for this deformity, as short and pointed shoe may lead to this condition.



Fig.21.4.— Congenital absence of toes of left foot with congenital constriction of the lower leg resulting in a trophic ulcer (shown by arrow). Note also congenital deformities of the fingers.

Hallux rigidus.— This means stiff great toe with painful limitation of dorsiflexion with fixity in the position of slight plantar flexion. This can also be a congenital or acquired deformity. In case of acquired deformity three causes have been found out which may lead to this deformity: (i) The hallux is longer than the 2nd toe so that it may be stubbed repeatedly against the toe cap of the shoe; (ii) Splitting osteochondritis of the head of the first metatarsal bone and (iii) Sesamoid chondromalacia is another possible precursor. The chief complaint is pain on walking especially on rough grounds and slopes. This condition is often bilateral. Adult males are mainly affected but adolescents of either sex are not completely exempt from this condition.

Hammer toe.— The 2nd toe on one or both the feet is commonly affected. Hallux valgus is often associated with this condition. The metatarsophalangeal joint is hyperextended and the proximal toe joint is fixed flexed. A corn or a bursa is often present on the dorsum of the first interphalangeal joint.

Curly toes.— The metatarsophalangeal joints are hyperextended and the toe joints are flexed. Several toes are generally affected. The condition is often bilateral and may be associated with pes cavus deformity. A positive family history is often elicited. Painful callosities may develop on the dorsum of the toes.

Rare congenital deformities.— There may be superneumarary toes, *absence of toes* (Fig. 21.4), *bifid foot,* overlapping 5th toe etc. These are often associated with congenital deformities of the fingers.

SWELLINGS.— *Corns* and *callosities* occur at the sites of intermittent pressure. A corn consists of a conical wedge of highly compressed keratotic epithelial cells. This occurs over a very limited area and impinges on the nerve endings. This gives rise to pain. A callosity on the other hand is distributed over a comparatively large area. This is nothing but a greatly thickened and cornified skin which ceases at the periphery where it is being continued with the normal skin.

A *soft corn* occurs where the skin is macerated between the toes. This is commonly seen in the cleft between the 4th and 5th toes where the soft skin is subjected to pressure between the bases of the proximal phalanges.

Plantar wart is commonly seen on the weight-bearing portion of the sole. These warts are dark and exquisitely tender. These differentiate this condition from corn or callosity. When seen through magnifying glass, one may find



Fig.21.5.— Squamous cell carcinoma affecting the fore-foot.

red or black spots which are haemorrhages from attenuated fronds of the submerged papillomas.

A *ganglion* is more or less similar to that found in the hand and wrist.

A *bursa* superficial to the tendo Achillis may be enlarged due to inflammation.

Swelling of the ankle joint may be due to *effusion* in the joint.

Other causes of swellings of the foot are the ***tumours*** affecting the foot. Of the tumours the commonest is malignant melanoma followed by squamous cell carcinoma. *Malignant melanoma* occurs mainly on the medial aspect of the sole where the skin is relatively soft. The swelling is asymptomatic in the beginning. Pigmentation and ulceration are the usual features. Regional lymph nodes are always enlarged and occasionally the liver may be involved by metastasis. *Squamous cell carcinoma* on the other hand affects the weight-bearing areas of the forefoot where the skin is relatively hard. Due to pressure of the weight the tendons and bones are soon infiltrated and the tumours become fixed to the deeper structures.

ULCERS.— Ulcers of the foot are more often seen in tropical countries and are caused by various infective agents. Of these ***tuberculosis*** is by far the commonest. Besides these infective ulcers, one may come across ***perforating ulcers*** in denervated sole. These are mainly situated on the weight-bearing zones, such as ball of the great or little toe or heel. These ulcers are usually surrounded by indurated skin and the ulcers tend to perforate right up to the bone justifying its nomenclature. Ulcers may develop from *ingrowing toe-nail* and *subungual exostosis* due to repeated friction of the skin against the nail or the bony exostosis. The surface becomes granulating.

Madura foot is a tropical disease caused by mycotic infection. This condition commonly affects persons who move about bare-footed and in the great majority of cases infection is introduced by prick of a thorn. Firm, painless and pale nodules develop on the foot. They increase in size and gradually vesicles appear on the surface of the nodule. Each vesicle bursts and a sinus develops which discharges purulent mucoid fluid containing the characteristic tiny granules. Lymphadenitis is conspicuous by its absence. Gradually the nodules infiltrate the underlying structures such as muscle, bone etc. Tendons and nerve tissues are resistant to invasion. Blood borne dissemination is also absent. Lymphadenitis may occur from secondary infection. This condition mimics actinomycosis.

The other rare cause of ulcer in the foot is ***Kaposi's sarcoma.*** This is commonly seen in the Jews, Italian and Eastern Europeans. Males in the middle of their lives are more susceptible to this condition. Multiple, painless, plum-coloured nodules particularly affecting the lower extremities are the characteristic features of this condition. The last but not the least is the ***malignant melanoma*** in the list of causes of ulcer of the foot.



Fig.21.6.— Perforating ulcer.

INFECTIONS OF THE FOOT.— By this we mean pyogenic infection of the foot and in many respects this is similar to that of the hand. In the sole, there are the *superficial plantar space* and *deep plantar space* lying superficial and deep to the plantar aponeurosis respectively.

Infection of the superficial fascial space is mainly seen in (i) the sole of the foot (in those who walk bare-footed), (ii) the web space, (iii) Interdigital subcutaneous space and (iv) the heel space.

Infection of the deep fascial space.— There are three deep fascial spaces in the sole — medial, central and lateral. The medial and lateral spaces are less important and are rarely infected. The

central plantar space is divided into four compartments between the five layers of the muscles. The diagnosis is made by the history of a penetrating injury, pain, tenderness and swelling. The swelling becomes more prominent on the dorsum even if the pus is situated under the sole.

DEFORMITIES AND LESIONS AROUND NAILS.—

Ingrowing Toe-Nail.— This occurs due to excessive lateral growth of the nail into the nail-fold may be due to trimming of the corners of the nail. The sharp lateral edge of the nail digs into and lacerates the nail-fold. Infection starts here and recurrent attacks of painful acute and subacute paronychia continue. Gradually the resulting granulation tissue may protrude. Usually the great toe is involved.





Figs.21.7 & 21.8.— MRI showing tuberculous cavity of the calcaneum with a track through which cold abscess is burrowing superficially and if allowed to burst a sinus will form. Note how MRI is helpful in locating the track so that proper surgery can be performed to excise the track and the tuberculous cavity.

Onychogryphosis (Ram's Horn Nail).— This is a condition in which usually nail of the great toe becomes thickened, crooked and over-grown. The cause is oft repeated trauma or fungus infection. Usual victims are bedridden old people.

Subungual exostosis.— It is an exostosis growing from the dorsal aspect of the distal phalanx and pushes the nail upwards which becomes discoloured. At this stage this condition becomes painful and results in deformity of the displaced nail which gradually splits and becomes a source of infection with severe pain. Ultimately the nail breaks away and the exostosis reaches the surface only covered with a mass of granulation tissue.

Onychomycosis.— This condition, which is a fungus affection of the nail of the great toe, mimics the early stage of the previous condition. It is a rare entity in which the nail becomes brittle, discoloured and split longitudinally at several places.

Subungual Malignant Melanoma.— A malignant melanoma sometimes grows as a pigmented nodule beneath a nail or nail groove. In a matter of months the nail is lifted up and eventually

lost due to quick proliferation of the growth. Ultimately the growth ulcerates and becomes secondarily infected. Though it retains its characteristic brown-black colour, occasionally it may be colourless *(amelanotic melanoma)*.

Glomus tumour — may occur below the tip of a toe nail as finger and is discussed in detail in pages 44 and 319.

PAIN IN THE FOOT

Pain in the foot can be classified according to the region affected.—

A. Pain in the heel; B. Pain in the mid-foot or C. Pain in the fore-foot.

A. **Pain in the heel.**— This can be subdivided into (a) *pain within the heel* e.g. fracture or disease of the calcaneum (osteomyelitis or tumour or Paget's disease) and arthritis of the subtaloid joint; *(b) Pain behind the heel* e.g. tendo Achillis bursitis, retrocalcaneum bursitis, apophysitis of the calcaneum (Sever's disease) and rupture and paratendinitis of the tendo Achillis; and (c) *Pain beneath the heel* e.g. infracalcaneum bursitis and plantar fasciitis (Policeman's heel).

Calcanean spur.— This is usually revealed in X-ray and is a bony projection forwards from undersurface of the calcaneal tuberosity. It is nothing but ossification of the plantar fascia at its calcaneal end. This has very little significance so far as the pain in the heel is concerned. That means if a patient complains of pain in the heel and on X-ray one can find the presence of calcanean spur, the clinician cannot infer that the calcanean spur is the cause of pain. Very often inflammation of the soft tissue or a bursa beneath the spur gives rise to pain.

B. **Pain in the mid-foot.**— A *strain on the inferior calcaneonavicular ligament* (spring ligament) occurs when the foot flattens rapidly due to weakness of the short muscles of the sole or after a prolonged confinement in the bed. *Kohler's disease* (osteochondritis of the navicular bone) is another cause of the pain in the mid-foot. The usual victim is the child under 5 years of age. Painful limp and tenderness over the navicular bone are the diagnostic considerations, the navicular bone becomes dense with altered shape. An *"overbone"* connecting the dorsal surfaces of the medial cuneiform and the base of the 1st metatarsal bone gives rise to pain in the mid-foot. A tender and bony lump just proximal to the base of the 1st metatarsal bone is the diagnostic feature of this condition.

C. **Pain in the fore-foot or metatarsalgia.**— (a) DISORDERS OF THE FOOT may give rise to pain in the fore-foot e.g. splay foot associated with hallux valgus, curly toes, a claw-foot with claw toes etc. (b) DISORDERS OF INDIVIDUAL TOES e.g. hallux valgus, hallux rigidus, ingrowing toe-nail, hammer toe etc. (c) SPECIAL VARIETIES OF METATARSALGIA : This includes (i) *Freiberg's disease.*— This is nothing but crushing type of osteochondritis affecting the head of the 2nd or 3rd metatarsal bone. It is generally seen in young adults and girls predominate. A bony lump or irregularity is palpable which is tender and the affected joint becomes irritable. X-ray shows dense and the flattened epiphysis, increase in joint space and a thick neck (similar to what is seen in Perthes' disease).

(ii) *Morton's metatarsalgia.*— This is a fibroneuroma affecting usually the 3rd digital nerve just before its division into two branches. Middle-aged women are more often affected. Sharp intermittent pain shoots into the affected toes. Sensation may be diminished in the adjacent toes. Localized tenderness can be elicited over the neuroma. Relief is obtained by taking the shoe off and squeezing or massaging the fore-foot.

(iii) *March or stress fracture.*— This usually affects the 2nd or 3rd metatarsal bone. It occurs in young adults after unaccustomed long walking. Swelling and tenderness may be felt on the dorsum of the affected metatarsal bone. X-ray appearance is at first normal but later on one may find a fusiform callus around a fine transverse fracture in about 2 to 3 weeks time.

Chapter

22 EXAMINATION OF THE HEAD AND FACE

The clinical examination of swellings and ulcers on the head and face is carried out as discussed in the general chapters. Here differential diagnosis of various lesions of the head and face are discussed below :

DIFFERENTIAL DIAGNOSIS



Fig.22.1.— Hydrocephalus.

CONGENITAL LESIONS.— ***Hydrocephalus*** is a condition of excess of cerebrospinal fluid in the cranium, commonly due to failure of development of the arachnoid villi through which absorption takes place. There is often a huge enlargement of the head with widening of the anterior fontanelle which normally becomes obliterated between 15th and 18th months. The eyes are bulging and looking downwards (Fig. 22.1). ***Meningocele*** (protrusion of the meninges), ***encephalocele*** (protrusion of the brain) or ***meningo-encephalocele*** (protrusion of the meninges as well as the brain) are sometimes met with at the root of the nose, the occipital region or anterior fontanelle. They are diagnosed by their typical situation (in the



Fig.22.2.— Meningocele at the occiput.





Figs.22.3. & 22.4.— Meningocele at the root of the nose. In the second figure an impulse on coughing is felt.



Fig.22.5.— A typical case of unilateral hare lip.

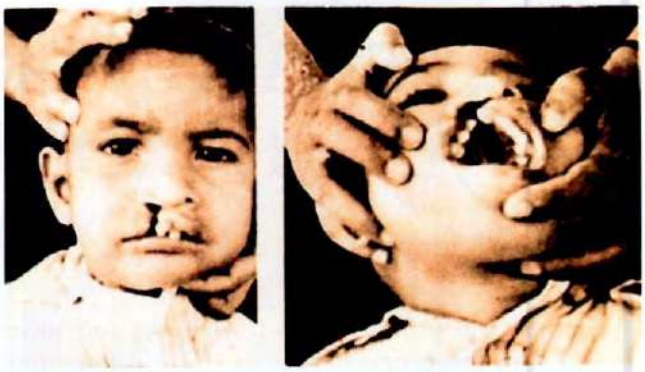

Figs.22.6. & 22.7.— Unilateral cleft lip with cleft palate.

midline), impulse on coughing (crying in case of children) and translucency. ***Dermoid cysts*** occur in the line of ectodermal fusion. They are commonly met with just above the outer canthus of the eye, behind the ear (post-auricular dermoid cyst) and in the midline. Clinically they are cystic, free from the skin but are often fixed to the underlying skull in which a saucer-shaped depression with a peripheral ridge may be felt. ***Cleft (hare) lip*** (Fig. 22.5) is due to failure of union of the medial nasal process with the maxillary process. It may be unilateral or bilateral. The latter condition is frequently associated with forward displacement of the premaxilla and cleft palate. ***Cleft palate*** results from failure of the two



Fig.22.8.— Bifid nose.



Fig.22.9.— Macrostoma. Note the nodules in front of the pinna — another developmental anomaly.

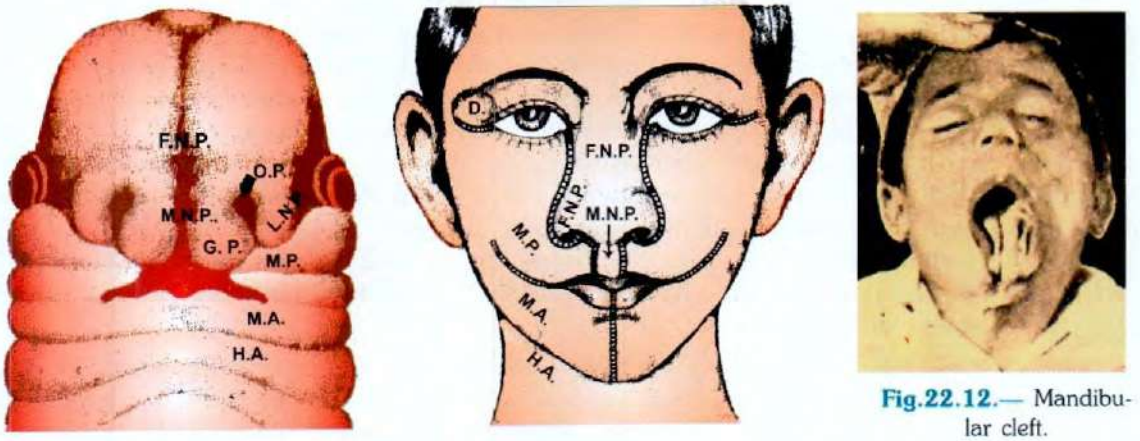

Figs.22.10. & 22.11.— Show the development of the face. F.N.P.— Frontonasal process; M.N.P.— Medial nasal process; L.N.P.— Lateral nasal process; O.P.— Olfactory pit; G.P.— Globular process; M.P.— Maxillary process; M.A.— Mandibular arch; H.A.— Hyoid arch; D.— Dermoid cyst at the commonest site.

Fig.22.12.— Mandibular cleft.

palatine plates of the maxillary processes to fuse together and with the premaxilla developed from the frontonasal process. Note whether the nasal septum is hanging free or is attached to one side of the cleft. ***Bifid nose*** (Fig. 22.8) is a developmental curiosity in which one half of the frontonasal process remains isolated from the rest. If the lateral nasal process fails to unite with maxillary process, a fissure known as ***facial cleft*** will be evident extending from the upper lip to the inner canthus of the eye along the side of the nose. ***Macrostoma***, or abnormally large size of the mouth, results from imperfect union of the maxillary process with the mandibular arch. ***Macrocheilia*** or hypertrophy of the lip is usually congenital but may be due to lymphangiectasis. ***Mandibular cleft*** is a very rare abnormality in which the mandibular arch fails to unite with its fellow in the midline. ***Pre-auricular sinus*** develops from imperfect fusion of the 6 tubercles which form the pinna. This sinus generally opens at the root of the helix or on the tragus. The track runs downwards and ends blindly. At times the mouth of the sinus becomes closed, a cyst develops and becomes infected. Later on it may burst and an ulcer develops. This ulcer refuses to heal as infection is maintained within the sinus. ***Congenital short frenum of the upper lip*** may be seen with a wide gap between the permanent incisor teeth. ***Congenital fistulae of the lower lip*** are rarely found as two blind pits one on either side of the midline. These are wide-open mucus secreting glands which are found in certain quadrupeds.



Fig.22.13.— Cancrum oris.

TRAUMATIC LESIONS.— Haematoma and fracture are the two main traumatic causes of swellings in this region. Details of fractures which may occur in skull bone have been mentioned in the chapter of 'Head Injury'. Fractures of facial bones are not quite common and do not come in the domain of such book. **Haematoma of the scalp** quite commonly occurs in head injury. Such haematoma usually occurs in either in the second connective tissue layer of the scalp or in the 4th layer which consists of loose areolar tissue of the scalp.

While bleeding in the second layer of the scalp above the galea aponeurotica is a localized haematoma, haemorrhage in the 4th layer of the scalp below the galea aponeurotica (subaponeurotic) spreads considerably and is limited posteriorly by the attachment of the aponeurotic layer with the occipital region of the skull, laterally by the zygomatic arch, but anteriorly this aponeurosis has no bony attachment so blood may track into the root of the nose and the eye-lids. **Cephal haematoma** (subpericranial haematoma) occurs due to accumulation of blood beneath the pericranium. It is commonly seen in the parietal region often following forceps delivery. It may also occur alongwith fracture of the skull. It forms a localized swelling being limited to the affected bone bounded by its suture lines. The swelling is soft and fluctuant but is not translucent. The swelling gradually disappears over a period of weeks or months.

INFLAMMATORY LESIONS.— ***Pott's puffy tumour*** is nothing but localized pitting oedema of the scalp over the cranial bone which has been affected with osteomyelitis. Acute localized pain, localized tenderness and swelling over the affected bone are the clinical features of this condition. Extradural abscess may develop in the deeper aspect. ***Boils, carbuncles, cellulitis*** and ***erysipelas*** are quite common in the head and face. The serious complication of such infections is the cavernous sinus thrombosis. The infection spreads (i) along the angular vein to the ophthalmic vein — a tributary of the cavernous sinus or (ii) along the deep facial vein which communicates with the cavernous sinus through the pterygoid plexus of veins passing through the foramen ovale and foramen lacerum. Diagnosis of such complication is made by noting severe constitutional disturbances, proptosis, squint and paralysis of the ocular muscles, especially the rectus lateralis which is supplied by the abducent nerve. The nerve is situated in the interior of the cavernous sinus in contradistinction to the 3rd and 4th cranial nerves which lie on the lateral wall of the cavernous sinus.



Fig.22.14.— Haemangioma of the lip.

Cancrum oris (infective gangrenous stomatitis) (Fig. 22.13) occurs more often in debilitated children after long-continued typhoid fever or kala-azar.

ULCERS.— ***Lupus vulgaris*** (cutaneous tuberculosis) is a chronic ulcer found in the face in tropical countries. ***Rodent ulcer*** is commonly found in the face particularly above the line joining the angle of the mouth to the tragus of the ear. ***Actinomycosis*** rarely affects the lower jaw and may cause multiple sinuses of the face with surrounding induration discharging pus with sulphur granules. Lymph nodes are usually not involved. In the lip, the commonest cause of ulcer is ***carcinoma of the lip***. ***Extragenital chancre*** or ***mucous patches*** or ***condylomas*** (manifestations of syphilis) may be seen in the lip.

TUMOURS and **CYSTS.**— Benign and malignant tumours originate from the skin, subcutaneous tissue or bone.

Benign tumours, e.g. papilloma, lipoma (subcutaneous and subpericranial), haemangioma, cirsoid aneurysm, neurofibroma, osteoma and osteoclastoma may be seen. ***Haemangioma*** is quite common in the face. Capillary haemangiomas are more common which are discussed in chapter

3 of 'Examination of a Lump or a Swelling'. Plexiform haemangioma or arterial haemangioma or cirsoid aneurysm is almost only seen in the face particularly in the forehead. It is nothing but a network of a dilated interwoven arteries commonly affecting the superficial temporal artery and its branches. It feels like a bag of pulsating earthworms in the forehead. The overlying skin may be thinned out with loss of hair. This tumour enlarges slowly. Occasionally there may be ulceration of skin over this haemangioma which may lead to serious haemorrhage. X-ray of the skull almost always shows erosion and occasionally there may be perforations in the skull due to intracranial extension of such haemangioma being connected with dilated tortuous vessels in the extradural space. ***Osteoma*** particularly sessile type (compact osteoma or ivory exostosis) is a tumour commonly seen affecting the outer table of the skull. The frontal, parietal and occipital bones are often involved. Very occasionally this tumour may originate from the inner surface of the skull when it may give rise to focal epilepsy. This osteoma is known for its stony hard consistency. The adolescents or young adults are the common victims and the presenting symptom is the hard painless lump.

Among **malignant tumours** squamous cell carcinoma, malignant melanoma, osteosarcoma and secondary carcinoma in the skull may occur. Ectopic salivary tumour may be rarely seen particularly in the lip of a young adult male. A tumour arising from the skin or subcutaneous tissue can be moved freely over the bone. Skin can be moved freely over the tumour which is arising from subcutaneous tissue or bone. ***Cylindroma*** (Turban tumour) occurs very occasionally in the scalp involving whole of it and that is why it is also known as 'Turban tumour'. It forms a red, lobulated swelling, which grows slowly. It is considered to be a type of basal cell carcinoma, though a few pathologists are of the opinion that it is an endothelioma. But it is definitely a locally malignant tumour. It is almost always associated with alopecia of the area affected. ***Secondary carcinoma*** is not uncommon tumour of the skull. Though skull is not a very common site of bone involvement of secondary carcinoma, yet of the tumours of the skull secondary carcinoma is one of the common tumours. It is usually caused by blood borne metastasis and it commences in the diploe. It presents as solitary or multiple swellings of the skull. The consistency varies from stony hard to very soft depending on its vascularity. Soft and very vascular metastases often show pulsation presenting as pulsatile swelling.





Figs.22.15 & 22.16.— Squamous cell carcinoma of the lip. In the first figure note the 'kiss lesion' affecting the upper lip as well.

Paget's disease of the skull.— Though it is not a tumour or cyst but this malformation syndrome of bone often affects the skull. This condition almost always affects the skull and the skull enlarges so that the patient often requires a bigger hat after certain time interval. This disease usually affects old individuals above 40 years and males are more often affected. Pain is often an important symptom. The thickened cranial bones are sometimes quite vascular so as to produce systolic bruit on auscultation.

Among the **cysts**, ***sebaceous cysts*** occur quite frequently in the scalp and face. They may

suppurate and ulcerate to give rise to *Cock's peculiar tumour* (this looks like a squamous cell carcinoma). *Mucous cysts* are often found on the mucous surface of the lip and cheek (these are recognized by their blue colour and translucency). ***Dermoid cysts*** are discussed earlier.

SOME CHARACTERISTIC FACIES.— In a few surgical conditions the face of the patient assumes a characteristic appearance. These are discussed below :—

The hippocratic facies.— This characteristic facial appearance is almost pathognomonic of advanced diffuse peritonitis. The eyes are sunken, but bright, the nose is pinched. The forehead is cold and clammy. There are crust on the lips. The tongue is dry and shrivelled. It is in fact due to dehydration rather than peritonitis that the appearance of sharp nose, hollow eyes and collapsed temples are produced. But when this facial appearance is combined with thready pulse and a grossly distended abdomen, the condition is nothing but an advanced case of diffuse peritonitis.

The facies of hepatic cirrhosis.— The eyes are sunken and there is variable degree of icterus present in the watery conjunctivae. There is also presence of spider naevi and all these indicate a moderately advanced case of hepatic cirrhosis.

The adenoid facies.— A high arched palate, narrow dental arch and protruding incisor teeth are the characteristic features found in a patient with enlarged adenoids. However this concept has been challenged nowadays and these features are not considered to be pathognomonic of enlarged adenoids.

The moonface of Cushing's syndrome.— The face becomes round shaped like a full moon and often the lips are pursed in a case of Cushing's syndrome.

The facies of cretinism.— The face is pale, puffy and wrinkled. The skin is dry and cold. The tongue is protruded. The anterior fontanelle remains open. The thyroid gland may or may not be enlarged. This is the characteristic appearance of a case of cretinism.

Carcinoid facies.— This occurs when a carcinoid tumour metastasises in the liver and excess of serotonin is secreted. This condition produces characteristic facial flushing, which is known as carcinoid facies.

Chapter

23 EXAMINATION OF THE JAWS AND TEMPOROMANDIBULAR JOINT

THE UPPER JAW

Maxilla, which constitutes the upper jaw has got **5 surfaces**. These surfaces are examined systematically.

(1) ***Anterolateral surface (superficial surface).***— It is most obviously available for examination. The condition of the skin is noted. The upper lip is everted to expose a portion of this surface. When a swelling is present, examine it with a finger.






Figs.23.1 to 23.4.— Examining the orbital, superficial, palatine and nasal surfaces of the maxilla. In the last figure the patient has been asked to breathe through the naris of the affected side while his other naris and mouth are kept closed. Any obstruction present is thus demonstrated.

(2) ***Superior surface (orbital surface).***— This surface constitutes the floor of the orbit. The inferior orbital margins of both sides are palpated and note any difference in sharpness and level. If this surface is bulged upwards, it causes proptosis and diplopia. One may have a glance at each profile of the patient in order to consider relative protuberance of the eyeball.

(3) ***Inferior surface (palatine surface).***— The patient is asked to open his mouth. Note if there is a swelling. It is examined in the usual manner. The nasopharynx is also examined. The teeth are examined. If there is any missing tooth, careful examination may reveal an odontome.

(4) ***Medial surface (nasal surface).***— This forms the lateral wall of the nostril. The patient is asked to blow through his nose occluding the nares one at a time. If the nostril on the affected side is not blocked, it is obvious that the medial wall of the maxilla is not bulging to any great extent. This surface can only be seen with the help of a nasal speculum. The patient should be asked if any discharge is coming out through the nostril of the affected side. Whether the discharge is purulent or sanguineous? Constant overflow of tears from the eye (epiphora) indicates obstruction of the nasolacrimal duct.

(5) ***Posterior surface.***— The surface forms the anterior boundary of the pterygopalatine fossa and is absolutely beyond our reach. Only extension of the growth from this surface may firstly be felt in the infratemporal region. So this region must be palpated before completion of the palpation of the surfaces of the maxilla.

While examining these surfaces, if any **swelling** or **ulcer** is discovered, examine it in the usual way. When there is a growth arising from the mucoperiosteum, i.e. **epulis**, note whether it is sessile or pedunculated, soft or firm, bleeds easily during palpation or not.



Fig.23.5.— Fibrous epulis from the mucoperiosteum of the upper jaw.

If there is any tenderness in the maxillary antrum without any distension of its wall, it may suggest empyema of the antrum. This of course may be associated with unilateral purulent nasal discharge. This is confirmed by anterior rhinoscopy, posture test, transillumination, X-ray and aspiration of the antrum through the inferior meatus.

The **teeth** should be count. Dental cyst is frequently associated with caries tooth. Dentigerous cyst is invariably associated with unerupted permanent tooth.

The **cervical lymph nodes** must always be examined, particularly the submandibular group. Any inflammatory lesion or carcinoma will lead to enlargement of the regional lymph nodes. But sarcoma of the upper jaw does not lead to enlargement of the regional lymph node.

The 2nd division (maxillary division) of the 5th cranial nerve **(trigeminal nerve)** is always tested for its integrity. This nerve and its branches are likely to be involved when the growth extends backwards and upwards.



Fig.23.6.— Dentigerous cyst. Skiagram of this patient showed two unerupted teeth.

THE LOWER JAW

When there is a history of trauma look for evidence of **fracture of the mandible**. When the patient tries to support the fragments with his hands, speech is impossible and when the saliva is blood-stained (as the fracture of the mandible is nearly always *compound* into the mouth), one may suspect the case is one of fracture of the mandible. The intimately adherent mucoperiosteum always gives way in case of fracture of the mandible to make the fracture compound. Majority of the fractures of the mandible occur in the horizontal portion (at the region of the canine tooth as the bone is weak due to deep canine socket). Contour of the alveolus is carefully noted as also alignment of the teeth. Loss of continuity of the lower border and crepitus leave no doubt about the diagnosis. When the fracture occurs above the angle of the mandible the diagnosis may not be made with certainty. But swelling at the site of fracture, localized tenderness and skiagraphy help to make the diagnosis.

The body, the angle and the inferior part of the ramus are accessible to the palpating fingers. Examination can be done both from without and from within the mouth. *Bimanual palpation* i.e. one finger inside the mouth and fingers of the other hand applied externally can



Fig.23.7.— Adamantinoma of the lower jaw.



Fig.23.8.— Bimanual palpation of the lower jaw.

palpate comparatively inaccessible portion of the mandible. In case of **swelling** enquire particularly its duration. A long history of a slow growing large tumour would suggest adamantinoma. The swelling is examined in the usual way, noting its position, size, shape, consistency (whether uniform or variable), pulsation, egg-shell crackling, mobility etc.

Examine the **lymph nodes** of the neck particularly the submandibular lymph nodes.

THE TEMPOROMANDIBULAR JOINT

The patient is asked to open and close his mouth. Normally one can open the jaw to the extent of 2-5 cm distance between the upper and lower incisor teeth. Place the fingers over the joint just below and in front of the tragus to appreciate the movements of the condyle and to feel if there is any crepitus (as in osteoarthritis) or clickling (as in a loose meniscus). One may auscultate with a stethoscope placed over the joint to know more about crepitus and click.

Ankylosis of the mandibular joint is evident by restriction in opening the mouth. False ankylosis may be seen in osteoarthritis or fibrosis resulting from virulent infections like cancrum oris.

The patient sometimes cannot open his mouth because of muscular spasm which is known as ***trismus.*** Severe trismus may complicate any imflammatory process or painful condition in the neighbourhood of the joint. Erupting 3rd molar tooth (wisdom tooth), a dental abscess or parotitis may cause trismus. Trismus is also seen in tetanus with a characteristic facies — risus sardonicus (painful smiling appearance).

Displaced articular cartilage of the temporomandibular joint may lead to clicking jaw. This condition occurs more in females and in the first instance the patient hears snap in the ear and subsequently almost every time she opens her mouth, a click can be heard. Locking of the jaw occurs suddenly when the patient opens her mouth during yawning and fails to close the mouth. This is accompanied by pain which radiates to the pinna.

Dislocation of the temporomandibular joint can be either bilateral or unilateral. In case of bilateral dislocation, the mouth is open and fixed, a prognathous deformity may be evident. In case of unilateral dislocation, the partially opened jaw is deviated to the opposite side. A small hollow can be felt just behind the dislocated condyle. In a suspected case, a little finger is inserted into the external ear with the pulp directed forwards. The movement of the condyle will not be felt on the dislocated side when the mouth opens and closes.

SWELLINGS OF THE JAW

A. Arising from mucoperiosteum, i.e. **Epulis** : (i) Granulomatous; (ii) Fibrous; (iii) Sarcomatous; (iv) Myelomatous; (v) Carcinomatous.

B. Arising from the tooth germs, i.e. **Odontomes** : (i) Dental cyst; (ii) Dentigerous cyst; (iii) Adamantinoma. Rare varieties of odontomes are : fibrous odontome, cementoma, radicular odontome, compound follicular odontome and composite odontome.

C. **Osseous tumours** : See the list in Page 163.

D. **Inflammatory group** consisting of (i) Alveolar abscess, (ii) Osteomyelitis; (iii) Actinomycosis etc.

DIFFERENTIAL DIAGNOSIS

Epulis means 'upon the gum'. There are several types : *Granulomatous* (or false) type is a mass of granulation around carious tooth. *Fibrous epulis* is the commonest and is a slow-growing firm growth (Fig. 23.5). It arises from the periodontal membrane. It is red, firm, sessile or pedunculated lesion. Although it is benign yet it has a tendency to recur after operation, if its root is not thoroughly excised. *Sarcomatous epulis* is differentiated from the fibrous type by its more rapid growth, softer feel and bleeding more readily. It is bluish red in colour and of varying consistency. *Myelomatous epulis* or periosteal osteoclastoma produces a sessile swelling, soft, lobulated purplish in colour. Egg-shell crackling may be palpated, regional lymph nodes are not enlarged and in X-ray typical soap-bubble appearance is produced. It may undergo malignant change — malignant myelomatous epulis, which is characterized by bleeding on touching and ulcer formation. *Carcinomatous epulis* — an undesirable term given to epithelioma — is not uncommon in the gum. It is an infiltrating lesion around the tooth or its socket which may invade the bone, ulcerate or fungate. There is always lymph node enlargement.

Odontomes.— In the development of the tooth, downward extension of epithelium takes place which later forms the enamel organ. A cluster of this epithelium persists as '**epithelial debris**' from which the epithelial odontomes are formed, e.g. dental cyst, dentigerous cyst and adamantinoma.

DENTAL CYST (Radicular or Periapical cyst).— This condition occurs in association *with a carious tooth* and develops at the apex of the tooth with necrotic pulp. Once the cyst develops, it enlarges slowly by resorption of adjacent bone and expansion of the jaw. It usually affects the upper jaw, where it tends to enlarge to fill the maxillary sinus. In case of lower jaw, if untreated, it involves greater part of the body of the mandible even including the ramus. There may be 'egg-shell crackling' when the bone is thinned out or it may even elicit fluctuation when the bone is completely destroyed. The fluid within the cyst is clear and may contain cholesterol crystals. X-ray is helpful in diagnosis.

DENTIGEROUS CYST (Follicular Odontome).— It is associated *with unerupted permanent tooth*. This develops from enamel epithelium from the surface of the crown of an unerupted tooth with

accumulation of fluid inside it. This cyst also enlarges like the dental cyst. The unerupted tooth is displaced deeper by the cyst thus preventing its eruption. The crown of the tooth protrudes into the cyst cavity and the cyst lining is attached around the neck of the tooth. The upper or lower third molar tooth is usually affected. The cyst contains viscid fluid and unerupted tooth. It may also produce egg-shell crackling on palpation. Condition is confirmed by X-ray.

ADAMANTINOMA (Multilocular cystic disease or ameloblastoma).— It gives rise to a multilocular cystic swelling commonly occurring in the lower jaw (Fig. 23.7). Differentiation from osteoclastoma is really difficult even by skiagraphy as both these conditions cause expansion of bone with trabeculae in the interior. But it more looks like a honey-comb. Adamantinoma is a more slow-growing tumour but locally malignant. Usual victims are between 20 to 30 years of age. Almost always the mandible is affected and the tumour expands at the cost of the outer table.

Solitary bone cyst.— This resembles solitary bone cyst of long bone. It usually involves the premolar or molar region of the mandible. In the beginning the bone cavity is round and oval, but it gradually bulges outwards in a lobulated fashion. Histological examination reveals bone resorption and certain amounts of bone deposition at the periphery. Complication like haemorrhage inside the cyst is quite common from the thin walled vessels in the wall. That is why in aspiration the fluid looks yellow containing high bilirubin level. Unlike fluid from other jaw cyst, it will clot.

Giant-cell granuloma.— This lesion usually occurs centrally in the jaw either in the mandible or in the axilla. It presents as a lobulated tumour. It often erodes through the cortex and is covered by a thin layer of subperiosteal new bone. The roots of adjacent teeth are misplaced. It should not be confused with a giant-cell epulis. Histologically it bears resemblance with osteoclastoma of long bone, but it is quite benign. It contains a stroma of connective tissue, scanty collagen, thin-walled blood vessels and numerous osteoclasts-like giant-cells. Histiocytes may be present scattered throughout the lesion. So histologically it resembles giant-cell epulis and brown tumour of hyperparathyroidism. It is differentiated from osteoclastoma of the jaw by histology.



Fig.23.9.— Adamantinoma of the lower jaw affecting the left mandible.

Tumours of the Upper Jaw.— Besides the benign tumours, e.g. ivory osteoma and osteoclastoma, the upper jaw may be affected with malignant growths — osteosarcoma and carcinoma arising from columnar epithelium lining the maxillary antrum or from squamous epithelium overlying the hard palate. Their *clinical features* vary according to the direction in which the tumour spreads. If the roof of the antrum is invaded, there will be proptosis and diplopia; if the anterolateral wall is involved,

there will be obvious swelling of the face; if the medial wall is affected, there will be nasal obstruction, epistaxis and epiphora; if the floor is invaded, there will be bulging of the hard palate. In the early stage, it is extremely difficult to distinguish a sarcoma from a carcinoma arising from the lining membrane of the maxillary antrum. A diagnosis of carcinoma is suggested when the tumour burrows through one of its walls and ulcerates or when the submandibular lymph nodes are involved.

Tumours of the lower jaw.— Benign tumours are mainly (i) Fibro-osseous group; (ii) Paget's disease of the jaw and (iii) Osteoclastoma. (i) Fibro-osseous group.— The mandible being mainly a membranous bone this type of tumour may obviously occur in this bone. If it is localized it is called Monostotic fibrous dysplasia and if it is diffuse it is called Polyostotic fibrous dysplasia. According to the portion of the fibrous tissue and bone this tumour may be either soft or hard. (ii) Paget's disease may be part of the generalised Paget's disease or confined mainly to the jaws. Old person complains of pain and swelling of the affected bone. X-ray shows the typical appearance of Paget's disease. (iii) Giant-cell tumour or osteoclastoma.— This lesion occurs between the ages of ten and twenty-five years, though this tumour in other sites appears between 25 to 40 years of age. Females are more often affected. The usual complaint is painless swelling. X-ray is characteristic of osteoclastoma anywhere in the body.

Malignant neoplasm is rare, more so is the primary variety. The mandible however may be involved by an advancing primary carcinoma of the tongue or the floor of the mouth. Neoplastic involvement may also occur from the secondarily involved facial lymph nodes lying by the sides of the facial artery.

Burkitt's tumour.— In many parts of Africa this is the commonest neoplasm in children of first decade. It is a type of multifocal lymphoma whose aetiology is not very clear. Viral origin has been strongly suggested. Age distribution has been very characteristic in the sense that majority of the patients are in the range of 3-7 years of age. Involvement becomes progressively diminished as age increases. Maxillary tumours generally present in relation to the molar and premolar teeth. As the tumour develops the alveolus expands on both sides and the affected teeth loose their attachments to the bone. Subsequently the tumour develops around the teeth with an external swelling which appears under the cheek distorting the face. Mandibular tumours develop in the same way with marked distortion of the face though without significant ulceration and often with surprisingly little evidence of pain. Multiple jaw lesions with involvement of several jaw quadrants are one of the characteristic features. When two jaw quadrants are involved it is nearly always the maxilla and the mandible of the same side. Radiological features of this tumour in the jaws are disappearance of the lamina dura round the affected teeth. Subsequently multiple small areas of bone dissolution appear and eventually coalesce forming larger areas of bone destruction. So the bone involvement is essentially osteolytic. Abdominal tumours are the second most frequent mode of presentation. Retroperitoneal mass, liver enlargement or ovarian tumours may be seen. The adrenal and pancreatic involvements are also common. Enlargement of mesenteric lymph nodes can give rise to an epigastric mass. Splenic involvement is not very significant. Lesion involving the spinal nerves is the 3rd commonest mode of presentation. Radiographs frequently show paravertebral mass in the lower dorsal or upper lumbar region. Intracranial lesions in the form of cranial nerve palsies may be seen in this condition. This tumour may affect the salivary gland, the thyroid, the breast, the bones and lymph nodes.

Alveolar abscess.— This condition mainly affects children and early adults. In children abscesses may occur in either jaw while in case of early adults this abscess develops mainly in the lower jaw. The disease starts as acute pulpitis which gradually affects the osseous tissue through the root of the tooth, localized osteitis and later on abscess develops. These abscesses

tend to bulge towards the external surface, barring the one in relation to the upper lateral incisor and in relation to an impacted wisdom tooth. In both these conditions abscesses show a natural tendency to bulge on the medial aspect, so that in case of the former, a swelling becomes evident on the palate and in case of the latter, the abscess may burst through the medial wall to cause the dangerous Ludwig's angina. Alveolar abscess if not treated properly by antibiotic therapy and drainage, osteomyelitis of the jaw may be expected.

The patient complains of dull and constant aching. Later on swelling of the cheek becomes evident with redness and oedema of the gum. Excruciating pain is the characteristic feature and the regional lymph nodes are almost always enlarged. X-ray may show rarefaction around the root of the affected tooth in late cases (no less than 10 days).

COMPLICATIONS OF ALVEOLAR ABSCESS.— Infection from lower teeth may spread lingually to cause cellulitis of the sublingual space. Apical abscesses of the 2nd and 3rd molars may perforate the lingual plate below the mylohyoid muscle to spread into the submandibular space. Bilateral sublingual and submandibular space infections constitute *Ludwig's angina.* Backward spread from here around the sublingual vessels results in oedema of the epiglottis and respiratory obstruction. From molars there may be posterior spread to the pterygoid space between the pterygoid muscles and the medial side of the ramus. From here infection spreads to the cavernous sinus by way of emissary vein. Abscess from upper canine tooth may travel upto the medial corner of the eye and may cause thrombophlebitis of the angular vein and cavernous sinus thrombosis. Alveolar abscess of the apex of the upper lateral incisor is closer to the palatal surface than the labial cortex and thus causes a palatal abscess. Pus from lower third molar may travel back beneath the masseter as a submasseteric abscess. Pus from the lower incisors may erode the bone below the origin of the mentalis muscle. Gradually the abscess reaches the surface between the two muscles and drains via a sinus in the midline of the chin, known as *Median mental sinus.*

Osteomyelitis of the jaw.— Three types of osteomyelitis are come across in jaws :

(i) *Acute osteomyelitis* is occasionally seen in infants as a complication of acute fevers like measles or scarlet fever. Either the upper or the lower jaw may be affected. Swelling, redness and puffiness are the features. In case of maxilla pressure may cause pus to come from the nostril. X-ray is not much helpful.

(ii) *Subacute osteomyelitis* is the commonest of the three varieties. Adults are mainly affected. Epical dental infection or alveolar abscess or fractured jaw or injudicious extraction of tooth with poor general condition is the main cause of this condition. Endarteritis of the artery supplying the mandible will cause obstruction to the blood supply leading to bone necrosis. The maxilla is rarely affected due to the fact that series of vertical arteries anastomose and maintain the blood supply to the bone.

Pain, swelling, tenderness and irregularity of the bone are usual features of this condition. Increased tension in the dental canal compresses the inferior dental nerve causing numbness of the chin in the distribution of the mental nerve. X-ray may show bone necrosis in very late cases (no less than 3 weeks time).

(iii) *Chronic osteomyelitis* also affects the mandible more often than maxilla. This condition usually follows apical dental infection or alveolar abscess or fractures. Patient seeks advice many months after the original disease. X-ray will show local osteitis, localized abscess (similar to Brodie's abscess) or formation of sequestrum.

Chronic osteomyelitis may also follow radiation or chemical necrosis due to phosphorus poisoning. Tuberculous, syphilitic and actinomycotic necrosis may also be found.

Median mental sinus is a form of chronic osteomyelitis, which is produced by an apical

abscess on one or more of the lower incisors. The cortical plate is penetrated and the abscess accumulates deep to the mentalis muscles. The pus ultimately escapes to the surface only in the midline through a sinus in a centre of the chin.

Actinomycosis.— Facio-cervical actinomycosis is the commonest actinomycosis occurs in the human body. The lower jaw is usually involved adjacent to a carious tooth. The gum becomes indurated. Nodules gradually appear which soften. The overlying skin becomes indurated and bluish in colour which gradually softens in patches. Ultimately abscesses burst through the skin and multiple sinuses form. Swelling, brawny induration, irregularity of the bone with multiple sinuses are the features of this condition. The multiple sinuses discharge sulphur granules which is pathognomonic. X-ray appearance is usually normal.

Micrognathism.— Occasionally the mandible may be excessively small, when it is called 'Micrognathism'. There may be respiratory obstruction in case of neonates with micrognathism, as this deformity results in backward displacement of the tongue. Oral cavity is also small. Special airway plates should be used to prevent airway obstruction, which is much better than sewing of the tip of the tongue to the lower lip. Nowadays monoblock orthodontic appliance has been devised to correct this small mandible.

Mandibular prognathism.— When the mandible is larger than average and protrudes, it is called mandibular prognathism. Occasionally the maxilla may be hypoplastic producing a relative mandibular prognathism.

Chapter

24 EXAMINATION OF THE PALATE, CHEEK, TONGUE AND FLOOR OF THE MOUTH

HISTORY.—

1. **Age and Sex.**— Cleft lip and Cleft palate are seen since birth. Stomatitis may occur at any age. Mucous retention cyst also occurs at any age. Carcinoma of lip and Carcinoma of tongue occur more often in males above 50 years of age.

2. **Occupation.**— Carcinoma of lip is commonly seen in men involved in outdoor activities and that is why it is often called 'countryman's lip'.

3. **Residence.**— White Caucasians residing in Australia are the major sufferers of lip cancer. Negroes are less susceptible to this disease.

4. **Swelling or Ulcer.**— The lesions of the lip, cheek, tongue and floor of the mouth usually present as a swelling or an ulcer. Enquire about the onset, duration and progress of the lesion. While a *mucous retention cyst* usually occurs on the inner side of the lip or cheek and grows very slowly and presents for quite a long time; a *cancer of the lip* may present as a swelling or ulcer, gives a relatively short history though it is a slow-growing cancer and a *cancer of the tongue* gives an even shorter history.

5. **Pain.**— This is an important symptom of these lesions. A careful history must be taken about its site, radiation or referred pain. Stomatitis is a painful condition particularly aphthous stomatitis. Similarly dental ulcer is very painful, but tuberculous ulcer is less painful. Pain is conspicuous by its absence in leukoplakia, mucous retention cyst and early stage of carcinoma of lip or tongue. If an old patient presents with ulcer of his tongue, but without pain, is an ominous sign. But it must be remembered that in late cases pain appears even in carcinoma of tongue. Site of pain is important e.g. pain is complained of at the side of the tongue in case of dental ulcer. In certain late cases of carcinoma of tongue pain is referred to the ear of the affected side as lingual nerve and auriculotemporal nerve supplying the anterior surface of the external ear are both the branches of the mandibular nerve.

6. **Certain specific complaints.**— Excessive salivation is a very common specific complaint of carcinoma of tongue. If an old patient is seen in surgical outdoor holding handkerchief in his mouth, he is most probably suffering from carcinoma of tongue. Inability to protrude the tongue is a symptom of tongue-tie and late cases of carcinoma of tongue with invasion to the floor of the mouth. Difficulty in speech is the main complaint of cleft lip and cleft palate and carcinoma of tongue. Deviation of tip of the tongue when protruded towards the side of the lesion is a sign of carcinoma of tongue. Alteration of voice may be the first symptom in carcinoma of posterior 1/3 of the tongue which may remain unnoticed for quite sometime.

7. **Personal history.**— Enquiry must be made whether the patient smokes a lot or in the habit of drinking alcohol or taking spicy food. These may cause leukoplakia which is a pre-malignant condition. Similarly habit of taking betel nut and supari or 'Khaini' is quite common among the sufferers of carcinoma of the cheek.

PHYSICAL EXAMINATION

INSPECTION.— Inspection of inside of the mouth should be carried out preferably in day light or in good light and you should always use a spatula. To inspect the *lips* properly not only the outer surfaces of the lips are examined, but also the lips are retracted to see the mucosal surface of the lips. Similarly the *cheeks* are retracted outwards to see the buccal mucosal surface of the cheek as also the buccal side of the gum. To see the inside of the gum and floor of the mouth, the tongue is pushed away to one side or the other. For inspection of the tongue, the mouth is fully opened and the tongue is protruded to see the anterior 2/3rd of the tongue. To see the lateral aspect of its posterior third the tongue is pushed to one side or the other with a spatula. To see the fauces, tonsils and the beginning of the pharynx, one should depress the tongue with a spatula.

(1) **Lips.**— Cleft lip is obvious in inspection. *Cleft lip* may be complete when there is total failure of fusion and then the cleft extends upto the corresponding nostril. In case of incomplete cleft lip the cleft does not extend upto the nostril. There may be bilateral complete cleft lip in which there is also a cleft palate and a protruberant pre-maxilla. A *facial cleft* is a cleft between the maxilla and the side of the nose. *Pigmentation of the lips* and buccal mucous membrane is sometimes seen in Addison's disease. Small bluish-black spots on the lips and on the buccal and palatal mucous membrane are seen in Peutz-Jegher's syndrome. This syndrome is a familial disease which is inherited by autosomal dominant gene and the main pathology lies in the small bowel in the form of adenomatous polyp which may cause intussusception or intestinal colic, but rarely undergo malignant change. *Chancre of the lip* presents as a painless ulcer with dull red colour. *Cracked lips* are indolent cracks in the midline of the lower lip as a result of exposure to cold weather. These may occur more often in the angles of the mouths. *Ectopic salivary neoplasms* are usually seen in the upper lip as slow growing lobulated tumours. *Carcinoma of the lip* is seen in old individual which presents as erosion in the early stage — as red granular appearance with whitish flecks followed by yellowish crusting in the middle of the erosion. Gradually the centre becomes ulcerated and the margin becomes everted. The skin over the tumour becomes red and vascular. *Machrocheilia* means thickening of the lip which often involves the upper lip.



Fig.24.1.— Lymphangioma of the right half of the tongue.



Fig.24.2.— Haemangioma of the left half of the tongue.

(2) **Tongue.**— Ask the patient to open the mouth and note : (a) The ***volume*** of the tongue; massive tongue ***(macroglossia)*** is commonly due to lymphangioma, haemangioma, neurofibroma and muscular macroglossia commonly seen in Cretins. (b) Its ***colour*** — the white colour of leukoplakia (chronic superficial glossitis), the 'red glazed tongue' when the leukoplakia plaques are desquamated, the blue colour of venous haemangioma and black hairy tongue due to



Fig.24.3.— Lingual thyroid with a branchial fistula in front of the lower part of the sternomastoid.

hyperkeratosis of the mucous membrane in heavy smokers or caused by a fungus called Aspergillus niger are very characteristic. (c) *Any* ***crack or fissure***; note the direction of the fissures. Congenital fissures are mainly transverse whereas syphilitic fissures are usually longitudinal. (d) ***Swelling*** and (e) An ***ulcer*** if any.



Fig.24.4.— Carcinoma at the right border of the tongue.

If there is a swelling or an ulcer, note its site, size, shape, colour, surface, margin etc. as discussed in chapters 3 and 4 respectively. Note also whether it has extended to the floor of the mouth, to the jaw or tonsil. The site of the ulcer is usually characteristic e.g. the dental ulcer occurs on the side of the tongue where they come in contact with sharp teeth or dentures, tuberculous ulcers on the tip and sides, gummatous ulcer on the dorsum and carcinomatous ulcers occur usually on the margin of the tongue (on the dorsum where superimposed on chronic superficial glossitis).

Very rarely one can discover an angioma-like swelling in the region of the foramen caecum — this is *lingual thyroid*. This may be the only thyroid gland the patient possesses and therefore should not be removed.

Lastly, the ***mobility of the tongue*** is tested. Ask the patient to put the tongue out and move it sideways. Inability to put the tongue out completely is due to ankyloglossia. If the tongue deviates to one side during the protrusion, it indicates impairment of nerve supply to that half of the tongue. This may be noticed in advanced carcinoma of the tongue which has damaged the nerve supply of the consequent side. If a child with impaired speech fails to protrude the



Fig.24.5.— Swelling at the hard palate.



Fig.24.6.— Congenital cleft of the palate.

tongue, it is possibly due to tongue-tie; look for the short frenum linguae.

(3) **Palate.**— Is there a congenital cleft, perforation, ulceration or a swelling? In case of a *congenital cleft*, note the extent of the cleft (involving only the uvula, only the soft palate or part or whole of the hard palate) and also whether the nasal septum is hanging free or is attached to one side of the cleft. *Perforation* of the hard palate is usually caused by gumma (syphilitic affection) (Fig. 24.7). The student must be careful to note if there is any scar of operation around or such history, as sometimes a hole may persist after an operation for closure of a congenital cleft. An *ulcer* or a *swelling* is examined in the usual way.



Fig.24.7.— Gummatous perforation of the hard palate.

(4) **Gums.**— In order to examine the gums each lip must be everted fully. A spatula and a torch will be essential to visualize more posterior portions of the gums. Healthy gums are bright pink in colour. The earliest sign of *pyorrhoea alveolaris* is a deep red line along the free edge of the gum. *Vincent's stomatitis* is an



Fig.24.8.— A typical ranula at the floor of the mouth. Note its bluish colour.

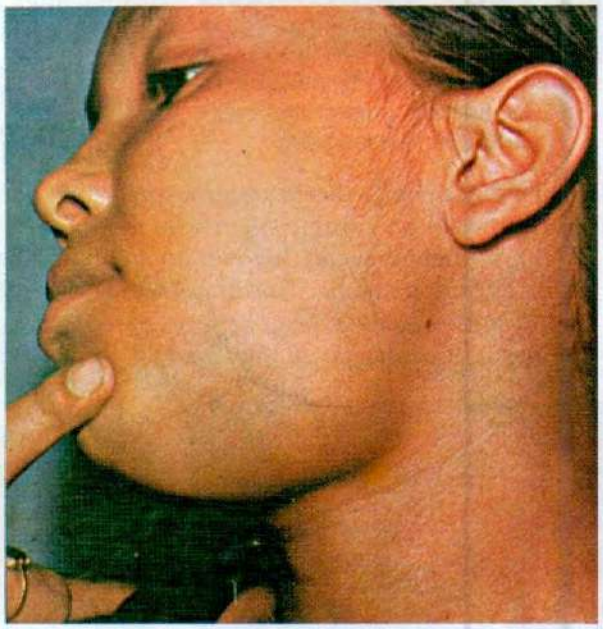

Fig.24.9.— A case of plunging ranula. This is the same case as shown in Fig. 24.8. Note how the swelling is so obvious in the submandibular triangle.

inflammatory condition of the gingivae. There is ulceration of the gingival margin and formation of a pseudomembrane. This condition is often associated with very bad smell. *Cancrum oris* starts with a painful purple-red indurated papule found on the alveolar margin in the region of the molar or premolar teeth. Later on an ulcer forms which rapidly exposes the underlying bone and extends to the cheek and lip. This is also associated with foul smell. Swollen gum is sometimes a feature of dental abscess. A blue line may be seen in case of patients who work with lead.

(5) **Floor of the mouth.**— Ask the patient to open his mouth and to keep the tip of his tongue upwards to touch the palate. This will expose the floor of the mouth. When a swelling is present, note amongst other features, its colour and position. A *ranula* appears as a unilateral bluish translucent cyst over which Wharton's duct can often be seen. A *sublingual dermoid* is opaque, lies exactly in the midline and may extend into the submental region. A deep or plunging ranula may have a cervical prolongation into the submandibular region.



Fig.24.10.— Carcinoma of the cheek.

(6) **Cheek.**— Examine the inside of the cheek for aphthous ulcer, leukoplakia, mucous cyst, lipoma, mixed salivary tumour, papilloma or carcinoma. Pigmented patches may be seen in Addison's disease and in Peutz-Jegher's syndrome. Of the above list, *mucous cyst* deserves special mention. Such cyst may develop anywhere on the inner side of the lips and the cheek, though more common on the inner side of the lower lip and on the buccal mucous membrane of the cheek at the level of the bite of the teeth.

PALPATION.—

(1) **Lip.**— Any lesion of the lip should be carefully palpated. While benign neoplasms are firm and lobulated,



Fig.24.11.— Method of palpation for enlarged submandibular lymph nodes in a case of carcinoma of the lip. Note that the carcinoma originally affected the lower lip and now 'kiss lesion' is seen in the upper lip. Carefully note the method of palpation of submandibular lymph nodes. The head is bent to the side being palpated with one hand to relax the platysma and the muscles of that side of the neck for better palpation with the other hand.

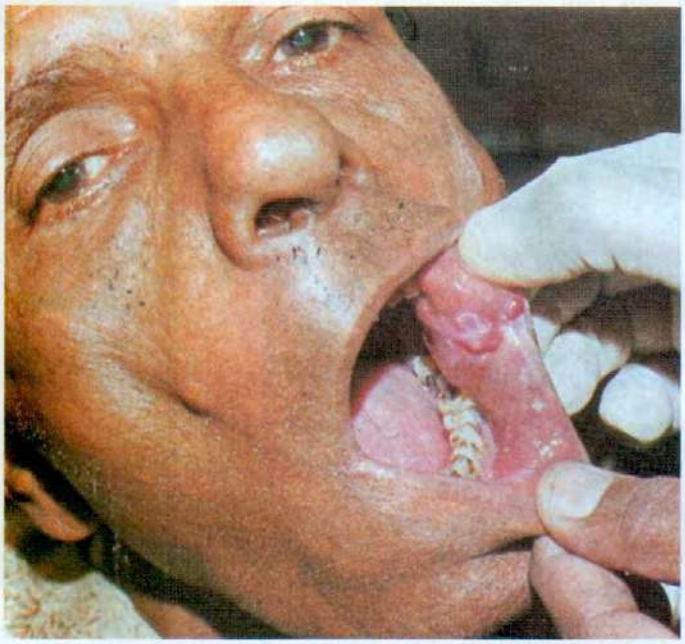

Fig.24.12.— Mucous retention cyst at the inner surface of the cheek.



Fig.24.13.— Shows another case of carcinoma of the lip where the submandibular lymph nodes are being palpated for enlargement. Note the method of palpation.

carcinoma of the lip is hard in consistency. Hunterian chancre is rubbery hard, whereas carcinoma of lip is stony hard. When carcinoma of lip is an ulcer hold the base of the ulcer with index finger and thumb which is always hard. With one hand the lip is now fixed and with the other hand the lesion of the lip is held by two fingers and is attempted to move against the lip. The carcinoma is almost always fixed. Mucous retention cyst is often seen on the inner surface of the lip (mostly in the lower lip). Fluctuation and transillumination test are positive when the cysts are large. But these tests are not easy to perform in the lip. For fluctuation test one should follow the technique for small swelling as mentioned in chapter 3 (page. 29). Regional lymph nodes are always felt in the submental and submandibular region (See Fig. 24.11).

(2) **Tongue.**— While palpating for *induration* of the base of an ulcer, it is desirable that the tongue should be relaxed and at rest within the mouth. If it is kept protruded, the contracted muscles may



Fig.24.14.— Showing the correct method of palpation of the tongue for induration (which is a characteristic feature of carcinoma of the tongue). The tongue must lie at rest within the mouth.



Fig.24.15.— Showing the wrong method of palpation for induration of the base of an ulcer. If the tongue is kept protruded, the contracted muscles may give an impression of induration.

give a false impression to induration and lead to error in diagnosis. Induration is an important clinical sign of epithelioma. It may be present in gummatous ulcer but is absent in tuberculous ulcer. Note whether the *ulcers bleed readily during palpation*. This usually occurs in a malignant ulcer. Palpate carefully for a sharp tooth or tooth plate against an ulcer in the tongue.

Palpate the back of the tongue for any ulcer or swelling. The patient sits on a stool. The examiner stands on his right. The head is first fixed by holding it firmly against him with the left hand; the index finger of this hand is pushed in between the upper and lower jaws over the cheek to prevent closing of the mouth and biting the examiner's finger. The right index finger is then passed behind the soft palate. The back of the tongue and the pharynx are explored.

(3) **Palate.**— A tender fluctuating swelling close to the alveolar process is an alveolar abscess. A soft swelling in the middle of the hard palate is usually a gumma. An ulcer or a swelling is examined in the usual way. Mixed tumour of ectopic salivary gland may be felt in the palate.

(4) **Gums.**— As age advances the gums recede and the teeth appear longer. The gums may bleed on palpation, which become swollen, spongy and tender in *scurvy*. Gums may bleed in uraemia but they may not be as spongy as in scurvy. *Epulis* is a swelling of the alveolar margin of the gum. The margin, consistency, surface, mobility should be noted to come to a definite diagnosis of the type of epulis. These have been discussed in details in chapter 23.

(5) **Floor of the mouth.**— A ranula is a fluctuating swelling with positive translucency. To know its extent, bimanual palpation of the floor of the mouth on one side and submandibular triangle on the other hand is necessary. Sublingual dermoid is not a translucent swelling but it is a tense fluctuant swelling on the midline. Carcinoma of the floor of the mouth may be revealed by its indurated base and probable fixation to the underlying structures.

(6) **Cheek.**— Mucous cyst has a smooth surface and is movable over the deeper structures. Fluctuation can be elicited by pressing on the top



Fig.24.16.— A ranula is being tested for translucency.

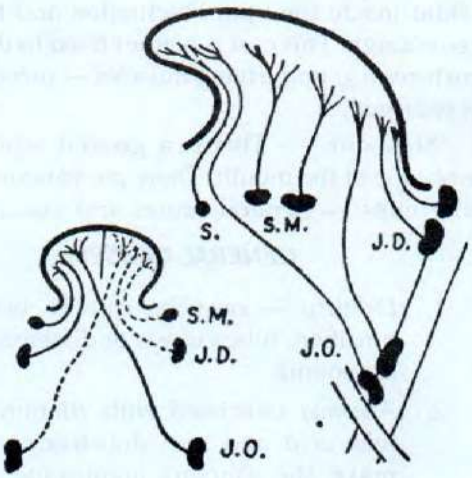

Fig.24.17.— Lymph drainage of the tongue. From the tip — to the submental (S) and jugulo-omohyoid (J.O.); from the margin — to the submandibular (S.M.) and upper deep cervical group; from the back — to the jugulodigastric (J.D.) and jugulo-omohyoid (J.O.). The other figure shows decussation of lymph vessels.

of the cyst while the sides are palpated by other two fingers. Papilloma is a solid tumour with irregular surface and mobile on the deeper structures. Carcinoma is fixed and indurated.

Examine the cervical lymph nodes (see 'Examination of the neck'), particularly the (i) submental, (ii) submandibular, (iii) jugulodigastric and (iv) jugulo-omohyoid groups. The lymph nodes of both sides must be examined even if the lesion is unilateral as the lymph vessels decussate.

GENERAL EXAMINATION

(1) If the ulcer of the tongue seems to be tuberculous, look for the primary focus in the lungs.

(2) In *gummatous ulcer*, look for syphilitic lesions in other parts of the body. Since an epithelioma may develop on a syphilitic base, a positive W.R. will not exclude a carcinoma.

DIFFERENTIAL DIAGNOSIS

Mucous retention cyst.— This cyst usually develops due to obstruction of the duct of a small mucous secreting gland. So this cyst may occur anywhere on the inner surface of the lips, cheek and the mouth where these mucous secreting glands are present. It is most common on the lower lip and in the buccal mucous membrane of the cheek at the level of the bite of the teeth. The cyst may occur at any age. The main complaint is a lump on the inner side of the lip or cheek, which is *not* painful, but grows slowly and interferes with eating and may get bitten. The colour of such cyst varies according to the state of the overlying epithelium. If the epithelium is healthy the cyst is pale-pink with grey glairy appearance of the mucus inside the cyst. If the epithelium is damaged it looks white, scarred and obscure the colour of the mucus inside the cyst. This cyst is usually spherical with smooth surface and consistency varies from soft to hard according to the tension of fluid inside the cyst. Fluctuation and transillumination tests are positive when the cysts are large enough. This cyst is neither fixed to the overlying mucous membrane, nor fixed to the deeper structures e.g. underlying muscles — orbicularis oris or buccinator. The regional lymph nodes are not enlarged.

'Stomatitis'.— This is a general term to describe inflammation of any kind of the lining membrane of the mouth. There are various *causes* of stomatitis which can be broadly classified into two groups — General causes and Local causes.

GENERAL CAUSES

1. *Debility* — may be due to lack of nutrition, tuberculosis or disseminated carcinoma.
2. *Anaemia* associated with vitamin B12, folic acid and iron deficiency which make the mucous membrane thin, atrophic with loss of papillae of the dorsum of the tongue.
3. *Vitamin Deficiency.*— Lack of several varieties of Vitamin B may lead to red mucous membrane and angular cheilitis. Vitamin C deficiency (Scurvy) casues ulceration of gums and buccal

LOCAL CAUSES

1. Poorly fitting denture, sharp tooth and excessive smoking.
2. Infections with Vincents angina, Candida albicans, monilia or Herpes Virus.
3. *Trauma* — mechanical, chemical, thermal or X-rays.

mucosa due to interference in collagen synthesis. Vitamin B and C deficiency are also come across in Sprue, Coeliac disease, Pellagra and Kwashiorkor.

4. *Blood diseases* e.g. leukopenia, agranulocytosis, aplastic anaemia and hypogammaglobulinaemia and severe anaemia are the conditions which reduce ability of the oral mucosa to deal with various infections and thus lead to stomatitis.
5. *Drugs*.— Certain drugs e.g. adrenal cortical steroid, phenobarbitone, phenytoin, lead, mercury, bismuth or sulphur poisoning. Excessive ingestion of iodides may also lead to stomatitis or sore mouth and excessive salivation.
6. An autoimmune mechanism is often believed to be at the root of forming stomatitis.
7. Secondary syphilis.

4. Foot and mouth disease.

Infecting organisms of this disease can be classified into two groups — (i) Facultative pathogens, that means the pathogens which are normal oral commensals, but take advantage of any weakness in the defence mechanism of the oral mucosa to produce localized or generalized infection of the mouth. These are streptococci, staphylococci and occasionally Vincent's organism. (ii) True pathogens, which are real pathogens and produce specific infections. *The followings are the different varieties of stomatitis* :—

Catarrhal stomatitis.— The whole of the mucous membrane of the mouth becomes oedematous and red. This usually occurs in association with acute upper respiratory tract infection and acute specific fever.

Aphthous stomatitis.— In this condition the inside of the mouth is covered with small painful vesicles with hyperaemic base. The vesicles break and ulcers form which are round or oval in shape, with yellow base and red erythematous margin. These ulcers are exquisitely painful and are usually associated with generalized debilitating diseases. These ulcers are seen on the inside of the cheek, lips, soft palate and floor of the mouth. These usually heal within 10 to 14 days. These are more frequently seen in women than in men.

Monilial stomatitis (Thrush).— This condition occurs due to oral infection with a fungus — *Candida albicans*. This is more commonly seen in children and in people with debilitating disease and also as a complication of a long continued antibiotic therapy. This may accompany the onset of AIDS. Small red patches appear on the buccal mucosa and tongue, which gradually turn white. This white colour is due to a layer of oedematous desquamating epithelium which is heavily contaminated with the fungus. This is also a very painful condition with excessive salivation.

Ulcerative Stomatitis (Vincent's angina).— This condition is caused by Borrelia Vincenti and Fusiformis Fusiformis. Borrelia Vincenti is a mobile spirochaete whereas fusiformis fusiformis is a rod shaped organism with pointed ends. Both of these are anaerobic and Gram negative. In this

condition the gums are swollen, inflamed and painful with numerous small ulcers that are covered with yellow slough. These ulcers bleed easily and patients often complain of spontaneous gingivial haemorrhage with fetor oris. This condition is mainly seen in adolescents and young adults. Patients are often unwell in particularly acute cases with fever and loss of appetite. The cervical lymph nodes are often enlarged and tender.

Gangrenous Stomatitis (Cancrum oris).— It is a severe form of stomatitis affecting the young and poorly nourished children. Malnutrition is the main predisposing cause and sometimes a complication of measles and leukaemia. It begins as an area of oedema and induration on the gums which becomes necrotic. The area of necrosis spreads on to the inside of the cheek, the lips and then through to the skin surface, producing a large area of full-thickness tissue loss. This is an extremely painful condition and the patient is very ill with anorexia, malaise and pyrexia.

Angular Stomatitis (Angular cheilosis).— In this condition there are moist, infected reddish brown fissures at the angles of the mouth. The saliva usually leaks at the corners of the mouth and the moist skin becomes infected by Candida and staphylococci. It may occur in children who rub or lick the corners of their mouths, when it is called 'Perleche'. This condition may also occur in middle-aged and elderly using dentures.

Occasionally small radiating cracks in the corners of the mouth may develop in patients with congenital syphilis, the condition is known as 'Rhagades'.

Hunterian Chancre of the lip.— The features of primary chancre of the lip are similar to those of one on the genitalia. Initially there is an elevated, pink macule. This grows slowly into hemispherical papule. Upto this stage the condition is painless. Gradually the mucosal covering breaks down and a superficial ulcer forms which is often covered with a thick crust. The base of this ulcer is rubbery hard. This ulcer is slightly painful. The regional lymph nodes in the neck become enlarged and slightly tender. This ulcer is highly contagious. Ultimately the ulcer heals leaving a fine permanent superficial scar.

The mucous patch of syphilis.— In the secondary stage of syphilis mucous patches are seen on the inside of the lips, cheeks and on the pillers of the fauces. These are greyish white in colour due to oedema and desquamation of the epithelium. When this grey patch of dead epithelium separates, the underlying mucosa is seen raw and bleeding. These mucous patches are also highly contagious. The patient with these mucous patches often complain of sore throat.

'Snail track' ulcer.— These ulcers form due to coalescence of a number of small mucous patches. So these ulcers are also seen on the inside of the lips, cheeks and mainly on the pillers of the fauces. These look like linear ulcers which are covered with white boggy epithelium and thus these are called 'snail track' ulcers.

Benign neoplasms of the lip.— These are quite rare in the lip. Only when benign neoplasms develop in minor salivary glands such tumours are seen. Usually the upper lip is affected. Firm, slow growing, lobulated and mobile tumours are seen which are nothing but pleomorphic adenomas of the ectopic salivary glands. In extreme rare cases malignancy may develop in these ectopic salivary glands.

Carcinoma of the lip.— Usually males over 50 years of age become the victims of this disease. It usually occurs in individuals who are involved in outdoor occupations and that is why this condition is sometimes called 'Countryman's lip'. White Caucasians residing in Australia are often affected. Exposure to sunlight, especially the ultraviolet part, seems to be an important aetiological factor. Leukoplakia of the lip, recurrent trauma from pipes and cigarettes are other aetiological factors. The lower lip is involved in more than 90% of cases. Upper lip is affected in only 5% of cases and 1% for each corner of the lip. Initially patient complains of blistering,

thickening or white patches on the lips which are persisting. Gradually a nodule appears, the centre of which becomes ulcerated and the margin becomes everted. Such ulcer fails to heal. As the ulcer grows it gradually invades into deeper structures, it often bleeds and may produce offensive discharge. It must be remembered that this condition is *painless*. The regional lymph nodes are almost always enlarged and the patients often show lumps under their chins.

Tongue-tie.— It is a developmental anomaly, in which the frenum of the tongue is short and thicker. This frenum holds the tip of the tongue close to the lower central incisors. So the patient fails to protrude the tongue. Such attempt will cause eversion of the lateral margin of the tongue and heaping up of the midportion of the dorsum. It usually does not cause any other disability.

Leukoplakia (chronic superficial glossitis).— In this condition normal surface of the dorsum of the tongue is lost and white colour of thickened patches of epithelium which have lost their papillae cover the dorsal surface of the tongue. The lesion starts as thin and wrinkled white patches which gradually coalesce to form creamy-white thick surface. Later on this surface becomes dried and cracked. If the superficial epithelium is shed over a considerable area a 'red glazed tongue' may develop. In early cases if one is suspicious about this condition one may press a glass slide on the surface of the tongue which makes the thickened epithelium more obvious. While palpating, one must be careful to palpate the whole of the tongue to exclude any induration anywhere to suggest the malignant change which might occur.

Though syphilis was by far the commonest cause previously, yet carcinoma is gradually taking over this place. The other predisposing causes are smoking, spirit, sepsis and spices. So students should remember of five 'S' as the predisposing factors of this condition. No less than 30% of cases of carcinoma of the mouth is being preceded by leukoplakia.

Five stages are recognizable in this condition :—

Stage I.— Mild thickening of the surface with hypertrophy of the papillae and hyperkeratosis.

Stage II.— Stage of leukoplakia — the tongue is covered with smooth paint.

Stage III.— The surface becomes irregular like dried paint.

Stage IV.— Warty projections appear with cracks and fissures (precancerous stage).

Stage V.— Desquamation of the abnormal mucosa leading to 'red glazed tongue'. This condition may gradually lead to carcinoma.

Macroglossia.— This means chronic painless enlargement of the tongue. The causes are lymphangioma, haemangioma (which may be associated with congenital arteriovenous fistula), plexiform neurofibroma, muscular macroglossia (is often a feature of cretinism) and amyloid infiltration.

Manifestations of syphilis in the tongue.—

Primary syphilis.— Extra-genital chancre may occur in the tongue with enlargement of the regional lymph nodes (submandibular and submental lymph nodes).

Secondary syphilis.— Multiple shallow ulcers may be found on the under surface and sides of the tongue. Mucous patches may be seen on the dorsum of the tongue as well as in the fauces. Hutchinson's Wart (a condyloma) may be seen on the middle of the dorsum of the tongue.

Tertiary syphilis.— Gumma of the tongue always occupies the midline position on the dorsum.

Black hairy tongue.— This is due to hyperkeratosis of the mucous membrane caused by a fungus, Aspergillus niger. Generally heavy smokers are the victims.

Median rhomboid glossitis.— A reddish colour may be seen in the midline just in front of the circumvallate papillae. This is probably due to inadequate covering of the tuberculum impar in the formation of the anterior part of the tongue. This condition is often mistaken for syphilitic wart or epithelioma of the tongue.

Congenital fissuring of the tongue.— Usually there is a deep median furrow from which transverse furrows originate on both sides. This condition usually reveals itself at the age of 3 years.

Syphilitic furrowing of the tongue.— In contradistinction to the congenital fissures, the syphilitic fissures are generally longitudinal in direction and the intervening epithelium is either hyperkeratotic or desquamated.

Ulcers of the tongue.— Various types of ulcers may be found in the tongue. Of these the important ulcers are described below :—

Aphthous (dyspeptic) ulcer — is a small painful ulcer seen on the tip, undersurface and sides of the tongue in its anterior part. The ulcer is small, superficial, with white floor, yellowish border and surrounded by a hyperaemic zone. This condition is quite painful and usually starts in early adult life. These ulcers tend to recur and show a familial predisposition. Women suffer from this condition more often than men.

Dental ulcer — is caused by mechanical irritation either by a jagged tooth or denture. These ulcers occur at the periphery or on the undersurface of the tongue at the sides. This ulcer is elongated, often presents a slough at its base and surrounded by a zone of erythema and induration. This ulcer is quite painful.

Syphilitic ulcer — has been discussed above under the heading of 'Manifestations of syphilis in the tongue'.

Tuberculous ulcer — is shallow, often multiple and greyish yellow with slightly red undermining margin. These ulcers are also seen at the margin, tip or dorsum. This ulcer when occurs in the anterior 2/3rd of the tongue becomes very painful. Tuberculosis of the lungs or larynx is frequently associated with.

Post-pertussis ulcer occurs only in children with whooping cough. It is usually seen at the frenum linguae.

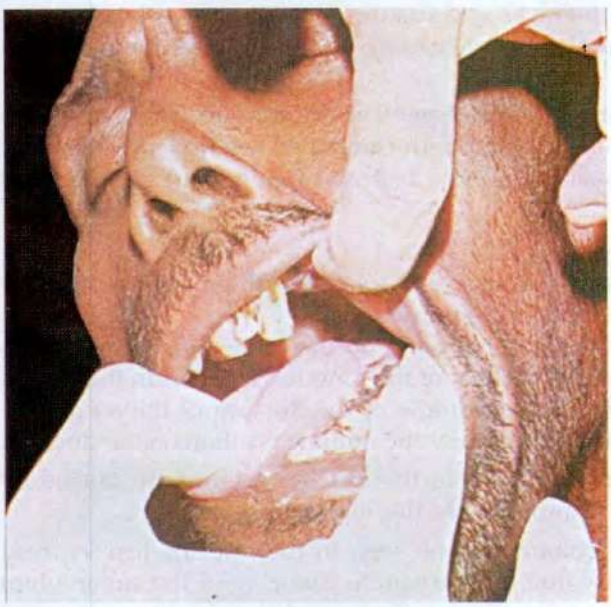

Fig.24.18.— Carcinoma at the left border of the tongue.

Chronic non-specific ulcer usually occurs in the anterior 2/3rd of the tongue. No aetiological factor can be found out. It is moderately indurated and not very painful.

Carcinomatous ulcer is painless to start with and only becomes painful in late cases. Pain may be referred to the ear. The ulcer has a raised and everted edge with indurated base. Lymph node involvement is also quite early.

Carcinoma of the tongue.— It is highly important to know the *precancerous conditions* which are (i) chronic superficial glossitis, (ii) smoking pipes and cigars, (iii) syphilis, (iv) sessile papilloma and (v) Plummer vinson syndrome.

CLINICAL TYPES : (i) fungating or warty type; (ii) ulcerating or excavating type; (iii) fissure or cracked type following chronic superficial glossitis; (iv) nodular

type and (v) 'frozen' type, when the tongue is transformed into an indurated mass. Of these, the first 3 types are common.

CLINICAL FEATURES.— Carcinoma of the tongue should be diagnosed whenever an elderly man (sometimes a woman) presents a fungating growth or an ulcer having raised and everted margin with indurated base at the lateral border of the anterior 2/3rd of the tongue. There is little pain in the tongue; in late cases one may complain of pain and it may be referred to the ear since irritation of the lingual nerve is referred to the auriculotemporal nerve. *Profuse salivation* is common and an elderly man sitting in the surgical out-patient department with handkerchief continuously pressed at the mouth to soak saliva, is probably suffering from this condition. This is partly due to irritation of the nerves of taste and partly due to difficulty in swallowing due to *ankyloglossia*, that means the patient cannot protrude the tongue out of the mouth. This indicates that the carcinomatous process has infiltrated the lingual musculature and even the floor of the mouth. Besides these, in late cases there will be difficulty in speech, *dysphagia* i.e. difficulty in swallowing and *faetor* (offensive smell).

Growth at the posterior third of the tongue often escapes the notice and in these cases *alteration of the voice* and *dysphagia* are the important symptoms. Diagnosis is made by palpating the growth which has been described in the section of "palpation" and by laryngoscopy.

SPREAD occurs (i) *locally* into the floor of the mouth and mandible when the growth is situated on the anterior 2/3rd of the tongue; and on the sides into the tonsil, fauces, epiglottic vallecula and soft palate when occurring on the posterior 3rd of the tongue. (ii) *Lymphatic spread* takes place into the submental, submandibular, jugulo-digastric and jugulo-omohyoid groups of lymph nodes of the same side as well as of the opposite side. Lymph node enlargement becomes more conspicuous in carcinoma of posterior 3rd of the tongue where growth is relatively out of sight. (iii) *Blood spread* is exceptional and only seen in cases of growth situated in the extreme posterior part of the tongue.

DEATH results from (i) inhalation bronchopneumonia due to aspiration, (ii) cancerous cachexia and starvation, (iii) haemorrhage from the primary growth and also from carotid artery when eroded by metastatic lymph nodes and (iv) asphyxia due to pressure on the air passages by metastatic lymph nodes or oedema of the glottis.

Ranula.— It is a translucent cystic swelling with bluish tinge situated on one side of the frenum linguae. It is almost always unilateral. Often the submandibular duct can be seen traversing the dome of this swelling. A big ranula may fill the floor of the whole mouth.

Deep or plunging ranula.— When a ranula extends into the neck so that it can be palpable in the submandibular triangle, it is called a 'deep or plunging ranula'. Bimanual palpation will reveal cross fluctuation between the floor of the mouth and its cervical extension. This type of ranula probably derives from the cervical sinus.

Sublingual dermoid.— This is a congenital condition, but unfortunately is not seen before 10 years and majority of the patients when enter the surgical clinic are in their 20s. Thus ranula which is an acquired condition, becomes the most important condition in differential diagnosis. Though median variety is more common yet lateral sublingual dermoids are not unseen. While the median variety develops from inclusion of ectoderm between the two halves of the developing mandible, the lateral variety develops from the 2nd branchial cleft. It is an opaque and non-translucent swelling in the floor of the mouth when situated above the mylohyoid. When situated below the mylohyoid, a cystic swelling develops either just below the chin, giving rise to a double chin or in the sub-mandibular region giving rise to a cystic swelling there. It is filled with sebaceous material and unlike other dermoid cysts does not contain hair.

Chapter

25 EXAMINATION OF THE SALIVARY GLANDS

THE PAROTID GLAND

HISTORY.—

1. **Swelling.**— Careful history must be taken as 'How did the swelling start?' 'Where exactly was the swelling first noticed?' 'How long is the swelling present?' 'Has the swelling enlarged uniformly throughout the period?' or 'Has it suddenly enlarged very recently?' So the onset of the swelling, exact site of the swelling, duration of the swelling and growth of the swelling are noted. In dehydrated patient with poor oral hygiene if he complains of sudden increase in size of both the parotid glands with considerable pain, the case is probably one of acute parotitis. If there is brawny oedematous swelling of the parotid region with pain, this is probably a case of parotid abscess. When there is generalized enlargement of all major salivary glands including lacrimal glands, it is called Mikulicz's syndrome. If this is associated with dry eyes and generalized arthritis the condition is called Sjogren's syndrome. A slow growing tumour having duration for years or months of the parotid gland is the pleomorphic adenoma. When such a tumour suddenly starts growing rapidly and becomes painful, it is highly suggestive of malignant transformation of this adenoma (mixed parotid tumour). Site is important as adenolymphoma, which is also a slow-growing painless tumour, arises in the lower part of the parotid gland at the level of the lower border of the mandible slightly lower than the usual site of pleomorphic adenoma. 'Does the swelling increase in size, becomes tense and painful during meals?' This is characteristic of obstruction of the parotid duct with stone.

2. **Pain.**— Acute parotitis is a painful condition. It must be remembered that mumps is the commonest cause of bilateral parotitis (See Fig. 25.15). Throbbing pain is the characteristic feature of parotid abscess. Excruciating pain, slight swelling and redness in the region of the parotid gland are characteristic features of parotid abscess. In case of obstruction of the parotid duct with a stone or stricture patient will complain of colicky pain during meals when the swelling of the parotid gland will also be increased.

3. **Watery discharge** from a sinus in the region of the parotid gland or its duct particularly during meals is significant of a parotid fistula.

INSPECTION and PALPATION.—

(1) **Swelling.**— The students must keep in mind the position of the parotid gland, which is below, behind and slightly in front of the lobule of the ear (Fig. 25.1). A swelling of the parotid gland thus obliterates the normal hollow just below the lobule of the ear. This position of the parotid gland is very important as many of the lymph node swellings are often mistaken for parotid gland tumour and vice versa. While examining the swelling its extent, size, shape, consistency etc. should be noted as in any other swelling. Whether the swelling is fixed to the

masseter muscle or not is examined by asking the patient to clinch his teeth and the mobility of the swelling is tested over the contracted masseter muscle (Figs. 25.3 & 25.4).





Figs.25.1 & 25.2.— Note the typical site of the mixed parotid tumour.

Enlargement of the deep lobe of the parotid gland, though occasionally seen is not very easy to diagnose. The examinations detailed above are all for the superficial lobe. A bimanual examination with one finger of one hand inside the mouth just in front of tonsil and behind the 3rd molar tooth and one finger of the other hand externally behind the ramus of the mandible is necessary for palpation of the deep lobe (Fig. 25.5).





Figs.25.3 & 25.4.— Testing for mobility over the contracted masseter. The patient is asked to clinch his teeth to make the masseter contracted.

(2) **Skin over the parotid gland.**— Careful inspection and palpation must be made for the skin over the parotid gland. In case of parotid abscess the skin becomes brawny oedematous with pitting on pressure. It must be remembered that fluctuation is a very late feature of a parotid abscess as there is strong parotid fascia overlying the parotid gland. So the findings of the skin mentioned above should be considered as conclusive evidence for the diagnosis. The skin will also be warm and extremely tender. One should also look for any scar or fistula in



Fig.25.5.— Method of palpation of the deep lobe of the parotid gland. See the text.

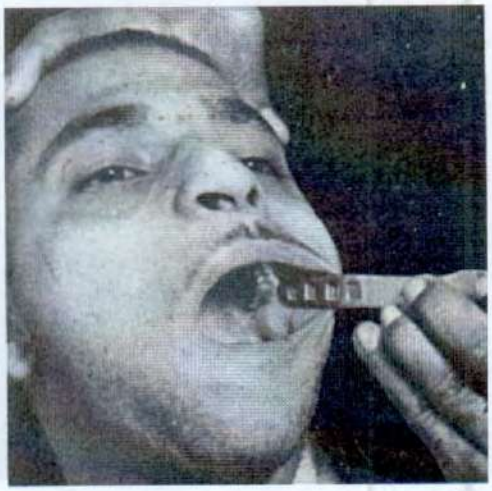

Fig.25.6.— Examining the orifice of the parotid (Stensen's) duct opposite the crown of the upper second molar tooth.

this region. When parotid malignancy is suspected careful examination must be made to exclude if there is infiltration of the skin by the tumour.

(3) **Duct.**— The parotid (Stensen's) duct starts just deep to the anterior border of the gland and runs superficial to the masseter muscle, then it curves inwards to open on the buccal surface of the cheek opposite the crown of the upper second molar tooth. For its proper inspection, one has to retract the cheek with spatula (Fig. 25.6). If one suspects the case to be one of suppurative parotitis, gentle pressure over the gland will cause purulent saliva to come out of the orifice of the duct. Similar pressure may find blood to come out in case of malignant growth of the gland. While the duct rounds over the masseter muscle one can feel the duct by rolling the finger over the taut masseter muscle. The terminal part of the duct is best palpated bidigitally



Fig.25.7.— Bidigital palpation of the terminal part of the parotid duct.

between the index finger inside the mouth and the thumb over the cheek (Fig. 25.7).

(4) **Fistula.**— If there is a parotid fistula, note its position : whether in relation to the gland or the duct (masseteric or premasseteric).

Examine the facial nerve as discussed in page 274.



Figs.25.8 & 25.9.— Examination is being performed to test the integrity of the facial nerve. In the first figure there is no paralysis of the facial nerve whereas in the second figure there is definite paralysis of the facial nerve.

The facial nerve is not involved in a benign tumour of the parotid gland, but is involved in a malignant growth.

Lymph nodes.— Lymph nodes of the neck must be examined as a routine. The preauricular, the parotid and the submandibular groups of lymph nodes are mostly involved.

Movements of the jaw may become restricted if the growth is malignant and has involved the periarticular tissue of temporomandibular joint.

Sialography.— A watery solution of lipiodol (Neohydriol) is injected into the orifice of Stensen's duct and a skiagram is taken. Any obstruction of the duct by a calculus or dilatation of the ducts and acini (sialectasis) may be demonstrated. In parotid fistula, it helps to locate the site of lesion — whether in the main duct or in a ductule.

SUBMANDIBULAR SALIVARY GLAND

History.— Appearance of a swelling in the submandibular region with colicky pain at the time of meals is diagnostic of stone in the submandibular duct. This swelling is tense and painful. *Otherwise, swelling in this region is more often due to lymph node enlargement rather than salivary gland tumours.*

LOCAL EXAMINATION

INSPECTION.— If the patient gives the history which is very much suggestive of a stone in the submandibular salivary duct, the patient may be asked to suck a little lemon or lime juice.



Fig.25.10.— A diagrammatic representation of the position of the facial nerve (F), the parotid gland (P) and the submandibular gland (S).



Fig.25.11.— A swelling of the submandibular salivary gland. The patient states that the swelling gets tense and tender during meals — stone in the salivary gland.



Fig.25.12.— Mikulicz's disease.

The swelling will at once appear. In *Mikulicz's disease* submandibular salivary glands along with the parotid glands and lacrimal glands may be enlarged (Fig. 25.12). Otherwise majority of the swellings in this region are due to enlarged lymph nodes. But a careful palpation must be performed to come to the definite diagnosis rather than biased by assumptions.

Inspection of the orifices of the submandibular (Wharton's) ducts is made by means of a torch on the floor of the mouth. The orifices are situated on either side of the frenulum linguae. It is noted whether each orifice looks inflamed or swollen due to impaction of a stone in the duct. Occasionally a stone may be impacted in the ampulla just deep to the orifice and can be seen if inspected carefully. If the salivary gland is infected, slight pressure on the gland will extrude pus through the respective orifice. If a stone is impacted in one duct, saliva will be seen coming out with normal flow from the other orifice while the orifice concerned remains dry. This may be tested by putting two dry swabs one on each orifice and some lemon juice is given on the dorsum of the tongue. A minute later the patient is asked to move the tongue up and the two swabs are taken out. The swab on the orifice of the duct where the stone is impacted will remain dry.



Fig.25.13.— Examining the orifice of the Wharton's duct.

PALPATION.— Palpation must be done very carefully as lymph node swellings are quite common in this region. Nodular swelling either discrete or matted is suggestive of lymph node enlargement. In case of submandibular salivary gland enlargement, it is one swelling and not a few nodular

swellings. Submandibular salivary gland is best palpated *bimanually*. The patient is asked to open his mouth. One finger of one hand is placed on the floor of the mouth medial to the alveolus and lateral to the tongue and is pressed on the floor of the mouth as far back as possible. The fingers of the other hand, in the exterior, are placed just medial to the inferior margin of the mandible. These fingers are pushed upwards. This helps to palpate both the superficial and deep lobes of the salivary gland. Presence of a calculus is also appreciated by this bimanual examination. *This examination also differentiates an enlarged salivary gland from enlarged submandibular lymph nodes.* The finger inside the mouth can feel the deep part of the salivary gland but not the lymph nodes as the former is situated above the mylohyoid muscle and the latter below the muscle. To exclude impaction of stone in the duct, the whole duct must be palpated bimanually.



Fig.25.14.— Shows bimanual palpation of the submandibular salivary gland.

So far as the lymph node swellings are concerned the students must remember that the swelling may be due to primary or secondary involvements of lymph nodes. For the latter case one must examine thoroughly the inside of the mouth including the upper lip, the lower lip, the cheeks, the tongue and the floor of the mouth.

X-ray.— In case of stone in the salivary gland or duct this special investigation is very helpful, as majority of the stones here are radio-opaque.

DIFFERENTIAL DIAGNOSIS

THE PAROTID GLAND

Congenital sialectasis.— It is a condition of dilatation of the ductules and alveoli, occurring in one gland usually. The symptoms commence in infancy and are characterized by attacks of painful swelling of the parotid gland, often accompanied by fever. Some patients show an allergy to certain food-stuffs. Diagnosis is established by sialography.

Calculus is rarely formed in the parotid gland as the secretion is watery.

Acute suppurative parotitis.— Infection reaches the gland from the mouth and rarely it is blood-borne. There is brawny oedematous swelling over the parotid region with all signs of inflammation. Fluctuation is a late feature owing to the presence of strong fascia over the gland.

The Auriculotemporal (Frey's) Syndrome.— This condition follows injury to the auriculotemporal nerve while incising for the suppurative parotitis. At the time of meals, the parotid region and the cheek in front of it become red, hot and painful; very soon beads of perspiration appear on this area. Cutaneous hyperaesthesia is also present over this area and becomes evident to the patient while shaving.

Acute Parotitis, *due to mumps,* is a nonsuppurative condition. It may be unilateral to start with but becomes bilateral within a few days. It is associated with constitutional disturbances and other manifestations of mumps.

Subacute and chronic Parotitis.— This affection may be unilateral or bilateral. Patient complains of recurrent swelling of the parotid gland. The swelling is particularly seen during meals. The gland feels firmer, slightly tender and rubbery. Diagnosis is confirmed if purulent saliva or watery saliva can be ejected from the opening of the duct while gentle pressure is exerted over the gland.



Fig.25.15.— Acute parotitis due to mumps.

Parotid tumours.— Approximately 90% of the neoplasms of the salivary glands occur in the parotid glands, 10% in the submandibular glands and very rarely in the sublingual and ectopic salivary glands. Approximately 3/4th of the epithelial lesions in the parotid are clearly benign; the remaining 1/4th is composed of definite carcinomas alongwith the muco-epidermoid and acinic cell tumours which are generally considered to be cancers of variable aggressiveness. But in submandibular gland majority of the tumours are malignant. The most common cancers in the salivary glands are in descending order of frequency — muco-epidermoid tumours, adenoid cystic carcinoma, adenocarcinoma, epidermoid carcinoma, undifferentiated carcinomas and carcinomas arising in pleomorphic adenomas (malignant mixed tumours).



Fig.25.16.— A huge parotid tumour. For the last month it is growing rapidly.

After considering the general points, as have been mentioned in the previous paragraph, we now consider classification of the tumours of the salivary glands. They are classified as follows:

(A) **Epithelial tumours.**—

Benign — (1) Pleomorphic adenoma (mixed tumour), (2) Papillary cystadenoma lymphomatosum (adeno-lymphoma or Warthin's tumour) and (3) oxyphil adenoma (oncocytoma).

Malignant.— (1) Mucoepidermoid carcinoma, (2) Adenoid cystic carcinoma, (3) Adenocarcinoma, (4) Epidermoid (squamous cell) carcinoma, (5) Undifferentiated carcinoma and (6) Carcinoma arising in pleomorphic adenoma (malignant mixed tumour).

(B) **Connective tissue tumours :** *Benign* — haemangioma, fibroma, lipoma etc. and *malignant* tumours.

(C) **Metastatic tumours.**

Only the common tumours are described below :

Pleomorphic adenoma (mixed tumour).— This is the commonest tumour of the major salivary glands and its marked feature is histologic diversity. It is called 'mixed' as there is cartilage besides epithelial cells. It is believed that the cartilage is not of mesodermal origin but is derived from mucin secreted from the epithelial cells. It is characterized principally by epithelial and myoepithelial components distributed in varied patterns through an abundant matrix of mucoid, myxoid or chondroid supporting tissue.

Diagnosis is made by the presence of a lobulated and painless swelling over the parotid region being present for many months or years. It is neither adherent to the skin nor to the masseter muscle. The tumour is generally firm but variable consistency is the diagnostic feature. The facial nerve remains free. Sometimes it is difficult to enucleate completely despite encapsulation. Adding to the difficulty, the capsule may at points be thinned and somewhat deficient to define surgically. At such places of capsular deficiency, small pseudopods of tumour may protrude and left behind after enucleation. Thus recurrences following resection are reported to occur from 5 to 50% of cases with a higher incidence in tumours of the minor salivary glands. These recurrences may not become apparent until one to two decades later.

Though rare yet malignant transformation of this tumour may occur in approximately 3% to 5% of cases. This *malignant transformation* is suggested when the tumour (a) becomes painful, (b) starts growing rapidly, (c) feels stony hard and (d) gets fixed to the masseter and mandible deeply or to the skin superficially and (e) involves the facial nerve — an important feature. (f) The cervical lymph nodes are enlarged and (g) movements of the jaw may be restricted.

Papillary Cystadenoma Lymphomatosum (Warthin's tumour).— This represents about 5-15% of parotid tumours and *almost always occurs in the lower portion of the parotid* overlying the angle of the mandible. Infrequently these tumours occur bilaterally or in other salivary glands. It is the only salivary neoplasm that occurs preponderantly in males above 40 years. This tumour presents as a slow growing painless swelling over the angle of the jaw. The overlying skin looks normal. The surface of the swelling is smooth and well defined and the margin is distinct. Consistency is soft, often fluctuate, but not translucent. The regional lymph nodes are *not* enlarged. This tumour was previously considered to be teratoid or branchiogenic in origin. But today it is believed that the tumour is essentially epithelial in origin and that the lymphoid component represents reactive element perhaps of immunologic origin, comparable to that seen in Hashimoto's thyroiditis or Sjogren's syndrome.

This tumour is composed of cystic or glandular spaces lined by columnar epithelium within an abundant lymphoid tissue, harbouring germinal centres. The cells are eosinophilic. Though this tumour may be firm, yet it may be soft and frequently cystic. Irregular papillary processes of tall columnar epithelium project into the cystic spaces.

This tumour is more often seen in white races and not seen in Negroes. These are encapsulated lesions and do not undergo malignant transformation. However they are susceptible to infection and may sometimes be converted into abscesses.

Carcinoma of the parotid gland (adenocarcinoma, epidermoid and undifferentiated carcinoma).— The patients are usually over 50 years of age. Males and females are equally affected. The main complaint is a rapidly enlarging swelling in the parotid region which was painless to start with, but becomes painful at later stage particularly during movements of the jaw. The pain may radiate to the ear and over the side of the face. On examination there is often infiltration of the tumour to the overlying skin, when the skin becomes tethered and reddish blue. It also becomes hyperaemic. But the tumour is not tender (cf. acute parotitis when the swelling is extremely tender). The surface is irregular and the margin is often indistinct. Consistency is firm to hard. The swelling is fixed to deeper structures and gradually restricts the jaw movements. The facial nerve is often infiltrated by the tumour which becomes irritable initially with muscle spasm and ultimately leads to facial paralysis. The cervical lymph nodes are always enlarged and hard. General examination must be made to exclude disseminated blood-borne metastases.

Oxyphil adenoma.— When Warthin's tumour becomes devoid of lymphoid element and is composed entirely of epithelium it is called an oxyphil adenoma.

Mucoepidermoid tumour.— This accounts for 6-8% of all neoplasms in the major salivary glands. This occurs more frequently in parotid rather than submandibular glands. This tumour has variable level of aggressiveness and sometimes subdivided into high, intermediate and low variants. The majority are slow growing cancers which can be successfully treated by adequate radial excision. On cross section they may be solid, cystic or semi-cystic. The fluid within the cyst is clear, mucous or thick turbid secretion. Histologically there are cords or sheets of squamous, mucous or intermediate cells. The cells range from well differentiated cells with small regular nuclei to less differentiated cells with hyperchromatism and mitotic figures in the nuclei. These tumours yield to about 85% 5-years' survival rate.

Adenoid cystic carcinoma (cylindroma).— These are poorly encapsulated infiltrating tumours to which the name 'Cylindroma' is commonly applied. Approximately 10% of the malignant tumours of the salivary gland are of this type. Though this tumour arises more frequently in the parotid glands yet in the submandibular and ectopic salivary glands this represents a higher proportion of all tumours (20%). The tumour cells are small, darkly stained with relatively little cytoplasm and are arranged about the stromal elements in a pseudoglandular (adenoid) pattern. They display a wide range of patterns — either tubular or cribriform or solid. The stroma in most of these tumours is moderately cellular fibrous tissue but is strikingly hyalinized.



Fig.25.17.— Ultrasonography showing calculus in the submandibular salivary duct with enlarged submandibular salivary gland noted as 'mass'.

This tumour is slow growing and may be mistaken as a mixed tumour. But local recurrence and continuous growths involving the surrounding structures soon reveal itself. Local pain is prominent and sometimes an early symptom. The tendency of this tumour to invade the perineural lymphatics accounts for the high frequency of facial nerve paralysis. Five-year cure rate has been quoted as less than 25%.

THE SUBMANDIBULAR SALIVARY GLAND

Calculus.— This is more common in the submandibular than in the parotid gland, as the secretion is more watery in the latter gland. It has the same composition as that of the tartar formed upon the teeth, viz., calcium and magnesium phosphates. It may occur within the gland or its duct. The pathognomonic feature of the salivary calculus is the swelling of the gland during meals, often preceded by salivary colic. When this history is forthcoming, the patient

should be given some lemon juice and the swelling can be reproduced. At the same time examination of the orifice of the affected duct shows little or no ejection of saliva. The stone, if it is situated in the duct, can be easily palpated bidigitally. Radiograph is often helpful in confirming the diagnosis. Ultrasound is nowadays more often used as this non-invasive technique is more competent to detect stone in the submandibular salivary gland or duct.

The tumours of the submandibular salivary glands.— Tumours in this gland are uncommon in comparison to the parotid tumours. Enlargement of this gland is more due to calculus rather than a tumour. Of the tumours seen in this gland, the *mixed* tumour is the commonest. Mixed tumour presents as a slow growing tumour of moderate size. The swelling is hard but not stony hard. One must exclude lymph nodes swelling in this region before coming to this diagnosis.

Carcinoma of the submandibular gland is extremely rare.

THE SUBLINGUAL AND ECTOPIC SALIVARY GLANDS

Mucous cyst (Retention cyst).— This is the result of cystic degeneration of the sublingual salivary gland or of glands of Blandin and Nuhn that are situated in the floor of the mouth or under-surface of the tongue.

Tumours.— Tumours of the minor salivary glands, mostly mixed tumours, are encountered frequently in the palate. The upper lip is second in frequency. But these are also encountered in the nasopharynx, larynx, bronchi and nasal sinuses. Adenoid cystic carcinomas also occur in the bronchi, trachea, pharynx, paranasal sinuses and lacrimal glands.

* * * * * *

Mikulicz's disease (Syndrome).— This disease is characterized by (i) symmetrical and usually progressive enlargement of all the salivary glands — both parotids, both submandibulars, both sublinguals and frequently the accessory salivary glands. (ii) Enlargement of the lacrimal glands. This causes a bulge below and outer ends of the eyelids, thus narrowing the palpabral fissures. (iii) Dry mouth. The enlargement of the lacrimal and salivary glands is due to replacement of the glandular tissue by lymphocytes. Usually the disease occurs in persons between 20 and 40 years of age. In the beginning one salivary gland or often the lacrimal gland is attacked and the disease may be localized in that gland for quite a long time before involving the others. Mikulicz disease is probably due to an autoimmune process in the glands and is often looked upon as a clinical variant of Sjogren's syndrome. The diagnosis is established only by histological examination.

Sjogren's syndrome.— This syndrome is characterized by all the features of Mikulicz's syndrome *plus* (i) dry eyes (keratoconjunctivitis sicca) and (ii) generalized arthritis (rheumatoid). Enlargement of the salivary glands is often not so gross as seen in Mikulicz's disease. Recently other connective tissue diseases such as systemic lupus erythematosus or scleroderma has been seen to be associated with it. In this condition the salivary and lacrimal glands are also infiltrated with lymphocytes and the acini are progressively destroyed. The epithelium of the ducts becomes hyperplastic and may form casts within the lumen blocking smaller ducts. Thus blocking of the ducts, strictures, proximal duct dilatations and ascending infection may complicate the syndrome. This condition is also considered to be an autoimmune disease as autoantibodies and hypergammaglobulinaemia are usually detected. $^{99}Tc^{m}$ Technetium Scan may be performed to know the function of the gland.

Chapter

26 EXAMINATION OF THE NECK (EXCLUDING THE THYROID GLAND)

HISTORY.— The commonest cause of swelling in the neck is enlarged lymph nodes.

Age is useful so far as conditions in the neck are concerned. Sternomastoid 'tumour' occurs in the newborn baby and there is often a history of difficult labour. Both branchial cyst and branchial fistula, though congenital, are more often seen in early adult life. Cystic hygroma is met with in infancy or in early childhood. Inflammatory swellings may occur at any age but commonly seen in early adults. Carcinomatous swelling is more common in the old.



Fig.26.1.— Branchial fistula is shown. Note the typical site.

Swelling.— Swelling is a very common symptom of the lesions of the neck. A careful history to know the *mode of onset* and *duration* is very essential. Swellings with long history are generally benign. Tuberculous lymphadenopathy and cold abscess also give history of more than a month. Quickly-grown swellings within a short span of time are mostly malignant tumours. But swelling due to acute lymphadenitis is also of short duration.

Pain.— It is always an important symptom and question must be asked 'whether the swelling is *painful or not*?' Inflammatory swellings are always painful. This distinguishes acute lymphadenitis from a malignant growth as the former is extremely painful whereas the latter is painless unless in late stages when there may be nerve involvement. A swelling in the submandibular triangle particularly seen during meals with pain is due to calculous obstruction of the duct of the submandibular salivary gland.

LOCAL EXAMINATION

INSPECTION.— For proper inspection of the neck, it has to be exposed upto the level of the nipples. The students often forget of the supra-clavicular fossa. Enlargement of the left supra-clavicular lymph nodes is an important sign so far as the cancer of breast and cancer of many abdominal organs are concerned.

(1) Swelling.— As in other places, whenever there is a swelling, note its *number, situation, size, shape, surface* etc. Multiple swellings indicate the diagnosis of enlarged lymph nodes. The SITUATION is very important as it often indicates the diagnosis by itself. The *branchial cyst**

* Branchial cyst develops from the buried ectodermal pouch formed under the 2nd branchial arch which overlaps the 3rd and the 4th and fuses with the 5th. A branchial fistula is formed if this pouch communicates with the exterior due to failure of fusion. So structures developed from the 2nd branchial arch lie superficial to this fistula whereas structures developed from the 3rd and 4th branchial arches lie deep to this fistula.



Fig.26.2.— Branchial cyst in its typical position.

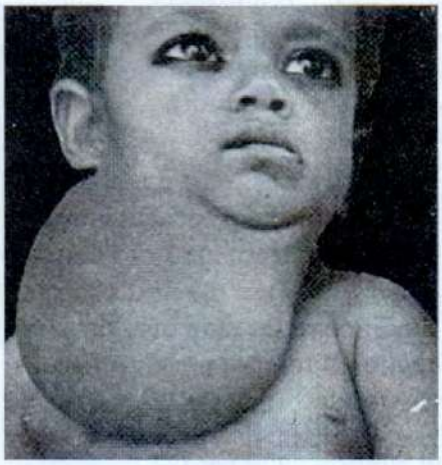

Fig.26.3.— Cystic hygroma.



Fig.26.4.— Deep or plunging ranula in the submandibular triangle.

is situated in the upper part of the neck with its posterior half lying under cover of the upper 3rd of the sternomastoid muscle. In the submandibular triangle, besides lymph nodes, there may be enlarged *submandibular salivary gland* and *deep or plunging ranula*. A *dermoid cyst* occurs in the midline of the neck, either in the most upper part giving rise to double chin or in the most lower part in the space of Burns. *Cystic hygroma* is commonly seen in the posterior triangle of the neck in its lower part. Sometimes in the lower part of the posterior triangle one may look for the prominence of a *cervical rib*. An *aneurysm* is likely to be seen in the line of the carotid artery. An oval swelling along the line of the sternomastoid muscle in a newly-born baby is probably a *sternomastoid 'tumour'*. A *carotid body tumour* lies under the anterior margin of the sternomastoid at the level of bifurcation of the common carotid artery, i.e. at the level of the upper border of the thyroid cartilage. At last the *swellings that occur over the known sites of the lymph nodes should be considered to have arisen from them* unless some outstanding clinical findings prove their origin to be otherwise.

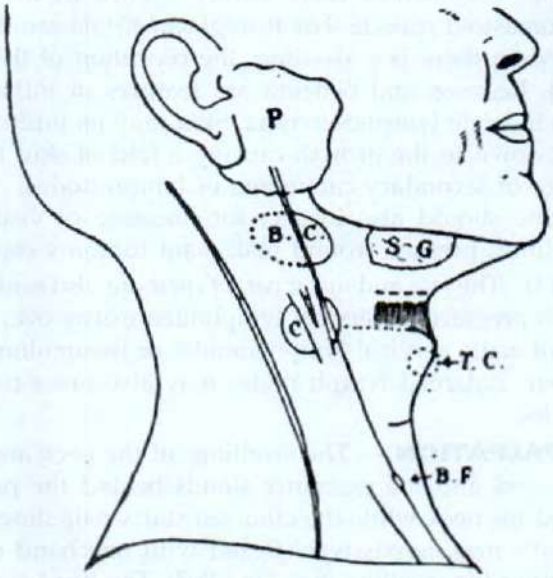

Fig.26.5.— Showing the situation of different swellings of the neck. 'P'–parotid gland; 'S.G.'– sub-mandibular salivary gland; 'B.C.'– Branchial cyst, posterior part is covered by the sternomastoid muscle; 'C'– Carotid body tumour situated behind the bifurcation of the common carotid artery; 'T.C.'– Thyroglossal cyst; 'B.F.'– indicates the position of branchial fistula.

The patient is asked to swallow and note whether the swelling moves on deglutition or not. The swellings which are adherent to the larynx and trachea move upwards on swallowing, e.g. thyroid swelling, thyroglossal cyst and subhyoid bursitis. Tuberculous and malignant lymph nodes when they become fixed to the larynx or trachea will also move on deglutition.

(2) **Skin.**— A sinus, fistula, ulcer or scar should be noted during inspection of the skin of the neck. *Tuberculous sinus or ulcer* arising from bursting of caseous lymph nodes is not uncommon in the neck. Undermining edge is typical of this ulcer. Puckering scar may also be found on the skin after healing of these ulcers or sinuses. *Sinus due to osteomyelitis of the mandible* is usually single and lies a little below the jaw, whereas multiple sinuses over an indurated mass at the upper part of the neck would suggest *actinomycosis*. Sulphur granules in the pus is very much confirmatory of actinomycosis. A *branchial fistula* is seen just in front of the lower 3rd of the anterior border of the sternomastoid muscle. *Gummatous* ulcer rarely occurs in the sternomastoid muscle. For *thyroglossal fistula* see the next chapter.

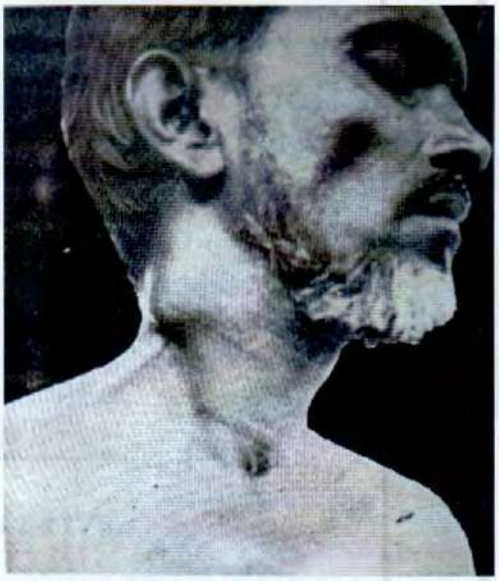

Fig.26.6.— Secondary carcinoma of the lymph nodes. Observe the fold of skin below the swelling. This is due to infiltration of the skin and platysma by the carcinomatous growth.

When there is a swelling, the condition of the skin over the swelling should be carefully noted. Redness and oedema are features of inflammation. Presence of subcutaneous dilated veins indicate lymphosarcoma. Skin may be infiltrated by the *malignant growth* and the skin is stuck down to the growth causing a fold of skin to stand out above it. This is a characteristic feature of secondary carcinoma of lymph nodes.

One should also inspect for presence of visible and dilated cutaneous veins. These are sometimes present around malignant tumours especially the lymphosarcoma.

(3) The *face* and *upper part of chest* are also noticed to see if there is any venous engorgement due to pressure of cervical lymphadenopathy over the jugular vein. There may be torticollis in case of acute cervical lymphadenitis or tuberculous lymphadenitis or in case of sternomastoid tumour. Enlarged lymph nodes may also press on the nearby nerves to cause wasting of the muscles.

PALPATION.— The swellings of the neck are best palpated from behind. The patient sits on a stool and the examiner stands behind the patient. Natural tendency of the patient is to extend his neck while the clinician starts palpating the neck. This obscures the swelling. So the patient's neck is passively flexed with one hand on his head and the other hand is used for palpating the swelling (See Fig. 26.7). The head is also flexed passively towards the side of the swelling for proper palpation. This is to relax the muscles and fasciae of the neck.

(1) **Swelling.**— Examine the swelling systematically noting its situation, size, shape, surface, margin, consistency, reducibility, impulse on coughing, translucency, mobility, pulsation (expansile or transmitted) etc. as discussed in Chapter 3. Mobility should be tested in all directions. A carotid body tumour or an aneurysm can be moved across but not along the line of the carotid artery.



Fig.26.7.— Method of palpating a swelling in the submandibular triangle. Note that the head is passively flexed towards the side of the swelling to relax the muscles and fasciae of the neck.



Fig.26.8.— A cystic hygroma in the posterior triangle of the neck.

Determine the *relation of the swelling with the sternomastoid muscle.* To test one side place your hand on the side of the patient's chin *opposite* to the side of the lesion and tell him to nod the head to that side against the resistance of your hand. To test both sides simultaneously, put your hand under the point of the chin and ask him to press down against resistance when both sternomastoids are put into action. If the swelling lies deep to the muscle which is a common occurrence, it disappears under the taut muscle either completely or partially depending on the size of the swelling; the





Figs.26.9 & 26.10.— Testing for an impulse on coughing and translucency in a case of cystic hygroma shown in Fig. 26.8.

mobility of the swelling becomes very much restricted at the same time. If the swelling is situated superficial to the muscle, it will be more prominent and movable over the contracted muscle.

Whether the swelling has *involved the neighbouring structures* such as the larynx, trachea, oesophagus, blood vessels, nerves etc. should also be determined. A malignant growth lying just below the angle of the jaw may involve the hypoglossal nerve and lead to



Fig.26.11.— Demonstrating the method of making the sternomastoid muscle taut. Relation of a swelling with sternomastoid muscle is quite important in the examination of the neck.

paralysis of the same half of the tongue. The patient is asked to put his tongue out. In case of paralysis, the tongue will deviate towards the side of lesion. *Involvement of the skin* with the growth should also be examined. This is done by pinching the overlying skin off the tumour or by gliding the overlying skin over the tumour. Skin is often involved in case of malignant lymphatic growths and in case of certain benign conditions e.g. acute lymphadenitis or tuberculous lymphadenitis with cold abscess just on the verge of bursting to the exterior.

One should carefully note whether the swelling is *pulsatile* or not. In case of pulsatile swellings one should differentiate between transmitted pulsation and expansile pulsation. In case of aneurysm of the carotid artery there will be expansile pulsation, whereas a tumour in front of the carotid artery will give rise to transmitted pulsation e.g. carotid body tumour or malignant lymph node enlargement around the carotid artery. Cystic hygroma is a brilliantly translucent swelling, whereas branchial cyst or cold abscess are not translucent, so *transillumination test* is also important in case of a swelling of the neck. Any cystic swelling of the neck will elicit *fluctuation test* positive e.g. cystic hygroma, branchial cyst, thyroglossal cyst, dermoid cyst, subhyoid bursal cyst, cold abscess and pharyngeal pouch.

(2) **Lymph nodes.**— In case of palpation of the cervical lymph nodes one should follow the same technique as used for palpation of swelling in the neck. A system should be maintained to palpate all the groups of lymph nodes in the neck. It may be started from below with supraclavicular group, then moving upwards palpating the lymph nodes in the posterior triangle, jugulo-omohyoid group, jugulodigastric, submandibular, submental, preauricular and occipital groups. (a) In case of enlargement of lymph node one should examine the *drainage area* for inflammatory or neoplastic focus. (b) *Other groups of lymph nodes* lying in other parts of the body should also be examined in case of enlargement of cervical lymph nodes. These groups include the axillary, the inguinal and abdominal groups. The causes of generalized enlargement of lymph nodes are discussed in chapter 8. (c) The *spleen* and the *liver* should be examined in case of Hodgkin's disease and (d) the *lungs* for tuberculosis.



Fig.26.12.— Shows the method of palpation for enlargement of lymph nodes by the side of internal jugular vein. Note that the head is passively flexed towards the side of examination to relax the muscles and fasciae of the neck.



Fig.26.13.— Examining the inside of the mouth as well as the tonsils in case of enlarged lymph nodes at the angle of mandible.

Examination of the drainage area.— If the *submental group* is involved examine the chin, central part of the lip, gingiva, floor of the mouth and tip of the tongue. If the *submandibular group* is affected, one should examine the palate, the tongue, floor of the mouth, the lower lip, cheek, gingiva, nose and antrum. Involvement of the *jugular chain* should draw one's attention to the tongue, mouth, pharynx, larynx, upper oesophagus and thyroid. The *tonsillar node* which

lies below the angle of the mandible at the junction of the facial vein and the internal jugular vein may be enlarged in case of inflammatory or neoplastic lesion of the tonsil. If the *supraclavicular (Virchow's) nodes* are enlarged (Troisier's sign), one should examine not only the arm, breast and chest (bronchus) but also the abdomen right down to the testis.

Percussion.— This is not very important examination, yet a rare disease — laryngocele may be revealed by the tympanic note which is connected with the larynx through a narrow neck. The swelling becomes more apparent when the patient blows his nose.

Auscultation.— A bruit may be heard over an aneurysm or carotid body tumour.

Movements.— A patient with cold abscess of the posterior triangle of the neck may not be able to move his neck due to tuberculous affection of the cervical vertebrae. All movements of the neck will be restricted. Care must be taken to minimise forceful movements of the neck as sudden death is on record following examination of movements of the neck in this condition from dislocation of the atlanto-axial joint (the dens pressing on the medulla).

Special investigations will be carried out along the lines discussed in chapter 3 and 8. The fluid *aspirated* from a branchial cyst often contains cholesterol crystals. X-ray is helpful in the diagnosis of the caries of the cervical spine and cervical rib. A radio-opaque fluid (uropac) may be injected into a branchial fistula to determine its extent. A complete fistula will extend upto the supra-tonsillar fossa. Barium swallow (a little amount) or urograffin pushed through a Ryle's tube will diagnose pharyngeal pouch in skiagraphy. In case of secondary malignant lymph nodes (a) *Laryngoscopy* if laryngeal carcinoma is suspected, (b) *bronchoscopy*, if bronchial carcinoma is suspected, (c) *X-ray chest* and *mediastinoscopy* if mediastinal growth or lung cancer is suspected, (d) *Oesophagoscopy* and *barium swallow* in oesophageal cancer and (e) *mammography* in case of breast cancer may be performed to come to a definite diagnosis. Above all excision biopsy of the affected lymph nodes is of immense value.

DIFFERENTIAL DIAGNOSIS OF SWELLINGS OF THE NECK

For differential diagnosis, swellings of the neck can be divided into (a) midline swellings and (b) lateral swellings according to their site of origin.

Midline swellings of the neck from above downwards are : Ludwig's angina, enlarged submental lymph nodes, sublingual dermoid and lipoma in the submental region; thyroglossal cyst and subhyoid bursitis; goitre of the thyroid isthmus and pyramidal lobe, enlarged lymph nodes and lipoma in the suprasternal space of Burns, retrosternal goitre and thymic swelling. A dermoid cyst may occur anywhere in the midline.

Lateral swellings according to their sites may be divided into the following regions :—

(i) *SUBMANDIBULAR TRIANGLE.*— Besides the lymph nodes and enlarged submandibular salivary gland, there may be deep or plunging ranula and extension of growth from the jaw. (ii) In the *CAROTID TRIANGLE* aneurysm of the carotid artery, carotid body tumour, branchial cyst and branchiogenic carcinoma may be met with. Thyroid swellings will be deep to the sternomastoid, a sternomastoid tumour may develop in a new-born baby. (iii) In the *POSTERIOR TRIANGLE* — besides enlarged supraclavicular lymph nodes, there may be cystic hygroma, pharyngeal pouch, subclavian aneurysm, aberrant thyroid, cervical rib, lipoma (Dercum's disease) etc.

For clinical diagnosis the swellings of the neck may also be divided into acute and chronic swellings. **Acute swellings** are cellulitis including Ludwig's angina, boil, carbuncle and acute lymphadenitis. **Chronic swellings** may be further subdivided into : (a) *Cystic* — Branchial cyst,

thyroglossal cyst, dermoid cyst, cystic hygroma, sebaceous cyst, cystic adenoma of the thyroid gland, cold abscess etc. (b) *Solid* swellings are swellings arising from thyroid, branchiogenic carcinoma, sternomastoid tumour etc. (c) *Pulsatile* swellings are aneurysm of the carotid or subclavian artery, Carotid body tumour, lymph node swellings lying in close proximity to the carotid artery to elicit transmitted pulsation and a few primary toxic goitre.

Brief descriptions of the important swellings of the neck are described below :

Lymph node swellings.— No doubt lymph node swellings occupy the most important position so far as the swellings of the neck are concerned. Of the lymph node swellings, tuberculous lymph nodes, carcinomatous lymph nodes (secondary) and various types of lymphoma comprise major components in this group.



Fig.26.14.— A typical case of cervical lymph node enlargement due to tuberculosis.

Tuberculous lymph nodes.— In Indian subcontinent, this is probably the commonest cause of lymph node swelling in the cervical region. The pathology passes through various stages and has been discussed in detail in chapter 8. The first stage is solid enlargement which goes by the name of lymphadenitis. Subsequently periadenitis develops and the glands become matted. Later on the whole matted mass liquifies and "cold abscess" develops deep to the deep cervical fascia. Fluctuation can be elicited with difficulty at this stage due to the presence of tough fascia superficial to the abscess. In a very late stage the deep cervical fascia gives way forming a "collar stud" abscess. At this stage fluctuation can be elicited more easily. In the last stage, the skin over the swelling becomes inflamed and the abscess finds its way out through a sinus which refuses to heal.

Carcinomatous lymph nodes (secondary).— Usually the patients are elderly above 50 years of age. The only exception is papillary carcinoma of the thyroid, which occurs and metastasises at young age. Men are usually more often affected than women. The swelling is always painless and grows relatively fast. New lumps may appear by the side. On examination there is no rise of temperature and the swelling is not tender. The surface is usually nodular and the consistency is hard (often stony hard). The swelling may be fixed to the skin and to the deeper structures at later stage, so the swellings become immobile at this stage. Majority of these swellings lie deep to the anterior edge of the sternomastoid muscle. Rarely such swelling may be pulsatile when it lies just in front of the carotid artery. The students must remember that the greater cornu of the hyoid bone may be mistaken for carcinomatous lymph nodes. The patient may be asked to swallow, in which case the bone will move up but not the lymph nodes. Whenever a secondary carcinomatous lymph node is detected, a careful search should be made for the primary focus in the mouth, tongue, nasopharynx, larynx, thyroid, external auditary meatus, lungs and in case of left supraclavicular lymph nodes, the abdomen and testis.

Lymphoma.— In this group the common members are Hodgkin's disease, lymphosarcoma and reticulosarcoma. Detail description of these tumours are laid down in chapter 8.

Cellulitis.— Cellulitis in the neck is the most serious form of its kind. The inflammatory exudates are held tightly under tension by the unyielding deep cervical fascia. So the diagnosis becomes late. The neck becomes stiff and very painful with swelling in the submental region. This inflammatory exudate tends to track down towards the mediastinum. *Ludwig's angina* is the most serious form of cellulitis which affects the floor of the mouth and submental region. It produces a diffuse swelling beneath the jaw with redness and oedema at that region. Besides fatal septicaemia, oedema glottis is the most dangerous and final complication of this condition.

Branchial cyst.— Though congenital, it does not appear before adolescence and early adult life. The commonest way of presentation is the (painless) cystic swelling of the upper part of the neck half in front and half deep to the sternomastoid muscle. The cyst is usually ovoid in shape with its long axis running forwards and downwards.. Majority of branchial cysts are between 5 and 10 cm wide. Its surface is smooth and the margin is distinct. The consistency depends on the tension of fluid inside the cyst. When lax it feels soft and when tense it is hard. Fluctuation test is positive. Transillumination test is usually negative. The content of the cyst is thick and white and contains desquamated epithelial cells. The fluid may be golden yellow containing fat globules and cholesterol crystals. This cyst cannot be compressed or reduced. The local deep cervical lymph nodes are usually not enlarged. If these are palpable you should reconsider the diagnosis in favour of cold abscess or so. The cyst may become inflamed and confuses the clinician to be misdiagnosed as an inflammatory swelling. The diagnosis is confirmed by finding cholesterol crystals in the aspirate.

Branchiogenic carcinoma.— This condition is very rare and diagnosis is made mainly by exclusion. Whenever a swelling in the neck is deemed to be carcinomatous, possibility of secondary carcinomatous lymph nodes should be considered and a thorough search should be made for the primary focus. If the primary source is not available, one may think in the line of branchiogenic carcinoma. It is a tumour arising from the remnants of branchial cleft.

Cystic hygroma.— It is a type of congenital lymphangioma and the common victims are infants and children. The swelling is soft cystic and brilliantly translucent as it contains clear fluid. As it is a multilocular swelling fluid of one locule can be *compressed* into the other. It generally positions itself at the root of the neck and may extend its pseudopods deep into the muscles or down to the mediastinum and pectoral region. Mediastinal extension may be suspected if it shows impulse on coughing. The swelling is a multilocular one but occasionally it may be unilocular where the term 'hydrocele of the neck' is used. It may be inflamed as a result of nasopharyngeal infection to cause some confusion to the diagnosis. There is no lymph node enlargement unless infected. Occasionally it may occur in other places like axilla, mediastinum and very rarely in the groin.

Branchial fistula.— It is diagnosed by the typical site of the external orifice of this fistula which is situated in the lower 3rd of the neck near the anterior border of the sternomastoid. Occasionally it may be bilateral. This fistula represents a persistent 2nd branchial cleft. This fistula is a congenital one and must not be confused with an acquired sinus which may result from incision of an inflamed branchial cyst. In this case the sinus will be situated in the upper 3rd of the neck. This fistula often becomes the seat of recurrent attacks of inflammation. The fistula often discharges mucus, the amount of which varies. This fistula is frequently a sinus that is an incomplete one. When complete the internal orifice of the fistula is situated on the anterior aspect of the posterior pillar of the fauces.

Pharyngeal pouch.— It is a pulsion diverticulum of the pharynx through the gap between the lower horizontal fibres and upper oblique fibres of the inferior constrictor muscle. The victims of this condition are usually, but not necessarily, the middle-aged or old men. The main complaint

is regurgitation of undigested food long time after meal. It may be during turning from one side to the other at night, when the patient wakes up by a bout of coughing or during swallowing of the next meal. At this stage abscess of the lung may result from aspiration from the pouch. In the last stage gurgling noise in the neck may be heard when the patient swallows. The pouch may form a visible swelling in the posterior triangle of the neck particularly when the patient drinks. Increasing dysphagia is probably the last symptom which compels the patient to visit a surgeon. Radiology with a very thin emulsion of barium particularly in semi-lateral view is diagnostic.

Laryngocele.— This is an air-containing diverticulum from herniation of the mucous membrane through the thyrohyoid membrane at the point where it is pierced by the superior laryngeal vessels. It is a resonant swelling and appears prominently when the patient blows his noses. It is probably commoner in trumpet-blowers, glass-blowers and those with chronic cough.

Sternomastoid 'tumour'.— It is a swelling in the middle third of the sternomastoid muscle which results from birth injury. It is seen in new born babies. It is a circumscribed firm mass within the muscle. This swelling usually subsides spontaneously but the abnormal segment of muscle becomes fibrotic and contracted which may, later on, lead to torticollis. The tumour is fusiform with its long axis along the line of sternomastoid muscle. Its surface is smooth. Its anterior and posterior margins are distinct whereas upper and lower margins are indistinct and continuous with normal muscle. At first the lump is firm, gradually becomes hard and then begins to shrink.

Carotid body tumour.— This tumour is located at the bifurcation of the common carotid artery. It forms a slowly growing painless hard ovoid lobulated swelling, which is movable laterally but not vertically. Transmitted pulsation is often seen. A few patients complain of attacks of faintness on pressure over the lump — carotid body syncope. It is a very slowly growing tumour and remains localized for years. Regional metastasis occurs in 1/5th of the cases and distant metastasis is almost unknown.

Cervical rib.— See page 93.

TORTICOLLIS



Fig.26.15.— A case of torticollis.

Torticollis or wryneck is a deformity in which the head is bent to one side whilst the chin points to the other side (Fig. 26.15). In long-standing cases, there may be atrophy of the face on the affected side. The measurement from the outer canthus of the eye to the angle of the mouth is smaller, the eyebrow is less arched, the nose is somewhat flattened and the cheek is less full than on the sound side. These phenomena are probably due to imperfect vascular



Fig.26.16.— A case of torticollis.

supply resulting from the restricted mobility. The different varieties of wryneck are : (a) *Congenital.*— The diagnosis is made by a history of difficult labour, followed by the appearance of a sternomastoid 'tumour'. The affected muscle feels firm and rigid. (b) *Traumatic* — fracture-dislocation of the cervical spine. (c) *Rheumatic* — sudden appearance of wryneck after an exposure to cold or draught is suggestive. (d) *Inflammatory* — e.g. from inflamed cervical lymph nodes. (e) *Spasmodic* — when the sternomastoid of the affected side and the posterior cervical muscles of the opposite side are found in a state of spasm. (f) *Compensatory* — e.g. from scoliosis, defect in sight (ocular torticollis). (g) *From Pott's disease* of the cervical spine. (h) *From contracture* — e.g. after burns, ulcers etc.

Chapter

27 EXAMINATION OF THE THYROID GLAND

HISTORY.— 1. **Age** of the patient is a very important consideration. *Simple goitre* is commonly seen in girls approaching puberty. In endemic areas deficient iodide is the cause of the simple goitre. Goitrogens and dyshormonogenesis are also the causes of simple goitre. These are mainly found in teen-aged girls. Where hormone production is not very much below the normal level, simple goitre may appear in conditions of need e.g. puberty and pregnancy when requirement of hormone is augmented. Both *multinodular* and *solitary nodular goitres* as well as *colloid goitres* are found in women of 20s and 30s. A word of caution is very much in need in this context — carcinoma of thyroid is not necessarily a disease of old age. *Papillary carcinoma* is seen in young girls and *follicular carcinoma* in middle-aged women. Of course, *anaplastic carcinoma* is mainly a disease of old age. In case of *primary toxic goitre*, the patients are usually young, whereas in *Hashimoto's disease* the victims are usually middle-aged women. Patients with unbalanced psychic condition is seen in case of primary thyrotoxicosis. Worry and anxiety are always the embarassing features of this condition.

2. **Sex.**— Majority of thyroid disorders are seen in females. All types of simple goitres are far more common in the female than in the male. Thyrotoxicosis is eight times commoner in females than in males. Even thyroid carcinomas are more often seen in females in the ratio of 3 : 1.

3. **Occupation.**— Though occupation has hardly any relation with thyroid disorders, yet thyrotoxicosis may appear in individuals working under stress and strain. The patients with primary toxic goitre may be psychic.

4. **Residence.**— Except endemic goitre due to iodine deficiency, no other thyroid disorder has any peculiar geographical distribution. Certain areas are particularly known to have low iodine content in the water and food. Residents of these areas often suffer from iodine deficiency endemic simple goitre. These areas are near rocky mountains e.g. Himalayas, the Vindyas, the Satpuda ranges which form the goitre belts in India. Such goitre is also probably more common in Southern India than in Northern India. In Great Britain such areas are in the Mendips, Derbyshire, Yorkshire etc. Endemic goitre is also found in low land areas where the soil lacks iodides or the water supply comes from far away mountain ranges e.g. Great Lakes of North America. In the mountains of Bulgaria arises the river Struma, which flows into the Aegean Sea. Along its banks and those of its tributaries endemic goitre has been prevalent. Calcium is also goitrogenic and areas producing chalk or lime stone are also goitrogenic areas e.g. Southern Ireland and Derbyshire.

5. **Swelling.**— In case of thyroid swellings history about the *onset, duration, rate of growth* and whether *associated with pain* should be noted. In case of any thyroid swelling it should be asked 'how does the patient sleep at night?' 'Does she spend sleepless nights?' In primary thyrotoxicosis patients often complain of sleepless nights. Whether the patient is very worried, stressed or strained. These are also features of thyrotoxicosis. Palpitation and ectopic beats and

even congestive cardiac failure may be noticed in cases of secondary thyrotoxicosis. These symptoms may develop in already existing thyroid swelling cases for years. In secondary thyrotoxicosis the brunt of the attack falls more on the cardiovascular system, whereas in primary thyrotoxicosis the brunt of attack falls more on the nervous system. Sudden increase in size with pain in a goitre indicates haemorrhage inside it. A thyroglossal cyst may be present since birth. The rate of growth of the swelling is quite important. While simple goitre grows very slowly or may remain of same size for quite sometime, multinodular goitre or solitary nodular goitre or colloid goitre increases in size though extremely slowly for year. These goitres may also increase in size little faster than before. A special feature of papillary and follicular carcinoma of the thyroid is their slow growth. They may exist as a lump in the neck for many year before metastasising. Anaplastic carcinoma however is a fast growing swelling.

6. **Pain.**— The goitre is usually a painless condition. Inflammatory conditions of thyroid gland are painful. Malignant diseases of the thyroid gland are painless to start with, but become painful in late stages. In Hashimoto's disease there is discomfort in the neck. Anaplastic carcinoma is more known to infiltrate the surrounding structures and the nerves to cause pain.

7. **Pressure effects.**— Enlarged thyroid may press on the trachea to cause *dyspnoea* or may press on the oesophagus to cause *dysphagia* or press on the recurrent laryngeal nerve to cause *hoarseness of the voice*. It must be remembered that thyroid swellings can rarely obstruct the oesophagus as it is a muscular tube and can be easily stretched or pushed aside. As in the first stage of deglutition the thyroid gland moves up, so an enlarged thyroid gland makes swallowing uncomfortable but usually this is not true dysphagia. An enlarged thyroid may compress on the trachea or deviate it to one side or the other to cause difficulty in breathing. This symptom is often worse when the neck is flexed forwards or laterally. When air rushes through a narrowed trachea, a whistling sound is produced which is called *stridor*. Hoarseness is usually due to paralysis of one recurrent laryngeal nerve and anaplastic carcinoma infiltrating the nerve is often the cause.

8. **Symptoms of primary thyrotoxicosis.**— It is quite important to know the symptoms of primary thyrotoxicosis as often in these cases there is not much enlargement of the thyroid gland and only these symptoms will indicate the presence of this disease. The most significant symptom is *loss of weight* inspite of good appetite. *Preference for cold* and intolerance to heat and *excessive sweating* are the next symptoms. Nervous excitability, irritability, insomnia, tremor of hands and weakness of muscles are the symptoms of involvement of nervous system which are the main features of primary thyrotoxicosis. Cardiovascular symptoms are not so pronounce as seen in secondary thyrotoxicosis, but even then palpitation, tachycardia (rise in sleeping pulse) and dyspnoea on exertion are symptoms of this disease. Exophthalmos is often associated with this condition. The patient may complain of *staring* or *protruding eyes* and difficulty in closing her eye lids. Double vision or diplopia may be caused by muscles weakness (ophthalmoplegia). Oedema or swelling of the conjunctiva (chemosis) is seen in very late cases of exophthalmos alongwith persistent primary thyrotoxicosis. Ultimately the patient may get pain in the eye if the cornea ulcerates. Some women may have a change in menstruation, usually amenorrhoea.

9. **Symptoms of secondary thyrotoxicosis.**— When a longstanding solitary nodular goitre or multinodular goitre or colloid goitre shows manifestations of thyrotoxicosis the condition is called *secondary thyrotoxicosis*. As mentioned above the brunt of the attack falls more on the cardiovascular system than on the nervous system. Palpitations, ectopic beats, cardiac arrhythmias, dyspnoea on exertion and chest pain are the usual symptoms. Even congestive cardiac failure may appear at late stage with swelling of ankles. Nervous symptoms and eye symptoms may be mild or absent.

10. **Symptoms of myxoedema (Hypothyroidism).**— Increase of weight is often complained of inspite of poor appetite. Fat accumulates particularly at the back of the neck and shoulders. Intolerance of cold weather and preference for warm climate is noticed. There is minimal swelling of thyroid. The skin may be dry. There may be puffiness of the face with pouting lips and dull expression. Loss of hair is a characteristic feature and 2/3rds of the eyebrows may fall off. Muscle fatigue and lethergy are important symptoms with failing memory and mild hoarseness due to oedema of vocal cords. Constipation and oligomenorrhoea are sometimes complained of.

11. **Past history.**— Enquiry must be made about the course of treatment the patient had and its effect on the swelling. In case of thyroglossal fistula there may be a previous history of an abscess (an inflamed thyroglossal cyst) which was incised or burst spontaneously. The patient should also be asked if she was taking any drugs e.g. PAS or sulphonilurea or any antithyroid drugs as these are goitrogenic.

12. **Personal history.**— Dietary habit is important as vegetables of the brassica family (cabbage, kale and rape) are goitrogens. Persons who are in the habit of taking a kind of sea fish which has particularly low iodine content, may present with goitre.

13. **Family history.**— It is often seen that goitres occur in more than one member in a family while endemic goitres may affect more members in the same family. Similarly enzyme deficiency within the thyroid gland which are concerned in the synthesis of thyroid hormones are also seen to run in families. Primary thyrotoxicosis has been seen in more than one member of the same family. Thyroid cancers are seen to involve more than one member of the same family.

A. PHYSICAL EXAMINATION

GENERAL SURVEY.— 1. **Build and State of Nutrition.**— In thyrotoxicosis the patient is usually thin and underweight. The patient sweats a lot with wasting of muscles and in hypothyroidism the patient is obese and overweight. In case of carcinoma of thyroid there will be signs of anaemia and cachexia.

2. **Facies.**— In thyrotoxicosis one can see the facial expression of excitement, tension, nervousness or agitation with or without variable degree of exophthalmos. In hypothyroidism one can see puffy face without any expression (mask-like face).

3. **Mental state and intelligence.**— Hypothyroid patients are naturally dull with low intelligence. This is more obvious in cretins.

4. Not only the pulse rate becomes rapid, but it becomes irregular in thyrotoxicosis. Irregularity is more of a feature of secondary thyrotoxicosis. Particularly *sleeping pulse rate* is a very useful index to determine the degree of thyrotoxicosis. In case of mild thyrotoxicosis, it should be below 90, whereas in case of moderate or severe thyrotoxicosis it should be between 90 to 110 and above 110 respectively. In hypothyroidism the pulse becomes slow (bradycardia).

5. **Skin.**— The *skin* is moist particularly the hands in case of primary thyrotoxicosis. The clinician while feeling for the pulse should take the opportunity to touch the hand as well. Hot and moist palm to come across in primary thyrotoxicosis. Skin is dry and inelastic in myxoedema.

B. LOCAL EXAMINATION

Examination of the thyroid swelling should be made as discussed in Chapter 3 under 'Examination of a swelling', besides these examinations peculiar to the thyroid gland will be described below :

INSPECTION.— Normal thyroid gland is not obvious on inspection. It can be seen only when the thyroid gland is swollen. In case of obese and short-necked individual inspection of the thyroid gland becomes more difficult. To render inspection easier one can follow *Pizzillo's method* (Figs.27.6 and 27.7) in which the hands are placed behind the head and the patient is asked to push her head backwards against her clasped hands on the occiput. The thyroid swelling may be uniform involving the whole of the thyroid gland (physiological goitre, colloid goitre, Hashimoto's disease etc.) (See Fig. 27.4) or isolated nodules of different sizes may be seen in the thyroid region (See Fig. 27.5) (nodular goitre). Rarely a swelling on the lateral side of the neck is not due to enlargement of an aberrant thyroid gland but is caused by metastasis in lymph nodes from hidden carcinoma of the thyroid gland.



Figs.27.1 & 27.2.— Nodular goitre. Note how the swelling moves up during swallowing in the second picture.

Ask the patient to swallow and watch for the most important physical sign — ***a thyroid swelling moves upwards on deglutition.*** This is due to the fact that the thyroid gland is fixed to the larynx. *Other swellings which may move on deglutition* are thyroglossal cysts, subhyoid bursitis and prelaryngeal or pretracheal lymph nodes fixed to the larynx or trachea. Such movement of the thyroid becomes greatly limited when it is fixed by inflammation or malignant infiltration.

In *retrosternal goitre*, pressure on the great veins at the thoracic inlet gives rise to dilatation of the subcutaneous veins over the upper anterior part of the thorax. When these are present, ask the patient to swallow and determine, on inspection, the lower border of the swelling as it moves up on deglutition. This is not possible in case of retrosternal goitre. The patient should be asked to raise both the arms over his head until they touch the ears. This position is maintained for a while. Congestion of face and distress become evident in case of retrosternal goitre due to obstruction of the great veins at the thoracic inlet.

A *thyroglossal cyst* also moves upwards on



Fig.27.3.— The typical position of a thyroglossal cyst.



Fig.27.4.— A typical case of colloid goitre.

deglutition. But the pathognomonic feature is that it moves upwards with protrusion of the tongue since the thyroglossal duct extends downwards from the foramen caecum of the tongue to the isthmus of thyroid gland.

Thyroglossal fistula is seen near the midline a little below the hyoid bone. The opening of the fistula is indrawn and overlaid by a crescentic fold of skin (See Fig. 27.34).



Fig.27.5.— A typical case of solitary nodule of the thyroid.

PALPATION.— The thyroid gland should always be palpated with the patient's neck slightly flexed. The gland may be palpated from behind and from the front. The patient should be sitted on a stool and the clinician stands behind the patient. The patient is asked to flex the neck slightly. The thumbs of both the hands are placed behind the neck and the other four fingers of each hand are placed on each lobe and the isthmus (See Figs. 27.12 & 27.13). Palpation should be carried out in their entirety. Careful assessment of the margins of the thyroid gland is important, particularly the lower margin. Additional information about one lobe may be obtained by relaxing the sternomastoid muscle of that side by flexing and rotating the face to the same side.



Figs.27.6 & 27.7.— Shows how Pizzillo's method improve inspection of a goitre. The first figure shows inspection in normal position and the 2nd figure shows Pizzillo's technique.

To get more information about a particular nodule of the thyroid gland one may ask the patient to extend the neck. This only makes the nodule more prominent for better palpation.

Palpation of each lobe is best



Figs.27.8 & 27.9.— Show that the thyroglossal cyst moves up with protrusion of the tongue.

carried out by Lahey's method. In this case the examiner stands *in front* of the patient. To palpate the left lobe properly, the thyroid gland is pushed to the left from the right side by the left hand of the examiner. This makes the left lobe more prominent so that the examiner can palpate it thoroughly with his right hand.

During palpation the patient should be asked to swallow in order to settle the diagnosis of the thyroid swelling. Slight enlargement of the thyroid gland or presence of nodules in its substance can be appreciated by simply placing the thumb on the thyroid gland while the patient swallows. (Crile's method).

During palpation the following points should be noted :—

(i) ***Whether the whole thyroid gland is enlarged?*** If so, note its surface — whether it is smooth (primary thyrotoxicosis or colloid goitre) or bosselated (multinodular goitre) and its consistency whether uniform or variable. It may be firm in case of primary thyrotoxicosis, Hushimoto's disease etc., it is slightly softer in colloid goitre and hard in Riedel's thyroiditis or carcinoma in which the consistency may be variable in places.

(ii) ***When a swelling is localized,*** note its position, size, shape, extent and its consistency. It must be remembered that a cystic swelling in the thyroid gland often feels firm due to great tension within the cyst which is surrounded by relatively soft surrounding tissue of the gland. A calcified cyst may even feel hard.

(iii) The ***mobility*** should be noted in both horizontal and vertical planes. Fixity means malignant tumour or chronic thyroiditis.

(iv) ***To get below the thyroid gland*** is an important test to discard the possibility of retrosternal extension. Clinician's index finger is placed on the lower border of the thyroid gland. The patient is asked to



Fig.27.10.— A large solitary nodular goitre in a woman of 40 years of age.



Fig.27.11.— Shows how to get below the thyroid swelling to exclude presence of retrosternal prolongation. The patient is asked to swallow. The thyroid swelling moves up. Clinician now puts his fingers at the lower margin of the thyroid to be sure that there is no further downward extension of the thyroid tissue.





Figs.27.12 & 27.13.— Show the method of palpation of the thyroid gland from behind. Note how the thumbs are placed on the occiput to flex the neck in the lateral view (Fig. 27.12), and how the four fingers are placed on the lobes of the thyroid for better palpation in the anteroposterior view (Fig. 27.13).

swallow, the thyroid gland will move up and the lower border is palpated carefully for any extension downwards (See Fig. 27.16).

(v) ***Pressure effect*** from the thyroid swelling should be carefully looked for. Pressure may be on the *trachea* or *larynx*, which may lead to stridor (inspiratory noise of inrushing air through narrowed trachea) and later on dyspnoea. Pressure may be on the *oesophagus* which may lead to dysphagia. Pressure may be on the *recurrent laryngeal nerve*, which may lead to hoarseness of voice. Pressure may be on even the *carotid sheath*. If pressure on trachea is suspected, slight push on the lateral lobes will produce stridor **(Kocher's test)**. This test, if positive, indicates an obstructed trachea.



Fig.27.14.— Shows the Lahey's method of palpation of each lobe of the thyroid gland. The right lobe is pushed to the right by the examiner to make the lobe prominent for better palpation.

Kocher's test.— Gentle compression on lateral lobes



Fig.27.15.— Lahey's method for palpation of the right lobe of the thyroid gland. In this case the right lobe is pushed to the right by the right hand of the clinician to make it more prominent, so that he can palpate with his left hand easily.



Fig.27.16.— Shows how to get below the thyroid gland. The patient is asked to swallow. The thyroid gland will move up and the lower border is palpated carefully to exclude any extension downwards.



Fig.27.17.— Shows how to palpate the trachea to ascertain its position or any pressure effect being exerted on it due to thyroid enlargement.

may produce stridor. This is due to narrow trachea. This test is particularly positive in multinodular goitres and carcinoma infiltrating into trachea which produce narrowed trachea. The position of the larynx and trachea should also be noted. This may be assessed by placing stethoscope on the suspected zone. Passage of air will indicate the position of the trachea. Simple palpation by an experienced hand will indicate the position of the trachea. Finally X-ray may be advised to know the exact position of the trachea. Narrowing of the trachea, i.e. 'Scabbard' trachea becomes quite obvious in skiagram. The carotid sheath may be pushed backward by a benign swelling of the thyroid gland where the pulsation of the carotid artery may be felt (Fig. 27.19). A malignant thyroid may engulf the carotid sheath completely and pulsation of the artery cannot be felt. Sympathetic trunk may also be affected by thyroid swelling. This will lead to Horner's syndrome, i.e. slight sinking of the eye-ball into the orbit (enophthalmos), slight drooping of the upper eye lid (pseudoptosis), contraction of the pupil (miosis) and absence of sweating of the affected side of the face (anhidrosis). Obstruction to the major veins in the thorax causes **engorgement of neck veins** are not uncommon. This sign becomes obvious when the patients are asked to raise the hands above the head and the arms touch the ears. This is known as **Pemberton's sign.**

(vi) Whether there is any ***toxic manifestation*** or not. Primary toxic thyroid is generally not enlarged whereas an enlarged thyroid or nodular thyroid with toxic manifestation is generally a case of secondary thyrotoxicosis. In this case the brunt of attack is generally borne by the cardiovascular system whereas in primary thyrotoxicosis it is the nervous system which is mainly affected.



Fig.27.18.— Shows how to feel for carotid pulsation. A malignant thyroid may engulf the carotid sheath so that no pulsation can be felt.



Fig.27.19.— Shows how to feel for the carotid pulsation in case of thyroid enlargement. In certain pathological conditions of the thyroid the pulse may be obliterated. See the text.



Fig.27.20.— Auscultation of the thyroid to exclude presence of bruit there.

(vii) Whether there is any evidence of myxoedema or not.
(viii) Whether the swelling is a malignant one or a benign one.
(ix) Is there any pulsation or thrill in the thyroid?
(x) ***Palpation of cervical lymph nodes.***— This is extremely important particularly in malignancy of thyroid. Occasionally only cervical lymph nodes may be palpable, while the thyroid gland remains impalpable. Papillary carcinoma of thyroid is notorious for early lymphatic metastasis when the primary tumour remains quite small. Such enlargement was called 'aberrant thyroid' previously, which is nothing but metastatic enlarged lymph nodes.

Percussion.— This is employed over the manubrium sterni to exclude the presence of a retrosternal goitre. This is more of theoretical importance rather than practical.

Auscultation.— In primary toxic goitre a systolic bruit may be heard over the goitre due to increased vascularity.

Measurement of the circumference of the neck at the most prominent part of the swelling may be taken at intervals. This will determine whether the swelling is increasing or decreasing in size.





Figs.27.21 & 27.22.— Feeling and auscultating the thyroid for thrill and bruit in a case of slightly exophthalmic goitre.

GENERAL EXAMINATION

In general examination one should look for (i) primary toxic manifestations in case of goitres affecting

the young, (ii) secondary toxic manifestations in nodular goitre and (iii) metastasis in case of malignant thyroid diseases.

(i) Primary toxic manifestations.— One should look for five cardinal signs:—

1. *Eye signs.*— There are four important changes that may occur in the eyes in thyrotoxicosis. Each one may be unilateral or bilateral —

(i) ***Lid retraction.***— This sign is caused by over-activity of the involuntary (smooth muscle) part of the levator palpebrae superioris muscle. When the upper eye lid is higher than normal and the lower eyelid is in its normal position this condition is called lid retraction. *'Lid lag'* is a different term. This means the upper eyelid cannot keep pace with the eyeball when it looks down following an examiner's finger moving downwards from above. Both lid retraction and lid lag are not exophthalmos.



Fig.27.23.— Shows how to feel for the pulse of a thyroid patient. In primary toxic goitre the pulse rate will be fast. Secondary toxic goitre also manifests through it. Pulse may be irregular in the latter case. See the text.

(ii) ***Exophthalmos.***— When eyeball is pushed forwards due to increase in fat or oedema or cellular infiltration in the retro-orbital space the eyelids are retracted and sclera becomes visible below the lower edge of the iris first followed by above the upper edge of the iris. Now the following tests or signs —

(a) *Von Graefe's sign.*— The upper eyelid lags behind the eyeball as the patient is asked to look downwards.

(b) *Joffroy's sign.*— Absence of wrinkling on the forehead when the patient looks upwards with the face inclined downwards.

(c) *Stellwag's sign.*— This is staring look and infrequent blinking of eyes with widening of palpebral fissure. This is due to toxic contraction of striated fibres of



Fig.27.24.— Progressive (malignant) exophthalmos which developed over a period of 3 months following radioiodine therapy for thyrotoxicosis. Extensive chemosis and periorbital oedema obscures the degree of exophthalmos.

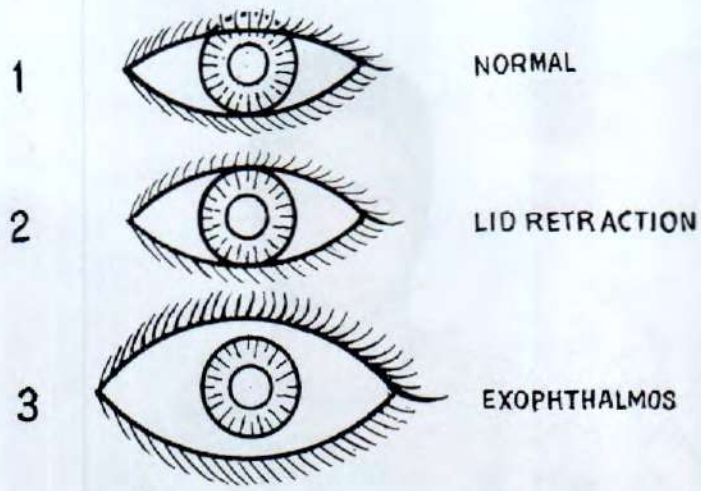

Fig.27.25.— 1.— Normal eye. 2.— Lid retraction of the upper eye lid, whereas lower lid is normal. This is *not* exophthalmos. 3.— Exophthalmos, where both lids are moved away showing sclera both below and above the iris.



Fig.27.26.— The four cardinal signs of primary toxic goitre are shown by numbers. (i) Exophthalmos; (ii) thyroid swelling with or without thrill; (iii) tachycardia and (iv) tremor.

levator palpebrae superioris.

(d) *Moebius' sign.*— This means inability or failure to converge the eyeballs.

(e) *Dalrympte's sign.*— This means the upper sclera is visible due to retraction of upper eyelid.

(iii) ***Ophthalmoplegia.***— There may be weakness of the ocular muscles due to oedema and cellular infiltration of these muscles. Most often the superior and lateral rectus and inferior oblique muscles are affected. Paralysis of these muscles prevents the patient looking upwards and outwards.

(iv) ***Chemosis.***— This is oedema of the conjunctiva. The conjunctiva becomes oedematous, thickened and crinkled. Chemosis is caused by obstruction of the venous and lymphatic drainage of the conjunctiva by the increased retro-orbital pressure.

2. ***Tachycardia*** or increased pulse rate without rise of temperature (See Fig. 27.23) is constantly present in primary toxic goitre. Sleeping pulse rate is more confirmatory in thyrotoxicosis. Regularity of the pulse may be disturbed and a rapid irregular pulse should arouse suspicion of auricular fibrillation.

3. ***Tremor*** of the hands (a fine tremor) (See Fig. 27.30) is almost always present in a primary thyrotoxic case. Ask the patient to straight out the arms in front and spread the fingers. Fine tremor will be exhibited at the fingers. The patient is also asked to put out the tongue straight (See Fig. 27.33) and to keep it in this position for at least 1/2 a minute. Fibrillary twitching will be observed. In severe cases the tongue and fingers may tremble.

4. ***Moist skin*** particularly of the hands and feet are quite common in primary thyrotoxic cases. It should be a routine practice to feel the hands just after feeling the pulse at the wrist. The palms are hot and moist and the patients cannot tolerate hot weather, on the contrary tolerance to cold is increased.

5. ***Thyroid bruit*** is also quite characteristic in Graves' disease (primary thyrotoxic goitre). This is due to increased vascularity of the gland (Fig. 27.20). But this sign is a relatively late sign and mostly heard on the lateral lobes near their superior poles.

(ii) Secondary thyrotoxicosis may complicate multinodular goitre or adenoma of the thyroid. The cardiovascular system is mainly affected. Auricular fibrillation is quite common. The heart may be enlarged. Signs of cardiac failure such as oedema of the ankles, orthopnoea, dyspnoea while walking up the stairs may be observed. *Exophthalmos* and *tremor* are *usually absent*. Patients in this group are generally elderly.

(iii) Search for metastasis.— When the thyroid swelling appears to be stony hard, irregular and fixed losing its mobility even during deglutition a careful search should be made to know about the spread of the disease. Besides examining the cervical lymph nodes, one should also look for distant metastasis such as bony metastasis which is quite common in thyroid carcinoma particularly the follicular type. The skull, the spine, the ends of the long bones, the pelvis etc. should be examined for metastasis. Lastly metastasis in the lungs, which is not uncommon, should also be excluded.

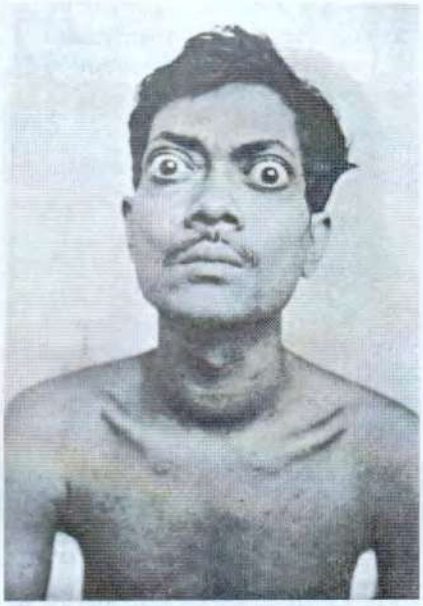

Fig.27.27.— A typical exophthalmic goitre.

SPECIAL INVESTIGATIONS

Thyroid function tests.— The most important investigation of thyroid function is meticulous clinical assessment of the patient. But clinical diagnosis has to be confirmed by investigations to know exactly the hormonal status of the thyroid and also its relation with the anterior pituitary and hypothalamus. The following tests are useful to detect the function of the thyroid gland.

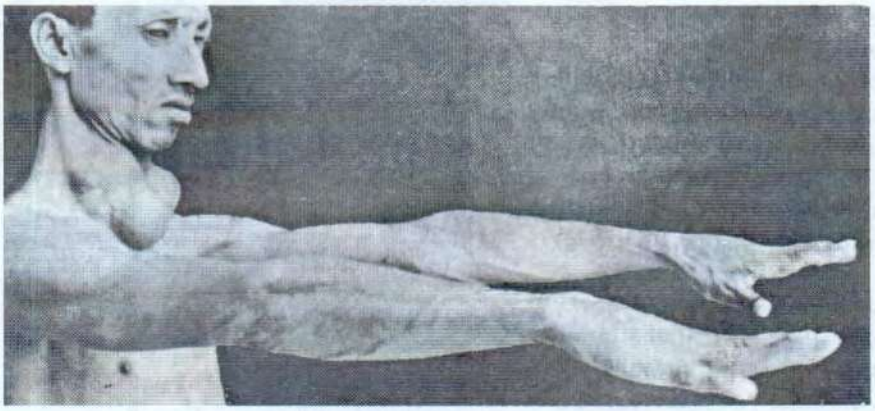



Figs.27.28 & 27.29.— Tremor is a sign of primary thyrotoxicosis. It is mainly looked for in two sites — (i) fingers of an outstretched arm and (ii) the protruded tongue.



Fig.27.30.— Shows how to look for tremor in the extended fingers. This is a manifestation of primary toxic goitre and not of the secondary toxic goitre.

A. In-vitro tests :—

(1) **SERUM PROTEIN BOUND IODINE (PBI).**— In euthyroid condition, the range is 3.5–8 µg per 100ml. It is cheap and can be easily assessed, but it lacks specificity in that it measures non-hormonal forms of iodine in the blood. False positive results are found in pregnancy, persons taking iodides in various forms particularly the contrast media, expectorants containing potassium iodide and in those taking oral contraceptives. False negative results are found in persons taking salicylates, androgens, hydantion-like drugs and in nephrotic syndrome.

(2) **SERUM THYROXIN (T^4).**— Thyroxin is transported in the plasma mainly in the bound form with the thyroxin binding globulin (T.B.G.) and by thyroxin binding prealbumin. Only a small amount circulates in the blood in the free form. Measurement is more difficult and can be measured only by competitive protein binding or radio-immunoassay method. The normal range varies from 3.0–7.5 µg per 100 ml.

(3) **TOTAL SERUM TRI-IODOTHYRONINE (T^3).**— The estimation is very difficult and is only possible by radio-immunoassay method. This test is more effective in the sense that some cases of hyperthyroidism are due to excessive production of T^3 without any accompanying rise in the level of serum T^4.

(4) **T^3 RESIN UPTAKE.**— The patient's serum is incubated with radio-active T^3 so that the latter becomes fixed to any thyroid binding protein not carrying T^3 or T^4. The amount so fixed can be measured and thus the number of binding sites in the serum which are unoccupied can be measured. Naturally in hyperthyroidism the number of free binding sites is low and in hypothyroidism this number is high. The secondary



Fig.27.31.— A huge colloid goitre is being tested for tremors. It must be remembered that toxicity if supervenes on such a goitre, it will be secondary thyrotoxicosis. Manifestations of secondary thyrotoxicosis are mainly on the cardiovascular system and not on the nervous system. So tremors are usually not seen in these cases.

binder, where the unutilized radio-active T^3 become fixed, was a resin previously and later on Thyopac or Sephadex was used. The fraction of lebelled T^3 taken up by the resin can be compared with that of a standard serum and this test goes by the name of "resin uptake ratio". The normal range being .91–1.21 µg. While using the Thyopac method one may take 100 percent as the mean normal value for free binding sites. In this case 85 percent or less will suggest hyperthyroidism as in this case the number of free sites will be less and a figure of 120 percent or more will suggest hypothyroidism as the number of free sites is high in this case.

(5) FREE THYROXIN INDEX (F.T.I.).— This is calculated from the formula that F.T.I. is equal to serum T^4 (or PBI) × T^3 uptake percent. The normal range is from 3.5 to 8. It correlates closely with the level of free T^4 in serum and thus accurately reflects the thyroid status of an individual. This can be considered as the best single test available at present.

(6) SERUM THYROID STIMULATING HORMONE (TSH).— The serum concentration of TSH is measured by immunoassay. The normal level is about 1 µu/ml. It is raised in primary hypothyroidism and almost undetectable in hyperthyroidism. This test is more of help in the diagnosis of hypothyroidism rather than hyperthyroidism. It is also of value to measure TSH level following radioiodine therapy and subtotal thyroidectomy.

(7) TEST OF HYPOTHALAMIC-PITUITARY AXIS.— When thyrotrophin-releasing hormone (TRH) is given I.V. in a dose of 200 µg to a normal individual, the level of TSH in the serum rises from a basal level of about 1 µu/ml to a mean pick concentration of about 10 µu/ml at 20 minutes and returned to normal by 120 minutes. In hypothyroidism there is an exaggerated rise of an already elevated TSH level but in hyperthyroidism there is no response of a depressed TSH level. Its importance remains to certain extent in the diagnosis of T^3 thyrotoxicosis if it is not possible to measure the circulating level of T^3. Many drugs interfere with the result e.g. T^4, antithyroid drugs, corticosteroids, oestrogens and levodopa. These modify the TSH response to TRH. Probably its main indications remain in cases of mild hyperthyroidism when diagnosis is in doubt, in hypopituitarism and in ophthalmic Graves' disease.

B. **In-Vivo tests :—**

These tests hardly help in the diagnosis of hypothyroidism. These are mainly used in the diagnosis of thyrotoxicosis and in the assessment of functional activity of thyroid nodules by scanning. The radioisotopes are mainly used and ^{99}mTc (Technetium) is gradually replacing iodine isotopes because of the low energy and short half-life of the former. The radiation dose to the thyroid is about 1/10000 time that of ^{132}I. Moreover Technetium is concentrated in the thyroid gland in the same way as iodine but is not bound to tyrosine. Therefore it gives a more accurate measure of the iodine trap.

(1) UPTAKE TESTS.— The rate at which the thyroid gland traps iodine reflects the rate of secretion of the thyroid hormone. In hyperthyroidism both the proportion of the tracer dose taken up and the rate at which this takes place are increased. The best time to measure the isotope uptake is between 10–120 minutes after administration. At this stage there is no additional discharge of radioactivity from the gland. The tracer dose of ^{131}I is 5 microcuries. The uptake is first measured and then the radioisotope passes back into the serum being incorporated into the T^3 and T^4 molecules and can be measured as protein bound ^{131}I. ^{132}I may also be used as a diagnostic tracer but only for thyrotoxicosis as it has a short life (2.3 hours as opposed to 8 days of ^{131}I). One point must be remembered that in case of hyperplastic non-toxic goitre of iodine deficiency will show an increase uptake and lead to an erroneous diagnosis of toxic goitre. This test cannot be performed immediately after contrast medium X-rays such as I.V. pyelography,

cholecystogram etc. The contrast medium is excreted in about 2 weeks time after I.V. pyelography and more than a month after cholecystogram and even years after bronchography and myelography.

This test should not be performed in children or during pregnancy because of whole body radiation. But isotopes with shorter half-life e.g. ^{132}I or ^{99}mTc may be used.

(2) **T^3 SUPPRESSION TEST (WERNER).**— This test differentiates thyrotoxicosis from other causes of raised uptakes e.g. iodine deficiency and the autonomous thyroid nodules. This test is dangerous in elderly patients and those with heart failure as there always remains a potential risk of inducing transient hyperthyroidism.

The initial uptake is measured. 40 μg of tri-iodothyronin is given 8 hourly by mouth for 5 days, after which the uptake is repeated. T^3 is used because of its more rapid effect and its shorter half-life. Considerable suppression in thyroid uptake is noted in the range of 50 to 80 per cent by this amount of exogenous hormone. Slight suppression in the range of 10–20 percent is noted in thyrotoxicosis. The TRH test gives similar information and has replaced the T^3 suppression test in centres where a radioimmunoassay of serum TSH is available. In patients who are on antithyroid drug treatment for thyrotoxicosis, this test may be used as an indicator of remission of the disease. A return to normal suppressibility in treated patients usually indicates remission.

(3) **THYROID SCAN.**— Scanning with a tracer dose will show which part of the gland is functioning or which part is not functioning (hot or cold). Both ^{131}I and ^{99}mTc can be used. ^{131}I scan can be obtained at 24 hours whereas ^{99}mTc scan is obtained at about 1/2 hour. It is not useful to scan all enlarged glands, but it is helpful to scan the thyroid when (i) a solitary nodule is palpated, (ii) in case of suspected retrosternal goitre or (iii) ectopic thyroid tissue. *A single non-functioning thyroid nodule is an indication for surgery.* Only histological examination can reveal whether it is a carcinoma or one of other causes of nonfunctioning nodules such as a cyst, colloid-filled adenoma or a focal area of autoimmune thyroiditis. If a nodule is autonomous most of the isotopes will accumulate in the nodule and the rest of the gland will show little activity. But if the nodules are functioning but not autonomous, both the nodules and the rest of the gland will take up the isotopes.

Metastasis can be demonstrated by scanning the whole body of the patient but there should be no functional thyroid tissue as the thyroid cancer cannot compete with the normal thyroid tissue in the uptake of iodine.

C. **Miscellaneous tests.**— These comprise the **BMR**, serum cholesterol, serum creatine, measurement of tendon reflexes, ECG etc. Of these **BMR** and measurement of tendon reflexes may help in the diagnosis of hypothyroidism. Other tests are of little value.

Radiography.— This is helpful to diagnose the position of the trachea — whether displaced or narrowed. Straight X-ray is also helpful in diagnosing retrosternal goitre. In case of malignant thyroid, the bones (especially the skull) if suspected to be secondarily involved should be X-rayed for evidence of metastasis.

X-ray after barium swallow may indicate whether there is any pressure effect on the oesophagus or not.

Selective angiography can also differentiate between a functioning and non-functioning thyroid nodule. Moreover it may indicate presence of retrosternal goitre.

Bone scan may be done to exclude early bony metastasis.

Fine Needle Aspiration Cytology (FNAC).— This is an excellent, simple and quick test for thyroid cysts which can be performed as outpatient method. Thyroid conditions which may be diagnosed by this technique are — thyroiditis, colloid nodule (quite common), benign tumours

like follicular adenoma, follicular carcinoma, papillary carcinoma, anaplastic carcinoma, medullary carcinoma and lymphoma.

Ultrasound.— It has a value to differentiate between solid and cystic swellings. It also demonstrates impalpable nodules. But its value to diagnose malignancy is limited.

CT and **MRI.**— These newer methods have not yet proved themselves very helpful in detecting day-to-day thyroid disorders. These are still in the experimental stage.

DIFFERENTIAL DIAGNOSIS OF THYROID SWELLINGS

A thyroid swelling is recognized by its position, its shape and by the fact that it moves upwards during deglutition.

The term "goitre" denotes here any enlargement of thyroid gland irrespective of its pathology. It is best classified as :—

(a) Non-toxic goitre (simple goitre).— 1. Diffuse parenchymatous; 2. Colloid; 3. Multinodular; 4. Solitary nodular.

(b) Toxic goitre.— 1. Diffuse (Graves' Disease); 2. Multinodular; 3. Toxic nodule (solitary nodular).

(c) Neoplastic.— 1. Benign; 2. Malignant.

(d) Thyroiditis.— 1. Acute bacterial; 2. Granulomatous; 3. Autoimmune; 4. Riedel's; 5. Chronic bacterial from tuberculosis or syphilis.

(e) Other rare types — Amyloid goitre etc.

Diffuse parenchymatous (hyperplastic) goitre.— It occurs especially in endemic area affecting the children and adolescents between the ages of 5 and 20. There is uniform enlargement of the thyroid gland and it feels comparatively soft. This is due to increased TSH stimulation in response to low level of circulating thyroid hormones. (i) Iodine deficiency, (ii) goitrogenic substances like turnips, brassica family of vegetables (e.g. cabbage, kale, rape etc.), soyabin, antithyroid drugs, para-amino salicylates etc. and (iii) genetic factors with deficiency of some enzymes of thyroid concerned with production of hormones, are the factors responsible for the development of this type of goitre. At the time of puberty when the metabolic demands are high and in pregnancy when there is too much stress, this goitre may develop *physiologically*. This goitre usually subsides by itself (natural involution) or with iodine therapy. But it may lead to colloid goitre when TSH stimulation ceases and the follicles become inactive and filled with colloid. Fluctuating TSH levels may lead to areas of active and inactive lobules (nodular goitre).

Colloid goitre.— The patients usually present between the ages of 20 and 30 years i.e. after physiological hyperplasia should have subsided. The whole gland becomes enlarged, soft and elastic. There is no other trouble. Pressure effects e.g. dyspnoea, venous engorgement and discomfort during swallowing are rare unless the swelling is enormous.

Nodular goitre.— There may be a single nodule — *solitary nodular goitre* (syn. adenoma) or a number of nodules — *multinodular goitre* (syn. adenoparenchymatous).

MULTINODULAR GOITRE.— Cut surface of multinodular goitre reveals nodules with haemorrhagic and necrotic areas separated by normal tissue which contains normal active follicles. In endemic areas this goitre appears early between 20 and 30 years, whereas in sporadic areas it appears late between 30 and 40 years. This goitre is found six times commoner in females than males. It presents as slowly enlarging painless lump in the neck. Sudden enlargement with pain is complained of when there is haemorrhage into the inactive nodules.



Fig.27.32.— A huge colloid goitre.

Pressure symptoms e.g. dyspnoea, engorged neck veins, discomfort during swallowing, stridor etc. are complained of when the swelling becomes quite large. Secondary thyrotoxicosis occurs in approximately 25 percent of cases. In long standing multinodular goitres most of the nodules gradually become inactive and myxoedema may ensue by the time she reaches 60 or 70 years of age. *On examination* the gland assumes asymmetrical shape and its surface becomes smooth and nodular. Consistency of the nodules vary from soft to hard (nodules which are tense with haemorrhage).

SOLITARY NODULAR GOITRE.— It must be remembered that approximately half of the patients who present with solitary nodules actually have multinodular goitres. A solitary nodule may be present anywhere in the thyroid gland, though its common site being the junction of the isthmus and one lateral lobe. In general, in case of nodular goitres the patient seeks medical advice for disfigurement, dyspnoea (from pressure on the trachea) or toxic symptoms (see secondary toxic goitre).

Complications such as haemorrhage, calcification, secondary thyrotoxicosis and carcinoma may develop especially in the nodular type. Sudden haemorrhage into the goitre may cause dyspnoea, demanding immediate tracheostomy.



Fig.27.33.— Shows how to examine for tremor in a protruded tongue, which is a manifestation of primary toxic goitre (and not of secondary toxic goitre). See the text.

Primary Toxic Goitre (Graves' disease or Exophthalmic Goitre).— Primary toxic goitres are said to be due to increased LATS (Long Acting Thyroid Stimulating) in the form of IgG (a form of gamma-globulin) in the serum. This humoral agent is supposed to be derived from lymphocytes. This occurs in a previously healthy gland (cf. secondary toxic goitre). Commonly seen in young women. A history of overwork, worry and severe mental strain is often obtained. The disease is characterized by five features : (1) exophthalmos; (2) some enlargement of the thyroid gland; (3) loss of weight inspite of good appetite; (4) tachycardia and (5) tremor. In addition to these, there may be thirst and disturbed menstrual function. The basal metabolic rate is increased to even 100 per cent. Thyroid gland is enlarged, firm or soft, a bruit may be present mostly near the upper pole.

Secondary Toxic Goitre.— Toxicity is superimposed on a previously diseased gland more commonly a nodular goitre. It must be remembered that the brunt of attack falls on the cardiovascular system. There may be no exophthalmos, no tremor and no tachycardia but the

pulse becomes irregular in rate and rhythm. The patient complains of precordial pain and exhaustion, later on auricular fibrillation and heart failure may set in.

Retrosternal goitre.— It may be *substernal*, wholly *intrathoracic* or *plunging* i.e. intrathoracic but is forced into the neck while coughing. The patient becomes dyspnoeic on lying on one side only — right or left. The most diagnostic feature is the presence of engorged veins over the upper part of the chest. X-ray pictures will show soft tissue shadow in the superior mediastinum or calcification. Compression or deviation of trachea may be seen. I^{131} scan can locate the gland. Arteriography also helps in the diagnosis.

TUMOURS.— Benign tumours are rare and can be either papillary adenoma or follicular adenoma. They present as solitary nodules.

Malignant tumours may be primary or secondary. Primary malignant tumours can be either 1. Carcinoma or 2. Medullary carcinoma or 3. Malignant lymphoma. Carcinoma is again classified as follows :

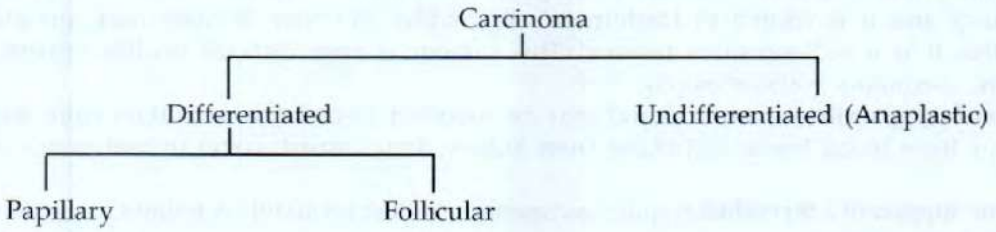

Carcinoma.— There are three types : (i) *Papilliferous* (in the young), (ii) *Follicular* (in the middle-aged) and (iii) *Anaplastic* (in the elderly). It is more common in goitrous districts. The diagnosis is suggested by the hard feel and indistinct outline of the thyroid swelling. It gradually infiltrates into the neighbouring structures such as the trachea, oesophagus, recurrent laryngeal nerve, infrahyoid muscles etc., causing dyspnoea, dysphagia and hoarseness of voice. The carotid sheath may be surrounded by the growth so that its pulsation cannot be felt at the back of the swelling. Metastasis in bone may be the first symptom with pathological fracture or pulsating bone tumour.

Papillary carcinoma.— Females are affected 3 to 4 times more than males. Common presenting symptom is relatively slow growing painless lump in the neck for more than a year. The lump is hard and not tender. This spreads by lymphatic channel in the early phase, so enlargement of regional lymph nodes is early. Multiple foci may be seen in the same thyroid due to lymphatic spread. These carcinomas are TSH dependent, so responds to thyroxin very well.

Follicular carcinoma.— Females are more often affected. Presenting symptoms are similar to those of papillary carcinoma, but the age of the patient is more and there may be pain in the bones due to metastasis. These often metastasize through blood to bones or lungs in the first instance. 50% remains non-invasive. These respond to radio-iodine more than the former.

Anaplastic.— Females are again more often affected. There may be aching pain alongwith the lump. The lump is slightly tender, hard, irregular and the margins are diffused due to infiltration. Dyspnoea, pain in the ear, hoarseness of voice are the complaints due to infiltration of surrounding structures. Thyroid may not move up during deglutition due to fixity to the surrounding structures. Though lymph nodes are almost always enlarged and hard, yet such enlargement may be obscured by the primary mass. General malaise and weight loss are common

features. *Duration of symptoms is much less* (months) than the preceding varieties of carcinoma. These metastasize through lymphatics, blood stream and local infiltration. These are extremely lethal.

Medullary carcinoma.— These tumours derive from the parafollicular (C) cells, which are derivatives of ultimobranchial body (5th arch). Patients are between 50–70 years. When these affect the younger group, a familial incidence is often found. The common presentation is firm, smooth and distinct lump in the neck, indistinguishable from any other form of thyroid solitary nodule. *Diarrhoea* is an important symptom which is complained of by at least 1/3 of the patients. These patients may also have phaeochromocytoma, parathyroid tumour, neuromas of the skin or mucous membrane etc. Lymph node metastasis is found in half the patients and blood borne metastasis is not very rare. High serum calcitonin is seen which is secreted by the tumour cells. Patients often complain of diarrhoea due to high 5HT or prostaglandin.

Malignant lymphoma.— This presents as a rapidly enlarging firm, painless mass in older woman. Symptoms caused by compression of the trachea and oesophagus are common. So clinical presentation is almost similar to anaplastic carcinoma. It represents only 5% of thyroid malignancy and it is related to Hashimoto's thyroiditis and may develop from pre-existing thyroiditis. It is a radiosensitive tumour. This tumour is very difficult to differentiate from anaplastic carcinoma without biopsy.

Secondary growths — are rare and may be involved from local infiltration from adjacent organs or from blood borne metastasis from kidney, lung, breast, colon or melanoma of any site.

Acute suppurative thyroiditis is quite uncommon. Almost invariably it follows an acute upper respiratory tract infection.

Autoimmune thyroiditis (Hashimoto's disease).— This is the most common form of chronic thyroiditis. Four autoantigens have been detected — thyroglobulin, thyroid cell microsomes, nuclear component and non-thyroglobulin colloid. Of these antimicrosomal and antithyroglobulin antibodies can be measured in the patient's serum. There is some evidence of genetic predisposition. The thyroid is symmetrically enlarged, soft, rubbery and firm in consistency in 80% of cases. The enlargement may be asymmetric, lobulated and even nodular in rest of the cases. Though the disease is focal in the beginning yet it extends to involve one or both lobes and the isthmus. Majority of patients are women of an average age of 50 years. The most frequent complaints are enlargement of the neck with slight pain and tenderness in that region. Coughing is a common symptom. Shortness of breath, increasing fatigue and increase in weight are more related to hypothyroid state. There may be transient hyperthyroidism, but hypothyroidism is inevitable. There may be pressure symptoms on the oesophagus and trachea. Increased incidence of other autoimmune diseases e.g. rheumatoid arthritis, disseminated lupus, haemolytic anaemia, purpura, myasthenia gravis and pernicious anaemia may be found in these patients or in their families. There may be associated other endocrine organ failure syndrome e.g. Addison's disease, diabetes mellitus and ovarian or testicular insufficiency. In special investigation one may find low T4, T3 and FTI values. Diagnosis is confirmed by demonstrating high titres of thyroid antibodies in the serum. Biopsy may be indicated in case of asymmetric and nodular goitres to rule out carcinoma.

Granulomatous (Subacute or De Quervain's) thyroiditis.— Aetiology is controversial yet viral origin has been advocated and it is not an autoimmune disease. Majority of the patients are females around 40 years of age. Firm and irregular enlargement of the thyroid with adhesion to surrounding tissues is quite common. But these adhesions are separable. Fever, malaise and pain in the neck often accompany. In 10% of cases the onset is acute, the goitre is painful and

tender and there may be symptoms of hyperthyroidism. White blood cells count is usually normal but ESR is almost always raised and ^{131}I uptake is usually low. Needle biopsy is quite helpful in diagnosis as enlargement of the follicles with infiltration by large mononuclear cells, lymphocytes, neutrophils and foreign body type of giant cells containing many nuclei can be detected easily.



Fig.27.34.— Shows thyroglossal fistula in the suprahyoid position, which is not very common.

Riedel's (Struma) thyroiditis.— It is a rare chronic inflammatory process involving one or both lobes of the thyroid even extending to the surrounding tissues. The gland is firmly attached to the trachea and surrounding tissues. When it is unilateral it is indistinguishable clinically from carcinoma. Women around 50 years are usually affected. Slight enlargement of the gland with difficulty in swallowing and hoarseness are usual symptoms. In the beginning serum P.B.I. and radio-iodine uptake are normal. But in late cases these are lowered. Some patients may have circulating thyroid autoantibodies but in lower titres than in patients with Hashimoto's disease.

Thyroglossal cyst.— Though this cyst can appear at any time of life, yet it is commonly seen in early childhood (cf. branchial cyst). The thyroglossal cyst is mainly diagnosed by its characteristic position. It being a cyst of the thyroglossal tract, it is mainly a midline structure. The commonest position is the *subhyoid* (just below the hyoid bone) and next common is the *suprahyoid* (just above the hyoid bone) position. The cyst is essentially midline in position in these two places. In case of suprahyoid position one must carefully differentiate this cyst from the sublingual dermoid cyst. Thyroglossal cyst may be seen *at the level of the thyroid cartilage*, when it is slightly shifted to the left and must be differentiated from cervical lymph node enlargement. The least common position is *at the level of the cricoid cartilage* when it may mimic an adenoma of the isthmus of the thyroid.



Fig.27.35.— Note how a thyroglossal fistula moves up when the tongue is protruded.

The cyst is usually too small or the content is too tense to exhibit definite fluctuation. That



Fig.27.36.— A typical case of thyroglossal cyst.

the swelling moves up during swallowing and *that it moves upwards when the tongue is protruded* are the two pathognomonic features of this condition. One thing must be remembered that this cyst is very much liable to be infected.

Thyroglossal fistula.— This condition is usually an acquired one either from bursting or incision of an inflamed thyroglossal cyst or from local removal of the thyroglossal cyst leaving behind the thyroglossal tract. It is also a midline fistula.

Hyperparathyroidism.— It must be remembered that parathyroid disease presents as a disturbed endocrine function and never as a swelling in the neck.

Primary hyperparathyroidism is due to increased secretion of parathyroid hormone which mobilizes calcium from bone, increases calcium uptake and causes phosphate loss from renal tubules resulting in hypercalcaemia. Such overactivity of the parathyroid usually result from an adenoma (90% of cases), or due to hyperplasia (9%) or rarely due to carcinoma (1%). Patients may present with symptoms of hypercalcaemia or the case may remain asymptomatic only to be revealed on routine serum analysis. Recurrent renal calculus is the commonest presenting feature. There are certain gastrointestinal symptoms — features of peptic ulceration due to hypercalcaemia-induced gastrin secretion. There may be acute or chronic pancreatitis. Bone manifestation is more common histologically and is not often clinically evident. Radiological appearances resembling rickets may occur in children from resorption of metaphyseal bones. Osteitis fibrosa cystica (brown tumour) arises from a process of subperiosteal bone resorption with patchy fibrous replacement. Mental disturbances with psychosis, dementia and behavioural changes are often noticed. Calcification may occur in other tissues such as cartilage resulting in pseudogout, in the cornea there may be a band — keratopathy. Other features of hypercalcaemia include myopathy and hypertension.

This condition must be differentiated from sarcoidosis, milk-alkali syndrome, disseminated malignancy and excessive vitamin-D ingestion, all of which cause hypercalcaemia.

It must be remembered that hyperparathyroidism may be a feature of *multiple endocrine neoplasia syndrome* (MEN). In MEN type I there are parathyroid tumour, islet tumours of the pancreas producing gastrin to cause Zollinger-Ellison syndrome, medullary carcinoma of the thyroid and pituitary chromaffin adenomas producing prolactin or giving rise to acromegaly.

In MEN type IIa there is parathyroid hyperplasia, together with medullary carcinoma of thyroid and phaeochromocytoma. In type IIb in addition there are features of neurological complications with the presence of neuromas of the lips and eyelids and ganglioneuromatosis together with even megacolon.

Secondary hyperparathyroidism is a reactive hyperplasia of the parathyroid glands in response to chronic calcium-losing conditions, chronic renal failure or malabsorption. There is unlikely of any clinical manifestation.

Tertiary hyperparathyroidism results from overactivity of the parathyroids associated with chronic calcium loss which may become autonomous later on. It may occur after renal transplantation.

It is rather impossible to palpate an enlarged parathyroid gland be it a case of hypertrophy or adenoma. But a systemic palpation should always be made to discover enlarged parathyroid gland. One thing must be remembered that even in presence of hyperparathyroidism if one finds a swelling at the posterior aspect of a thyroid lobe, very often it is a thyroid adenoma rather than parathyroid adenoma.

Parathyroid Tetany.— This is mainly a complication of thyroidectomy and reveals itself within first 5 days after operation. Early complaints are tingling and numbness of the lips, nose and the extremities. Later on painful cramps of the hands, feet and ultimately all the muscle of the body may occur. Strong adduction of the thumbs is a common feature of this condition and this when coupled with strong extension of the feet, constitutes the "carpopedal spasm". Lastly the muscles of respiratory system may be affected which results in severe dyspnoea. Blurring of vision due to spasm of intraocular muscles is not uncommon. The two common signs associated with this condition are :— (i) *Chvostek-Weiss sign* in which a gentle tap on the facial nerve as it emerges in front of the external auditory meatus will invite a brisk muscular twitch of the same side of the face. (ii) *Trousseau's sign* in which a sphygmomanometer cuff is placed around the arm and the pressure is raised to 200 mm Hg. Within 5 minutes typical contractions of the hand can be seen, i.e. the fingers are extended but the metacarpophalangeal joints are slightly flexed and the thumb is strongly adducted— the so called 'Obstetrician's hand'.

Chapter

28 EXAMINATION OF INJURIES OF THE CHEST

HISTORY.— A careful history must be taken about the nature of violence. In civil practice road accidents and stab wounds are the main forms of chest injuries. Crush injuries are the severe forms of chest injuries in which apart from contusion of the chest wall and rib fractures there may be stove-in-chest, flail chest, lung contusion or laceration, aortic rupture etc. The patient must always be asked whether he has coughed up any blood or not. This indicates injury to the lung.

PHYSICAL EXAMINATION

General Survey.— The patient must be stripped properly and immediate careful observation must be made althroughout the body. Chest injuries are often associated with injuries of the abdomen which are more serious and may demand immediate surgical intervention, head injury and injuries of the limb. Note whether the patient is lying quiet (shock) or is restless and gasping (internal haemorrhage). Is the patient cyanosed or dyspnoeic? In traumatic asphyxia, which may complicate compression injuries of the thorax, petechial haemorrhages due to extravasation of blood from compressed venules may be seen in the face, conjunctivae and neck.

LOCAL EXAMINATION

INSPECTION.— For proper inspection of the chest the patient should be stripped to the waist.

1. **Skin.**— Any bruise or ecchymosis should be noted. These may indicate as to the nature of injury. If there is a wound assess whether it has penetrated the pleura or not. In a penetrating injury, air and blood will pass in and out of the wound with a loud sucking noise. This may be associated with pneumohaemothorax and surgical emphysema. If the opening is quite large, the patient will be in great distress. Under such circumstances, a detailed examination should be deferred and *the wound should be immediately occluded by a pad of sterile gauze and strappings*. This avoids harmful effects of open pneumothorax and mediastinal flutter. Subsequently the patient should be taken into the operation theatre and the wound should be excised and closed.

2. **Respiration.**— Note the *character* of breathing (hyperpnoea, shallow breathing or dyspnoea) and the *type* (abdominal or thoracic). The patient is asked to take a deep breath in. In fracture of the ribs the patient experiences an excruciating pain whose site he can point out.

Note if there is any ***paradoxical respiration,*** i.e. collapse of the chest wall during inspiration and expansion during expiration. This is mainly seen in multiple rib fractures particularly when ribs are fractured at two places (at the anterior and posterior angles). This may lead to ***flail chest,*** i.e. a flaccid unstable chest wall which is sucked in by negative pressure within the

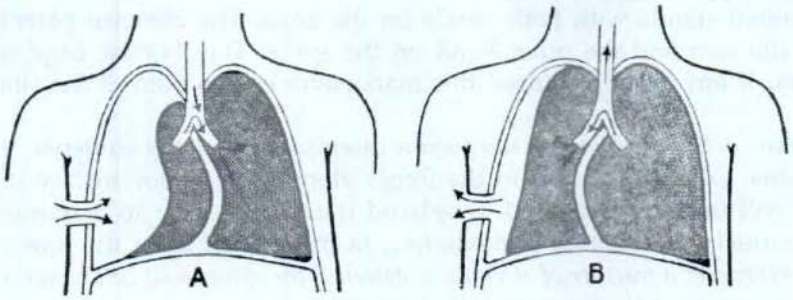

Figs.28.1 & 28.2.— Showing the mechanism of mediastinal flutter and paradoxical respiration. When the opening of the chest wall is large the lung of the affected side shrinks during inspiration as the air rushes into the pleural cavity through open wound pushing the mediastinum towards the healthy side pressing upon the unaffected lung whose aeration is also impaired. In the second figure, during expiration, the mediastinum is pushed towards the affected side with air pushing from the good lung to the affected lung. The side-to-side movement of the mediastinum is known as 'mediastinal flutter' and since the heart and the great vessels are implicated it leads to shock with rapid pulse.

During inspiration the affected lung collapses and during expiration it expands, i.e. reversal of the normal process. This is referred to as 'paradoxical respiration'. It is more evident from outside in a case of 'flail chest' when the two ends of the ribs are fractured.

resulting from chest injury may not be localized to the chest wall but may spread to the neck, face, abdomen and even to the scrotum.

4. If the patient coughs out **sputum**, the students must make a careful look at it. A blood stained sputum indicates nothing but injury to the lung or to the upper respiratory tract and mouth.

PALPATION.—

1. **Palpation of the ribs.**— When injury is severe causing multiple fractures of the ribs, a careful assessment must be made as to which ribs are affected and the sites of fractures. More difficult is the case of simple crack fracture of a single rib when the patient may not attend the doctor immediately after the injury but will report only when the pain persists even after a few days of injury. If the patient can locate the exact site of pain the clinician should run his finger along the concerned rib to find out local bony tenderness, bony irregularity and crepitus. This indicates pleural cavity during inspiration and pushed out in expiration by air coming from the good lung to the lung of the affected side.

3. **Swelling.**— This is not very frequently seen, neither very significant so far as injuries of the chest are concerned. Mostly a swelling is a haematoma. *Surgical emphysema* does not give rise to a localized swelling but may produce a diffuse swelling or a puffy appearance. The students must remember that surgical emphysema



Fig.28.3.— Compression test. The patient stands wih both hands on the head. The clinician places his one hand on the sternum and the other hand on the spine. The thoracic cage is now compressed anteroposteriorly. If any rib is fractured this manoeuvre causes pain at the site of fracture.

fracture of the rib. When the patient cannot indicate the exact site of pain the clinician must try to discover the site of fracture by *"compression test"*.

Compression test.— The patient stands with both hands on the head. The clinician places the base of one hand on the sternum and the other hand on the spine. The thoracic cage is now *compressed anteroposteriorly*. If any rib is fractured this manoeuvre causes pain at the site of fracture.

2. **Palpation of the sternum.**— Fracture of the sternum is often missed by the students. It should form a part of the routine examination to run the finger along the anterior surface of the sternum. A crack fracture will thus be diagnosed. Displaced fracture is easier to diagnose as consequent deformity will attract the attention immediately. In majority of cases the upper fragment overrides the lower. *Whenever a fracture of sternum is detected, the spine must be examined for evidence of fracture, since these two conditions coexist quite frequently.*

3. **Swelling.**— If there is a diffuse swelling, put your hand on the swelling. The typical crepitant feel of *surgical emphysema* once experienced is never forgotten. In fracture of the ribs, the surgical emphysema appears first at the site of the fracture, whereas in the *mediastinal emphysema* due to rupture of the bronchus or oesophagus the surgical emphysema starts in the neck and rapidly spreads to the face, chest and abdomen.

Usual findings of a swelling should be noted. Besides these one should feel for impulse on coughing. This is present in subcutaneous herniation of the lung.

4. **Vocal fremitus.**— Diminution of absence of the vocal fremitus is the finding in pneumothorax and haemothorax.

5. **Apex beat of the heart.**— This will be shifted to the opposite side in cases of pneumothorax and haemothorax.

PERCUSSION.— In pneumothorax the percussion note will be resonant. In haemothorax it will be dull. In right sided pneumothorax, it may obliterate the upper limit of liver dullness, whereas on the left side it may obliterate the normal cardiac dullness. In case of haemopericardium the area of cardiac dullness is increased.

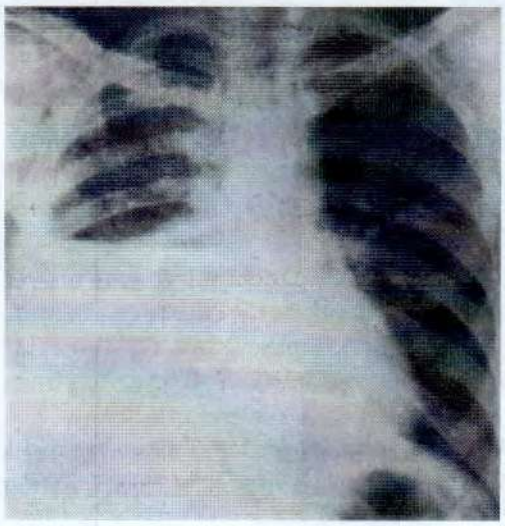

Fig.28.4.— Haemopneumothorax showing the horizontal level of blood in the right pleural cavity.

AUSCULTATION.— 1. *Crepitus* may be heard when the bell of the stethoscope is placed exactly over the site of the rib fracture. This may be confused with surgical emphysema.

2. *Lungs.*— In cases of pneumothorax and haemothorax the breath sounds and vocal resonance will be diminished or absent.

3. *Heart.*— 'Silent heart' is pathognomonic of haemopericardium.

SPECIAL INVESTIGATIONS

1. **X-ray examination.**— Importance of this investigation cannot be emphasised too hard. Fractures of the ribs with or without displacement are clearly seen. Pneumothorax and amount of air inside the pleural cavity can be diagnosed. The outer margin of the lung is also clearly delineated in X-ray. In haemothorax the horizontal level of blood in the pleural cavity is easily seen in X-ray.

Skiagraphy will also diagnose rupture of diaphragm and oesophagus as also haemopericardium. Aortography is helpful when injury to major artery is suspected.

2. **Estimation of blood gases.**— Regular estimation of arterial oxygen and carbondioxide partial pressure will give a clue to the amount of respiratory insufficiency particularly in cases of paradoxical respiration.

3. **Aspiration.**— This test is better avoided for diagnostic purpose only, as there remains a chance of empyema to develop from secondary infection. In case of haemothorax blood can be aspirated out. This can be done after several days or weeks as the blood does not tend to coagulate due to constant movement of the lungs. Pleural shock must be avoided by properly infiltrating the parietal pleura with local anaesthetic.

DIAGNOSIS

Fracture of the rib.— The main complaint of the patient is pain while taking a deep breath in. Nothing more can be elicited from inspection except presence of slight bruising. On palpation, local bony irregularity, tenderness and crepitus are the findings of fractured rib. The compression test becomes positive. The clinician should run his finger along each rib in the region of injury to reveal local bony tenderness. The students must not forget to look for signs of other concomitant injury such as lung, liver (on the right side) and spleen (on the left side). Surgical emphysema denotes injury to the lung. Skiagraphy though confirmatory yet may miss a hair-line crack fracture.

Stove-in-Chest.— This condition develops from an extensive localized crushing force which produces multiple rib fractures. This results in depression of the chest wall in that region. Relative immobility leads to accumulation of bronchopulmonary secretions. This condition, if associated with depressed fractured clavicle, becomes a serious condition.

Flail-Chest.— This condition also develops from crushing injury. Multiple ribs fracture anteriorly at the costochondral junction and posteriorly near the angle of the ribs. This results in a fragment of the chest wall which becomes unstable having no bony connections. This part moves in during inspiration and moves out during expiration resulting in paradoxical movement of the chest wall. This condition very badly affects aeration of the lung and progressive accumulation of carbondioxide. It may so happen that a number of ribs or costal cartilages on either side of sternum a little away from it may be fractured and then it becomes a flail sternum. It must be remembered that with quiet respiration paradoxical movement may not be apparent, but if the patient coughs or takes deep breathing paradoxical movement becomes obvious. Immediate surgical intervention in the form of tracheostomy and positive pressure respiration should be called for. If slight paradoxical movement still persists the ribs should be exposed and the ends joined by stainless-steel wire or nails.

Surgical emphysema.— This means air in the subcutaneous tissue. The mechanism is injury to the lung through which air is forced into the chest wall. *This may not be associated with pneumothorax*, the rent in the lung being sealed off. This should not be confused with mediastinal emphysema which is a sequel of rupture of the bronchus or oesophagus. In this condition emphysema is first noticed in the neck and it rapidly spreads to the face, chest wall, abdominal wall and even to the scrotum. The tension may rise sufficiently to cause embarrassment to the heart and great veins.

Traumatic pneumothorax.— Air in the pleural cavity is called "pneumothorax". In majority cases of trauma blood is associated with air in the pleural cavity and then it is called haemo-pneumothorax. Air may reach the pleural cavity through a small rent in the lung which may

subsequently be closed (*closed pneumothorax*). Air may enter the pleural cavity through a wound in the chest wall (*open pneumothorax*). Sometimes the leak in the lung through which air comes out becomes valvular, i.e. air enters the pleural cavity from the lung during inspiration but cannot leave the pleural cavity during expiration as the leak in the lung becomes closed. That means with each inspiration more air is drawn into the pleural cavity causing collapse of the injured lung. This condition is called *tension pneumothorax*. The mediastinum deviates to the healthy side. The onset of this emergency is suggested by increasing dyspnoea and cyanosis. The trachea with the mediastinum shifts to the opposite side. Immediate aspiration of the air through the second intercostal space anteriorly is a life-saving procedure.

Pneumothorax, as a whole, is easily recognized by varying degrees of dyspnoea, pain, shock, cyanosis etc. Hyperresonance, absence of breath sounds and shifting of the trachea and apex beat towards the opposite side are the findings of this condition.

Traumatic haemothorax.— This means accumulation of blood in the pleural cavity. This results from contusion of the lung or injury to the parietal vessels. The diagnosis is made by dullness on percussion, weak breath sounds, impaired vocal resonance etc. Haemothorax may be complicated by infection.

Contusion and laceration of the lung.— Contusion generally results in areas of consolidation and usually resolves spontaneously whereas laceration permits leakage of blood and air into the pleural cavity. Minor lacerations also heal spontaneously but severe degrees of lacerations require exploration by thoracotomy.

Injury to the lung is clearly evidenced by *haemoptysis*. In every case of thoracic injury, the patient must be questioned whether he has coughed up any blood or not. Even a small quantity of frothy blood if coughed up is an indication of injury to the lung. *Surgical emphysema* is another strong evidence of lung injury. It must be remembered that besides the common surgical emphysema which is seen on the chest wall, *injury to the lung may result in* ***mediastinal emphysema***. If the visceral pleura remains intact, air comes out through the traumatic rupture of the pulmonary tissue and accumulates to the hilum of the lung, from there to the mediastinum and neck.

Traumatic asphyxia occurs in crushing injury of the chest. Blood from the heart being driven into the veins of the head and neck and upper part of the chest causing extravasation of blood into the conjunctivae and skin of those regions.

Injury to the heart and **haemopericardium** (cardiac tamponade).— When the heart is injured by penetrating wound blood accumulates in the pericardium. This compresses the heart and the circulation fails considerably. The three classical signs are (i) "silent heart", i.e. diminution of cardiac sounds; (ii) increased area of cardiac dullness; and (iii) steady fall of arterial pressure with gradual rise of venous pressure. Immediate aspiration of the pericardium through the left costoxiphoid angle should be carried out as a life-saving measure.

Rupture of the thoracic aorta — is rare and fatal. Patients only come to the hospital when mediastinal pleura or adventitia holds the pulsating haematoma. Widening of the superior mediastinum with tracheal shifting in straight X-ray will give a clue, which will be confirmed by aortography.

Tear of the bronchus is rare and may occur in severe chest injury. A continuing massive leakage of air indicates a torn bronchus which may develop into a severe mediastinal emphysema culminating in surgical emphysema which may extend into the scrotum. Bronchoscopy will finally diagnose this condition.

Rupture oesophagus.— This condition is very rare after injury to the chest, though perforation of oesophagus does develop through inexpert use of oesophagoscope or a

gastroscope. Great pain and dyspnoea give indication towards the diagnosis. X-ray will reveal air in the mediastinum, the pleural cavity and in the neck. Radiograph may be taken after swallowing a small quantity of lipiodol to diagnose this condition. Urgent operation under antibiotic cover is the main solution to this problem.

Rupture of the thoracic duct — is also and will cause chylothorax. Aspiration of chyle during pleural-tapping will confirm the diagnosis. If the patient is asked to ingest cream containing confectioner's green, this will mark the tear on thoracotomy.

Injury to the diaphragm and diaphragmatic hernia.— Rupture of diaphragm is often associated with thoracic injury and this may lead to diaphragmatic hernia. Increasing dyspnoea after injury, which cannot be explained otherwise, straight X-ray showing abnormal gas shadow within the thorax and barium swallow examination will reveal coils of intestine inside the thoracic cavity.

Injury to the subdiaphragmatic organs.— An account of thoracic injury cannot be made complete without mentioning about injury to the abdominal organs. This is important as this injury requires more attention than injury to the chest proper. This is fatal and demands immediate surgical intervention. The liver, the spleen, the kidney, stomach, colon are the organs which may be involved in injury and is discussed in the Chapter on "Examination of abdominal injuries".

Chapter

29 EXAMINATION OF DISEASES OF THE CHEST

This chapter is mainly of physician's interest and elaborately described in the books of medicine. Here only conditions of surgical importance will be discussed.

HISTORY.— A careful history must be elicited. Whether the patient is in early postoperative period or not? How did the disease start — spontaneously, after an attack of acute lobar pneumonia (e.g. acute empyema) or following inhalation of a foreign body (e.g. lung abscess). Sudden acute pain in the chest with collapse after 7-10 days of operation may indicate pulmonary embolism. Appearance of dyspnoea, cyanosis and fall of blood pressure on second postoperative day suggests pulmonary atelectasis. Enquiry must be made about fever, pain in the chest, cough, sputum, haemoptysis etc.

Pain.— This is the commonest symptom of diseases of the chest. Pleural conditions like pleurisy, empyema, pneumothorax and haemothorax all give rise to chest pain. Lung conditions like lung abscess, bronchiectasis, infarction, embolism, atelectasis and late cases of bronchogenic carcinoma give rise to this symptom. Pain is intermittent and throbbing in lung abscess. Radiation of pain along an intercostal space is typical of intercostal neuralgia. In acute empyema pleural pain is quite significant. About half of the patients with carcinoma of lung complain of chest pain when first seen by a doctor. It is often described as 'heaviness'. Constant pain indicates poor prognosis. Shoulder pain radiating to the corresponding arm is a feature of Pancoast (apical) tumour.

Fever.— This is a common symptom of empyema, lung abscess, bronchiectasis etc. Enquire about its onset, nature, duration and timings.

Dyspnoea — is also a very common symptom of almost all pleural and pulmonary diseases. Enquire about its onset, type, whether continuous or only on exertion.

Cough — with or without sputum (dry) is a characteristic symptom of a few diseases of lung. It is quite common in lung abscess and bronchiectasis. In bronchiectasis the cough is chronic and productive with purulent expectoration, whereas in lung abscess cough is productive with foul-smelling sputum. In carcinoma of lung this is the commonest manifestation and it may or may not be productive. This is a rare complaint of pleural diseases.

Haemoptysis.— This is a very significant symptom of a few lung disorders. Whereas tuberculosis is the commonest cause of haemoptysis in India, yet a few surgical conditions also manifest with this symptom. It is seen in bronchiectasis. It is an alarming symptom of lung carcinoma and occurs in approximately 1/3 of cases. Occasionally haemoptysis may be massive in this condition constituting surgical emergency.

Loss of weight.— It is complained of in lung abscess, but it is significantly present in carcinoma of lung. In tuberculosis also it is seen but basically it is a medical disease and very occasionally it may need surgery.

Sinus formation.— Patients may present with this. Sinus formation may occur from empyema

necessitatis. It is also a characteristic feature of actinomycosis of lung in which the patient presents with multiple sinuses in the chest wall with induration and bluish skin around.

Past history.— This is important particularly in tuberculosis, empyema and spontaneous pneumothorax. In a case of swelling of the chest wall or in a case who presents with haemoptysis and fever past history of tuberculosis suggests the possibility of cold abscess of flaring up of the old infection. Past history of pneumonia suggests the post-pneumonic empyema which is the commonest cause of empyema. A recent past history of persistent cough treated by medicine and now the patient presents with cough, dyspnoea, haemoptysis and weight loss should arouse suspicion of carcinoma of lung.

Personal history.— Excessive smoking for quite sometime is still considered to be the commonest aetiological factor of carcinoma of lung.

PHYSICAL EXAMINATION

General Appearance.— Presence of cyanosis, anaemia, clubbing should be noted. Whether the patient is dyspnoeic or not? Emaciation is a feature very often seen in malignant diseases. Patient must be asked whether he is losing weight very fast or not.

LOCAL EXAMINATION

INSPECTION.—

1. **Contour of the chest.**— Look at the chest as a whole, whether there is any abnormal prominence or retraction. If present, ask whether it was present previously or appeared after the beginning of the present illness. If there is undue prominence of ribs anteriorly on one side, exclude scoliosis before considering an intrathoracic disease.

Funnel chest (Pectus excavatum).— There is posterior concavity of the body of the sternum from above downwards deepest above its junction with the xiphoid. The lower costal cartilages dip posteriorly to meet the depressed sternum. So there is concavity from above downwards, antero-posteriorly and side-to-side of the chest giving rise to the appearance of a funnel. It predisposes repeated respiratory infection and cardiovascular disturbances.

Pigeon chest (chicken breast or pectus carinatum).— This is also a congenital deformity with occasional association with congenital heart disease. It is also a sequel to chronic respiratory disease in childhood. In this the sternum appears prominently bowed forward alongwith the costal cartilages, often accompanied by indrawing of the ribs to form symmetrical horizontal grooves (Harrison's sulci).

Barrel shaped chest.— It commonly occurs in obstructive emphysema of the lungs. Antero-posterior diameter of chest is greater than the transverse diameter. There is prominent sternal angle and wide subcostal angle.

Flat chest.— Here the transverse diameter is more than the anteroposterior diameter.

Thoracic kyphoscoliosis.— This may have profound effects on pulmonary function, as the chest deformity reduces the ventilatory capacity of the lungs.

Rachitic chest.— This occurs in rickets. There are bead-like prominences at costochondral junction known as 'Rickety rosary'.

2. **Respiratory movements.**— Note the rate, character and type of breathing. It is always advisable to compare both the sides. Sluggish movement on one side of the chest may be due to pleural effusion, consolidation, collapse etc.

3. **Apex beat of the Heart.**— It is better palpated than inspected. Collection of effusion,

blood or air in one pleural cavity will push the apex beat to the opposite side, whereas in massive collapse the apex beat will be shifted to the same side.

4. Any **swelling** or a **sinus** must be carefully looked at and examined. They are always very significant in surgical conditions. The methods of examination have been discussed thoroughly in Chapters 3 and 5 respectively.

5. **Neck veins** may be engorged due to congestive cardiac failure or secondary to long-standing lung disorders.

PALPATION.—

1. **Respiratory movements.**— The clinician places his hands on the chest — each hand on each side of the chest. They are so placed that the tips of the two thumbs come in contact with each other in the centre. The patient is now asked to take a deep breath in and out. See how each thumb moves away from the midline with each inspiration. Deficient movement or immobility of one thumb indicates pleural effusion, consolidation, collapse etc. of that side.

2. **Apex beat of the Heart.**— Place the palm of the hand on the apex beat of the heart. One can easily assess whether it is shifted medially or laterally.

3. **Position of trachea** should be examined to know if this is shifted to one side or the other.

4. Feel for **vocal fremitus.**— It is much diminished in pleural effusion or pneumothorax, whereas it is increased in consolidation of the lung.

5. **Swelling.**— Test for its consistency, mobility, compressibility, reducibility, fluctuation, impulse on coughing etc. Bony hard swelling arising from a rib is a *tumour*. Soft, fluctuating swelling mainly on the anterior axillary line or parasternal line is a *cold abscess*. Presence of impulse on coughing means empyema necessitatis (See Fig. 29.2). Reduction is often complete in *empyema necessitatis*. A cold abscess arising from caries of the rib is compressible. Ascertain the mobility of the swelling over the chest wall and note whether the swelling is free or fixed to the chest wall. Fixed swellings are those arising from the ribs or may grow from within the thorax e.g. parietal carcinoma of the lungs, endothelioma of the pleura etc. If the swelling is pulsatile, note whether it is an expansile or transmitted pulsation. An expansile pulsating swelling is probably an *aneurysm*.

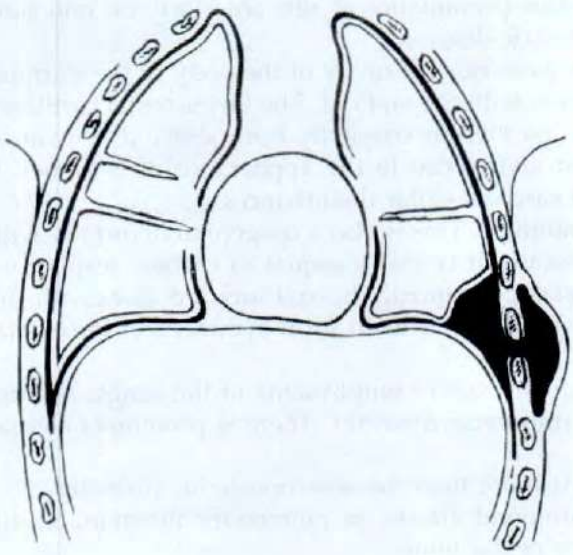

Fig.29.1.— Diagram of empyema necessitatis showing encapsulated pleural empyema, a narrow opening between the ribs through which the empyema has burrowed externally presenting a collection of pus in the subcutaneous tissues giving rise to a fluctuating swelling.

6. **Sinus.**— Single sinus is mostly due to bursting of a long-standing *cold abscess*. Palpate the neighbouring ribs for tenderness, irregularity, thickening etc. to denote the origin of this condition. Multiple sinuses with marked induration may be due to *actinomycosis of the lung*. If they extrude sulphur granules diagnosis is confirmed.

PERCUSSION.— A dull note over a normally resonant area indicates thickened pleura, pleural effusion, consolidation of the lung or a tumour. Increased resonance suggests pneumothorax or emphysema of the lung. Define the area of cardiac dullness. In pleural effusion the heart may be displaced to the other side.

AUSCULTATION.— Character of the breath sounds should be noted. *Diminished* breath sounds will be heard in pleural effusion, pneumothorax, haemothorax etc. whereas *increased* breath sound will be heard in consolidation. Note the nature of vocal resonance.

EXAMINATION OF LYMPH NODES.— The axillary group or the supraclavicular group may be involved in carcinoma of the lung. This denotes grave prognosis.

GENERAL EXAMINATION.— When a cold abscess is present on the chest wall examine the spine for Pott's disease.

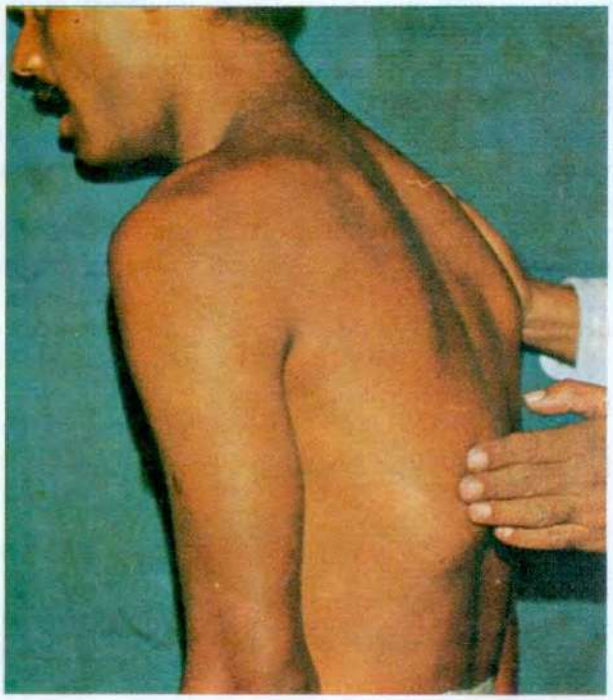

Fig.29.2.— Lipoma affecting lower part of the left chest which clinically simulates empyema necessitatis. It is being excluded by looking for impulse on coughing which is positive in case of the latter but not in case of a lipoma.

SPECIAL INVESTIGATIONS

1. **Aspiration.**— Note the character of the fluid after aspiration. This often gives a clue to the diagnosis. Presence of blood in unknown cases of pleural effusion indicates malignant disease. In empyema note whether the fluid is turbid or thick pus. It should be sent for culture and sensitivity tests.

2. **X-ray examination.**— (a) A straight film is of great value in detecting a bony lesion, pleural effusion, air or blood in the pleural cavity, aneurysm, bronchial carcinoma, mediastinal tumour etc. In case of bronchial carcinoma it may show a hilar or peripheral shadow and features of obstructive emphysema, atelectasis or consolidation as secondary changes. (b) In chronic empyema with a sinus, *injection of lipiodol followed by skiagraphy* will show the position and extent of the empyema cavity. In bronchopleural fistula, if a few crystals of Sudan III are added to the injected lipiodol, the sputum is coloured pink. (c) *Bronchography* is done by injecting a radio-opaque substance e.g. Neohydriol into the bronchial tree through the trachea. The 'rat-tail' deformity of the main bronchus is pathognomonic of carcinoma of the bronchus. Diagnosis of bronchiectasis can also be made with certainty by this method. (d) *Tomography* is very helpful in studying a cavity inside a dense shadow which is not clearly visualized in an ordinary film. Skiagram is taken while the tube is moving in one direction and the film in the opposite direction, so that all the objects above and below the cavity throw blurred shadows but the cavity stands out clearly. This will also help in demonstrating enlarged mediastinal nodes and lung cancer. (e) *Skiagraphy after barium swallow* may show deviation of the oesophagus in the case of mediastinal deposits.

3. **Bronchoscopy.**— This is an important investigation so far as bronchogenic carcinoma is concerned. This examination will reveal the lesion which is centrally placed. It also helps to take a biopsy from the tumour under vision. Bronchoscopy gives useful information regarding operability of the tumour. Widening of the carina, involvement of the main bronchus within 1.5 cm. from the carina, compression of the trachea and paralysis of the vocal cord are the features of non-operability. This examination, of course, fails to reveal any lesion in the segmental division of the upper bronchus and the peripheral lesions. Cytology study can be performed by bronchial washing and brushing through bronchoscopy. Even biopsy specimen may be taken through bronchoscopy.

4. **Laryngoscopy.**— A left-sided paralysis suggests a tumour under the arch of the aorta whereas a right-sided paralysis indicates an apical tumour spreading below the subclavian artery.

5. **Mediastinoscopy.**— Through a small incision just above the sternum the instrument is introduced to know involvement of the mediastinal structures particularly the lymph nodes.

6. **Cytological examination.**— In carcinoma of the lung, the sputum or the aspirated material from the pleura can be examined histologically for malignant cells by Papanicolaou's technique.

7. **Scalene node biopsy** — is done as a routine in certain centres. Involvement excludes the possibility of radical operation.

8. **C.T. Scan** is extremely helpful in detection of pulmonary metastasis. It can detect small pulmonary nodules, identifies enlarged mediastinal nodes. It is used to stage carcinoma of lung.

9. **Screening of diaphragm** will give a clue whether the phrenic nerve has been involved or not.

10. **Liver, brain** and **bone scanning** should be done if these organs are suspected to be involved.

11. **Lung function test** is very important and always done before operation.

12. **Exploratory thoracotomy** should be performed if an early diagnosis and radical extirpation are desired.

DIFFERENTIAL DIAGNOSIS

SOLID SWELLINGS OF THE THORACIC WALL.— These are the usual *tumours of the skin, subcutaneous tissue and bone.* Tumours of the rib and nerve deserve special mention. Other group of swelling is *costochondritis* be it tubercular or non-specific.

Rib tumours may be primary or secondary. Primary rib tumour may be a chondroma, osteoma, osteoclastoma, chondrosarcoma, osteosarcoma etc. Secondary carcinoma of rib may be seen in cancer of the breast, bronchus, suprarenal, prostate, kidney etc. In case of benign tumours swelling and deformity are the main symptoms. In case of malignant tumours pain and tenderness are often come across, which become more obvious in case of secondary growths.

Two types of *tumours of the nerve* may be seen in the thorax. Neurofibroma arising from the intercostal nerves and ganglioneuroma from the sympathetic chain. The former appears close to the neck of the rib while the latter lies more medially close to the vertebral bodies. These tumours are detected by straight X-ray as they tend to erode the adjacent ribs and the vertebrae. Some may extend through the intervertebral foramina into the neural canal. Here they may press upon the spinal cord to cause paraplegia.

Costochondritis is nothing but a swelling at the junction of a rib and the costal cartilage. Pain is quite prominent which attracts attention towards the swelling. This swelling must not be confused with the breast swelling as the whole of the breast can be moved over the swelling.

CYSTIC SWELLINGS OF THE THORACIC WALL.— By far the most important in this group is the cold abscess. Empyema necessitatis and hernia of the lung are rare entities.

Cold abscess mainly originates from the tuberculous lymphadenitis of the posterior mediastinal group of lymph nodes in front of the necks of the ribs or the internal mammary group or from the Pott's disease affecting the vertebrae. Only rarely perinephric abscess may burrow superficially to give rise to an abscess in the posterior aspect. Cold abscess in the chest wall is usually seen along the anterior axillary line and the parasternal line. This is because of the fact that the abscess follows the lateral and the anterior cutaneous branches of the intercostal nerves to become superficial.

Empyema necessitatis means pus of the empyema burrows to the chest wall and becomes superficial either in the lateral or anterior aspect (See Fig. 29.1). This is mostly seen between 3rd and 6th intercostal spaces. This condition is diagnosed by presence of impulse on coughing and reducibility.

Hernia of the lung is very rare and seen usually at the root of the neck behind the clavicle. It is a tympanitic cystic swelling which can be reduced completely.

SINUS OF THE CHEST WALL.— Three types of sinuses may be seen — (i) chronic empyema sinus; (ii) sinus following cold abscess and (iii) actinomycotic sinus. The last named sinus is extremely rare.

Chronic empyema sinus only develops when the empyema cavity was drained but (a) drainage was ineffective or (b) presence of foreign body within the empyema cavity or (c) there is some underlying lung pathology.

Cold abscess sinus develops from an inadvertent attempt to drain a cold abscess or a long-standing cold abscess ultimately burrows superficially and drains itself forming a sinus.

Actinomycotic sinus is usually multiple. Surrounding induration, dusky hue and linear puckering of the skin are the characteristic features of this condition. It must be remembered that most often it is secondary to actinomycosis elsewhere.

EMPYEMA.— It is a collection of pus in the pleural cavity. It may be an acute or chronic empyema.

Acute empyema.— In this condition there is profound toxaemia and shock with pleural pain. Collection of pleural fluid is the diagnostic point, which should be confirmed by needle aspiration. Chest X-ray will confirm the diagnosis.

Chronic empyema.— This is a localized empyema walled off by a thick wall. It results from mismanagement of an acute empyema or due to underlying pathology in the lung e.g. bronchiectasis, lung tumour etc. The symptoms are usually vague like ill health, febrile bouts, malaise etc. Chronic empyema may develop due to delay in drainage of acute empyema. A chronic empyema ultimately may discharge outside continuously or intermittently through a sinus in the chest wall. Persistence of chronic empyema may result from either bronchopleural fistula or tuberculosis of the lung or the bronchiectasis or lung abscess or foreign body or rib sequestrum. Diagnosis is established by finding pus with an exploring needle and chest X-ray. If iodized oil is injected into the empyema and subsequent radiographs are taken, the cavity will be outlined.

LUNG ABSCESS.— It is a localized area of suppuration and cavitation in the lung. It usually occurs as a result of aspiration of a bit of septic debris from the oropharynx (with gingivodental disease or oral sepsis) into the lung. Such aspiration may occur during periods of unconsciousness from general anaesthesia, alcoholism, cerebral vascular accident, epilepsy or immersion. Direct route of the infected aspirated embolus in supine position is through the right

main bronchus to the superior division of the right lower lobe or posterior segment of the right upper lobe. So these two segments are the common sites of primary lung abscesses. The organisms responsible for this disease are alpha- and beta-haemolytic streptococci, staphylococci, non-haemolytic streptococci, E. Coli and anaerobic bacteria. *Common presentations* are cough, foul-smelling sputum, fever, chest pain, weight loss and night sweats. *Chest X-ray* (thoracic roentgenogram) is not always diagnostic particularly in early stages. In erect posture or lateral decubitus position air fluid level is diagnostic. *CT Scan* is more helpful in delineating the abscess.

BRONCHIECTASIS.— This means dilatation of bronchi. Bronchial obstruction, and dilatation and infection beyond the obstruction are the reasons. Bronchial obstruction may result from a foreign body, plug of tenacious mucopurulent material, tumour and extrabronchial occlusion by lymph nodes. Mucopurulent material fills the bronchi beyond the obstruction with subsequent infection of the bronchial wall with destruction of its muscle and elastic tissue. It is a disease of young people before 20 years of age. As bronchi of children are small, obstruction occurs easily. Cough with purulent expectoration, haemoptysis and recurrent localized pneumonitis are the main clinical manifestations. Bronchoscopy and bronchography are helpful to diagnose this condition.

CARCINOMA OF THE LUNG.— Carcinoma originates from the primary or secondary bronchus or peripherally from small bronchi. There is no pathognomonic symptom, but a patient complaining of vague symptoms with heavy smoking habit should be suspected of this condition. The patient may complain of cough, haemoptysis, dyspnoea, pain in the chest, loss of weight and appetite and wheezing. Finger clubbing is a frequent sign. Any of the above symptoms appearing in a middle-aged person should demand further investigation. In majority of cases the disease starts with influenza-like symptoms. Only a minority of cases start with haemoptysis. Symptoms often simulate those of chronic bronchitis and the clinician wastes valuable time in treating the condition as one of chronic bronchitis. Atelectasis or emphysema may be presented with as these are the obstructive features of a carcinoma of the bronchus. Pleural effusion may be present which may be sanguineous.

Patient may present first with secondary deposits. Deposits in the bone may lead to aching and even pathological fracture. Enlarged stony hard lymph nodes may be seen in the neck and axilla. Recurrent laryngeal nerve paralysis in the absence of thyroid cancer should arouse suspicion of this condition. Pancoast's tumour commences from the apex of the lung and is a type of peripheral tumour. It produces a syndrome known as "Pancoast's syndrome". This comprises Horner's syndrome (ptosis, miosis, enophthalmos and anhidrosis) due to pressure on the sympathetic chain, distension of the veins of the face, neck and thorax due to pressure on the superior vena cava and shooting pain down the arm due to pressure on the nerve trunks of brachial plexus. Later on paralysis of the lower brachial plexus develops.

IMPORTANT POSTOPERATIVE CHEST COMPLICATIONS.—

1. **Aspiration pneumonia.**— Sometimes following general anaesthesia, unconsciousness or semiconscious patient vomits and inhales the vomitus. A surgeon may be called to a dyspnoeic patient recovering from general anaesthesia. Smell of vomitus from the mouth and presence of some of it on the pillow may clinch the diagnosis. Open the mouth, draw forward the tongue and insert a finger far back into the laryngopharynx to look out a piece of food or denture. A bronchoscope may be used if this method fails to remove anything in the trachea or main bronchus to save the patient.
2. **Atelectasis (Collapse) of the lung.**— This is the most frequent postoperative pulmonary complication. This is essentially blockage of some part of the bronchial tree with inspissated

mucus plug. In 80% of cases atelectasis occurs in the right lung and within 1 or 2 days following operation. Infection often occurs in the uninflated portion of the lung. Three varieties are usually seen —

Lobular or segmental atelectasis.— Basal part is usually affected. There is little or no constitutional disturbance. The most important early sign is presence of sonorous rhonchi over the base. Cough and pyrexia are only seen when infection supervenes. If untreated this condition is followed by bronchopneumonia and is called 'postoperative pneumonia'.

Lobar atelectasis.— This is characterized by rise of temperature, dyspnoea and chest pain. On examination, there is limited movement of respiration on the affected side.

Massive atelectasis (Collapse).— This occurs when a plug of mucus obstructs the main bronchus, commonly the left one. There is absolutely no respiratory movement of the affected side. Trachea is displaced to the side of lesion. The apex beat is shifted to the side of lesion. The sternal head of the sternomastoid muscle of the affected side becomes more tense than its fellow as this is an accessory muscle of respiration. This is known as 'Sternomastoid sign'. Cyanosis of the nail beds is almost always seen.

Pulmonary embolism.— This condition is a contributing factor in the deaths of even a large number of patients than previously. Mortality from this complication following surgical procedures is about 0.11 per cent. More importantly, the clinical diagnosis was frequently not made or even considered. To the contrary it should be remembered that the clinical findings alone are insufficient to establish a diagnosis of pulmonary embolism. These findings resemble those of other serious cardio-respiratory diseases. Therefore before starting medical or surgical treatment for pulmonary embolism, an objective diagnosis should be established either by perfusion lung scan or by pulmonary arteriography.

Dyspnoea, chest pain, haemoptysis and hypotension are often present. Physical examination may reveal presence of tachycardia, accentuation of the second pulmonary sound and dilatation of the cervical veins. Hypoxia and peripheral cyanosis may be present particularly in severe pulmonary embolism.

The electrocardiographic changes are not specific but should be borne in mind. Enlargement of P waves, ST segment depression and/or T wave inversion especially in leads III, AVF, V_1, V_4 and V_5 may be noticed. The most common abnormality is ST segment depression probably due to accompanying myocardial ischaemia.

Chest X-ray may show diminished pulmonary vascular markings, though this finding should not be relied upon for diagnosis, as it returns to normal within 24 hours.

Elevated serum lactic dehydrogenase (LDH activity), increased serum bilirubin concentration and normal serum glutamic oxaloacetic transaminase (SGOT) are often the findings of this condition.

Radioisotope scanning of the lungs is a reliable method for diagnosis of pulmonary embolism. Macroaggregated particles of human serum albumin tagged with ^{131}I (10 to 100 micra) are injected intravenously. These particles lodge in the pulmonary arterioles and capillary bed and a scan delineates the distribution of pulmonary arterial blood flow to the various parts of the lungs.

Pulmonary arteriography is also a reliable test. The filling defects in the large pulmonary arteries are diagnostic.

Chapter

30 EXAMINATION OF THE BREAST

HISTORY

Majority of women who come to the surgical outpatient department complain of either pain or lump in the breast or discharge from the nipple. History is taken in the usual manner as mentioned in the chapter 1. Here only specific points are discussed.

1. **Age.**— Fibroadenoma usually occurs in females below 35 years of age. Fibroadenosis may occur at any age, though more common in the middle age. Intramammary breast abscess is most commonly seen in young lactating women and is often referred to as 'mastitis of lactation'. *Carcinoma of the breast* occurs usually in women above 40 years of age, though rarely it may occur earlier, so age should not be the criterion to exclude the diagnosis of breast carcinoma.

2. **Residence.**— Carcinoma of breast and fibroadenosis (mammary dysplasia) are more common in the western world with high incidence in England and Wales. Breast carcinoma is rare in Japan.

3. **Social status.**— Carcinoma of breast and fibroadenosis are more seen in the 'developed' world. There may be a link between diets rich in saturated fatty acids and breast carcinoma (in fact majority of breast diseases). Both these diseases are common in nulliparous women and who have refused the intended purpose of the breasts i.e. breast feeding. These diseases are less common in 'under developed' world where women give birth to multiple children.

4. **Lump.**— The commonest mode of presentation of diseases of the breast is 'lump'. Enquiry must be made about its *mode of onset*, *duration* and *rate of growth*. A lump may develop in the breast following trauma which is either a haematoma or fat necrosis. Trauma may simply attract attention of the patient towards a pre-existing lump. A lump with a long history and slow growth is a benign condition — either fibroadenosis (mammary dysplasia) or fibroadenoma. A lump with a short history and fast growth is probably a carcinoma, though atrophic scirrhous carcinoma is a slow growing tumour. The average duration between the patient finding the lump and reporting it to a surgeon is about 6 weeks in case of carcinoma of the breast.

5. **Pain.**— The student must remember that carcinoma of the breast is a painless condition. A lump which is painless and accidentally felt during washing may be a breast carcinoma and the clinician must be more particular in examining this case rather than ignoring it. Pain is the main complaint of acute mastitis. The pain is of throbbing nature when pus has formed. Pain is also a common complaint in case of fibroadenosis (mammary dysplasia) which becomes aggravated during menstruation. This type of cyclical breast pain is more common in young women with fibroadenosis. In case of fibroadenosis affecting women after menopause there is also localized breast pain which may be due to periductal mastitis or there may be referred pain from musculoskeletal disorders. The students must remember that all neoplasms of the breast — either benign or malignant including carcinoma are painless to start with.

In case of relatively long standing carcinoma of the breast enquiry must be made regarding pain at the back, hip or shoulder. Patients may ignore their presence considering them to be due to rheumatism and not having any relation with the 'lump of the breast'. Such pain may be due to bony metastasis of the carcinoma of the breast.

6. **Discharge from nipple.**— This may be the only complaint which has brought the patient to a surgeon. Fresh blood or altered blood may be discharged in case of duct papilloma or carcinoma. Pus may be discharged in case of mammary abscess. Milk may be discharged during lactation or galactocele or from mammary fistula due to chronic subareolar abscess. Serous or greenish discharge is seen in case of fibroadenosis (mammary dysplasia) and mammary duct ectasia.

7. **Retraction of nipple** may be rarely a complaint which may bring the patient to a surgeon. Retraction for quite a long time or since puberty may be developmental. Recent retraction is of importance and is usually due to underlying carcinoma of the breast.

8. **Loss of weight** is often complained of in case of carcinoma of breast or tuberculosis of breast or chest wall tuberculosis leading to retromammary abscess.

9. **Past history.**— Recurrence of abscess is sometimes seen in congenital retraction of nipple. Tuberculosis of breast may recur. Fibroadenosis (mammary dysplasia) may give rise to symptoms after a good gap. So that if asked carefully the patient may confess that similar problems she had a few years back which disappeared with some sort of treatment. Above all it must be remembered that carcinoma may recur in the opposite breast.

10. **Personal history.**— Marital status of the patient must be enquired into. Fibroadenosis and carcinoma of breast are more common in unmarried or nulliparous women. Menstrual history must be taken so that relation of pain with menstruation may be assessed. Lactational history should also be taken. Suppurative mastitis particularly occurs in women during first lactational period.

11. **Family history.**— Majority of the breast diseases including carcinoma often recur in a family. If specially asked for it may be revealed that the patient's mother or grand mother or sister also suffered from the similar disease.

PHYSICAL EXAMINATION

LOCAL EXAMINATION

The patient must be stripped to the waist to expose completely both the breasts before inspection is commenced. There must be adequate privacy so that the patient can be relaxed. The examining area must be well lighted so that subtle changes in the skin can be identified. The examination of breast is performed mainly with the patient in *sitting posture*. This gives more information regarding the level of the nipples, a lump and palpation of the axillary lymph nodes. Examination may also be performed in *semi-recumbent* (45°) *position*. This position is a good compromise between lying flat which makes the breasts flatten out and fall sideways, and sitting upright which makes the breasts pendulous and bulky. Examination can also be performed in the *recumbent position* so as to palpate the breasts lump against the chest for more information. If in doubt one can examine the patient in *bending forward position* which gives information regarding retraction of the nipple. Always compare both the breasts in inspection.

INSPECTION.— This is carried out (i) with the arms by the side of the body, (ii) with



Fig.30.1.— Compare the level of the nipples. The nipple of the right breast is raised.



Fig.30.2.— Note congenital asymmetrical breasts. The left breast is abnormally small.

the arms raised straight above her head when the lump or dimple may be more marked, (iii) with the hands on her hips pressing and relaxing as the surgeon commands when abnormal movement of the nipple or exaggeration of skin dimples may be evident and lastly (iv) with the patient bending forwards from the waist so that the breasts fall away from the body. Any failure of one nipple to fall away from the chest indicates abnormal fibrosis behind the nipple. Inspection of the whole breast should be done systematically.

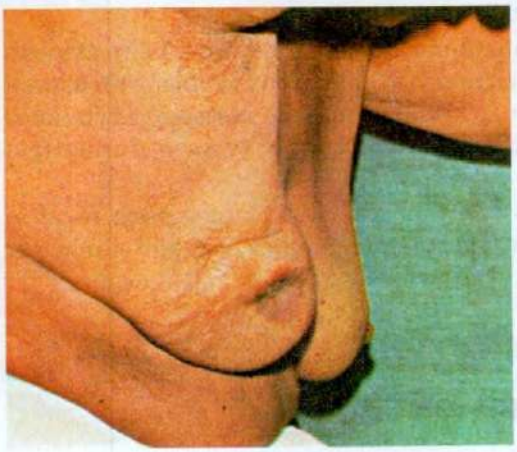

Fig.30.3.— Shows how retraction of nipple due to carcinoma (right side) can be so well detected in *bending forward position.*

1. **Breasts.**— Both the breasts are inspected in their entirety and the following points are noted — (i) *Position* — whether displaced in any direction. (ii) *Size* and *shape* — whether larger or smaller that its fellow. Sometimes males breast becomes enlarged — the condition is known as gynaecomastia. (iii) *Any puckering or dimpling*? In scirrhous carcinoma the breast may be shrunken and drawn in towards the growth. Dimpling of the skin may be made prominent by lifting the breast gently upwards. In presence of a **swelling** or an **ulcer** determine its position (in relation to four quadrants of the breast), *size, shape* and *surface.*

2. **Skin over the breast.**— (i) *Colour* and *texture.*— In acute mastitis the skin becomes red, warm and oedematous. Similar picture may be seen very rarely in acute mastitis carcinomatosa (acute lactational carcinoma). (ii) *Engorged veins.*— Presence of engorged veins is commonly seen in large soft



Fig.30.4.— A fine demonstration of Peau d' orange.

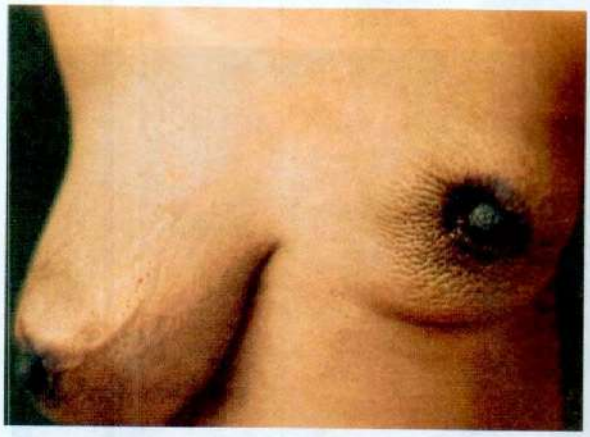

Fig.30.5.— Showing considerable retraction of the left nipple due to carcinoma.



Fig.30.6.— Note how the nipple is retracted towards the carcinomatous lump on the right side. This is even obvious in sitting posture.

fibroadenoma (cystosarcoma phylloides) and in rapidly growing sarcoma. Engorged veins may also be seen when there is presence of acute lactational mastitis with huge breast abscess. (iii) *Dimple, retraction* or *puckering* is often noticed in scirrhous carcinoma of the breast. (iv) *Peau d' orange* is a classical sign in case of carcinoma of the breast. This is due to blockage of subcuticular lymphatics with oedema of the skin which deepens the mouths of the sweat glands and hair follicles giving rise to the



Fig.30.7.— Best method to demonstrate the levels of the nipples. Note slight elevated level on the right side affected by carcinoma.

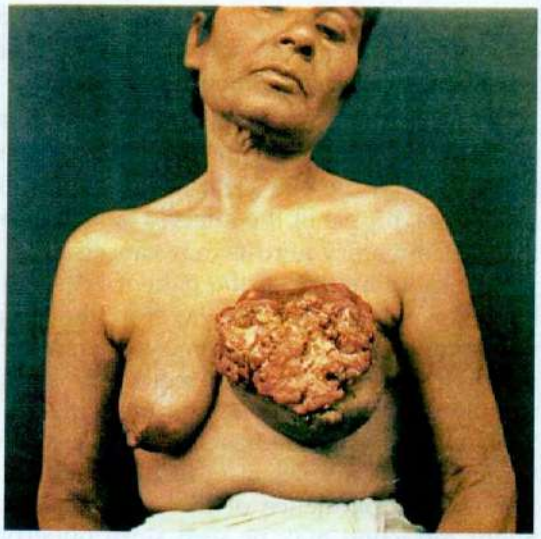

Fig.30.8.— An advanced carcinoma showing fungation and excavation.

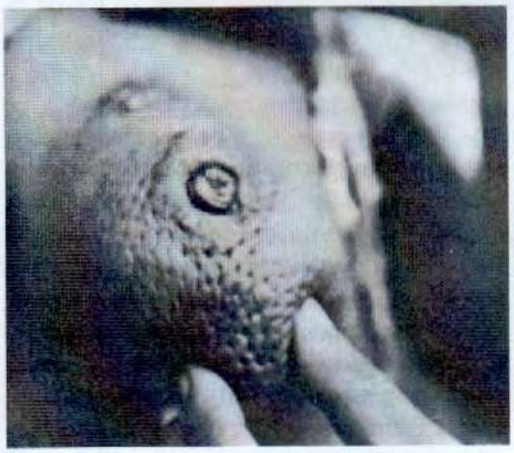

Fig.30.9.— A fine demonstration of 'peau d' orange'.



Fig.30.10.— Note retraction of the left nipple due to presence of carcinoma at the upper and outer quadrant shown by an arrow. One can detect a swelling there.

typical 'orange peel' appearance. (v) *Nodules* may be observed in the breast which are often metastatic. (vi) *Ulceration* and *fungation*.— There may be ulceration in any part of the skin of the breast which are examined according to chapter 4. Fungation of the skin is a late feature of advanced carcinoma of the breast due to infiltration of the skin by the growth. Fungation may also occur in case of large soft fibroadenoma or in a rapidly growing sarcoma due to the fact that the skin becomes atrophied at the site of maximum pressure over the huge swelling and ultimately gives way so that the growth fungates out. But in this case the skin is not infiltrated. This can be demonstrated by means of a probe which can be passed underneath the skin margin in this case, but this is not possible in case of a fungating carcinoma where the skin is infiltrated.

3. **Nipple.**— (i) *Presence*.— Are both nipples present and symmetrical or one is retracted or destroyed (Fig. 30.8). (ii) *Its position*.— Compare the level of the nipples on both sides. Vertical distance from the clavicle and horizontal distance from the midline should be considered. In carcinoma, nipple of the affected side is drawn up towards the lump. It should be remembered that inflammatory fibrosis may cause similar elevation of the nipple. This elevation of the nipple will be more marked if the patient is asked to raise both the hands above the head (Fig.30.12). Nipple may be displaced away from the lump in case of fibroadenoma. Nipple may be destroyed when Paget's disease has almost eroded the nipple or a fungated carcinoma has destroyed the nipple. (iii) *Number*.— Accessory nipples may be present besides the normal ones. These are usually found anywhere along the milk line (ridge) which extends from the axilla to the groin. Such accessory nipple has also been seen on the inner aspect of the thigh. Milk may discharge through these nipples also during lactation. (iv) *Size* and *shape*.— Is it prominent, flattened or retracted? Prominence of the nipple may be due to an underlying swelling such as a cyst. Slight retraction may be seen since puberty. Recent retraction of the nipple with the onset of the present illness is very much significant. Most often it is due to carcinoma of the breast and occasionally due to chronic inflammation. In Paget's disease, the nipple is completely des-



Fig.30.11.— Retraction of nipple with Peau d' orange is clearly seen in a case of carcinoma of the left breast.

troyed, a red and flat ulcer being present in its place. (v) *Surface.*— Look for cracks, fissures or eczema. (vi) *Discharge* if any.— Note the character (see above). Is the discharge coming from the nipple or from its immediate neighbourhood (mammary fistula)?



Fig.30.12.— Note how retraction of the nipple can be made more prominent by raising both hands above the head.

4. **Areola.**— The normal areola is slightly corrugated and contains a few small nodules — Montgomery's glands. These glands become larger during pregnancy when these are known as Montgomery's tubercles. (i) *Colour.*— The skin of areola of young girl is pale pink, but it becomes slightly darker in adult life. It becomes brown during pregnancy. (ii) *Size.*— It becomes larger in case of a huge swelling of soft fibroadenoma or sarcoma. Diminution of the size of the areola is sometimes noticed in scirrhous carcinoma. (iii) *Surface* and *texture.*— Look for crack, fissure, ulcer, eczema, swelling or discharge. In Paget's disease, the areola becomes bright red in the early stage and is destroyed leaving a red weeping ulcer later on. It is useful to remember that eczema is usually a bilateral affection, whereas Paget's disease is purely unilateral. As mentioned earlier glands of Montgomery may become hypertrophied during pregnancy and lactation to produce small swellings here. This is not a pathological condition. Occasionally Montgomery's gland may be enlarged forming a retention cyst similar to a sebaceous cyst. Such cyst may become infected.

5. **Arm and thorax.**— After completing inspection of the breast a quick look at the arm of the affected side and the thoracic wall may be well informatory. *'Cancer en cuirasse'* i.e. multiple cancerous nodules and thicken infiltrated skin like a coat of armour may be seen in the arm and the thoracic wall. *Brawny oedema* of the arm may be due to extensive neoplastic infiltration of the axillary lymph nodes. It is mainly due to lymphatic blockage. Oedematous arm may also be seen after radical mastectomy. It is also a feature of lymphatic obstruction, but infection may play a contributory role.

6. **Axilla and supraclavicular fossa.**— These regions should particularly be inspected for any swelling due to enlarged lymph nodes. The students must make a habit of inspecting these regions, so that he should never ignore these regions. Subsequently he has to palpate these regions.

7. **The patient is asked to raise her arms above her head.** This is the last part of



Fig.30.13.— Palpating the breast with the palmar surface of the fingers with the hand flat. Remember breast carcinoma is best felt with this method and with the flat of the hand.

inspection and should not be missed. The change in the shape of the breast caused by lifting the arms often reveals lumps, puckering and distortion, not visible when the arms are by the sides. This action also reveals the lower surfaces of the breasts. If the submammary fold is still not visible, lift up the breast and inspect it. This may reveal a swelling which was missed so long, as also skin nodules (metastatic) or presence of any skin disease. In this position the clinician should inspect the axillae properly for swelling, skin puckering and ulceration. The shoulder movements are also noticed which may be affected by lymph node enlargement in the axilla.

PALPATION.— Palpation should be made initially in sitting position, in semi-recumbent (45°) position and later on in recumbent position. It is advantageous to put a small pillow under the scapula on the side to be examined, so that the breast concerned rests evenly on the chest wall and does not fall to the side of the body. Sometimes it is necessary to put her arm above her head during palpation.

It is advisable to **palpate the normal breast first.** The texture of the breast varies from woman to woman. In some it is soft and smooth when it is quite difficult to distinguish the glandular tissue from the subcutaneous tissue; whereas in others it is firm lobulated with nodularity. Palpation should be made with **palmar surface of the fingers** with the hand flat and not with the 'flat of the hand' as this means with the palm of the hand which is not correct. Palpation should also be made between the pulps of the fingers and the thumb to know more about a swelling. The normal breast gives a firm lobulated impression with nodularity. **Now the affected side is palpated** in a similar fashion keeping in mind the findings of the normal side and comparing them with those of the affected side. The **four quadrants** should be palpated systematically. Also feel the *axillary tail*. Do not miss to palpate just *behind the nipple*. There may be a small lump here and no other abnormality in the whole of the breast. This will be missed if the students do not make habit of this examination as a routine. While palpating this region an eye must be kept on the nipple — whether any discharge is being expressed out of the nipple or not. In case of duct papilloma or duct carcinoma blood will come out.

If any lump is detected in this examination, it should be felt by the palmar surfaces of the fingers with the hand flat. Remember, breast cancer is best felt by the hand flat, which being less sensitive fails to feel any other lump than carcinoma (e.g. fibroadenosis, fibroadenoma etc.).

If a lump is detected the following points should be noted :—

1. **Local temperature and tenderness.**— Local temperature is best felt by the back of the fingers. A warm and tender swelling is generally inflammatory in origin, but one should keep in mind acute mastitis carcinomatosa which may present the similar features.

2. **Situation** (in which quadrant).— Carcinoma can occur anywhere in the breast including the axillary tail (a prolongation of breast tissue into the axilla), but is commonly found in the upper and outer quadrant. Fibroadenosis also occurs more often in the upper and outer quadrant

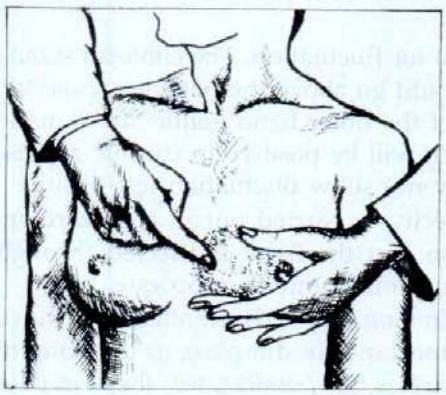

Fig.30.14.— Shows the method to elicit fluctuation in a case of a breast lump. The examination is carried out from behind. With one hand using two fingers the lump is held by the sides (watching fingers) and kept fixed, whereas with index finger of the other hand (displacing finger) the centre of the lump is pressed to displace fluid within the lump.

and in the axillary tail. Fibroadenoma is more commonly seen in the lower half than in the upper half though it may occur in any part of the breast.

3. **Number.**— Though majority of the breast lesions are solitary, yet fibroadenosis is known for its multiplicity. Multiple lumps are felt. Even the opposite breast may be affected.



Fig.30.15.— Testing a lump in the breast for fixity to the pectoralis major by moving the lump in the direction of its fibres while the muscle is made taut by asking the patient to press her hip as hard as she can.

4. **Size and Shape.**— Whether globular (fibroadenoma) or uneven (carcinoma).

5. **Surface.**— Smooth surface is a feature of benign condition, whereas an uneven surface is a significant feature of carcinoma.

6. **Margin.**— In case of fibroadenosis the margin is ill-defined. In case of fibroadenoma (a firm tumour within the soft tissue) and more so in carcinoma (stony hard tumour within the soft surrounding) the margin is well defined. In fibroadenoma the margin is regular and tends to slip off the palpating fingers, whereas in carcinoma the margin is very much irregular and does not tend to slip away from the palpating fingers as it is fixed to the breast tissue.

7. **Consistency.**— Consistency of the lump must be assessed properly — whether cystic, firm, hard or stony hard. In case of soft cystic swelling test for fluctuation. A firm, sotty or diffuse India-rubber feel is characteristic of fibroadenosis. A fibroadenoma is a firm



Fig.30.16.— See how to examine for fixity of fhe breast lump with the pectoralis muscle or pectoral fascia.

encapsulated tumour, whereas carcinoma is stony hard in consistency. In case of sarcoma consistency may vary from place to place.

8. **Fluctuation.**— A cystic swelling should be tested for fluctuation. The clinician stands behind the patient, who sits on a stool. His two hands should go above the patient's shoulder. With one hand he holds the cyst and with index finger of the other hand gentle tap is made on the centre of the cyst. Besides a cyst the fluctuation test will be positive in chronic abscess (it may not be tender) and lipoma. A very tense cyst may not show fluctuation test positive.

9. **Transillumination test.**— This can only be effectively carried out in a dark room. The torch is placed on the under-surface of the breast so that the light is directed through the breast tissue to the examiner. Fat is translucent but a solid tumour is opaque.

10. **Fixity to the skin.**— This can be tested in the following ways : (i) An attempt to move the tumour side to side or up and down will make the appearance of dimpling or tethering of the skin; (ii) the skin is made to slide over the tumour which is not possible; (iii) the skin over the tumour is pinched up, this is also not possible if the tumour is fixed to the skin. When a wide area of the skin over the tumour is attempted to pinch up, peau d' orange will become prominent. Hard nodules may be felt in the skin in late stage of breast cancer as part of cancer-en-cuirase.

Two terms must be understood in this respect — *'Tethered'* to the skin and *'fixed'* to the skin. (i) The term *'tethered'* to the skin means that the malignant disease has spread to the fine fibrous septae that pass from the glandular tissue of the breast to the skin. These are called Astley Cooper's ligament. Infiltration of these strands makes them shorter and inelastic and thus pull the skin inwards resulting in puckering of the skin. The lump at this stage can still be moved independently of the skin for some distance after which this may cause puckering of the skin. So tethering of the lump to the skin can be tested by moving the lump side to side and watching if the skin dimples at the extremes of movement. (ii) *'Fixity'* means that there is direct and continuous infiltration of the skin by the tumour and the tumour cannot be moved independent of the skin and the overlying skin cannot be pinched up.

It must be remembered that any tumour lying immediately deep to the nipple will be fixed to the nipple be it benign or malignant as the main mammary ducts may have travelled through the growth and so the nipple becomes fixed.

11. **Fixity to the breast tissue.**— This is demonstrated by holding the breast tissue with one hand and gently moving the tumour with other hand. A fibroadenoma is not fixed to the breast tissue and can be easily moved within the breast substance. That is why it is called a 'Breast mouse'. A carcinoma on the other hand is fixed to the breast substance and cannot be moved within it. Fibrous strands can be felt radiating from the mass into the breast substance.

12. **Fixity to the underlying fascia and muscles** (pectoralis major and serratus anterior).— The patient is asked to place her hand on her hip lightly. The lump is moved in the direction of the fibres of pectoralis major first and then at right angles to them as far as possible. The lump is mobile in both the directions. Now the patient is asked to press her hip as hard as possible. *Feel the anterior fold of the axilla* to verify that the muscle has been made taut (Figs. 30.15 & 30.16). Move the lump once more in the same directions and compare the range of mobility. Any restriction in mobility indicates fixity to the pectoral fascia and pectoralis major. There will be total restriction of mobility along the line of the muscle fibres if it is fixed to it but slight movement along the right angle of the fibres may be possible.

A swelling occupying the outer and lower quadrant of the breast will lie on serratus anterior, to which it may be fixed. This is ascertained by asking the patient to push against a wall with the outstretched hand of the affected side while the mobility of the swelling is tested. The swelling, if fixed to serratus anterior, will move very little.

13. **Fixity to the chest wall.**— If the tumour is fixed irrespective of contraction of any muscle, it is fixed to the chest wall.

14. **Palpation of the nipple.**— It is very important to palpate the nipple and the breast tissue just deep to the nipple. Tumour just deep to the nipple is usually fixed to the nipple. The underlying lump is moved and see if this movement causes or increases nipple retraction. Gentle pressing of such tumour may express discharge from the nipple. Note its colour and nature. Note whether it appears from one or many ducts. When the discharge is visible, try to decide its nature — whether blood, serum, pus or milk. Take the bacteriological swab for culture. The source of such discharge must be found out by gently pressing on each segment of the breast and areola. If the nipple is *retracted*, press gently from both sides deep to the nipple. This will evert it if the retraction is congenital or spontaneous. If it is due to carcinoma the nipple cannot be everted like this.

If there is any **ulcer,** examine it as discussed in Chapter 4.

EXAMINATION OF LYMPH NODES

This examination is very important. On the finding of this examination the staging of the breast cancer can be judged as also the prognosis. This examination is carried out in sitting position. The muscles and fasciae around the axilla should be relaxed. If this cannot be properly achieved this examination can be done in lying down position.

A. **Palpation of the Axillary group of lymph nodes.**—

1. PECTORAL GROUP.— This group is situated just behind the anterior axillary fold. The patient's arm is elevated and using the right hand for the left side the fingers are insinuated behind the pectoralis major. The arm is now lowered and made rest on the clinician's forearm



Fig.30.17.— Show the position of the arm while examining the lymph nodes of the axilla. Note that the arm is adducted and allowed to rest comfortably on the clinician's forearm.



Fig.30.18.— Method of palpation of the pectoral group of lymph nodes.

(Fig. 30.17). This will relax the pectoralis minor. With the pulps of the fingers try to palpate the lymph nodes. The palm should look forward. The thumb of the same hand is used to push the pectoralis major backwards from the front (See Fig. 30.18). This facilitates palpation.

2. BRACHIAL GROUP.— This group lies on the lateral wall of the axilla in relation to the axillary vein. To palpate this group left hand is used for the left side. The group is felt with the palm directed laterally against the upper end of the humerus (Fig. 30.23).

3. SUBSCAPULAR GROUP.— This lies on the posterior axillary fold and is best examined from behind. Standing behind the patient the examiner palpates the antero-internal surface of the posterior fold while with the other hand the patient's arm is semi-lifted. Now the nodes are palpated lying on this surface with the palm of the examining hand looking backwards (Fig. 30.19).

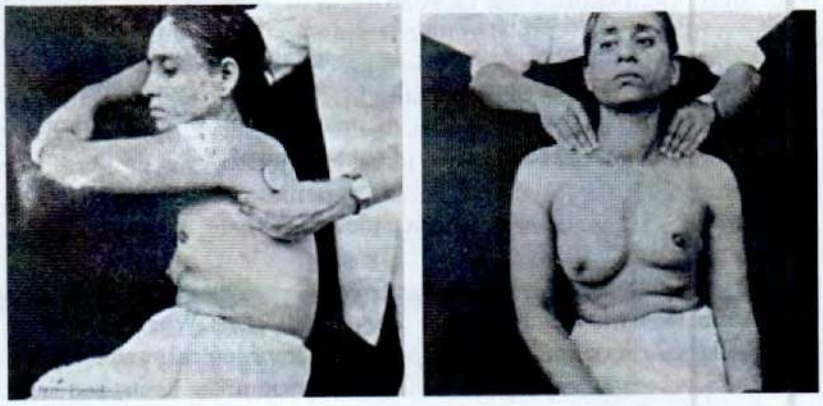

Figs.30.19 & 30.20.— Method of palpation of the subscapular and supraclavicular group of lymph nodes.

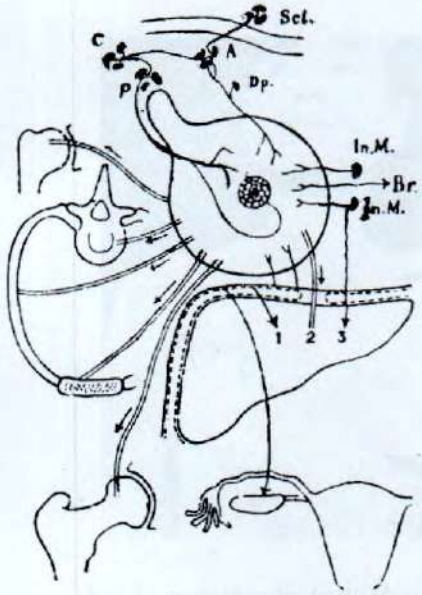

Fig.30.21.— Diagrammatic representation of lymphatic drainage (single line) and blood spread (double line) in carcinoma of the breast. Lymphatic drainage from the subareolar plexus of Sappey and outer quadrant of the breast takes place first to the pectoral (P), then central (C) and lastly to the apical (A) group of axillary lymph nodes. The other two groups of the axillary nodes, viz. the subscapular and lateral group may be involved in a retrograde way. From the apical group the supraclavicular group may be affected. On the left side the supraclavicular group is affected by retrograde permeation. The upper quadrant of the breast drains partly to the delto-pectoral node but mainly to the apical group. From the inner quadrant the lymph spread occurs to the internal mammary group (In. M) and to the other breast (Br). From the lower and inner parts of the breast the lymph vessels form a plexus over the rectus sheath and pierce the costal margin to communicate with the subperitoneal lymph plexus. From this place, cancer cells may drop by gravity into the pelvis (Transcoelomic implantation) and may cause metastases in the ovary (Krukenberg's tumour). It may be noted that the liver may be involved in two ways — subperitoneal plexus and by blood spread.

Blood spread — occurs in addition to the liver, to the bones, especially to the sternum, ribs, spine and upper ends of the humerus and femur. Lungs may be affected.

Method of examination for various groups of lymph nodes involvement in carcinoma of the breast. See the text.



Fig.30.22.— Pectoral group.



Fig.30.23.— Brachial group.



Fig.30.25.— Central group.



Fig.30.24.— Subscapular group.



Fig.30.26.— Supraclavicular group (Both sides should be palpated).

4. CENTRAL GROUP.— This group of the left side is examined with the right hand. At first the patient's arm is slightly abducted and pass the extended fingers right upto the apex of the axilla directing the palm towards the lateral thoracic wall. The patient's arm is now brought to the side of her body and the forearm rests comfortably on the clinician's forearm. The other hand of the clinician is now placed on the opposite shoulder to steady the patient. Palpation is carried out by sliding the fingers against the chest wall when the lymph nodes can be felt to slip out from the fingers (Fig. 30.25).

5. APICAL GROUP.— Examination is carried out in the same manner as the previous one, but the fingers are pushed further up. If the lymph nodes are very much enlarged they may push themselves through the clavipectoral fascia to be felt through the pectoralis major just below the clavicle.

B. Palpation of Cervical lymph nodes.—

One must always examine the *supraclavicular group* to conclude the examination of the lymph nodes. To examine this group the clinician stands behind the patient and dips the fingers down behind the middle of the clavicle. Two sides are simultaneously palpated and compared (See Fig. 30.20). Passive elevation of the shoulders would relax the muscles and fasciae of the neck to facilitate palpation. One must always flex the neck of the patient slightly for better palpation of this group of lymph nodes.

While palpating the lymph nodes careful assessment must be made as to their number, size, consistency, mobility etc. as discussed in Chapter 8.

GENERAL EXAMINATION

In *carcinoma of the breast,* the **liver** should be examined for secondary deposits. **Lungs** and **bones** particularly the ribs, spine, sternum, pelvis, upper ends of femur and humerus should also be examined as they may be involved by metastasis. **Rectal** and **vaginal** examinations are also necessary to detect Krukenberg's tumour of the ovary, which occurs by transcoelomic implantation or lymphatic permeation.

In *gynaecomazia* firstly a careful history should be taken. Patients having stilboestrol as treatment of prostatic cancer may persent with this condition. The testis should be examined for anorchism, cryptorchism, teratoma or chorionepithelioma. Liver should be examined for cirrhosis. Associated leprosy may cause enlargement of breast in males. Certain drugs like digitalis, spironolactone, isoniazide may initiate enlargement of breast. Of course, certain amount of breast enlargement in male is noticed during puberty, which is considered normal.

SPECIAL INVESTIGATIONS

These are mainly used firstly to differentiate cancer breast from other benign lesions of the breast, secondly to detect an early cancer and finally to know the extent of the cancer, its spread and staging.

1. ASPIRATION.— This is performed in case of cystic lumps of the breast which were preliminarily thought to be benign. But if the aspirated fluid is blood-stained, if the mass does not completely disappear on aspiration and if the cyst recurs rapidly after two aspirations, excision biopsy should be called for. Fluid should be sent for cytology. Though negative results is of little importance, yet the positive result means excision of the lump or even mastectomy.

2. MAMMOGRAPHY.— Roentgenography to identify breast disease was first used in 1913 at the University of Berlin. Since then, mammography has been widely accepted as a routine

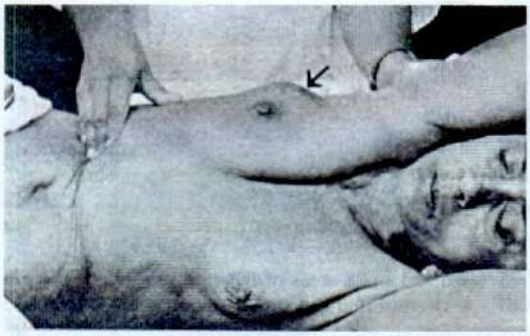

Fig.30.27.— Examining the liver in a case of carcinoma of the right breast.



Fig.30.28.— A case of gynaecomazia.

examination in the evaluation of breast diseases. There has been many technical improvements and modifications of equipment design in mammography. Most significant has been xeroradiography. This is not a different process but rather a different method of recording X-ray images.

Xeroradiography utilizes an aluminium plate thinly coated on one surface with vitreous selenium. Selenium is a photoconductor. The charged xeroradiographic plate is placed beneath the breast and a conventional exposure is made. The positive charges on the selenium are discharged in proportion to the varying intensities of the X-rays reaching the plate, modified by the tissues traversed. This leaves an electrostatic image of the breast on the plate. A finely divided negatively charged blue powder or toner is sprayed on the surface of the plate and is attracted to the latent image of positive charges. This produces a blue image of the breast which is transferred to a special plastic-coated paper and permanently fused by heat.



Fig.30.29.— Another case of gynaecomastia due to ingestion of stilboestrol for carcinoma of prostate.



Fig.30.30.— Mammography showing carcinoma of the breast. See the text.

Malignant lesions reveal themselves as localized fine or punctate calcification and small areas of increased stromal density and architectural distortion (See Fig. 30.30). Benign tumours like fibroadenoma present as denser calcification with smooth outline (Fig. 30.32). Accuracy of mammography is 95% or more in atrophic and post menopausal breasts. Accuracy is significantly lower in younger patients whose dense glandular breasts can obscure even clinically obvious masses.



Fig.30.31.— The best method of palpation of liver in case of carcinoma of the breast.

If mammography suggests that there is an impalpable carcinoma in a particular quadrant of the breast, difficulties may be experienced in attempting to localize the area for biopsy. It is of great importance that the excised specimen should be sent for radiology to ensure that the area of microcalcification is within the biopsy.



Fig.30.32.— Mammography showing a fibroadenoma. Note the smooth outline of the tumour.

Contrast Mammography.— In this technique contrast medium is injected in one of the major mammary duct and then soft tissue X-ray is taken. Intraductal tumour (duct papilloma is demonstrated by smooth filling defect; whereas duct carcinoma is demonstrated by irregular filling defect) can be detected by this technique.

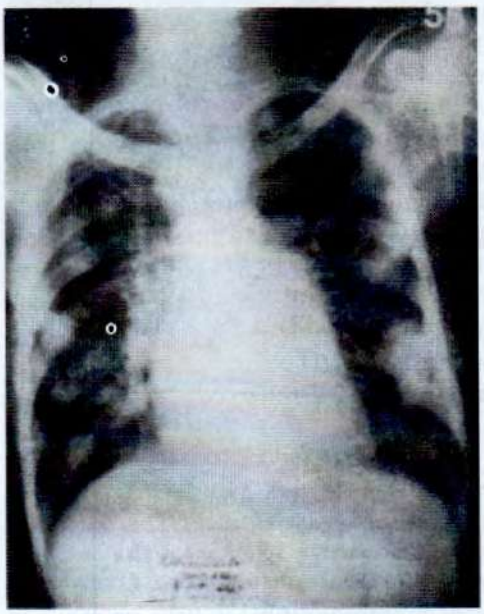

Fig.30.33.— Chest X-ray showing metastasis in the lungs in a case of breast cancer.

3. THERMOGRAPHY.— This is nothing but pictorial representation of the infrared emission of the breast. This shows malignant lesions as areas of increased heat production and increase in vascularity. But thermography has proved to be somewhat disappointing in the diagnosis of carcinoma of breast. At present 50 to 75 per cent of cancers are recorded as not being detected by thermographic scan. But when used in conjunction with physical examination and mammography, thermography can be expected to increase the number of cancers detected by 3 to 5 per cent.

4. ULTRASOUND.— This is an important diagnostic tool in many organ systems, but its application in breast cancer detection remains in the developmental stage. At present, ultrasonic examination of the breast is useful only in differentiation of solid from cystic swellings greater than 2.5 cm in diameter. Recently improvement in instrumentation has helped to detect 0.5 cm solid

breast masses. Fluid-filled lesions lack an internal echo pattern, whereas solid lesions are filled with internal echoes. If the solid lesions are homogeneous, the echo pattern is evenly distributed throughout the mass. Echoes from the boundaries of a benign lesion are smooth and well-defined. Infiltrating lesions such as scirrhous carcinoma have jagged borders. Breast ultrasonograms are of limited usefulness in the detection and diagnosis of breast cancer. If however sophisticated instruments become commercially available, gray scale echography may become a valuable adjunctive procedure.

5. BIOPSY.— It is customary when presented with a palpable mass in the breast to remove the lump for accurate diagnosis. Whatever the degree of suspicion of cancer, most surgeons still prefer to be quite certain before committing a woman to mastectomy or radiotherapy.

The frozen section histology technique has probably been put to use more often in the management of mammary lesions than in any other situation. There has been considerable interest recently in needle biopsy as an alternative to excision procedures. There were a few false-negative results, but greater problem was due to false positive results received with cytodiagnosis of aspirated material. Drill biopsy has been claimed to avoid this problem. 95% accuracy has been claimed. No false positive result has been recorded but the cancers less than 1 cm in diameter may be missed by drill biopsy. Needle can be introduced to the centre of the suspicious area under X-ray control. With this technique it has been claimed that as small as 3 mm in diameter tumours have been successfully identified and biopsied.

Search for distant metastases :—

6. CHEST X-RAY.— This is the simplest method of looking for potential site of visceral metastasis. This should be a routine investigation for all women with early carcinoma of the breast.

7. BONE X-RAY.— A skeletal survey is often asked for particularly X-ray of the spine, pelvis and upper ends of humerus and femur.



Fig.30.34.— Skull metastasis in breast cancer is being revealed by bone scan.

8. BONE SCAN.— Development of skeletal scintigraphy has undoubtedly improved our accuracy for detecting bony metastases. Radioactive fluorine was one of the first few bone-seeking isotopes that had successfully demonstrated skeletal metastases earlier than would be detectable by conventional X-ray. Since then enormous improvement in the sensitivity of the scanning devices and availability of newer radioactive bone-seeking isotopes have made skeletal scintigraphy an attractive method to detect bone metastases. So for routine skeletal survey a whole body skeletal scan followed by specific radiology of the areas of abnormal uptake should be the method of choice. Healing fractures, Paget's disease and osteoarthritis also show hot spots as bone metastases. Obviously presence of bone metastases detected by bone scan will put the patient into stage IV category. False positive and false negative results are disturbing. In suspicious cases shown by the scan, open bone biopsy is the last court of appeal.

9. LIVER SCAN.— Isotope scintigraphy of the liver using radioactively labelled colloid may demonstrate metastases, but the secondary deposits less than 1 or 2 cm in diameter may



Fig.30.35.— Showing accessory breast in the axilla.

be missed. Recent promising reports using grey scale ultrasonography, which appears to have a greater accuracy, are encouraging in this field.

10. COMPUTERISED TOMOGRAPHY (CT Scan) can be used to detect mediastinal or retroperitoneal masses of malignantly involved lymph nodes.

11. BIOCHEMICAL STUDIES.— Elevated alkaline phosphatase and gamma glutamyl transaminase are crude estimates of liver metastasis. Similarly increase in urinary hydroxyproline indicates collagen break down from metastasis.

So far as the diagnosis of early cases and determination of prognosis are concerned urinary steroids have got some value. An abnormally low level of aetiocholanolone (a metabolite of the adreneal androgen dehydroepiandrosterone) in relation to the total amounts of 17-hydroxycorticosteroids in the urine is detected in patients with breast cancer. It also indicates bad prognosis. This is called "negative discriminants". They show poor response to adrenalectomy and hypophysectomy.

DIFFERENTIAL DIAGNOSIS

Congenital abnormalities.— *Amazia* (congenital absence of breast) may very rarely affect one or both sides. It may be associated with absence of sternal portion of the pectoralis major. *Polymazia* (accessory breasts) may be seen occasionally in the axilla, groin and thigh — along the line of development of milk ridge. This is due to failure of disappearance of the milk ridge in that area. Accessory breast may lactate during the period of lactation. *Diffuse hyperplasia, pendulous breast* or *underdevelopment of the breast* on one side or both sides may be seen.

Traumatic fat necrosis.— An injury or subcutaneous injection to the breast may lead to this condition. This is due to death of some fat cells and saponification of their fat. These are presented as painless lumps very much similar to those of carcinomata of the breasts. On examination, hard, irregular lump will be felt which will be fixed or tethered to the skin. The findings are also akin to carcinoma. History of injury, discolouration of the skin, bruising (if present), no enlargement of lymph nodes, mammographic findings etc. are the distinguishing features from carcinoma. On incision white chalky area of fat necrosis becomes evident which is similar to fat necrosis following acute pancreatitis.

Acute Mastitis (Fig. 30.36, page 428).— This is commonly seen in the child-bearing age particularly during lactation. Bacteria enter the breast either through the blood stream or through the lactiferous ducts. The latter is due to trauma during lactation. Pain is the first symptom which is dull in the beginning and gradually becomes a *continuous* throbbing pain. On examination, the breast becomes swollen, red, hot and tender. Gradually localization takes place. Axillary lymph nodes are enlarged and tender. This condition leads to suppuration and formation of *intramammary abscess*. This should be diagnosed by throbbing pain, brawny, swollen, oedematous and tender swelling. Fluctuation is a late sign and should not be waited for.

Subareolar mastitis occurs from infected glands of Montgomary or from a furuncle on or near the areola.

Retromammary abscess has nothing to do with the breast. It arises from a tuberculous rib or spine and from empyema necessitatis.

Chronic abscess.— If attempts are made to control acute mastitis by injudicious antibiotic treatment, a chronic abscess develops. It becomes encapsulated by a thick fibrous wall. A painless firm mass (antibioma) develops which may or may not be fixed to the skin. At this time this condition becomes indistinguishable from carcinoma. A previous history of pain is very suggestive of this condition. Moreover this lump will be quite soft at the centre while a carcinoma is hardar at the centre. Aspiration is the final court of appeal in doubtful cases.

Mammary fistula.— This is a chronic discharging fistula. The usual sufferers are women of 3rd decade. It occurs unilaterally or bilaterally. The fistula communicates with one of the major ducts. This condition may be a frequent complication of long-standing retraction of the nipple and infection being restricted to a single obstructed duct. The abscess ruptures and subsides only to repeat the cycle till it forms the mammary fistula. This condition may also result from periductal mastitis, which has affected all the major ducts.

Mammary duct ectasia (Plasma cell mastitis).— This is generalized dilatation of the major duct system of the breast with retrograde dilatation of the lobular ducts. The lining epithelium is atrophic and the ducts are filled with secretion. This secretion is made up of amorphous debris and lipoid-containing macrophages. The fluid within the ducts which causes the nipple discharge, varies and may be coloured green, brown, viscous or even white. Due to leakage of lipoid through the thin duct wall, there is periductal mastitis, the cellular element of which is predominantly plasma cells. The associated periductal fibrosis often leads to nipple retraction. This inflammatory process regresses within a few days, but recurs again with more severe form. Ultimately an abscess develops at the edge of the areola.

Patients are usually in 40-55 years age group. Younger women with congenitally inverted nipples may be affected with this condition early. The disease may remain asymptomatic, but a persistent nipple discharge or a lump in the breast in the para-areolar region is the usual complaint. The problem is that if the abscess is drained, it leads to a fistula into the affected duct, which is known as *mammary duct fistula*. In chronic cases the characteristic appearance is a mammary duct fistula, with inverted nipple and distortion of the areola. Sometimes a chronic abscess may be formed which presents as a tender mass with skin fixity, nipple retraction and enlarged axillary lymph nodes — almost simulating a carcinoma. Diagnosis is established by needle biopsy.

Benign breast disease.— It is a very common condition occurring in women between the ages of 20 and 40 years. It is mostly seen in them who have denied its intended function e.g. spinsters, childless married women or multiparous women who have not suckled their children. The incidence strictly falls after menopause, in contrast to malignant breast disease. Various names were given over the past few years e.g. fibroadenosis, chronic mastitis, fibrocystic disease, cystic hyperplasia, benign mammary dysplasia, cystic mastopathy etc. None of these nomenclatures is now acceptable. These actually described the histological features of breast biopsies of this disease, such as fibrosis, epithelial hyperplasia, adenosis, microcyst formation and lymphocytic infiltration. These changes are quite non-specific and have been noticed even in breasts without any complaint. These aberrations are believed to be caused by very minor hormonal imbalances during the multiple menstrual cycles of the reproductive period.



Fig.30.36.— A case of acute mastitis.

The best nomenclature which is now accepted for this condition is — ***ABERRATIONS OF NORMAL DEVELOPMENT AND INVOLUTION*** **(ANDI)**. The aetiology is poorly understood but it seems to involve the action of cyclical circulating hormone levels on breast tissue. This is influenced by cyclical changes in the hormonal environment, oral contraceptives, hormone replacement therapy and probably some factors such as diet and smoking.

Microscopic changes include adenosis, cyst formation, papillomatosis, epithelial hyperplasia, fibrosis and lymphatic infiltration.

The commonest *MANIFESTATIONS* of ANDI are cyclical **pain** and nodularity. When pain is a dominant symptom, it needs to be assessed apart from nodularity. Such pain can be divided into cyclical (premenstrual) and non-cyclical (irregular or continuous) mastalgia. Cyclical mastalgia is often related with ANDI. But non-cyclical mastalgia is usually not associated with ANDI, but may be associated with musculoskeletal origin of the chest wall or may be associated with inflammatory episodes caused by duct ectasia or periductal mastitis. It must be remembered that a persistent, localized pain or discomfort may be a symptom of cancer.

Nodularity or **lump** in the breast is a very common symptom. It may be associated with certain amount of pain (mastalgia), which has been described in the previous paragraph. Though lump is present for sometime, yet it is often the pain which draws the patient's attention towards the lump. These nodules are often in the upper and outer quadrant of the breast and it must be remembered that lump in this region is noticed earlier than lump in the centre and inner half of the breast. The lumps usually become larger and more tender premenstrually. Though it is difficult for the patient to judge whether the lump is progressively becoming larger or not, yet if the patient suggests that the lump *fluctuates in size* is typical of this condition and it almost excludes the diagnosis of carcinoma. Lumps can be single or multiple and characteristically sudden in onset. Lumps are often cysts, as changes in the secretory activity of breast tissue commonly give rise to such a cyst. Cysts may be single or multiple and vary from barely palpable to very large size. The cysts are usually smooth, round and of variable consistence. Fluctuation of the cyst can be elicited if the lump is relatively superficial and is often best elicited from behind (Fig. 30.14). It must be remembered that very tense cyst is often hard and not fluctuant.

One must consider during examination whether the nodularity is focal or diffuse. When it is focal, one must take it seriously. *Diffuse nodularity* is often bilateral and found mainly in the upper and outer quadrant. If the patient is seen first in premenstrual period, it is useful to examine her again in the first half of the cycle.

Focal nodularity should be examined very carefully to exclude malignant condition. One must differentiate between a benign lump and a cyst. It is advisable to apply further diagnostic tests to obtain a definite diagnosis. One of the easiest method is fine-needle aspiration. The aspirate should be sent for cytological examination to exclude presence of malignant cells. Following successful aspiration, there should not be residual mass and the

breast should be re-examined several weeks later to ensure that it has not reaccumulated.

A benign lump or a cyst from this condition is neither fixed nor tethered to the skin or the underlying muscle and is usually moderately mobile within the breast. The axillary nodes are usually not enlarged. It must be remembered that the other breast may be affected with the similar condition.

Patient usually complains of pain in one breast, which becomes worse just before menstruation. Pain is also felt after over-using the arm. There may be greenish or serous discharge through the nipple. On examination, simultaneous palpation of both the breasts in standing posture from behind may reveal nodular breasts on both sides. They may be slightly tender. The nodules are better felt by the fingers and thumb, *but cannot be felt by the palmar surfaces of the fingers*. The nodules are firm and rubbery in texture without any fixation with the skin or pectoralis fascia. These are more often felt in the upper and outer quadrant. Cysts may or may not be palpable. Axillary lymph nodes may occasionally be slightly enlarged and tender.

Cysts and swellings simulating cysts arise from various conditions : (i) Cystic hyperplasia of fibroadenosis; (ii) Chronic abscess; (iii) Haematoma; (iv) Galactocele; (v) Hydatid cyst; (vi) Lymph cyst; (vii) Serocystic disease of Brodie; (viii) Colloid degeneration of carcinoma; (ix) Papillary cystadenoma etc.

Solitary cyst of the breast is diagnosed by the fluctuation test. The swelling is held with one hand and with the other hand the centre of the swelling is pressed. This displaces the fluid towards periphery to displace the fingers which are used to hold the swelling. The solitary cyst presents as the blue-domed cyst of Bloodgood. Aspiration of the cyst is diagnostic. (i) If the aspirate is not blood-stained, (ii) if there is no residual lump after aspiration, (iii) if the cyst does not refill and (iv) if the cytological examination of the aspirated fluid does not show evidence of malignant cells, *the cyst is considered to be not malignant*.

TUMOURS OF THE BREAST

BENIGN TUMOURS.—

Fibroadenoma.— Two histological varieties of fibroadenoma are seen — (a) *Pericanalicular* fibroadenoma which consists of fibrous tissue surrounding a few small tubular glands. This type of fibroadenoma is smaller in size and hard. (b) *Intracanalicular* fibroadenoma contains more glands which become stretched into elongated spidery shapes and become indented by fibrous tissue. This type of fibroadenoma is larger in size and comparatively soft.

The pericanalicular fibroadenoma (hard) occurs in young girls between 15 and 30 years, whereas the intracanalicular (soft) variety is seen in middle-aged women between 35 and 50 years. The main symptom is *a painless lump* in the breast. It is a slow growing tumour and remains more or less same size for quite a long time. This may occur anywhere within the breast substance, though more often seen in the lower half than in the upper half.

On examination, the swelling is not tender and without any rise in temperature. It is smooth, firm and possesses a well-defined margin. This tumour is not fixed to the skin or deeper structure. It is a highly mobile tumour without any tethering inside the breast substance. That is why it is often called a "breast mouse" or a "floating tumour". There is *no enlargement of the axillary lymph nodes*. Sometimes a soft fibroadenoma undergoes cystic degeneration leading to cystadenoma which is ultimately transformed into cystosarcoma phylloides.

Cystosarcoma Phylloides (Serocystic Disease of Brodie).— This is a real giant fibroadenoma, seen in women of over 40 years of age. Main complaint is huge swelling, though occasionally the patients may complain of serous discharge through the nipple. This is not a malignant

condition. The tumour does not infiltrate the skin though the overlying skin becomes thin and tense. The subcutaneous veins become prominent. This tumour is not fixed to deeper structures. The axillary lymph nodes become rarely enlarged only secondary to infections.

Duct papilloma.— This tumour occurs in one of the major ducts. Occasionally two or more ducts of the same breast may be affected. Majority of the patients are above 30 years of age. *Bloody discharge* from the nipple is the main symptom. Generally it is bright red blood and less often dark blood. A cystic swelling may sometimes be felt just deep or lateral to the areola. If this swelling be pressed bloody discharge will come out from the affected duct. This should be considered as premalignant condition and the axillary lymph nodes are only enlarged when the growth has become malignant.

Other benign tumours like neurofibroma, lipoma, papillary cystadenoma etc. are rarely found in the breast.

MALIGNANT TUMOURS are : atrophic scirrhous carcinoma — the least malignant, scirrhous carcinoma — the commonest type, encephaloid (medullary) carcinoma, comedocarcinoma, colloid carcinoma and mastitis carcinomatosa — the most malignant, duct carcinoma, Paget's disease of the nipple and sarcoma.

Carcinoma (scirrhous).— Since there is great hope of curing this disease only when it is still localized to the breast tissue, *a diagnosis of carcinoma should be made in the early stage. A lump, as discovered by palpation with the flat of the hand, is painless, stony hard and irregular in surface and outline, is a carcinoma.* Carcinoma should not be excluded if the patient is young or the lump is free from the skin or deeper structure or if the lymph nodes are not involved. Involvement of lymph nodes determines the prognosis of the case. There may be dimpling, retraction or puckering of the skin (resulting from invasion of the ligaments of Cooper followed by contraction), retraction of the nipple (due to extension of the growth along the lactiferous ducts with subsequent fibrosis) or *peau d' orange* (i.e. oedema with pitting; oedema being due to obstruction of the lymphatics by cancer cells and pitting being due to fixation of the hair follicles and sebaceous glands to the subcutaneous tissue). Late features include adhesion to the deep fascia, pectoral muscle and chest wall, presence of distant subcutaneous nodules, fungation, brawny induration of the arm, *cancer en cuirasse* and distant metastases in the liver, lungs, bones (by blood) and ovary (by transcoelomic implantation).

Clinical stages : **Stage I** — The growth is limited to the breast. There may be a small area of adherence to the skin. **Stage II** — In addition to the growth in the breast, the axillary lymph nodes are involved but they are still mobile. There may be just tethering of the growth to the pectoral muscle. **Stage III** — The growth is fixed to the pectoral muscle or the skin involvement is larger than the tumour. **Stage IV** — The growth is fixed to the chest wall; axillary nodes are no longer mobile; supraclavicular nodes are affected; and there is metastasis in the opposite breast, skin away from the tumour, liver, lungs, bones or other distant organs such as the ovary.

International Classification & TNM Classification.— This is advocated by International Union against cancer. T denotes the characteristic of the tumour, N — the characteristic of the lymph nodes (particularly the axillary group) and M — the presence or absence of metastasis.

T1 — means the size of the tumour is same as or less than 2 cm diameter. No fixation or nipple retraction. T2 — more than 2 cm but less than 5 cm diameter. No pectoral fixation but skin may be tethered. T3 — more than 5 cm but less than 10 cm diameter. There may be pectoral fixation. Skin infiltrated or ulcerated. T4 — more than 10 cm diameter. Chest wall fixation. Skin involved, but not beyond breast. N0 — No palpable lymph nodes. N1 — Axillary

lymph nodes are palpable and mobile. N2 — Axillary nodes are palpable and fixed. N3 — Supraclavicular nodes are involved. M0 — No Metastasis. M1 — Metastases are present including involvement of the skin beyond the breast and contralateral nodes. This TNM classification can be applied in clinical staging :— **Stage I** — T1, T2 and N0, **Stage II** — T1, T2 & N1; **Stage III** — T3, T4 & M0; **Stage IV** — T4, N3 & M1.

Prognosis.— In assessing prognosis in a case of carcinoma of the breast, the following points should be taken into consideration : (1) **Age.**— The younger the patient, the worse becomes the prognosis. Prognosis is better when the growth occurs within 5 years of menopause. (2) **Sex.**— Carcinoma of the male breast carries a bad prognosis owing to early fixation to the chest wall. (3) **Site.**— Growths occurring at the inner and lower quadrant convey a bad prognosis owing to early metastasis into the mediastinum and abdomen. (4) **Nature of the Growth.**— The prognosis is the worst with the mastitis carcinomatosa whereas it is much better with the atrophic scirrhous as the spread is limited by extensive fibrosis. Contradictory to the common belief the prognosis is better with medullary carcinoma than with scirrhous. (5) **Metastasis.**— It must be remembered that there is 75% chance of cure if the carcinoma is operated upon before the involvement of lymph nodes; whereas the percentage comes down to 25 as soon as the axillary nodes are invaded — so the importance of diagnosing carcinoma before the involvement of lymph nodes cannot be too strongly impressed. Involvement of distant lymph nodes, lung, liver, bones etc. makes the case hopeless.

Atrophic Scirrhous.— The patient is very old and the tumour grows slowly for years. Due to excessive fibrosis, the spread and metastasis are limited.

Comedocarcinoma.— Tumours arising in peripheral ducts confine within the ducts and the proliferation of cells leads to central plug of necrotic neoplastic cells. These extrude from the cut surface of the growth.

Colloid carcinoma — is cystic and occurs in older patients. Microscopically the cells lie in pool of extracellular mucin. Prognosis is better than scirrhous carcinoma.

Encephaloid type occurs in young women. The tumour grows rapidly to give rise to a soft swelling which becomes adherent to the surrounding structures. There may be no retraction of the nipple. The lymph nodes are soon involved. This type of cancer has a high degree of lymphocytic infiltration, a factor which in itself is associated with a favourable prognosis.

Acute lactation carcinoma or mastitis carcinomatosa or inflammatory carcinoma is extremely malignant. It occurs during pregnancy or lactation. This often produces obstruction of subepithelial lymphatics and veins resulting in redness and oedema. This gives a false impression of inflammation. It has been mistaken for acute mastitis and incised to let out pus. Differentiation is made by the facts that pain and tenderness are comparatively slight and there may be fever but no rigor.

Duct Carcinoma.— The symptoms are very much similar to those of duct papilloma. On examination a *solid swelling* may be felt at the region just beneath or around the areola. The axillary lymph nodes are enlarged. Diagnosis is mainly established by mammography and finally by biopsy.

Paget's Disease.— This is a malignant condition characterized by gradual destruction of the nipple and *development of a carcinoma within the breast* usually close to the nipple. At first the nipple and areola become red and covered with scales. Subsequently, the scales are detached and the nipple is destroyed. Ultimately, the nipple disappears completely, leaving a flat bright red weeping surface. In the early stage this condition very much resembles eczema of the nipple. The differentiating features are.— (i) Eczema is often bilateral, whereas Paget's disease is unilateral;



Fig.30.37.— Fungated carcinoma. Note the everted edge.



Fig.30.38.— Fungated recurrence after mastectomy.

(ii) Eczema is often seen during lactation, whereas Paget's disease is seen at menopause; (iii) Eczema itches, but Paget's disease does not itch; (iv) Vesicles are formed in eczema whereas vesicles are not found in Paget's disease; (v) In eczema the nipple remains intact, but in Paget's disease the nipple may be destroyed; (vi) In eczema no lump can be felt deep to the nipple, whereas in Paget's disease one may feel a lump deep to the nipple.

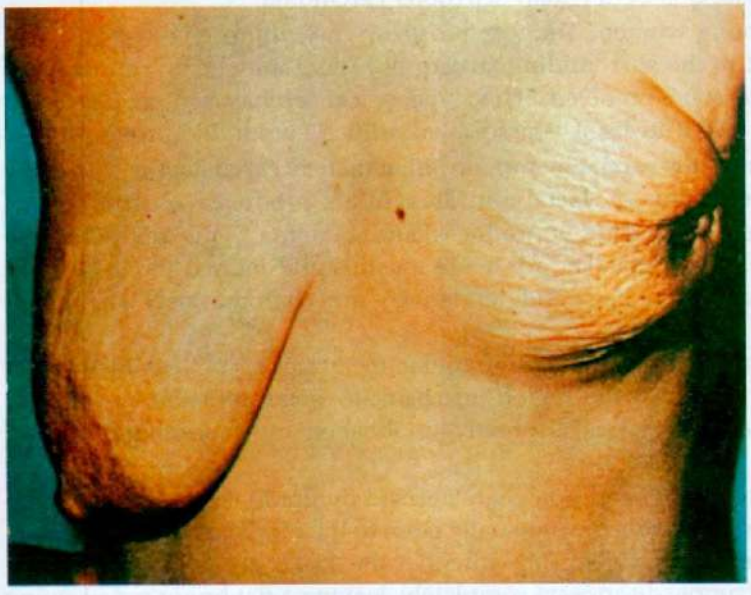

Fig.30.39.— Demonstration of extreme retraction of nipple due to carcinoma on the left side.

Carcinoma of the male breast — is a more serious condition than that in the female since it affects the chest wall more readily, owing to much less amount of tissue between the carcinoma and the chest wall. It has all the characteristic features of carcinoma with a great tendency to fungate quite early (Fig. 30.41).

Sarcoma.— Sarcomatous changes in a soft fibroadenoma account for more than half the cases of sarcoma of the breast. A history of swelling, which is present for months or years and has recently enlarged rapidly, is frequently obtained. On examination, a large prominent swelling with dilated subcutaneous veins and without retraction of the nipple is observed. It is of inequal consistency, parts of it being hard, parts soft and parts fluctuating, due to cystic degeneration or haemorrhage. Only in the late stages does the skin become adherent (without being infiltrated) or fungation occurs. Lymph nodes are not involved until very late.



Fig.30.40.— Carcinoma in a male breast showing fungation.

Gynaecomastia.— Increase in the ductal and connective tissue element of the male breast is called gynaecomastia. Though this condition may occur commonly at puberty idiopathically, yet one or other cause may be found out. It may occur in liver failure, in Klinefelter's syndrome, in leprosy, in chorioncarcinoma and sertoli cell tumours of the testis, in bronchial carcinoma (ectopic hormonal production), in adrenal or pituitary diseases, after stilboestrol therapy for prostatic carcinoma and after ingestion of certain drugs like digitalis, isoniazide, spironolactone, certain tranquillizers, steroid and a few other diuretics. The common idiopathic variety found at puberty among school boys is a firm disc of breast tissue beneath the areola and is called the 'hard' type. It may be slightly tender and is called 'true gynaecomastia'. But the variety which develops following oestrogen therapy is of soft consistency and is called 'soft' type of 'mammaplasia'.

Chapter

31 EXAMINATION OF A CASE OF DYSPHAGIA

HISTORY.—

1. **Age.**— Carcinoma of Oesophagus is a disease of old age (50 to 70 years). To the contrary in infancy the common causes of dysphagia are oesophageal atresia, dysphagia lusoria and congenital cardiospasm. In children dysphagia may be caused by impaction of a foreign body, paralysis of soft palate (due to diphtheria) and acute retropharyngeal abscess. In young girls hysterical spasm may be seen. In middle age the common causes of dysphagia are benign stricture (may occur at any age of adult life), achalasia (30 to 40 years) and Paterson-Kelly (Plummer-Vinson) syndrome.

2. **Sex.**— Paterson-Kelly syndrome (sideropenic dysphagia) occurs almost exclusively in females nearing menopause (over 40 years of age). Achalasia occurs in both sexes though women may dominate. Carcinoma of oesophagus mainly affects men.

3. **Mode of onset and progress.**— A sudden onset may suggest foreign body obstruction or acute oesophagitis. A comparatively short history of difficulty in swallowing (a few months duration) in the elderly suggests carcinoma of oesophagus. A slow onset with a long history obtained in benign stricture, achalasia, pharyngeal pouch etc. Progressively worsening dysphagia is typical of carcinoma and stricture. In case of spastic lesions, (Paterson-Kelly syndrome and Schatzki's rings) there may be periods of remission. Difficulty in swallowing first with solids and subsequently with liquids points to mechanical obstruction. This is mainly seen in carcinoma of oesophagus. Difficulty in swallowing first with liquids and subsequently with solids is typical of achalasia (cardiospasm). In the latter condition the weight of the solid helps in overcoming the spasm.

4. **Regurgitation.**— This is often seen in achalasia, but may be seen in sliding hiatus hernia with stooping or straining. Pharyngeal pouch may cause regurgitation. In this case a lump in the neck may be visible which may be emptied with pressure.

5. **Pain.**— Typical pain along with dysphagia is only complained of in reflux oesophagitis or in corrosive stricture. But majority of patients with dysphagia will complain of some sort of discomfort at the site of obstruction. This type of pain is mainly felt just beneath the sternum. According to the site of obstruction this is felt either behind the upper part of the sternum or behind its lower part.

6. **Vomitus.**— If present, should be examined noting the amount, reaction (it is generally not acid in causes other than reflux oesophagitis), odour and presence of blood (carcinoma or oesophageal reflux or very rarely in achalasia). When the oesophagus has been marked by dilatation the patient may complain of vomiting of foul-smelling stagnated intraoesophageal contents of 2 to 3 days old. Post-prandial vomiting is also complained of in para-oesophageal hernia. This condition may cause haematemesis.

7. **Coughing** is not a common symptom in these cases. Persistent coughing is only come across due to irritation by a mediastinal mass. Coughing occurring immediately after feeds

indicates tracheo-oesophageal fistula. Coughing, which occurs sometime after ingestion of meals may be due to regurgitation of food in case of cardiospasm or pharyngeal pouch.

8. **Loss of weight.**— This is quite appreciable and is common in achalasia and malignant lesion of the oesophagus.

Past history.— A history of radiation, instrumentation or swallowing of corrosive such as concentrated acid or alkali may be obtained in simple stricture of oesophagus. Past history of vagotomy indicates perioesophagitis to be the cause of dysphagia. Similarly previous history of hiatus hernia repair indicates excessive tightness of the repair to be the cause of dysphagia. Diphtheria may result in dysphagia. Symptoms of other bowel diseases may indicate a rare entity — Crohn's disease of oesophagus.

PHYSICAL EXAMINATION

General Survey.— Emaciation is usual in a case of dysphagia but is much more prominent in case of achalasia and malignant diseases. Anaemia is very much evident in Paterson-Kelly syndrome and carcinoma of oesophagus and in reflux oesophagitis. Radial pulses will be inequal on two sides in case of aneurysm of the aorta. Concave and spoon-shaped nail is peculiar of Paterson-Kelly syndrome. The tongue is also smooth, pale and devoid of papillae in Paterson-Kelly syndrome.

1. **Examination of the Mouth and Pharynx.**— Tonsils and fauces should be examined for any lesion. Test the mobility of the soft palate to determine if it is paralysed or not. The posterior wall of the pharynx is examined to exclude retropharyngeal abscess.

2. **Examination of the neck.**— An obvious swelling like enlarged thyroid or lymph nodes may press upon the pharynx or oesophagus to cause dysphagia. A soft swelling which appear during meals just above the left clavicle is the third stage of pharyngeal pouch. Pressure over such swelling will cause regurgitation of food into the mouth. 'Tracheal tugging' is a sign of aneurysm of the arch of the aorta. The clinician stands behind the patient and holds the cricoid cartilage with a little upward traction. The downward tug can be felt with each throb of the aorta. It must be remembered that if no relevant sign can be elicited on examination of the neck one must palpate the left supraclavicular fossa to exclude presence of enlarged lymph nodes which may be the only sign in case of carcinoma of the oesophagus.

3. **The Chest.**— This should be examined routinely but in majority of cases there will be hardly any abnormality in a case of dysphagia. One may get pleural effusion in a late case of oesophageal carcinoma. Aspiration pneumonitis, which may cause lung abscess, bronchiectasis, haemoptysis may be seen in achalasia. In this condition when the oesophagus is hugely dilated dyspnoea may be complained of with displacement of adjacent structures. On careful examination one may detect intra-thoracic hernial sac in case of paraoesophageal hernia.

4. **The abdomen.**— Barring an abnormal mass due to infiltration of oesophageal carcinoma to the upper end of the stomach and enlarged liver due to metastasis in carcinoma of the cardia, there will be hardly any abnormality in a case of dysphagia.

5. **The spine.**— If Pott's disease is suspected to cause dysphagia due to its cold abscess pressing on the pharynx or oesophagus one should examine the cervical region of the spine.

SPECIAL INVESTIGATIONS

1. **Laryngoscopy.**— This should be better performed by ENT specialist.

2. **Oesophagoscopy.**— This is an important investigation so far as a case of dysphagia is concerned. In case of *achalasia of the oesophagus* as soon as the instrument has passed the

cricoid cartilage it appears to enter a cave partially filled with dirty water. When the fluid is aspirated the cardiac orifice can only be located with difficulty due to its contracted condition. In case of *benign stricture* this investigation not only helps in the diagnosis but also can be used to dilate the stricture with an oesophageal bougie. In *carcinoma of oesophagus* it is not only diagnostic but also gives an indication about the histology of the cancer by taking biopsy specimen through oesophagoscopy. Cytologic examination may be performed from brushing to establish the diagnosis. In *reflux oesophagitis* this investigation shows inflammation of the mucosa of the lower end of the oesophagus.

3. **Chest X-ray.**— Chest X-ray may show an air-fluid level in the mediastinum behind the heart which is diagnostic of paraoesophageal hernia. However barium swallow radiography confirms the diagnosis. In achalasia with a moderately dilated oesophagus if a lateral chest X-ray is taken a typical air-fluid level may be seen in the posterior mediastinum which along with the typical symptoms is diagnostic of achalasia. Conditions like Pott's disease and aneurysm of the aorta (calcification of the wall) can be diagnosed by straight X-ray.

4. **Radiography with Barium Meal.**— This is by far the most important investigation in dysphagia. More or less all the conditions which may give rise to dysphagia will be diagnosed by this investigation. If a ***pharyngeal pouch*** is suspected a thin emulsion of barium should be used for barium swallow. This will show that the barium first feels the pharyngeal pouch, and then overflows from the top. *In* ***stricture*** the meal is first arrested in the dilated oesophagus immediately above the constriction and gradually trickles down through the stricture. The stenosed portion is usually smooth and does not produce any soft tissue shadow as may be obtained in carcinoma. In case of ***carcinoma*** the dilatation of the oesophagus above the tumour is less marked. Moreover, the constricted part is extremely irregular (the filling defect which is often called 'Rat-tail' deformity) and a 'shouldering' may be seen at the proximal end of the filling defect. A soft tissue shadow of the tumour can be obtained. In ***achalasia*** the radiographic appearance varies according to the extent of the disease. In early stage there is only mild dilatation of the oesophagus, whereas in late stage there is massive dilatation and tortuosity of the oesophagus. Retained intraoesophageal contents are typically seen. The hallmark of achalasia on barium swallow examination is the distal 'bird-beak' taper of the oesophagogastric junction at the distal end of the dilated oesophagus. No benign oesophageal tumours produce characteristic features in barium swallow examination. In case of ***leiomyoma*** there is a smooth filling defect. In case of ***polyps*** there is also characteristic filling defect detected in this examination. Barium swallow oesophagogram is quite helpful in diagnosing both type I and type II ***hiatus hernia***. In type I the gastro-oesophageal junction is above the level of the diaphragm, whereas in type II one can see the barium filled part of stomach in the thorax. In ***gastro-oesophageal reflux*** during the course of barium swallow examination reflux can be demonstrated. To demonstrate such reflux



Fig.31.1.— The typical Barium meal X-ray of a pharyngeal pouch.

one can even use 'water-sipping' test accompanied by abdominal compression. Swallowing of water will cause relaxation of the distal oesophagus.

5. **Manometric examination.**— This examination is helpful to diagnose a case of achalasia by showing failure of LES (Lower Oesophageal Sphincter) to relax reflexly with swallowing and lack of progressive peristalsis throughout the length of the oesophagus. In *diffuse oesophageal spasm* this is the main test to diagnose this condition. This study shows multiphasic, repeatitive and high-amplitude contractions that occur after swallowing in the smooth muscles of the oesophagus. This study is also helpful in diagnosis of *scleroderma*. In case of *gastro-oesophageal reflux*, pH recording in the oesophagus 5 cm above the distal oesophageal high-pressure zone shows decline in pH to less than 4, which is a clear evidence of gastro-oesophageal reflux.

6. **Exfoliative cytology.**— To examine the oesophageal lavage for malignant cells is a good investigation to discover oesophageal carcinoma in quite early stage when radiology is negative. This is more efficiently done through oesophagoscope.

7. **Ultrasound and CT Scan.**— The value of these investigations is not much in finding out the cause of dysphagia. These investigations however may find out abnormal masses in the mediastinum and aortic aneurysm which may press on the oesophagus to cause dysphagia.

CAUSES OF DYSPHAGIA

1. **In the mouth.**— Tonsillitis, quinsy (peritonsillar abscess), certain varieties of stomatitis, carcinoma of the tongue and paralysis of the soft palate (due to diphtheria in children and bulbar paralysis in adults).

2. **In the pharynx.**—

(i) *In the lumen* — impaction of a foreign body (e.g. coin, tooth and denture).

(ii) *In the wall* — acute pharyngitis, malignant growth, hysterical spasm, Paterson-Kelly syndrome.

(iii) *Outside the wall* — Retropharyngeal abscess, enlarged cervical lymph node, malignant thyroid etc.

3. **In the oesophagus.**—

(i) *In the lumen* — impaction of foreign body.

(ii) *In the wall* — (a) Atresia of oesophagus; (b) Benign stricture — may be due to reflux oesophagitis, swallowed corrosives, tuberculosis, scleroderma, radiotherapy etc.; (c) Spasm — Paterson-Kelly syndrome, achalasia, webs and rings, diffuse oesophageal spasm etc.; (d) Diverticulum; (e) Neoplasms — mainly malignant; (f) Nervous disorders — bulbar paralysis, post-vagotomy; (g) Miscellaneous — Crohn's disease etc.

(iii) *Outside the wall* — malignant or any large thyroid swelling, retrosternal goitre, pharyngeal diverticulum, aneurysm of the aorta, mediastinal growth, dysphagia lusoria, perioesophagitis after vagotomy, hiatus hernia particularly paraoesophageal (type II) and tight oesophageal hiatus repair.

DIFFERENTIAL DIAGNOSIS

Atresia of oesophagus with distal tracheo-oesophageal fistula.— This is the commonest form of oesophageal atresia occurring in about 90% of patients. The proximal oesophagus ends as a blind tube and the distal oesophagus is joined to the lower part of the trachea with a tracheo-oesophageal fistula. During foetal life this condition may be recognized by presence of hydramnios, but this may not be present. The most important clinical presentation is that the infant has an

abundance of saliva which may bubble out from the mouth. 'Spitting up' or frank vomiting during feeding is a characteristic sign. Aspiration, choking, cyanosis and respiratory distress are often noticed. The abdomen may be progressively distended. Attempts to push a nasogastric tube will be stopped at the upper mediastinum. When the tip of this tube is radio-opaque, straight X-ray is situ can diagnose this condition. Straight X-ray also reveals intestinal gas which indicates communication of distal trachea with distal oesophagus. The greatest risk of this condition is that there is a great possibility of aspiration of gastric juice, which is highly injurious to the lungs.

Paterson-Kelly syndrome (Plummer-Vinson syndrome).— This syndrome was first described by Paterson and Kelly in 1919 and subsequently more elaborately described by Plummer and Vinson in 1921. The patient is nearly always a middle-aged woman who presents with difficulty in swallowing. Glossitis, anaemia and dysphagia form the important triad of this disease. The tongue becomes devoid of papillae, smooth and pale. The lips and corners of the mouth are often cracked. Hypochromic anaemia is almost always present. The nails become brittle and spoon shaped (Koilonychia). Dysphagia is due to spasm of the circular muscle fibres at the extreme upper portion of the oesophagus. There may be formation of webs. The mucous membrane is hyperkeratotic at places and desquamated at others. This lesion is considered to be pre-cancerous.

Pharyngeal pouch.— It is also called Zenker's diverticulum occurring at the upper end of the oesophagus protruding posteriorly through a gap between two parts of the inferior constrictor muscle — i.e. oblique thyropharyngeal part and transverse cricopharyngeal part. It may be considered as a Pulsion diverticulum — herniation of the oesophageal mucosa and submucosa through the weakened area. This diverticulum mainly affects subjects over 50 years of age and more frequently men than women.



Fig.31.2.— Barium meal X-ray of a case of cardiospasm. Note the huge dilatation of the oesophagus above the smooth narrowing of the lower end of the oesophagus.

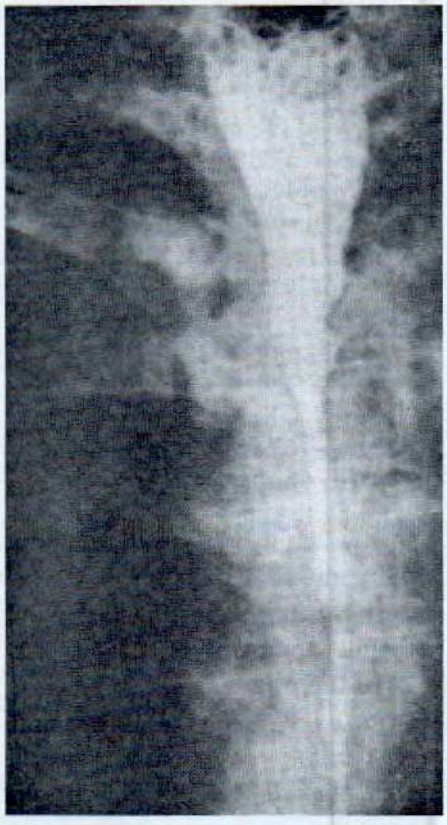

Fig.31.3.— Barium meal X-ray of benign stricture of the oesophagus. Note the long irregular narrowing with slight dilatation of the oesophagus above the stricture. There is no 'shouldering'.

Regurgitation of undigested food at an unpredictable time or after turning from one side to the other is often the main complaint in the beginning. Sometimes the patients may wake up from sleep with a feeling of suffocation followed by a severe cough. When the pouch enlarges it tends to compress the oesophagus which leads to dysphagia. When the patient drinks the pouch can be seen to be enlarging with gurgling noise in the neck. X-ray with a very thin barium emulsion should be performed as thick mixture refuses to be washed out from the pouch following examination.

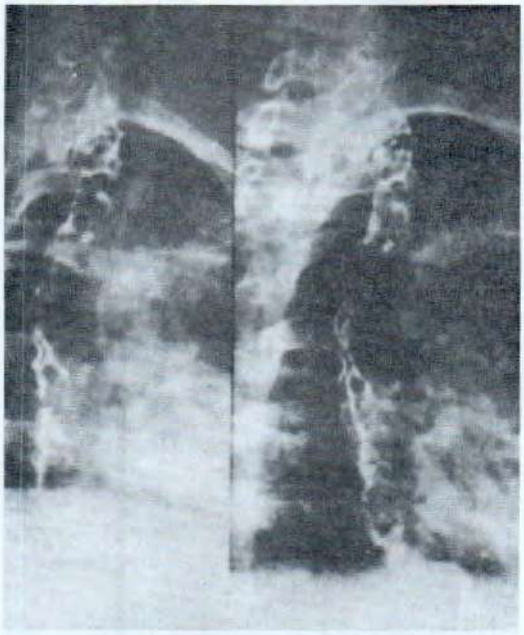

Fig.31.4.— Barium meal X-ray of a case of oesophageal varix.

Traction diverticula may be occasionally seen in the middle portion of the oesophagus near tracheal bifurcation. These result from pull of scar tissue from an adjacent inflammatory process, usually tuberculous lymph nodes. These diverticula are often symptomless.

Benign stricture.— The causes of benign stricture have been set out above. Past history must carefully be taken to find out the cause. Difficulty is more with solids than with liquids. X-ray with barium meal will show a long tortuous stricture with some dilatation of the proximal oesophagus and without any shouldering at the proximal end of the stricture.

Achalasia or Cardiospasm.— This represents failure of the lower oesophageal sphincter to relax with deglutition. The number of ganglion cells in the myenteric plexus seems to be diminished. Usually women around 40 years of age are affected. Regurgitation of food even several hours after meal is the main complaint. Dysphagia is more with liquids and less so with solid (weight of the food helps). Complications like pneumonia, bronchiectasis and lung abscess may take place. X-ray with barium meal will reveal enormous dilatation with smooth termination (smooth pencil-shaped 'bird-beak') and lack of fundal gas in the stomach.

Diffuse oesophageal spasm.— The aetiology of this condition is not known and the patients usually complain of chest pain and dysphagia due to repeatitive and high-amplitude oesophageal contractions. Some sort of emotional stress and anxiety are often associated with along chest pain and dysphagia. There is also regurgitation of food, though many patients experience regurgitation of intraoesophageal saliva during oesophageal colic. Ingestion of cold liquids and food aggravate the condition. Irritable bowel syndrome, pylorospasm, peptic ulcer disease, gallstone and pancreatitis may stimulate diffuse oesophageal spasm. Oesophageal manometry has been considered the ultimate test in the diagnosis of this condition.

Scleroderma.— Oesophageal motor disturbances occur in scleroderma or systemic sclerosis. This is due to fibrous replacement of oesophageal smooth muscle and then the distal oesophagus loses its tone and normal response to swallowing and gastro-oesophageal reflux occurs. In distal 2/3rds or 3/4ths of the oesophagus normal peristalsis gives way to weak nonpropulsive contractions.

Diverticula of oesophagus.— Oesophageal diverticula are epithelial-lined mucosal pouches

that protrude from the oesophageal lumen. All of them are acquired and occur mainly in adults. These commonly occur at 3 separate sites — I. At its most upper part at the pharyngo-oesophageal junction and is known as *pharyngo-oesophageal diverticulum* or *pharyngeal pouch* which has been discussed above. II. *Para-bronchial* or midoesophageal near the bifurcation of the trachea and III. *Epiphrenic* or supradiaphragmatic which arises from the distal oesophagus.

PARABRONCHIAL or MIDOESOPHAGEAL DIVERTICULUM.— This is a traction diverticulum which comes out from the midoesophagus and is in fact a true diverticulum. This occurs in association with tuberculosis or histoplasmosis of the subcarina and parabronchial lymph nodes to which this diverticulum becomes adherent. This condition rarely causes symptom and is discovered accidentally on barium oesophagogram.

EPIPHRENIC DIVERTICULUM occurs within the distal 4 inches of the oesophagus and is a pulsion diverticulum same as pharyngeal pouch. This is due to oesophageal motor dysfunction of the distal oesophagus leading to mechanical distal obstruction. An abnormal elevation of intraluminal pressure occurs and this blows out the mucosa and submucosa of the oesophagus through its muscles. Many patients may remain asymptomatic though dysphagia, regurgitation and retrosternal pain are the main symptoms. This condition is diagnosed by barium oesophagogram, though oesophageal manometry should be performed to identify the exact motor disturbance.

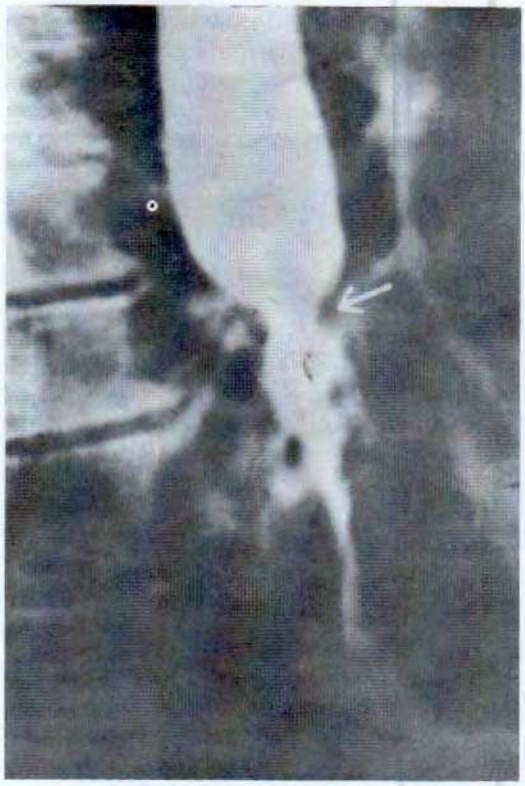

Fig.31.5.— Barium meal X-ray of a case of carcinoma of the oesophagus. There is virtually no dilatation of the oesophagus above the growth. The constricted part is very much irregular — 'rat-tail' deformity of the lower end of the oesophagus. Shouldering is shown by an arrow.

Webs and rings.— Membranous or partially fibrous structures extending across the lumen of the oesophagus and thus constricting the oesophagus partially are called webs or rings. In Paterson-Kelly syndrome this type of web is seen in the upper oesophagus. A lower oesophageal ring (Schatzki's ring) has been found with increasing frequency in patients with hiatus hernia. It is generally located at the oesophagogastric junction and has squamous epithelium on one side, gastric mucosa on the other side and fibrous tissues in the centre. Dysphagia to solid food occurs when the diameter of the lumen is under 13 mm. Careful X-ray examination with contrast will define the level of the web or ring.

Carcinoma of oesophagus.— It should be suspected when a man above 40 years complains of heaviness or oppression behind the sternum at the time of meals. Pain is conspicuous by its absence. Indeed the main complaint is dysphagia, which is steadily progressive. Due to sloughing of a portion of the growth dysphagia may be eased out temporarily. Difficulty is first felt with solid and then with liquid. Unfortunately the patient fails to report in the early stage and majority of them come to the surgical clinic when they are feeling difficulty in



Fig.31.6.— Barium meal X-ray of malignant growth of the oesophagus in its middle third. The filling defect is usually more irregular than is shown in this case.

swallowing semisolids. By this time 3/4 of the circumference has been involved. Pseudo-vomiting i.e. regurgitation of food is often seen. Regurgitated material is usually alkaline mixed with saliva and streaked with blood from malignant growth. Anorexia is another symptom but more often seen in growths at the lower end of the oesophagus. Barium meal X-ray is confirmatory (see 'Radiography with barium meal' under 'Special Investigations'), but too much stress should not be given on negative results. By oesophagoscopy one will be able to see the growth and to take biopsy from it. Exfoliative cytology from oesophageal lavage may clinch the diagnosis very early even when radiology has not been positive. In late stages pressure on recurrent laryngeal nerve may cause hoarseness of voice or erosion of bronchus may lead to broncho-oesophageal fistula. Erosion of aorta, though very rare, is a fatal complication.

Paraoesophageal hiatus hernia.— In this condition the oesophagus remains in its normal position, but a peritoneal hernia occurs alongside the oesophagus through the oesophageal hiatus. Usually a part of stomach herniates. This condition may remain symptomless. If symptoms occur these are usually fullness after meals, early satiety and post-prandial vomiting. Dysphagia is another important symptom. Gastro-oesophageal reflux, which is a very common occurrence in sliding or axial or type I hiatus hernia, does not take place in this condition.

Dysphagia lusoria.— During development of the aortic arch if the proximal portion of the right fourth arch disappears instead of the distal portion, the right subclavian artery will arise as the last branch of the aortic arch and then it courses behind the oesophagus (or in rare instances in front of the oesophagus between the oesophagus and the trachea or in front of the trachea) to supply the right arm. Due to its courses it presses on the oesophagus to cause dysphagia which is known as 'dysphagial lusoria' and it was first recognized by Bayford in 1974.

Gastro-oesophageal reflux.— Slight amount of regurgitation of gastric contents into the oesophagus after a large meal is not uncommon. It is only when reflux occurs with increased frequency and at times when the stomach is not distended that pathologic gastro-oesophageal reflux is considered. The symptoms of this reflux are heart-burn and regurgitation aggravated by postural change. These are associated with dysphagia, substernal chest pain, sensation of something sticking in the throat and bleeding. Reflux of gastric contents irritates the oesophagus causing secondary muscle spasm alongwith inflammation of the mucosa leading to fibrosis and stricture.

Chapter

32 EXAMINATION OF ABDOMINAL INJURIES

HISTORY.— *Mechanism of injury* should be enquired into. It may give a clue to the diagnosis. Closed injuries are due to waves of shock or direct compression of a viscus against a bony prominence. If a large segment of the abdomen or abdominothoracic wall is compressed it may burst or split organs like liver and spleen. It should be remembered that a similar force, particularly if the breath is held and the diaphragm is tense, may split the diaphragm. The structures e.g., the bladder, urethra etc. which are attached to the bone by fascial bands may be torn if such bones are fractured. In case of penetrating wounds, the length of the weapon and the velocity with which it was struck are important. High velocity injuries produced by gunshot or fragments from exploding mines and shells penetrate deeply and may damage extensively anything in or around their paths.

Seat-belt injuries, though not common in India, yet often seen in other countries where wearing a seat-belt is a must at the time of driving a car. The harness may impinge heavily on the points of contact with the trunk and the viscera may continue to move when the abdominal wall has suddenly been decelerated. The combination of these two factors may result in contusion of the abdominal contents, detachment of the gut from its mesentery and less commonly rupture of solid viscera.

Time interval is important. Similarly exact spot where the blow was struck is also important. It must be enquired into whether the patient has vomited following injury. If he has, what was the content? Did it contain blood? In suspected injury to the kidney and pelvic bones enquire whether the patient has passed urine or not. If the patient has passed blood mixed with urine, chance of injury to the kidney should be kept in mind. If the patient shows intense desire to pass water but no urine comes out, instead a few drops of blood comes out, extraperitoneal rupture of the bladder or rupture of the membraneous urethra is the most probable diagnosis. If the patient has not passed water and has no intention to do so, possibility of intra-peritoneal rupture of bladder should be kept in mind.

PHYSICAL EXAMINATION

GENERAL SURVEY.— The patient is quiet in peritonitis but restless in intraperitoneal haemorrhage. Note the pulse, respiration and temperature. Signs of hypovolaemia out of proportion of external injury, if blood in the chest can be excluded, is an almost cardinal indication for opening the abdomen. Note the appearance. The patient becomes pale in internal haemorrhage. Tachycardia and tachypnoea are noticed in internal haemorrhage. Subnormal temperature and low blood pressure are features of shock.

LOCAL EXAMINATION.—

INSPECTION.— 1. **Skin over the abdomen.**— This is carefully inspected. Particularly in

unconscious patient this is the only sign of site of injury. If the patient is conscious and indicates the site of pain with one finger — *'Pointing sign'*, it becomes rather easier to come to a diagnosis. Bruise, laceration or perforating wound is the external sign of injury which one may locate on careful inspection and injury to internal organ may be at the depth of this external wound. There may be 'pattern' bruising (an imprint of clothing or seat-belt) on the abdominal skin that indicates crushing force which may have ruptured the bowel against the vertebral column — known as 'London's sign'.

2. **Respiratory movements.**— These should be carefully observed. There will be absence of abdominal movements in respiration due to peritonitis from perforation or due to internal haemorrhage.

3. **Contour.**— One should carefully look whether there is generalized distension of the abdomen (*meteorism*) or localized distension of the abdomen. Generalized distension of the abdomen occurs in internal haemorrhage or in late case of peritonitis. Localized distension may be due to localized internal haemorrhage or localized peritonitis due to adhesion of the neighbouring structures and 'policeman-like' action of the greater omentum.

4. **Umbilicus** may be bulged due to distension of the abdomen caused by internal haemorrhage, late cases of peritonitis, intraperitoneal rupture of the urinary bladder and paralytic ileus.

PALPATION.— 1. **Tenderness** and **Rebound tenderness.**— Localized tenderness is felt on the injured organ. If it be hollow viscus peritonitis will ensue. When adhesion of the surrounding viscera and greater omentum succeed in keeping the peritonitis localized, there will be *localized tenderness*. When peritonitis becomes generalized, there will be *generalized tenderness*. Similarly if the viscus is a solid one injury will cause internal bleeding. When the internal bleeding is localized there will be localized tenderness and when the internal bleeding is generalized, there will be generalized tenderness.

Rebound tenderness can only be elicited when the parietal peritoneum is inflamed or irritated due to internal haemorrhage. Clinician's hand is gently placed on the abdomen and gradually pressure is applied with that hand. Now suddenly the hand is taken off the abdomen and the patient winces in pain. This occurs due to the fact that the irritated parietal peritoneum suddenly moves up along with the abdominal musculature on withdrawal of the examiner's hand.

2. **Muscle guarding and rigidity.**— Muscle guarding is an excellent sign of irritation of the parietal peritoneum due to peritonitis, presence of internal bleeding or presence of contents of hollow viscus in the peritoneal cavity. The abdominal muscles in the vicinity of the irritant parietal peritoneum go into involuntary spasm, leading to *muscle guard*. Generalized muscle guard occurs when there is generalized peritonitis or when internal bleeding has spread all over the peritoneal cavity.

Voluntary muscular rigidity means rigidity of the abdominal musculature brought about by the patient himself due to fear of being hurt during examination and also indicates abdominal injury underneath but no parietal peritonitis.

3. **Swelling.**— Carefully palpate the whole abdomen gently to find out any lump or swelling. Such swelling may be present due to subcapsular haematoma of the spleen or liver, or distended bladder in rupture of posterior urethra. In case of injury to the kidney there may be fullness of the loin. There may be bruise with haematoma affecting lumbar region which should arouse suspicion of renal injury. Similarly bruising with haematoma affecting lower ribs should arouse suspicion of liver or splenic injury according to the side of injury. In case of rupture of anterior urethra there will be perineal swelling or swelling due to extravasation of urine.

4. **Fluid thrill** will be present when there is free fluid in the peritoneal cavity.

PERCUSSION.— 1. **Obliteration of liver dullness** indicates perforation of a hollow viscus.

2. **Shifting dullness** test becomes positive when there is free fluid inside the peritoneal cavity. This may occur from internal haemorrhage without localization, in late case of generalized peritonitis, ascites etc.

3. **Percuss the suprapubic region** to know if the urinary bladder is distended or not.

AUSCULTATION — of the abdomen is very important as absence of bowel sound means peritonitis from injury to hollow viscus, internal haemorrhage and retroperitoneal haemorrhage. Normal bowel sound almost excludes any serious injury to the abdominal viscera. But this examination should be repeated as it takes sometimes for disappearance of bowel sound after injury to the viscera. Auscultation of the chest may indicate presence of bowel sound in case of rupture of the diaphragm.

GENERAL EXAMINATION.— Respiratory, Cardiovascular, Nervous, Muscular system and Bones should be examined properly to exclude any injury there.

The spine and pelvis (compression test) must be examined properly to exclude any injury here. Abdominal injury is often associated with these injuries. Patients often complain of abdominal pain in case of injury to the intercostal nerves (T7 to T12).

Head, face and neck should be thoroughly examined.

Rectal and vaginal examinations should always be performed. Fluid in the rectouterine or rectovesical pouch indicates free fluid in the peritoneal cavity, intraperitoneal rupture of urinary bladder and intraperitoneal haemorrhage. This examination also reveals pelvic visceral injury.

Genital examination.— The external urethral meatus is examined and blood drop there indicates injury to the anterior urethra. Perineum should also be examined.

Repeated examinations.— It cannot be emphasised too strongly that repeated examinations are highly important to come to a diagnosis in these cases. In many cases you will find that no definite clue can be received in the first examination, but characteristic signs appear later to clinch the diagnosis.

SPECIAL INVESTIGATIONS

1. **Blood** is examined for Hb, PCV, serum amylase level, grouping and cross-matching.
2. **Urine** for routine examination and haematuria (microscopic or macroscopic).
3. **X-ray chest** to exclude thoracic injury and presence of abdominal viscus in case of rupture of diaphragm.
4. **Straight X-ray of the abdomen** particularly in sitting position may reveal gas under the diaphragm — a definite sign of rupture of a hollow viscus. Along this one can also assess injury to the chest, lumbar spine and the pelvis. Loss of psoas shadow may be helpful in the diagnosis of retroperitoneal effusion of blood. Even in case of intraperitoneal haemorrhage one can find a bigger blurr gap between the air-fluid intestinal loops.
5. **Contrast radiography.**— (a) ANGIOGRAPHY is a more vigorous undertaking. Individual circulations are outlined by selective catheterization in case of hepatic, splenic, renal and superior mesenteric arteries. The signs of bleeding are stretching of vessels around an area of swelling and escape of contrast medium into the haematoma space. (b) IVU in renal injury. (c) GASTROGRAFIN test for stomach or duodenum injury.
6. **Endoscopy.**— (a) Gastroduodenoscopy may be performed in case of suspected injury to the stomach or duodenum.

(b) Proctoscopy, sigmoidoscopy and colonoscopy should be performed in case of suspected injury to the anal canal, rectum and colon respectively.

(c) Cystoscopy is of high value in diagnosis of urinary bladder injury.

7. **Scanning** may be applicable in case of liver, spleen and kidney injuries. This investigation is definitely helpful in both positive and negative results. Particularly in delayed rupture of the spleen, the diagnosis is established much before and operation can be undertaken earlier which would otherwise have been postponed until actual rupture has taken place.

8. **Diagnostic aspiration of peritoneal fluid** (Peritoneocentesis).— A four-quadrant peritoneal tap with No. 19 gauge needle is said to be a reliable test. First of all this test should only be ventured by those who are very much experienced in doing this test and secondly a negative result does not exclude intra-abdominal injury. Fluid should be sent for physical, chemical, microscopic and bacteriological examinations.

9. **Peritoneal lavage.**— It is indicated when the previous test has failed to produce any information. In this technique 250 ml saline solution is introduced in the peritoneal cavity. After a few minutes this fluid is aspirated out and examined thoroughly to come to a diagnosis.

DIFFERENTIAL DIAGNOSIS

Abdominal injuries can be broadly classified into two groups — 1. Closed (blunt or crush) injury and 2. Open (penetrating or stab) injury.

1. CLOSED INJURY is caused by compression force such as fall from a height, blow by fist or by blunt instruments e.g. 'lathi'. Crush injuries may occur in run-over accidents or fall of heavy objects on the abdomen. Seat-belt injury is also included in this group in which during driving a car sudden break will cause the trunk and viscera to move forward with the abdominal wall and become decelerated against the seat-belt and compressed against the spinal column behind. This causes even rupture of solid viscera and/or hollow viscera (e.g. small and large intestine). There may be even detachment of the gut from the mesentery and contusion of the abdominal contents.

2. OPEN INJURY is usually caused by a sharp cutting instrument e.g. knife or razor or by penetrating injury e.g. bullet or missile. In this type of injury the peritoneal cavity is exposed outside and peritonitis is almost inevitable. The intra-abdominal organ which may be injured by such injury depends on the site of this penetrating wound. As for example stab injury to the right upper quadrant of the abdomen may injure the liver.

The main concern of abdominal injury is injury to the viscera inside the abdomen. This often causes internal haemorrhage and/or peritonitis from injury to the hollow viscus. Internal haemorrhage produces certain general signs which are common for injury to any viscus inside the abdomen. But the local signs depend on injury to the concerned viscus.

In case of internal haemorrhage, increasing pallor, restlessness, small thready pulse, deep and sighing respiration (air-hunger), subnormal temperature and collapse are the **general signs.** The **local signs** are discussed below.

Liver.— In case of injury to the lower part of the chest on the right side one may suspect of ruptured liver. Liver injury may occur as a result of a penetrating wound by stabbing or bullet injury. Right lobe is more commonly injured (5 : 1) than the left lobe as it is less mobile and large. Patient complains of pain in the right upper quadrant of the abdomen. Occasionally when the central part of liver is ruptured bleeding occurs into the large radicles of the biliary tree so that liquid blood is carried along the bile passages into the duodenum and there is haematemesis. Examine for tenderness and rigidity in the right hypochondriac region. Look for increased area

of liver dullness, shifting dullness and silent abdomen. Scanning with radioactive isotopes like colloidal gold or ^{99}Technetium may detect injury to the liver. Straight X-ray may show increased haziness around the liver region and the diaphragm becomes immobile. Fracture of lower ribs or transverse processes of first two lumbar vertebrae may become evident. Selective angiography may be diagnostic.

Spleen.— Injury to spleen is usually caused by closed (blunt) left upper abdominal injury and only occasionally it may be caused by penetrating injury to the left lower costal region. This is more common in tropical countries where spleen is diseased by malaria. Rupture of spleen manifests itself in one of the three following types — 1. The patient succumbs rapidly; 2. There are immediate signs of rupture (commonest group); 3. Delayed type.

1. *The patient succumbs rapidly.*— This occurs due to tearing of the splenic vessels and complete avulsion of the spleen from its pedicle. This leads to catastrophic internal haemorrhage and becomes fatal within a few minutes.

2. *Immediate signs of rupture.*— This is the commonest group seen in surgical practice. There are signs of initial shock when it may not be possible to state precisely which organ has been damaged. Gradually this initial shock is recovered and the signs of intra-abdominal bleeding caused by ruptured spleen will become evident. The general signs have already been discussed in the beginning of 'Differential Diagnosis'. After moderate intra-abdominal haemorrhage, adequate clotting occurs to control the haemorrhage temporarily. Thus when the patient is first seen the general signs may not be that alarming, but the local signs become more important to come to a diagnosis.

Local Signs.— (a) There are tenderness and muscle guard over the left upper abdomen. (b) Abdominal distension (meteorism) gradually appears about 3 to 4 hours after the accident. It is due to paralytic ileus. (c) *Kehr's sign.*— Pain is referred to the left shoulder due to irritation of the left half of the diaphragm by splenic blood. There may be hyperaesthesia in the area of left shoulder. This sign may be demonstrated by elevating the foot of the bed for 15 minutes, by which time blood will accumulate below the left cupula of the diaphragm. (d) Presence of shifting dullness in the flanks is fairly common. *Ballance's sign.*— Persistent dullness on the left side of the abdomen due to early coagulation of splenic blood. Even at this stage shifting dullness is present on the right side. (e) Rectal examination may reveal tenderness and sometimes a soft swelling due to presence of blood or clot in the rectovesical pouch. (f) *Saegesser's splenic point* is the point in the lower part of the posterior triangle of neck between the left sternomastoid and the scalenus medius muscles above the clavicle. Application of pressure on this point will give rise to exquisite pain. Among the *investigations* (g) *straight X-ray of the abdomen* is important so far as the diagnosis of rupture of spleen is concerned. A well-outlined spleen is a reliable negative sign. The positive radiological signs are : (i) Obliteration of splenic outline. (ii) Obliteration of left psoas shadow. (iii) Elevation of the left side of the diaphragm. (iv) Fracture of one or more ribs on the left side. (v) Indentation of the gastric fundal gas shadow from the left. (vi) Presence of free fluid between gas-filled intestinal coils. (vii) Downward displacement of the splenic flexure. (h) *UItrasound* examination of the spleen is the investigation of choice when there is difficulty in diagnosis. The spleen may be visualized with a surrounding haematoma which suggests rupture. (i) Four-quadrant *peritoneal aspiration* may reveal frank blood but the source is not evident by this investigation.

3. *Delayed type.*— In this type, following the accident, there is a period of comparative freedom of symptoms for a few days (15 days or more). After which the patient is often readmitted with well-marked signs of internal haemorrhage. The causes of this delayed haemorrhage are — (i) the coagulum which was sealing the rent suddenly gives way (a type

of reactionary haemorrhage). (ii) Infection may lyse the coagulum to cause such haemorrhage (a type of secondary haemorrhage). (iii) The greater omentum which performs as a policeman to shut off the rent in the spleen gives way. (iv) A subcapsular haematoma bursts later on to cause this haemorrhage. Scanning of the spleen and angiography are helpful in diagnosing subcapsular haematoma with no sign of intraperitoneal haemorrhage.

Mesentery.— Both closed and open injury can result in mesenteric laceration. An expanding haematoma which compresses the arterial arcades may threaten the viability of a segment of intestine. So after injury to the abdomen when tenderness and rigidity persist and the patient's condition gradually deteriorates inspite of a good resuscitative treatment one should immediately consider of opening the abdomen.

The duodenum.— The *intraperitoneal rupture* gives rise to the similar clinical picture as perforation of peptic ulcer. *Retroperitoneal ruptures* are more difficult to detect. Symptoms develop a few hours or even a day after the injury. Severe pain in the epigastrium, in the back, associated with intractable vomiting, is the most important symptom. Generalized appearance of sepsis and systemic upset become apparent. On examination, epigastric and flank tenderness can be elicited. The abdomen may be slightly distended and on auscultation there will be diminished peristaltic sound. A straight X-ray not infrequently shows the presence of small bubbles of air in the region of right kidney and sometimes the margin of the right psoas muscle may be outlined by gas shadow. X-ray after a thin barium suspension swallow may show the retroperitoneal leak.

Small Intestine.— Rupture of small intestine may also occur from blunt injury or penetrating injury of the abdomen. In case of penetrating injury the symptoms and signs are more or less like perforation of peptic ulcer. In case of blunt injury the symptoms and signs may not appear early and this delay is due to appearance of traumatic necrosis involving the parts of the injured intestine. The fixed parts of the small intestine are more vulnerable to blunt injury particularly when the blow impinges these parts against the vertebral column. It is the first two feet of jejunum and last two feet of terminal ileum which are most vulnerable to closed traumatic rupture. Early diagnosis is highly important. The time interval between the perforation and development of peritonitis depends on the size of the rupture, whether the perforation occurs into the free peritoneal cavity and on the character of the intestinal contents. *Pointing test* is an important sign in rupture intestine. The patient is asked to point which is the most painful area or where the pain started. This often indicates the site of perforation. *London sign* indicates pattern of bruising of the skin (i.e. an imprint of clothing or a seat-belt is noted on the skin) with the type of crushing force applied to the abdomen against the vertebral column. *Local tenderness* is highly important as it often indicates the site of rupture. Rebound tenderness means peritonitis has set in due to rupture of small intestine.

Large Intestine.— Rupture of large intestine may be intraperitoneal or extraperitoneal. Rupture of ascending and descending colon may be intra- or extraperitoneal, whereas rupture of transverse and sigmoid colon is often intraperitoneal. Intraperitoneal rupture will lead to severe peritonitis as the contents of the large gut are highly infective. The condition is lethal. Radiography can be helpful mainly in that a large pneumoperitoneum suggests escape from the predominantly gas containing large bowel. Extraperitoneal injury will lead to spreading cellulitis and surgical emphysema in the loins. Gas gangrene may supervene. Very occasionally rupture of large intestine may be delayed. The colon is bruised by the trauma. Necrosis sets in slowly involving the thin colonic wall which takes sometime and suddenly the gangrenous portion perforates.

The Kidney.— Renal injuries can be classified into slight, severe and critical. Slight injuries comprise those where the parenchyma is damaged without rupture of the capsule or extension of the laceration into the renal pelvis or calyx. This also includes a contusion of the cortex of the kidney without tear of the capsule and this produces a subcapsular haematoma. This condition does not produce haematuria but slight tenderness at the renal angle can be elicited. *Severe injuries* are those where the capsule is broken, renal pelvis or calyx is distorted. This produces haematuria or a mass in the loin from a perirenal haematoma. There may be clot colic. There may be leakage of urine in the retroperitoneal tissue. Perinephric haematoma is suspected when there is flattening of the normal curvature of the loin. In many cases of renal injuries there will be generalized abdominal distension (Meteorism) which is caused by retroperitoneal haematoma pressing on the splanchnic nerves. One must continue to examine the urine for haematuria both macroscopic and microscopic. If haematuria gradually ceases, it is a good sign but the patient should be kept at rest for a few days more as such cessation of haematuria may be due to occlusion of the ureter by blood clot. A *critical injury* is such when the kidney is shattered or there is a tear in the renal artery or one of its branches. The patient rarely survives after this type of injury. *Delayed rupture* is very rare, though is occasionally seen in renal injury. A patient who after injury did not reveal any sign of kidney injury suddenly suffers from profuse haematuria usually between 3rd and 5th days of accidents. This usually occurs due to some movement which dislodges the clot into the renal pelvis. So rest in bed is extremely important even when minimum injury to kidney is suspected.

X-ray will show obliteration of the renal and psoas shadows. I.V.P. is important not only to diagnose the condition, but also to know that the other kidney is functioning alright. Scintiscan is also important to know the portion of the kidney affected.

Urinary Bladder.— This may be injured intraperitoneally or extraperitoneally. The rupture is extraperitoneal in 90% of cases. Intraperitoneal rupture can only occur when someone is drunk so that his abdominal musculature remains relaxed during the blow and the bladder is full. Symptoms of ruptured bladder are usually masked due to multiple injuries and shock. A question must be asked 'Has the patient passed urine since the accident?'

Extraperitoneal rupture.— It is usually associated with fractured pelvis. This is ascertained by 'compression test' by compressing the pelvis laterally inwards or by distraction test by distracting the pelvis. Fracture is indicated by pain. Extravasation occurs into the prevesical space (Figs.32.1 & 32.2). After a few hours there will be increasing tenderness over the lower abdomen and the pulse rate will rise. These factors in association with failure to pass urine and no evidence of bladder distension will confirm the diagnosis. This condition is often confused with rupture of membranous part of the urethra. This is differentiated by rectal examination in which the prostate may not be palpable as it is displaced upwards in rupture of membranous part of urethra (Vermooten's sign) and some amount of blood will definitely leak from the urethral meatus in the latter condition.

Intraperitoneal rupture.— In this condition the physical findings are those of peritonitis. Patient complains of agonising pain and is often accompanied by severe shock. There will be varying degrees of abdominal rigidity and a few hours later abdomen becomes obviously distended. Though the patient has not passed urine he does not show any intention whatsoever to do so. There is no dullness just above the pubis as the bladder is not distended. But tenderness will be present in the hypogastrium. Shifting dullness is usually present. Rectal examination reveals a bulged rectovesical pouch.

To confirm the diagnosis, a straight X-ray in the erect position will show ground glass appearance in the lower abdomen due to presence of urine. Descending cystography will

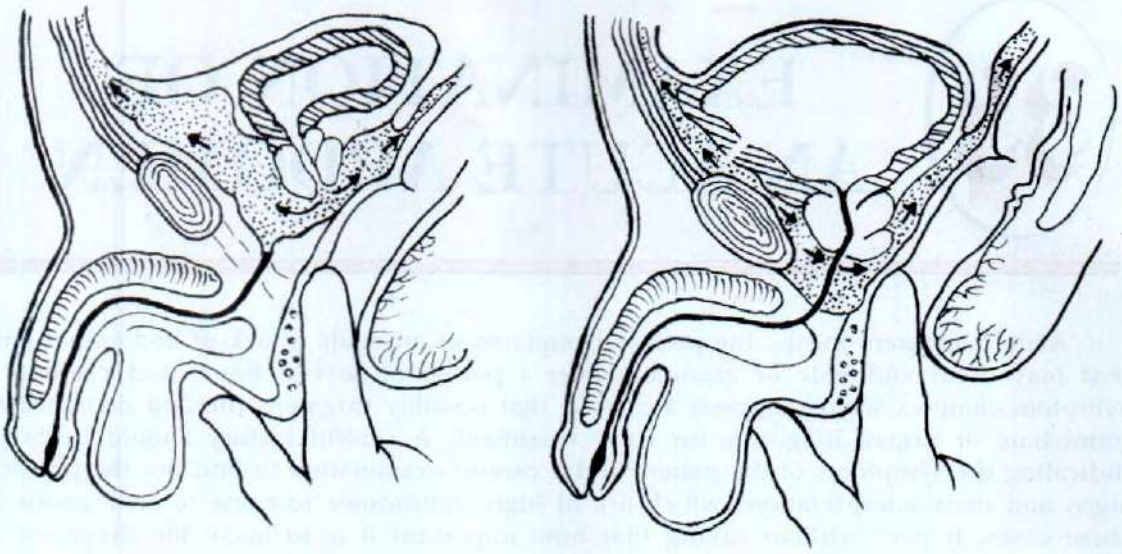

Figs.32.1 & 32.2.— Show deep extravasation of urine by dotted areas. *In Fig. 1* deep extravasation is due to rupture of membranous part of the urethra which usually tears the puboprostatic ligaments and thus the prostate is displaced posterosuperiorly and has gone beyond the reach of the finger in rectal examination. *In Fig. 2* deep extravasation of urine is due to extraperitoneal rupture or perforation of the bladder, in which the prostate is in its normal position and can be well felt by rectal examination.

confirm the diagnosis. In case of intraperitoneal rupture retrograde cystography is very helpful and may show the site of rupture. But retrograde cystography may be performed in extraperitoneal rupture when a diagnosis of rupture of urethra has definitely been ruled out. But the last-mentioned investigation does provide a serious risk of introducing infection, hence better be avoided.

Chapter

33 EXAMINATION OF AN ACUTE ABDOMEN

'Acute abdomen' means the patient complains of an acute attack of abdominal pain that may occur suddenly or gradually over a period of several hours and presents a symptom complex which suggests a disease that possibly threatens life and demands an immediate or urgent diagnosis for early treatment. A careful history should be taken indicating the symptoms of the patient and a careful examination to find out the physical signs and their interpretations which are of high significance to come to a diagnosis in these cases. It goes without saying that how important it is to make the diagnosis as early as possible in these conditions. Delay will definitely worsen the condition of the patient and may lead to fatal outcome.

HISTORY.—

(1) **Age.**— A few acute abdominal conditions are peculiarly seen at a definite age group. In NEW BORNS, intestinal obstructions due to intestinal atresia and stenosis, meconium ileus, meconium peritonitis, imperforate anus and annular pancreas are commonly seen. In INFANTS, midgut volvulus, intussusception and Meckel's diverticulitis are common. In CHILDREN, appendicitis, non-specific mesenteric lymphadenitis, primary pneumococcal or streptococcal peritonitis and round worm intestinal obstruction are commonly come across. In YOUNG ADULTS appendicitis and Meckel's diverticulitis are common. In ADULTS perforation of peptic ulcer, acute cholecystitis and acute pancreatitis are more common. In ELDERLY sigmoid volvulus, intestinal obstruction from malignant growth, diverticulitis and mesenteric occlusive disease are commonly seen.

(2) **Sex.**— Ruptured ectopic gestation, twisted ovarian cyst, acute salpingitis are obviously the diseases of women. But a few acute abdominal conditions are peculiarly more often seen in females than males. These are acute cholecystitis, acute appendicitis, primary peritonitis etc. Whereas perforation of peptic ulcer, pancreatitis, volvulus, intussusception etc. are more common in men.

(3) **Occupation.**— Painters may have recurrent abdominal colic due to lead poisoning, similarly workers in arsenic industries may suffer from similar disease.

(4) **Residence.**— Peptic perforation is more common in northern India and in southern India due to their habit of taking very spicy food. Acute cholecystitis is more common in Eastern India and Southern India. Amoebic typhlitis is only seen in tropical countries. Pancreatitis is more common in Western countries due to their habit of consuming alcohol. Appendicitis is also more common in Western countries may be due to their habit of taking low residue diet.

(5) **Social status.**— Appendicitis is more common in high income group probably they tend to take more protein as the main dish and ignore vegetables. Peptic

perforation is more common in low income group as they tend to ignore peptic ulcer disease at the early stage.

CHIEF COMPLAINTS.—

1. **Pain.—**

(a) *Time of Onset.—* The pain of acute appendicitis starts in the early morning, whereas sudden pain due to perforation of a peptic ulcer usually takes place in the afternoon after the lunch break but the patient is often brought to the hospital at night.

(b) *Mode of Onset.—* This is sudden in perforation, colic, torsion, volvulus etc. In acute intestinal obstruction the pain may not be severe at the onset but gradually increases in intensity. In acute appendicitis the pain becomes boring in the beginning and suddenly becomes acute in case of obstructive appendicitis which often wakes up the patient in the early morning. 'Acute abdomen' is sometimes precipitated by administration of purgatives (e.g. acute appendicitis), by straining (e.g. perforation) or by jolting (ureteric colic).

(c) *How long is the history of present complaint of pain?* Similar type of pain with varying intensity appearing on and off for the last few years is the feature of appendicitis, cholecystitis, etc. In peptic ulcer a periodicity is noted before perforation.

(d) *Site of pain.—* It usually coincides with the position of the affected organ. The patient is asked to indicate the site of pain with tip of one finger (Pointing test). If the pain is diffuse the patient will obviously use his whole hand instead of one finger to locate its site. If the pain is at the flank — renal origin is considered. When it is below the right costal margin — liver or gallbladder disease is suspected. If it is in the epigastric region, peptic ulcer perforation, acute pancreatitis, etc. are considered.



Fig.33.1.— The patient is always asked to show the site of pain with one finger. This figure shows the typical site of pain in a case of peptic ulcer.

(e) *Shifting of pain.—* This is characteristically seen in acute appendicitis. The pain is initially felt around the umbilicus, but later on shifts to the right iliac fossa with the onset of parietal peritonitis.

(f) *Radiation of pain.—* In spreading peritonitis the pain is first complained of at the region of the affected organ but it soon spreads all over the abdomen. In case of peptic perforation the pain is at first felt at the right hypochondriac region, but soon it is radiated towards the right iliac fossa as the gastric contents gravitate down the right paracolic gutter. At this time this condition mimics acute appendicitis. When the patient complains of a radiating pain towards the left iliac fossa while he is suffering from acute appendicitis, the condition is one of spreading peritonitis.

(g) *Referred pain.—* The pain is said to be referred when it is felt at some other regions having the same segmental innervation as the site of the lesion. In lesions of the stomach, duodenum and jejunum (T.5 to 8) the pain is felt in the epigastrium; in affections

of the ileum and appendix (T.9 & 10) around the umbilicus, whereas in case of colon (T.11 & 12, L1 & 2) in the hypogastrium. The diaphragm is supplied by the phrenic nerve (C.3, 4 & 5 of which the main supply comes from the fourth). The cutaneous nerves from the same segments are concerned in supplying the skin over the shoulder as also the upper part of the front of the chest through the supraclavicular nerves (C.3 & 4). Any irritation on the undersurface of the diaphragm either by gastric contents or blood or bile (after operation on the biliary tract) or inflammatory exudate may give rise to referred pain to the corresponding shoulder. In suspected cases the foot-end of the bed may be raised by about 18 inches to allow the exudates to gravitate down towards the undersurface of the diaphragm which will obviously initiate pain on the corresponding shoulder. In renal colic, pain is referred from the loin to the groin, testis and inner side of the thigh, i.e. the distribution of the genito-femoral nerve (L.1 & 2). The same segments supply the ureter also. In biliary colic the pain radiates from the right hypochondrium to inferior angle of the right scapula since the gallbladder is supplied by the 7th to 9th thoracic segments. In passing, it must be emphasised that the segmental nerve supply as has been referred to in this section is the sympathetic supply of the viscus. Of course the same viscus also receives the parasympathetic supply mostly from the vagus (the sole exception being the hindgut and the bladder which receive the sacral sympathetic supply).

Similarly irritation of the parietal pleura as may occur in pleurisy, haemothorax or pneumothorax may initiate referred pain to the abdominal wall as may mimic acute abdominal conditions.

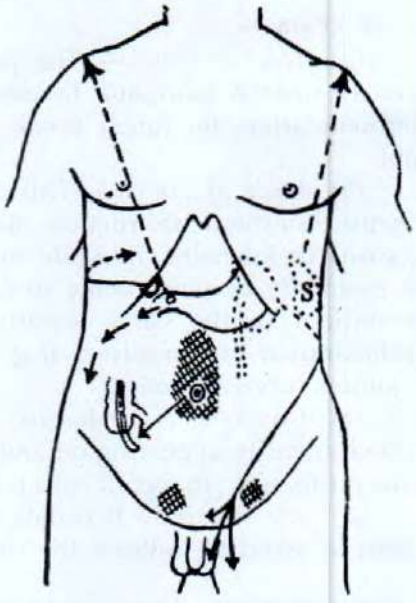

Fig.33.2.— A diagrammatic representation of various types of pain seen in acute abdomen. In perforation of peptic ulcer pain is frequently referred to the right shoulder and migrates along the right paracolic gutter towards the right iliac fossa. Pain originating in the gallbladder may radiate to the back just below the inferior angle of the scapula and even to the right shoulder. Splenic (S) pain is referred to the left shoulder (Kehr's sign). In appendicitis the pain occurs primarily at the umbilical or epigastric region and shifts subsequently to the right iliac fossa. Renal colic is referred to from the loin to the groin, testis and inner side of the thigh. Bilateral pain and tenderness over the hypogastrium (shown by criss-cross) characterize acute salpingitis.

(h) *Character of pain.*— (i) ***Colicky pain.***— It is a sharp intermittent griping pain which comes on suddenly and disappears suddenly. It indicates obstruction to a hollow organ — either bowel obstruction (intestinal colic) or obstruction of the common bile duct with a stone (biliary colic) or obstruction of the renal pelvis or ureter with a stone (renal or ureteric colic). (ii) ***Constant burning pain*** is a feature of peritonitis and often seen in perforated peptic ulcer. (iii) ***Severe agonising pain*** is very much characteristic of acute pancreatitis or of torsion. (iv) ***Throbbing pain*** is suggestive of inflammation, e.g. hepatitis or cholecystitis.

Change in character of the pain is sometimes noticed. Colicky pain of acute intestinal obstruction may change into constant burning type which indicates strangulation. Diminution of pain is not always a happy symptom. In acute appendicitis it may indicate perforation of an obstructive gangrenous appendix. In 2nd stage (stage of irritation) of peptic perforation, pain diminishes in intensity although the disease is continuing. This is due to the fact that the peritoneal exudate dilutes the irritant gastric content.

(i) *Effect of pressure on pain.*— In colics pressure gives relief but in inflammatory conditions it aggravates the pain.

(j) *Relation of the pain to jolting, walking, respiration and micturition.*— In amoebic hepatitis, cholecystitis and appendicitis the pain aggravates during walking and jolting. Ureteric colic sometimes gets worse by jolting. In diaphragmatic pleurisy pain is aggravated during deep inspiration and coughing. Pain during the act of micturition or 'strangury' is frequently met with in ureteric colic, pelvic appendicitis or even pelvic abscess.

(k) *What makes the pain better or worse?* In case of peritonitis, pain is slightly relieved if the patient lies still. If he rolls about the pain becomes worse. In case of pain due to diaphragmatic irritation either due to inflammatory exudate or due to blood from injury to the liver or spleen deep inspiration will aggravate the pain. In case of cholecystitis fatty foods will aggravate the pain whereas fat-free diet will give some relief. In case of peptic ulcer alkalis will make the pain better whereas alcohol, spicy food or drugs like aspirin will aggravate the pain. In case of hiatus hernia and reflux oesophagitis, stooping will make the pain worse.

(l) *How is the pain relieved?* Vomiting sometimes relieves the pain in peptic ulcer. In colics vomiting temporarily relieves the pain which reappears immediately. In acute pancreatitis the pain is relieved to a certain extent by sitting up from the recumbent position. Application of local pressure relieves colicky pain (biliary ureteric or intestinal).

2. **Vomiting.**—

(a) *Character of the act.*— The vomiting may be projectile i.e. involuntary forceful ejection of a large quantity of vomitus in high intestinal obstruction, toxic enteritis etc. In case of peptic ulcer perforation or general peritonitis the vomiting is quiet regurgitation of mouthfuls.

(b) *Vomitus.*— In intestinal obstruction at first the stomach contents, next the duodenal contents (bilious) and lastly the intestinal contents (faeculent) are voided. True faecal vomiting is not common. It is also seen in gastrocolic fistula. In case of biliary colic the vomiting is usually bilious. In case of peptic ulcer the vomitus is nothing but gastric contents. In late cases of peritonitis the vomitus becomes dark brown, faeculent being mixed with altered blood. This type of vomitus is also seen in uraemia.

(c) *Frequency and quantity.*— Vomiting is constant, frequent and profuse in acute intestinal obstruction and acute pancreatitis. In peptic ulcer vomiting is periodical. *In perforation of a peptic ulcer vomiting is not a diagnostic feature.* It may be once or twice during the first stage, it is more or less absent in the second stage and may reappear in the last stage with the characteristic vomitus of diffuse peritonitis. Similarly in acute appendicitis it may or may not be present. But nausea is more often complained of. Both nausea and vomiting are the characteristic complaints in pre- or post-ileal appendicitis.

(d) *Its relationship with pain.*— Pain precedes vomiting in acute appendicitis, acute pancreatitis, peptic ulcer, biliary and renal colics. In high intestinal obstruction, vomiting

appears almost simultaneously with the pain. In obstruction of the lower end of the ileum vomiting may not occur in the beginning but follows after a few hours; in large bowel obstruction vomiting is absent or is a late feature. Vomiting relieves pain in case of peptic ulcer but in colics it relieves pain temporarily so that it reappears immediately.

3. **Bowel habit.**— Absolute constipation i.e. arrest of both faeces and flatus is the usual accompaniment of intestinal obstruction and peritonitis. A history of one motion in the beginning of intestinal obstruction is not unusual. In acute appendicitis history of constipation is often received. In pelvic appendicitis or pelvic abscess, irritation of the rectum may lead to 'Tenesmus', i.e. ineffectual straining at stool with passage of mucus and blood. In children features of intestinal obstruction accompanied by passage of mucus and blood per anum is suggestive of acute intussusception. In mesenteric thrombosis, blood and putrid stool may be noticed. Diarrhoea occurs in acute ulcerative colitis, regional ileitis and acute enteritis.

4. **Micturition.**— 'Strangury', i.e. painful and frequent attempts at micturition passing only a small quantity each time is often come across in case of stone impacted in the lower end of the ureter and stone in the bladder. In inflammatory conditions in the neighbourhood of the bladder and ureter, such as retrocaecal appendicitis, pelvic appendicitis and pelvic peritonitis, they may give rise to the same condition. Even retrocaecal appendicitis lying in very close proximity to the ureter, may lead to haematuria which may mislead the clinician.

Personal history.— In women the *menstrual history* is very important and should never be missed. A history of missed period is often present in rupture of ectopic gestation. If a patient presents with symptoms very much similar to acute appendicitis in the middle of her menstrual period one should suspect ruptured follicular (lutein) cyst. Smoking and alcoholic habits should always be enquired into.

Past history.— (a) In perforation of peptic ulcer previous history of ulcer pain may be elicited, even there may be history of haematemesis and melaena.

(b) In suspected cases of acute appendicitis, biliary and renal colics, history of previous attacks may be presented which the patient may consider to bear no relation with the present illness.

(c) In intestinal obstruction one may get a history of previous abdominal operation.

(d) In acute cholecystitis there may be a past history of biliary colic, high rise of temperature and jaundice.

PHYSICAL EXAMINATION

GENERAL SURVEY.—

(1) **Appearance.**— In 'acute abdomen' the patient usually presents a peculiar facial expression — *'abdominal facies'*, which helps the clinician to discriminate an abdominal from an extra-abdominal case. In terminal stage of peritonitis, the typical *'facies Hippocratica'* can be observed. An anxious look, bright eyes, pinched face and cold sweat on the surface are the features of this type of facies, which once seen will never be forgotten. The *facies of dehydration* is also typical and consists of sunken eyes, drawn cheeks and dry tongue. The peculiar lividity or *blueness (cyanosis) of the face* is a feature which is characteristic, though not often found, in acute haemorrhagic pancreatitis. Extreme pallor

and gasping respiration in a woman of child bearing age should arouse suspicion of ruptured tubal gestation.

(2) **Attitude.**— In *colic* the patient is either tossing on the bed, doubbled up or rolls in agony seeking in vain a position of comfort. In *peritonitis* the patient remains quiet because movements will only increase the pain. Only in the last stage of peritonitis and post-operative peritonitis the patient becomes highly excitable which is evidenced by throwing of bed clothes, tossing of the head, grumbling, ineffective movements of the hands and feet etc. nothing seems to give him comfort.

(3) **Pulse.**— In the early stage of many acute abdominal conditions e.g. acute intestinal obstruction, acute haemorrhagic pancreatitis, perforation of peptic ulcer, the pulse remain normal in rate, volume and tension. But it is said to be a good diagnostic guide in acute appendicitis. Sometimes the patient who cannot locate the abdominal pain properly, probably the pulse plays an important role, so far as the diagnosis of acute appendicitis is concerned. In internal haemorrhage pulse becomes immediately rapid. In peptic perforation the pulse may become normal in the early stage but with the spread of peritonitis the pulse begins to quicken and becomes small in volume. In acute intestinal obstruction though the pulse remains normal in the beginning but with the advent of dehydration the volume and tension fall and its rate increases with no tendency to return to normal.

(4) **Respiration.**— Barring internal haemorrhage and late cases of peritonitis, the respiration rate may seldom be high in acute abdominal conditions. If the temperature becomes high, the respiration rate will be proportionately increased. Increased rate with movements of alae nasi should direct one's attention to the thorax as the seat of the disease. Referred pain in the abdomen is quite common in lobar pneumonia, basal pleurisy etc.

(5) **Temperature.**— In infective conditions the temperature will be raised. This rise of temperature varies from condition to condition. This may be quite high in case of acute appendicitis particularly in children, in acute cholecystitis it is raised to a moderate degree, whereas in acute pancreatitis or in acute diverticulitis the temperature may not be raised that much. But it must be remembered that rise of temperature is never an early sign, it occurs late in the disease, e.g. in acute appendicitis pain comes first followed by vomiting, and fever comes last of all (Murphy's syndrome).

(6) **Tongue.**— It is supposed to be an index of the state of the digestive system. Note whether it is dry or moist, coated or not. A dry tongue indicates dehydration. A dry and brown tongue signifies toxaemia. Even in the early stage of appendicitis, it may be dry and thinly coated, as the patient might have vomited a good quantity.

(7) **Anaemia, cyanosis and jaundice.**— Obvious pallor is seen in haemorrhagic conditions e.g. ruptured ectopic gestation. Cyanosis is noticed in case of haemorrhagic acute pancreatitis. Jaundice is often noticed after biliary colic and occasionally in acute pancreatitis.

EXAMINATION OF THE ABDOMEN

INSPECTION.— The patient should lie flat on his back with legs extended. The whole abdomen from the nipples above down to the saphenous openings (thus the inguinal and femoral rings are exposed) must be exposed. Examination should be carried out in good light, preferably in day light.

1. **First inspect all the hernial orifices.**— It is a good practice to start from the bottom. This should have been the last part of inspection. But if this examination be left for the last it may be missed and actual cause of acute abdomen may thus remain in the dark.

2. **Contour of the abdomen.**— Distension of the abdomen in acute intestinal obstruction occurs gradually and may not be evident till sometime has elapsed. Distension is central in case of small bowel obstruction whereas it is peripheral in large bowel obstruction. In volvulus of the sigmoid colon and caecum distension almost immediately appears. In second stage of peptic perforation slight distension may be evident, on the contrary in biliary colic, acute cholecystitis, acute appendicitis and renal colic the contour of the abdomen remains normal.

3. **Respiratory movement.**— Sluggish or no respiratory movement of the abdominal wall indicates wide spread irritation of the peritoneum as occurs in diffuse peritonitis (perforation of peptic ulcer) or haemorrhage into the peritoneal cavity (ruptured ectopic gestation). Similarly localized limitation of respiratory movement occurs in localized irritation of the peritoneum from inflammation of underlying organs e.g. acute cholecystitis, appendicitis etc.

4. **Peristaltic movements.**— The characteristic 'laddar pattern' peristalsis may be found in small bowel obstruction. Watch for a while patiently to detect visible peristalsis.

5. **Look for a pulsating swelling.**— In the case of leaking abdominal aneurysm the patient may come with acute pain in the abdomen.

6. **Skin.**— Discolouration in the left flank (Grey Turner's sign) and bluish hue around the umbilicus (Cullen's sign) are occasionally seen in late cases of acute haemorrhagic pancreatitis with extensive destruction of the pancreas (See Fig. 33.21). Sometimes there may be redness and even blisters on the skin at the site of pain. This is an indication of hot application to the site of pain to get relief.

PALPATION.— During palpation methods should be adopted same as those mentioned in chapter 34 of 'Examination of chronic abdominal conditions'. Two points need special emphasis in this chapter. They are: (i) The volar surfaces of the fingers are employed for palpation. The forearm should be kept horizontal along the level of the abdomen so that the fingers are placed flat on the abdominal wall. They must not be held vertical to poke



Figs. 33.3. & 33.4.— During the palpation the volar surface of the fingers should be employed and moved gently as in 'pill rolling'. The forearm should be kept horizontal along the level of the abdomen. In the second figure i.e. Fig. 33.4 the fingers are held vertical to poke the abdominal wall. *This is a wrong method of palpation.*

the abdominal wall. Rough palpation will lead to voluntary contraction of the abdominal muscles of the patient and this will definitely stand in the way of obtaining right information from palpation. (ii) The clinician must keep his hands warm before palpation of the abdomen. This will gain confidence of the patient.

1. **Hyperaesthesia.**— Sometimes cutaneous hypersensitivity can be obtained due to the presence of inflamed abdominal organ underneath. This can be elicited by gently picking up a fold of skin and lifting it off the abdomen or by simply scratching the abdominal wall with finger. Presence of hyperaesthesia in *Sherren's triangle* (this is formed by lines joining the umbilicus, right anterior superior iliac spine and symphysis pubis) is regarded as a good guide in the diagnosis of gangrenous appendicitis. If this hyperaesthesia disappears during the process of illness it indicates bursting of the gangrenous appendix. An area of hyperaesthesia between the 9th and 11th ribs posteriorly on the right side is known as *Boas's sign* — is suggestive of acute cholecystitis.

2. **Tenderness** is constant over an inflamed organ. Ask the patient to point out the site of pain (Pointing test). If this proves to be the site of maximum tenderness, it is certainly the site of diseased viscus. In acute cholecystitis, tenderness is present just below the tip of the 9th costal cartilage on the lateral margin of the right rectus. In acute appendicitis, tenderness is present on the McBurney's point. This point is situated at the junction of the lateral 1/3 and medial 2/3 of the right spino-umbilical line joining the right anterior superior iliac spine and umbilicus. It is a good practice to ask the patient to show the tender area. If he is not definite about it, he may be asked to cough, when a sharp twinge of pain may be felt over the inflamed area. Note carefully the *degree* and *extent* of tenderness. These indicate severity of the disease. In doubtful cases one can percuss the abdomen. Presence of tenderness over the inflamed organ can be easily revealed by this technique.

The *bed-shaking test* (Bapat) can be applied whether early peritonitis is still on doubt. The foot-end of the bed is moved slightly and this will evoke pain at the position of inflamed organ.

Spread of tenderness, if present, should be noted. In acute appendicitis if there is tenderness also on the left iliac fossa, it indicates spreading peritonitis and demands immediate surgical intervention. Similarly in a case of peptic perforation tenderness may be elicited in the right iliac fossa

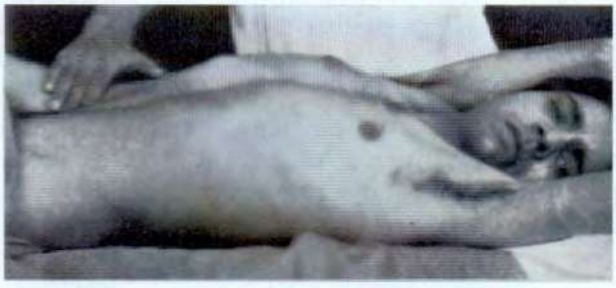



Figs. 33.5. & 33.6.— Showing how to elicit rebound tenderness. In the second figure i.e. Fig. 33.6 the hand of the clinician has been suddenly lifted and the patient screams with pain.

as the gastric contents gravitate along the right paracolic gutter. Very often a case of peptic perforation has been diagnosed as acute appendicitis due to presence of right iliac fossa tenderness.

Appendicular tenderness can be best elicited in the left lateral position when the viscera shift to the left exposing the appendix to direct palpation. The abdominal wall also becomes relaxed in this position.

Differentiation from Thoracic disease (e.g. diaphragmatic pleurisy or basal pneumonia often refer pain to the abdomen) can be made by the fact that in these conditions the skin may become hyperaesthetic but no definite tenderness can be elicited from deep palpation. Further if these cases complain of pain in the right iliac fossa and mimic appendicitis, pressure on the left iliac fossa will fail to elicit tenderness on the right iliac fossa (Rovsing's sign) which is typically present in appendicitis.

Rebound tenderness (Blumberg's sign or Release sign).— This is mainly a sign of peritonitis due to presence of an inflamed organ underneath it. The suspected area is palpated. With each expiration the hand on the abdomen is gradually pressed down as the circumstances may allow. The hand is now withdrawn suddenly and completely. As a result of this abrupt removal the abdominal musculature springs back into its original place. The patient will immediately cry out or at least wince in pain. This is due to the fact that the parietal peritoneum which has already been inflamed due to the presence of underlying inflamed organ also springs back along with the abdominal muscles. This sudden movement of the inflamed peritoneum is very much painful. In presence of abdominal guarding due to generalized peritonitis this test may not be necessary. Presence of this sign in acute intestinal obstruction suggests strangulation of the gut. A few tests of eliciting tenderness are described below :

Rovsing's sign.— If the left iliac fossa is pressed, pain is appreciated on the right iliac fossa in the case of acute appendicitis. This is due to the fact that the coils of ileum shift slightly to the right and press on the inflamed appendix. This is a very important test to differentiate acute appendicitis from similar other abdominal conditions.

Cope's Psoas test.— A retrocaecal appendix lies on the Psoas major muscle.



Fig.33.7.— Eliciting Rovsing's sign. The left iliac fossa is pressed and the pain is appreciated in the right iliac fossa in case of acute appendicitis.

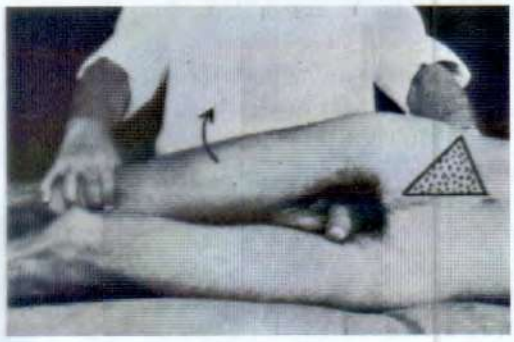

Fig.33.8.— Method of eliciting Cope's psoas test. The right thigh is being hyperextended which will initiate pain in a case of retrocaecal appendicitis. Note the position of Sherren's triangle, indicated by dots.



Fig.33.9.— Method of eliciting Cope's obturator test. The lower limb is being internally rotated which will stretch the obturator internus and will initiate pain in pelvic appendicitis.

Inflammation of this appendix will cause irritation of Psoas major muscle, which is concerned with flexion of the hip joint. When the right hip joint of the patient is hyperextended this muscle is stretched. This will initiate pain in case of retrocaecal appendicitis. The patient is turned to the left and the right thigh is hyperextended.

The obturator test.— A pelvic appendix may lie on the obturator internus muscle. When this appendix becomes inflamed internal rotation of the hip joint will stretch the obturator internus and the patient will wince in pain.

Baldwing's test.— A hand is placed over the flank of the patient. The patient is now asked to raise the right lower limb off the bed keeping the knee extended. The patient will immediately complain of pain in case of retrocaecal appendicitis. Retrocaecal appendix remains in close contact with the Psoas major muscle which becomes contracted during flexion of the hip joint.

In the passing it must be mentioned that in cases of retrocaecal and pelvic appendicitis, tenderness and rigidity may not be that prominent on McBurney's point. Here lies the importance of the above-mentioned tests which become positive in retrocaecal and pelvic appendicitis accordingly.

3. **Muscular Rigidity (Muscle Guard).**— Muscle guarding is an excellent indication of irritation of parietal peritonitis. This may be due to inflammation, presence of blood or contents of hollow organs within the peritoneal cavity. This is a part of the protective mechanism which is also seen in case of irritation of parietal pleura with restricted movement of the chest, irritation of the synovial membrane with restricted movement of the joint and irritation of the meninges in case of meningitis with rigidity of the neck.

It is of utmost importance to differentiate **voluntary** from **involuntary** muscular rigidity. While involuntary muscular rigidity or *muscle guard* indicates underlying parietal peritonitis and is one which the clinician is very much looking for, the *voluntary muscular rigidity* is



Fig.33.10.— Method of palpating the abdomen for muscle guard. The hand in contact with the abdomen feels for muscular rigidity whereas the hand over it applies pressure.

simple rigidity of the abdominal musculature brought about by the patient himself due to fear of being hurt and resentment due to exposure of the abdomen.

During palpation the hand must be placed flat on the abdomen using flexor surfaces of the fingers as the palpating media and must not try to poke the fingers deep into the abdomen. Gentle movement of the straight fingers will be able to find out presence or absence of involuntary muscle guard. This should be carried out all through out the abdomen so as to detect localized muscle guard, if present. Another method of eliciting involuntary muscle guard is to use both hands during palpation one above the other. The hand in contact with the abdominal wall remains passive and wholly utilized to feel the condition of the abdominal musculature while the hand above is used to exert a slight and steady pressure to assist the hand below for better palpation. Patient's confidence must be gained by being gentle in your behaviour. You may ask the patient to open his mouth and breathe deeply in and out. Unlike the involuntary muscle guard, the voluntary muscular rigidity will disappear during expiration and helps the clinician to palpate in a better way. The muscle guard usually corresponds to the area of tenderness.

Presence of a muscle guard over the upper half of the right rectus muscle in a patient who is seized with a sudden pain over the same region is strongly suggestive of perforation of a peptic ulcer and demands immediate surgical intervention. The Surgeon should not wait for board-like rigidity of the whole abdomen which is a late feature of this condition. In case of appendicitis the site of muscle guard varies according to the position of the appendix. In case of paracaecal appendix the rigidity will be present over the right iliac fossa, whereas in case of retrocaecal appendicitis it will be present over the loin and in the pelvic type there may not be any rigidity of the anterior abdominal wall. Muscle guard will be conspicuous by its absence in case of all colics due to absence of irritation of the parietal peritoneum. Similarly acute intestinal obstruction without strangulation will not show any rigidity of the abdomen.

Differentiation of rigidity due to thoracic disease from that due to perforated peptic ulcer is made by asking the patient to take deep breath in and out with open mouth. During expiration the rigidity will be diminished in case of thoracic diseases whereas in case of peptic perforation it is always present.

4. **Distension.**— In case of acute intestinal obstruction there will be central distension of the abdomen. The coils of intestine will be felt to harden and soften alternately. Generalized distension of the abdomen is a late feature of general peritonitis and the patient must not be allowed to reach that stage under any circumstances.

5. **Lump.**— Appendicular lump may be felt in the right iliac fossa if the case is brought late to the surgeon. Carefully palpate the lump noting its position, size, shape, consistency and mobility. Appendicular abscess, cold abscess and interstitial hernia also produce lumps and should be differentiated. In intussusception, a sausage-shaped lump may be felt in the epigastrium or left lumbar region. It is usually associated with empty right iliac fossa (Sign-de-dance).

6. **Palpation of the hernial sites** — is very important. Quite a large number of cases of acute intestinal obstruction are due to strangulated hernias and can be very well managed by timely operation.

PERCUSSION.— *Light Percussion* may be employed to elicit local tenderness.

1. **Shifting dullness.**— Presence of free fluid in the peritoneal cavity can be determined by eliciting shifting dullness. When the patient lies on his back the fluid gravitates down to



Fig.33.11.— Eliciting shifting dullness. The abdomen is percussed from the midline towards the flank. When the percussion becomes dull in the flank, the patient is turned to the opposite side. The figure shows that the flank is again percussed and the note becomes resonant.

the flanks and the intestine floats on the centre of the abdomen which will therefore be resonant and the flanks dull. Percussion should be commenced from the centre of the abdomen and is carried down to one flank. At the point where dullness starts the finger is kept in its position and the patient is asked to turn to the opposite side. That particular area is again percussed after waiting for a few minutes to allow the fluid to gravitate down. Now the note will be resonant to make the shifting dullness test positive.

There are many acute abdominal conditions of surgical importance in which free fluid can be accumulated in the peritoneal cavity. These are perforation of the peptic ulcer or typhoid ulcer, acute pancreatitis, ruptured ectopic gestation etc.

Fallacy.— Abnormal retention of enema may lead to distension of the intestine. In these cases shifting dullness test may be positive due to shifting of fluid inside the descending or ascending colon as the patient is rolled over. So the test becomes positive without the presence of free fluid inside the peritoneal cavity.

2. **Fluid thrill.**— This test has been discussed in chapter 34 of 'Examination of Chronic Abdominal Conditions'. It also indicates presence of free fluid in the abdomen in large quantity.

3. **Obliteration of liver dullness.**— Right mid-axillary line is percussed from above downwards. The percussion note will be resonant in the upper part of the mid-axillary line. At the upper border of the liver the resonant note is replaced by the dull note. If the liver dullness is replaced by a resonant note it indicates presence of *free gas* under the diaphragm as occurs in perforation of the gastro-intestinal tract. It must be remembered that absence of this sign does not exclude perforation since this sign will only be present when there is sufficient leakage of air.



Fig.33.12.— Demonstrating the presence of resonance over the area of liver dullness by percussing along the right midaxillary line about 3 inches above the costal margin. Resonance here indicates gas under the diaphragm.

Fallacy.— Considerable distension of the gut and emphysema of the lung may obliterate the area of normal liver dullness.

AUSCULTATION.— This is a *very important part of examination* in acute abdominal conditions and should never be omitted. The student should be familiar with normal peristaltic sounds noting their character and frequency by studying them in healthy abdomen. The 'silent abdomen' is a pathognomonic feature of diffuse peritonitis. Even localized absence of peristaltic sound will be evident around acute inflammation of the organ concerned. To the contrary a 'noisy abdomen' is a feature of acute intestinal obstruction. Normal intestinal sound is heard as clicks and gurgles but in intestinal obstruction distinct metallic tinkles or borborygmi can be heard. In case of peritonitis or paralytic ileus when the intestinal sounds are absent peculiar respiratory and cardiac sounds may become audible.



Fig.33.13.— Auscultation of the abdomen is of great value in differentiating peritonitis from intestinal obstruction. In peritonitis the abdomen is more or less silent — whereas in intestinal obstruction increased peristaltic sounds can be heard.

Measurement.— Rate of distension in acute intestinal obstruction or paralytic ileus or post-operative peritonitis can be assessed through repeated measurements.

Rectal examination.— No examination of an acute abdominal case is complete without the digital examination of the rectum. The right wall may be tender in pelvic type *appendicitis*, which may not show any tenderness or rigidity of the anterior abdominal wall. Tenderness is often elicited in the rectovesical pouch in *perforated peptic ulcer*. The bulging of the anterior wall of the rectum with tenderness is significant of a pelvic abscess. In *intussusception*, after the rectal examination has been finished one will find the gloved finger to be smeared with mucus and blood ('red-currant jelly') but there will be no faecal odour.

In majority of cases of acute abdomen there is ballooning of the rectum whose significance is yet to be found out.

Vaginal examination.— Purulent discharge and tenderness in both fornices are suggestive of *acute salpingitis*. In case of *ruptured ectopic gestation*, the cervix feels softer and any movement of the cervix will initiate pain.

GENERAL EXAMINATION

When the abdominal findings are not sufficient to account for the symptoms the patient is complaining of, one should think of extra-abdominal causes and proceed to examine in the following way :

1. **Examine the chest and chest wall.**— Pain is often referred to the abdomen from the thorax in such conditions as diaphragmatic pleurisy, basal pneumonia, angina pectoris, myocardial infarction etc. Pain may reflect from the upper and middle lobes of the right lung to the right hypochondrium and may wrongly lead to the diagnosis of acute cholecystitis. Similarly referred pain from the right lobe to the right iliac fossa may lead to the false diagnosis of acute appendicitis. Abdominal distension if present, adds to confusion. Typical findings of pneumonia may be lacking but presence of fever,

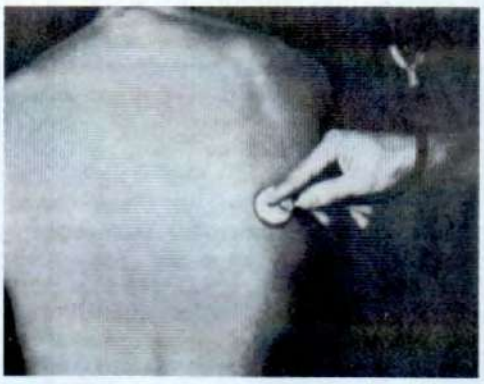

Fig.33.14.— The chest must be thoroughly examined in every case of acute abdomen. In diaphragmatic pleurisy and basal pneumonia pain is often referred to the abdomen.



Fig.33.15.— The spermatic cord and scrotum should always be examined for evidence of filariasis in a case of acute abdomen. Cases are on record when the patient complains of acute pain in the abdomen when the pathology lies in the testis e.g. pain complained in the right iliac fossa in case of torsion of the testis; abdominal pain sometimes in a child may be due to acute epididymitis.

hurried respiration with lowered pulse/respiration ratio, working of the alae nasi and absence of vesicular breathing all lead to a probable diagnosis of lobar pneumonia.

In case of children, confusion is much more due to lack of good history. *Thoracic compression test* by compressing the lower part of the chest from side to side will bring about pain in presence of thoracic diseases but not with typical acute abdomen.

When pain radiates from the back along one or more spinal nerves of the lower thoracic segments to the midline anteriorly, one should think of herpes zoster as the probable condition. This often leads to confusion with acute cholecystitis, but skin hyperaesthesia along the whole course of the affected nerve and absence of rebound tenderness may clinch the diagnosis.

2. **Examine the scrotum and spermatic cord** for evidence of filariasis. This may lead to acute abdominal pain from retro-peritoneal lymphangitis. Swelling, redness and tenderness of the groin due to filarial funiculitis supported by periodic fever should suggest this condition.

3. **Examine the spine for Pott's disease.**— Compression of the spinal cord or more often the intercostal nerves by the granulation tissue of Pott's disease may cause referred pain in the abdomen to mimic an acute abdomen.

4. **Examine the nervous system** to exclude Tabes Dorsalis. It may lead to gastric crisis consisting of pain in the abdomen and vomiting. A history of 'lightning pain' in the legs, Argyll-Robertson pupil (i.e. pupil not reacting to light but retaining the accommodation reflex) and absence of ankle and knee jerks will settle the diagnosis.



Fig.33.16.— Spine should be examined to exclude Pott's disease when the patient complains of abdominal pain.

There are a number of medical conditions which may mimic an acute abdomen. These are malaria, porphyria, diabetic crisis, Sickle-cell anaemia, haemophilia etc.

SPECIAL INVESTIGATIONS

1. **Blood.**— (a) *Leucocytosis* indicates inflammatory condition. Its role in the diagnosis of acute appendicitis is considered very high. Besides this, it is almost always present in acute cholecystitis, acute pancreatitis etc. Acute intestinal obstruction when complicated by strangulation may show presence of leucocytosis. (b) *Sugar* and *urea estimations* of the blood are important. Diabetic crisis may mimic an acute abdomen. Uraemia may present itself with persistent vomiting accompanied by increasing distension of the abdomen to make this condition confused with acute intestinal obstruction. In pancreatitis, (c) the *serum amylase* estimation will be high. While the normal value is 80 to 150 Somogyi units, 400 units is considered to suggest presence of acute pancreatitis. The highest level (1000 to 2000 units) reaches within the first 24-48 hours, after which it may come down to normal. (d) The *serum calcium* level is lowered in acute pancreatitis as calcium is fixed in the formation of soap. It may take 5 to 8 days after the attack. The fall in the serum calcium level is a good index of the severity of acute pancreatitis. A level below 7mg/100ml is considered to be dangerous. (e) The *serum bilirubin* level is raised in acute pancreatitis. (f) The *plasma fibrinogen* is also raised at the end of first week and should return to normal within the 3rd week. It is of considerable prognostic value. (g) *Serum deoxyribo-nuclease, leucine amino-peptidase* (LAD) and *lecithinase A* may be raised and considered to be a definite diagnostic index so far as acute

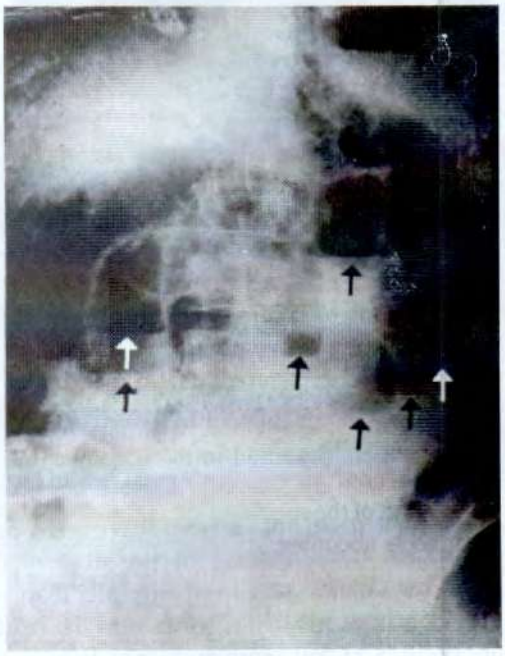

Fig.33.17.— Straight X-ray showing multiple fluid levels (shown by arrows) and gas in acute intestinal obstruction.



Fig.33.18.— Gallstone ileus — showing air in the biliary tree.

pancreatitis is concerned. (h) Increased *serum Methaemalbumin* indicates the presence of underlying haemorrhagic pancreatitis. Estimation of *C-Reactive Protein (CRP)* is important as high level in serum is considered to be diagnostic of acute appendicitis. C-Reactive Protein (CRP) is found to appear in sera of individual in response to various inflammatory conditions and tissue necrosis. This disappears when the inflammatory condition subsides. A venous blood sample is taken for estimation of CRP in plasma. CRP is estimated by extracting serum by centrifugation and determining the value by latex fixation test kit supplied by Ranbaxy India Ltd. When CRP value is more than 6 mg/L this is considered significant to be diagnostic of acute appendicitis.

2. **Blood pressure.**— This becomes low in any haemorrhagic condition. In acute pancreatitis where shock is a prominent feature of the disease, the blood pressure will be lowered.

3. **Urine.**— Routine urine examination should be a must in any case of acute abdomen. In acute appendicitis there may be presence of blood and pus cells in the urine due to approximation of inflamed appendix to the ureter. This does not indicate any disease of the urinary tract. Obviously in renal colic one may expect strick of haemorrhage in urine. *Estimation of urinary diastase* is an important laboratory test. In acute pancreatitis the diastase index may rise to 500 units or more from the normal 10 to 30 units. Glycosuria may be present in acute pancreatitis.

4. **X-ray Examination.**— Where there is facility, X-ray examination affords a distinct help in arriving at a diagnosis. In a straight X-ray multiple fluid levels and gas indicate *acute intestinal obstruction*. Straight X-ray in sitting position when shows presence of gas under the diaphragm it indicates *perforation of the gastro-intestinal tract*. In suspected gastroduodenal perforation 20 to 30 ml of air is injected into the stomach by means of Ryle's tube and a skiagram is taken in sitting position. Gas under the diaphragm confirms the diagnosis. Similarly gastrograffin may be used to mark the perforation. In *acute cholecystitis*, the bile ducts may be visualized by intravenous cholangiography with biligraffin but the gallbladder is not seen. If the gallbladder with the bile ducts is visualized it is not a case of cholecystitis. In *acute pancreatitis* gas in the duodenum and first coil of jejunum is sometimes seen. Stewart's sign i.e. gas filled hepatic and splenic flexures, no gas in the transverse colon is suggestive of this condition. Effacement of renal and psoas shadow and the film of fluid in between gas-filled ileal coils are additional evidences in favour of this condition. In case of *intussusception* screening and skiagraphy after a barium enema are of value in diagnosing the condition by showing pincer-shaped end of the barium enema. It also helps in spontaneous reduction of the intussusception. In suspected *gallstone ileus* the shadow of the stone near the termination of small intestine will clinch the diagnosis. To differentiate *renal colic* from appendicular colic, intravenous pyelography is very important. In *acute ulcerative colitis* a shadow of remarkable dilatation of the transverse colon — 'toxic megacolon' may be seen. After perforation free air within the peritoneal cavity may be noticed.

5. **Barium enema examination.**— This with air contrast may be helpful in detecting early stage of *acute ulcerative colitis*. Barium roentgenographic signs include loss of haustral markings and irregularities of the colon wall, which represent small ulceration. As the disease progresses pseudopolyps become prominent. When there are clinical signs of toxic megacolon, barium study is contraindicated. In *Crohn's disease* double-contrast barium study may reveal longitudinal and transverse mucosal ulcers or fissures

may present as 'spicules'. The irregular network of intersecting ulcers combine with submucosal oedema to result in coarse nodularity or 'cobblestone' pattern. There may be filling defects due to hyperplastic lymph follicles. The hallmark of this disease is presence of 'skip lesions' with apparently normal intervening bowel which may measure a few inches to several feet in length. Barium enema examination of *diverticulitis* shows segmental spasm with serrations (saw-toothing) of the bowel. Mucosal oedema and narrowing of the lumen may be evident. It cannot be over-emphasized that barium enema examination is absolutely contraindicated in very acute conditions. This examination however may be performed when acute condition has subsided.

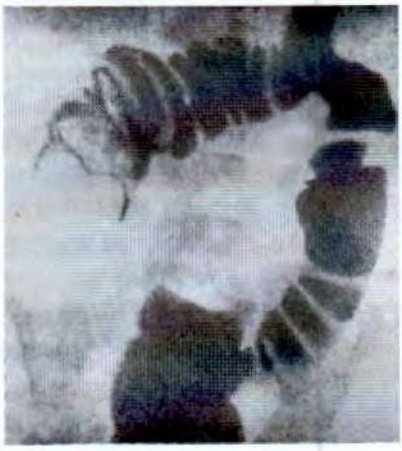

Fig.33.19.— Note the pincer-shaped ending of the barium enema — the pathognomonic feature of intussusception.

6. **Endoscopy.**— Proctosigmoidoscopy is helpful in *acute ulcerative colitis* as the rectum is involved in 90% to 95%. The mucosa is usually erythematous and granular and bleeds easily. Superficial mucosal ulcers are seen. In *Crohn's disease* (regional ileitis) endoscopy reveals cobblestone appearance with deep linear ulceration. Colonoscopy will determine the extent of the disease in ulcerative colitis and in Crohn's disease 'skip lesions' become evident. In very *acute diverticulitis* sigmoidoscopy may be painful. The mucosa is inflamed and diverticula may be seen. But narrowing of the colon, spasm, fixation and angulation are more commonly seen.

7. **Enema.**— Indiscriminate administration of enema in acute abdominal conditions must be *strongly condemned*. Nothing is more harmful than an enema given in a case of peritonitis. The only suitable subject for administration of an enema is one of the acute intestinal obstruction. In this condition the *'two enema' test* is of greater value. The first enema may show some result by evacuating the lower bowel. It is the result of the second enema given after an interval of 2 hours that leads to the diagnosis. In the presence of obstruction, the fluid of the second enema is either retained or rejected without any faecal matter. The patient is not relieved.

8. **Intravenous cholangiography** permits visualization of the entire extrahepatic biliary tree. Though this investigation was used earlier for acute cholecystitis as oral cholecystography is contraindicated, now it is losing ground in this condition.

9. **Ultrasonography.**— This non-invasive imaging technique has become the routine investigation in acute cholecystitis. It demonstrates gallbladder calculi, bile duct calculi, dilatation of the gallbladder with stone and sludge, stone in the cystic duct, dilatation of biliary tree and even a tumour in the pancreas.

Ultrasonography is a significant tool in diagnosing appendicitis. The overall specificity and sensitivity was found to be 90% and 88% respectively, giving USG a high specificity and sensitivity value in diagnosing appendicitis. It also helps in diagnosing other causes of right lower quadrant pain.

10. **Radio-isotope scanning.**— Cholescintigraphy with ^{131}I Rose Bengal or with a derivative of ^{99m}Technetium-iminodiacetic acid (technetium-IDA scan) has become more specific test than any other in acute cholecystitis. After intravenous injection

this material is excreted by the liver into the biliary ductal system. This shows the extrahepatic biliary tree including gallbladder. In acute cholecystitis the gallbladder is not visualized as presumably the gallbladder outlet or the cystic duct is obstructed. It has an accuracy of almost 100%.

11. **Computed Tomography (CT Scan).**— It provides almost similar informations as ultrasonography. It is probably useful for those in whom ultrasonography is difficult e.g. in obese patients and in those having excessive bowel gas.

12. **Exploratory laparotomy.**— On many occasions of acute abdomen the diagnosis is not established until a laparotomy is undertaken.

CAUSES OF 'ACUTE ABDOMEN'

A. INTRA-ABDOMINAL CAUSES :

1. ***Inflammation*** — e.g. acute appendicitis, acute cholecystitis, acute salpingitis, acute diverticulitis, acute regional ileitis, acute pneumococcal peritonitis, acute non-specific mesenteric lymphadenitis, amoebic liver abscess.

2. ***Perforation*** of peptic ulcer, typhoid ulcer, diverticular disease, ulcerative colitis etc.

3. ***Acute intestinal obstruction*** —

(a) *Mechanical* —

(i) In the lumen — gallstone, round worms, faecolith, etc.

(ii) In the wall — tubercular stricture, intussusception, growths etc.

(iii) Outside the wall — additional bands, volvulus, external and internal herniae etc.

(b) *Toxic* — Paralytic ileus.

(c) *Neurogenic* — Hirschprung's disease.

(d) *Vascular* — Occlusion of mesenteric vessels by embolism or thrombosis.

4. ***Haemorrhage*** e.g. rupture of ectopic gestation, ruptured Lutein cyst, spontaneous rupture of malarial spleen. Rupture or leaking aortic aneurysm, aortic dissecting aneurysm.

5. ***Tortion of pedicle*** e.g. twisted ovarian cyst, spleen etc.

6. ***Colics*** e.g. (i) biliary, (ii) ureteric, (iii) appendicular and (iv) intestinal.

B. EXTRA-ABDOMINAL CAUSES :

1. *Parietal conditions* e.g. superficial cellulitis of the abdominal wall, gas gangrene of the abdominal wall, abscess of the abdominal wall, rupture of rectus abdominis muscle and/or tearing of inferior epigastric artery.

2. *Thoracic conditions* e.g. diaphragmatic pleurisy, lobar pneumonia, spontaneous pneumothorax, pericarditis, angina pectoris, coronary thrombosis etc.

3. *Retro-peritoneal conditions* e.g. uremia, pyelitis, Dietl's crisis, retroperitoneal lymphangitis and lymphadenitis, leaking aneurysm of the aorta, dissecting aneurysm of the aorta etc.

4. *Diseases of the spine, spinal cord and intercostal nerves* e.g. Pott's disease, acute osteomyelitis of lower dorsal or lumbar vertebrae, gastric crisis in Tabes Dorsalis, herpes zoster of lower intercostal nerves and intercostal neuralgia.

5. *General Diseases* e.g. malaria, typhoid fever, porphyria, diabetic crisis, sickle cell anaemia, haemophilia, purpura, small pox, etc.

In children the following conditions are common :

(a) Acute appendicitis;
(b) Intussusception;
(c) Intestinal obstruction by round worms, congenital band or by bands including Meckel's diverticula;
(d) Acute nonspecific mesenteric lymphadenitis;
(e) Meckel's diverticulitis;
(f) Primary peritonitis.

In females the following conditions are common :

(a) Ruptured ectopic gestation;
(b) Ruptured lutein cyst;
(c) Twisted ovarian cyst;
(d) Acute salpingitis;
(e) Tubo-ovarian abscess;
(f) Torsion or degeneration of a uterine fibroid.

DIFFERENTIAL DIAGNOSIS

INFLAMMATION

Acute appendicitis.— Aetiology of this very common condition is still not clearly known. However diet (low residue diet), social status (high middle class and upper class), residence (European, American and Australian), familial susceptibility, obstruction of the lumen of the appendix with faecolith, foreign body, round worm or thread worm or a stricture and indiscriminate use of purgatives are all incriminated. Though no age is exempt, it is rare before the age of 2 years. It becomes increasingly common during childhood and adolescence and the maximum incidence is noticed between 20 and 30 years. Thereafter the incidence gradually drops. Clinically two varieties are seen — A. Non-obstructive type and B. Obstructive type. *Non-obstructive* variety progresses slowly, whereas *obstructive* type progresses very fast, and gangrene and perforation are commonly seen in this type. A careful history must be taken. If the patient gets pain around the umbilicus or in the epigastrium in the beginning and later on this pain shifts to the right iliac fossa, he is undoubtedly suffering from an acute appendicitis. The initial pain is visceral and felt on the midline irrespective of the position of the appendix, since developmentally the midgut, from which appendix develops, is a median organ. The second pain is due to irritation of parietal peritoneum lying in close proximity to the appendix, therefore it depends on the position of the appendix. The pain is dull aching in character in non-obstructive type of appendicitis, whereas this is of colicky nature in obstructive appendicitis. Pain is followed by nausea and vomiting along with anorexia depending on the degree of distension of the appendix.

Fever is almost always associated with this condition. The sequence of symptoms, viz. *pain, vomiting* and *temperature,* is known as 'Murphy's syndrome'. So far as the bowel habit is concerned constipation is the usual accompaniment, but there may be diarrhoea in case of acute pelvic appendicitis or with appendicular abscess.

Examination reveals presence of hyperaesthesia in Sherren's triangle, tenderness at McBurney's point, muscle guard and rebound tenderness over the appendix. Positive Rovsing's sign is a definite diagnostic clue and should always be looked for. Within

two or three days a tender and fixed lump develops at the site of the appendix, which is known as 'appendicular lump'. Sluggish peritoneal sound on the right iliac fossa is also evident in auscultation.

Should perforation take place, the outlook temporarily improves with disappearance of pain, but very soon the features of spreading peritonitis appears. Pain is complained of all over the abdomen, vomiting may become more marked, but more important is the pulse rate which gradually rises and the temperature becomes subnormal. Restricted movement of the abdominal wall, 'board-like' rigidity, spread of tenderness from the right iliac to the left iliac fossa and 'silent abdomen' on auscultation leave no doubt that the peritonitis is spreading. In estimating the degree of spread, the pulse rate is an important guide.

Variation of clinical features are observed according to the nature of the disease, the position of the appendix and the age of the patient.

Differentiation between catarrhal and obstructive appendicitis.— In catarrhal appendicitis the onset is gradual, the pain is dull and aching, the patient carries on her usual duties but with discomfort in the abdomen, nausea, vomiting and even anorexia. In obstructive appendicitis the onset is sudden. The patient immediately goes back to her bed with severe colicky pain in the abdomen along with vomiting and rise of temperature.

Retrocaecal appendicitis.— When the organ is entirely retroperitoneal, there is hardly any tenderness and rigidity on the anterior abdomen. There may be some tenderness and rigidity in the right flank or more posteriorly. To elicit such tenderness the patient should be rolled to her left side. If the appendix lies in close relation to the right ureter, the patient may complain of haematuria and pain radiating from the loin to the groin. This confuses the clinician and the diagnosis of ureteric stone has often been wrongly made. The history of initial pain around the umbilicus, Rovsing's sign and Psoas test will guide the clinician to the diagnosis of appendicitis.

Pelvic appendicitis.— Tenderness and rigidity may not be so prominent on the anterior abdominal wall as in normal. Moreover the picture becomes more confusing due to the history of diarrhoea and rise of temperature. Irritation of the bladder (strangury) and the rectum (passage of mucus per anum and tenesmus) are also very confusing. Even in this condition a careful history will elicit that pain started around the umbilicus. Presence of Rovsing's sign and obturator test will clinch the diagnosis. Rectal examination is often helpful as tenderness on the right side of the recto-uterine pouch in females and recto-vesical pouch in males will give definite clue to the diagnosis. A tender lump or cystic swelling in rectal examination is diagnostic of pelvic abscess.

Acute appendicitis in infancy and childhood.— The constitutional disturbances are more in children. The temperature is often high along with the pulse rate, vomiting and diarrhoea (instead of constipation) are the usual features. Elicitation of tenderness is not so easy as in case of adults. A good technique is to palpate the abdomen with the child's own hand. At the point of maximum tenderness the child will put its hand away. Appendicular lump is rarely seen due to short omentum and poor inflammatory response. For this, early perforation is the rule and the surgeon must diagnose the case very early and perform appendicectomy giving no chance to appendix to perforate by itself.

Acute appendicitis in the elderly.— These patients with laxed abdominal wall hardly show any rigidity. Moreover due to atherosclerosis of the appendicular artery chance of rapid gangrene and subsequent perforation becomes obvious. So distension of the abdomen in the second stage of peritonitis, with constipation and vomiting resemble

the picture of intestinal obstruction. The clinician, may advice enema erroneously to make the patient's condition much worse.

Acute appendicitis in pregnancy.— The enlarging uterus will cause upward displacement of the caecum and thus confuse acute appendicitis with cholecystitis. Careful history with positive Rovsing's sign should help to make the diagnosis. Sometimes concealed accidental haemorrhage or necrobiosis of uterine fibroid may lead to similar pain as in acute appendicitis. With the patient in supine position the most tender spot is marked with skin pencil. The patient is now turned to her left and is kept in this position for at least one minute. The most tender spot is again found out. If there is shifting of tenderness it indicates uterine pathology. Pyelitis and cystitis are also common during pregnancy. So one should be careful to consider these conditions in differential diagnosis.

Acute cholecystitis.— Fatty, fertile female of forty are the usual victims. A previous history of flatulent dyspepsia and belching and now with severe pain in the right hypochondriac region radiating to the inferior angle of the right scapula or to the top of the right shoulder are probable indications of a case of acute cholecystitis. Nausea, retching and vomiting, rise of temperature and an elevated pulse rate may be associated with this condition. Jaundice may be present in only 1/4 of the cases may be due to accompanying cholangitis or due to entry of the bile pigments into the circulation through the damaged gallbladder mucosa. Charcot's triad i.e. pain, jaundice and rigor (due to cholangitis and even septicaemia) is very characteristic of this condition. Tenderness and rigidity can be easily elicited on the gallbladder point. Gallbladder is hardly palpable. If so, it is due to the organ being wrapped with greater omentum. Overlying rigidity stands in the way of better palpation. Very rarely an empyema of the gallbladder may become palpable if the clinician becomes very gentle. In *special investigations* blood examination is helpful as in 85% of cases there is elevation of W.B.C. count. In half the patients there is rise in serum bilirubin and in one-third of cases serum amylase will be increased. Oral cholecystography is contraindicated. Ultrasound and radioactive scanning are helpful in diagnosing this condition.

Acute pancreatitis.— This condition is commonly seen over 30 years of age. Men slightly dominate over women. Pain which is felt over the epigastrium is excruciating and agonising in nature. It is the first in severity considering all abdominal cases. It tends to pierce to the back or to the left loin,

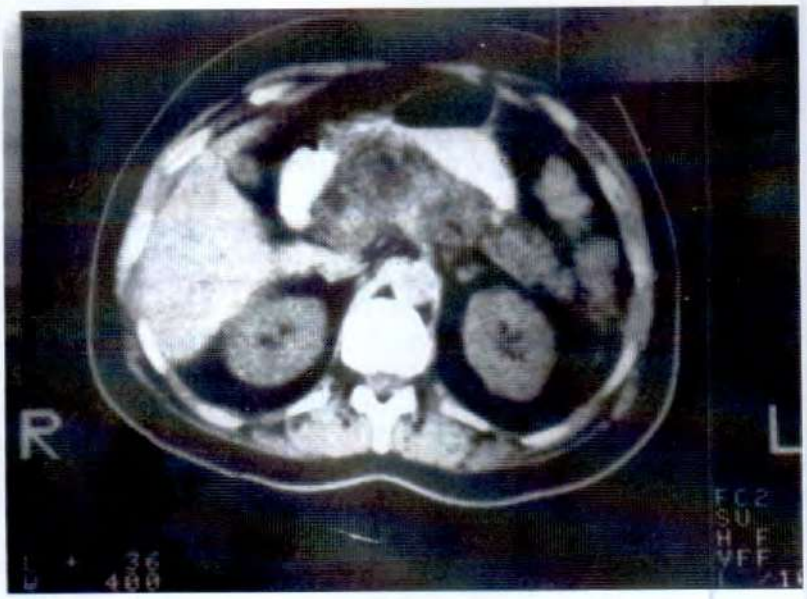

Fig.33.20.— CT Scan of the abdomen showing oedematous enlarged pancreas indicating acute pancreatitis.

which becomes more severe when the patient lies down. So the patient shows a tendency towards sitting on the bed leaning forward. The pain is *constant in nature* and not colicky. Vomiting is profuse, projectile and follows pain. Pulse rate is almost always quickened with the commencement of the disease. Shock and cyanosis are the two distinct features of this condition. Former is due to absorption of incompletely split products of protein and the latter to toxaemia and anoxia caused by diminished excursion of the diaphragm resulting from the inflamed pancreas. Temperature is at first sub-normal and does not rise over normal limit on the first day of the disease. While tenderness is very obvious just above the umbilicus, muscle guard is conspicuous by its absence. In acute pancreatitis the left costo-vertebral angle may be tender due to inflammation of the tail of the pancreas. In late cases muscular rigidity may be present to confuse this condition with peptic perforation. There may be some fullness of the epigastrium. Discolouration of the loin (Gray Turner's sign) and around the umbilicus (Cullen's sign) are late features of this disease. In *special investigations* estimation of serum amylase is the most widely used test. A serum level of more than 400 Somogyi units is suggestive whereas more than 1000 Somogyi units is almost diagnostic. Urinary amylase will also be increased in this condition. Recently elevation in the serum and urinary lipase have been given importance but subject to limitations. Paracentesis fluid is analysed and both amylase and lipase levels are raised. Straight X-ray findings have been discussed in the section of 'Special Investigations', but presence of 'sentinel loop'— a single dilated atonic loop of small bowel is a contributory evidence for diagnosis. In Ultrasonography and CT scan one may detect an oedematous pancreas. But the images are poor in the obese.

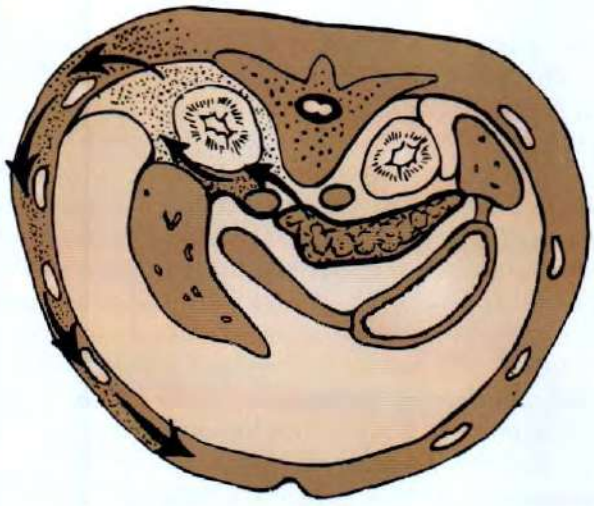

Fig.33.21.— Diagrammatic representation showing how haemorrhagic fluid from acute haemorrhagic pancreatitis tracks along the abdominal wall to cause discolouration of the loin (Gray-Turner's sign) and around the umbilicus (Cullen's sign).

Acute colonic diverticulitis.— This condition mainly affects the pelvic colon. Typically the pain is complained of in the left iliac fossa. A tender, thick pelvic colon can be palpated in the left side of the abdomen. Perforation is not very common. More common is the localized peridiverticular abscess. In this condition the pus is confined, the mesocolon is greatly thickened and the bowel becomes swollen and oedematous. Intestinal obstruction may result from thickened colon. Muscular rigidity is always present in this condition. Occasionally localized abscess may burst to the exterior (forming external fistula) or into any viscus viz. urinary bladder (forming internal fistula). Very rarely carcinoma may supervene. Sigmoidoscopy and barium X-ray are helpful in diagnosing this condition.

Acute regional ileitis.— This condition in many respects resembles acute appendicitis. Pain in the right iliac fossa is common to both these conditions. But in this condition there may be a long previous history of intestinal colic (due to intestinal obstruction, which is a feature of this condition and never found in appendicitis) and diarrhoea (it is again peculiar to this condition and never seen in appendicitis before the onset of the attack). A tender mass may be felt in the right iliac fossa and will be felt by pelvic examination. A patient when complains of pain in the right iliac fossa along with certain other complications like anal fissure, fistula or oedematous skin tag, the diagnosis becomes certain. If an appendicular lump does not resolve by medical treatment, one should think of 4 conditions of which the first is Crohn's disease, the second is ileo-caecal tuberculosis, the third is actinomycosis and the last, though rare, is carcinoma. If after appendicectomy sinus complicates, one should think of the possibility of Crohn's disease.

Acute salpingitis.— Usually the disease starts at the time of menstruation or during the first week after abortion or delivery. The pain of acute salpingitis is mainly felt on the sides of the hypogastrium or even in the iliac fossae. So to differentiate from acute appendicitis, one should carefully take the menstrual history and ask "where did the pain start?" Normally in appendicitis the pain starts around the umbilicus and then shifts to the right iliac fossa, whereas in this condition the pain remains static at the iliac fossa. The temperature usually rises to 102°F or even more. Difficulty in micturition e.g. scalding pain during micturition is a common accompaniment of this condition. Abdominal rigidity is not so pronounce as in appendicitis. Vaginal discharge is again a pathognomonic feature of this condition, it may be a recent onset or an exacerbation of a long standing discharge. Vaginal examination will reveal a somewhat enlarged uterus when this condition has occurred following abortion or puerperium. The cervix may be softer but will cause tremendous pain if it is moved. Only when the acute stage is over, unilateral or bilateral swollen tubal mass may be discovered.

Acute non-specific mesenteric lymphadenitis.— This is mainly a disease of children below six years of age. After 14 years it is better not to make this diagnosis. This condition mainly competes with acute appendicitis. The pain starts around umbilicus. The pain may be of colicky nature. Vomiting is usual and occurs in the beginning of the attack. The temperature may be raised just above normal. There is hardly any difference in pulse rate which is again a differentiating point against acute appendicitis. The patient indicates the site of pain a diffuse area above and medial to the position of appendix. The site of pain remains constant without showing any tendency to shift (cf. pain in appendicitis). On examination too much rigidity is never present. If one becomes gentle in palpation one may feel enlarged lymph nodes on deep palpation. Shifting tenderness (Klein's sign) is the pathognomonic feature of this condition. After locating the area of tenderness in the supine position, the patient is rolled to the left side and kept in this place for a few minutes. Tenderness moves to the left. This is a distinguishing feature from acute appendicitis, where tenderness is relatively fixed. Of course the students should remember of Meckel's diverticulitis which shows similar type of shifting tenderness.

Acute ulcerative colitis.— Ulcerative colitis is mainly a chronic condition characterized by relapses and remissions. Only in 5% of cases it may present as an acute condition and deserves mention in this chapter. Incessant diarrhoea containing blood, mucus and pus, high rise of temperature and a toxic state are the main features of this acute condition. When the whole or a substantial portion of the colon is involved the attack

is likely to be more severe with some systemic upset. The depth of the ulcers are also an important feature in this respect. Deep ulceration extending up to the deep muscular layer will cause toxic colitis with severe systemic manifestations. Severe abdominal distension may occur from toxic megacolon. Depletion of protein with a low serum albumin and loss of body weight also accompany this condition. Erythema nodosum, pyoderma, arthritis etc. are the complications of systemic involvement. It must be remembered that colitis in the elderly is much more dangerous than in young patients. Straight X-ray, endoscopy and rectal biopsy will clinch the diagnosis.

Subdiaphragmatic (subphrenic) abscess.— This condition usually follows some intraperitoneal lesion e.g. perforated peptic ulcer, abdominal trauma, acute appendicitis, operations on biliary tract and operations on the stomach. The patient usually runs temperature without any definite cause. Pulse rate and the rate of respiration also go up. Pain, if complained of, helps in the diagnosis. It is usually felt over the abscess in the hypochondriac region. Pain may be referred to the corresponding shoulder due to irritation of the diaphragm. On examination, careful palpation may elicit an area of tenderness over the abscess.

It must be confessed that there is hardly any definite diagnostic feature of this condition. Suspicion is the main help to the diagnosis. The popular aphorism that "signs of pus some where, signs of pus no where else, signs of pus there" is still to be remembered. Sluggish or no diaphragmatic movement in X-ray screening and elevation of the diaphragm on that side are diagnostic evidences.

Amoebic liver abscess.— It is not an uncommon condition to cause acute abdomen in tropical countries. Adult males are the usual sufferers. It is a complication of amoebic dysentery. The patient presents with acute pain in the right hypochondriac or epigastric region, which is increased by alcohol, walking, riding a vehicle and jarring. The patient often supports the upper right side of the abdomen with his hands when he expects jarring or vibration. Such pain is often associated with pyrexia, rigors and profuse sweating at night. On examination a swelling may be detected in the right hypochondriac or epigastric region which is extremely tender, moves with respiration and otherwise immobile. Aspiration reveals chocolate-coloured pus (anchovy-sauce). Radio-isotope liver scan, CT scan, sigmoidoscopy and Barium enema X-ray will reveal the diagnosis.

Complications are — Rupture of the abscess into (i) the peritoneal cavity (giving rise to acute peritonitis with board-like rigidity), (ii) the pleural cavity (empyema), (iii) into the lung (chocolate coloured pus is expectorated) or (iv) into the intestine.

PERFORATION

Peptic perforation.— The clinical picture is described in three stages.

(i) The first stage is known as *peritonism* i.e. irritation of the peritoneum. It is due to leakage of gastric juice into the peritoneal cavity (chemical peritonitis). This stage usually lasts for about six hours. Usually an adult male, who gives a previous history of peptic ulcer, is suddenly seized with acute burning pain over the epigastrium. The pain may be referred to the tip of the right shoulder due to irritation of the under surface of the diaphragm. The pain may gradually gravitate down along the paracolic gutter to the right iliac fossa. At this stage one may misunderstand the pain to be due to acute appendicitis. The patient may or may not vomit. On examination there will be little change in the pulse,

respiration and temperature. Tenderness and muscle guard are constantly present over the site of perforation i.e. upper half of the right rectus muscle. Great importance should be led on the diagnosis of this condition at this stage as chance of survival of the patient gradually declines with passage of time. Diagnosis in the first stage mainly rests on two features viz. onset of pain with a dramatic suddenness in a patient who has given a previous history of peptic ulcer and muscle guard over the upper half of the right rectus muscle. In the late phase of this stage pain may be felt on the right iliac fossa which adds confusion to this diagnosis.

(ii) The second stage is known as the *stage of reaction*. The irritant fluid becomes diluted with the peritoneal exudate. The intensity of the symptoms dwindles although the fire is still burning under the ashes. The patient feels comfortable and nothing is more deplorable than the attending doctor sharing the patient's comfort. Symptoms are no doubt relieved but the signs are there and should be looked for. Muscular rigidity continues to be present. The other two new features are obliteration of liver dullness and shifting dullness. Rectal examination may elicit tenderness in the recto-vesical or recto-uterine pouch. Straight X-ray in sitting position will show air under the diaphragm in 70% of cases.

(iii) The third or the final stage is the *stage of diffuse peritonitis* and it indicates that the patient has gone a step further towards the grave. The pinched and anxious face, sunken eyes and hollow cheeks — the so called facies hippocratica, with rising pulse rate which is low in volume and tension, persistent vomiting, 'board-like' rigidity of the abdomen, increasing distension of the abdomen all give hint to the diagnosis of this condition and imminent death.

Perforation of a typhoid ulcer.— This usually takes place in the 3rd or 4th week of the typhoid fever. Haemorrhage also occurs in this period. Sudden collapse, fast thready pulse and subnormal temperature indicate either perforation or haemorrhage. But a history of sudden pain, definite tenderness and rigidity (however slight it may be) will lead the diagnosis towards perforation. The liver dullness will be obliterated and shifting dullness test may be positive.

Perforation of ulcerative colitis.— In only 4% of cases of ulcerative colitis perforation may complicate the fulminating type of the disease. It is usually preceded by toxic megacolon. Sudden pain of the abdomen with distension and shock should immediately rouse suspicion of this condition. Faecal contamination of peritoneum is more dangerous and should be operated on immediately.

Perforation of diverticular disease of colon.— Generalized peritonitis from perforation is extremely rare. More often a localized abscess results. If general peritonitis takes place mortality rate is very high and is not less than 50%.

ACUTE INTESTINAL OBSTRUCTION

The mortality rate from acute intestinal obstruction rises with each passing hour from the onset of the disease; so early diagnosis is imperative. The three main clinical manifestations of acute intestinal obstruction are — intestinal colic, vomiting and distension. The absolute constipation which was also considered to be one of the cardinal features should be excluded as it takes no less than 24 hours to develop this symptom.

1. *Intestinal colic.*— When the obstruction lies in the jejunum or high in the ileum the colics appear in waves at intervals of 3-5 minutes. The pain lasts for about 30

seconds. This interval becomes longer in obstruction of the terminal ileum where it is about 8-10 minutes. The site of pain will give an indication as to the site of obstruction e.g. small intestinal cramps are referred to the epigastrium or umbilical region whereas colonic cramps to the lower abdomen (hypogastrium).

2. *Vomiting.*— This is a fairly constant symptom. The frequency of vomiting depends on the site of obstruction. In upper small bowel obstruction vomiting is much more frequent than obstruction in the terminal part of the small bowel. At first the vomitus is the gastric content i.e. ingested food particles and fluid, next it is the content of the duodenum, which is predominantly bile and lastly it is the content of the small intestine above the site of obstruction. Virtually it takes about 3 or 4 days in complete intestinal obstruction to vomit become faeculant. This is a grave sign and should be diagnosed long before this.

3. *Distension.*— It must be confessed that this may not be very early sign. But for an experienced clinician distension may be evident in the early stage and is considered to be a diagnostic feature.

4. *Absolute constipation.*— It must be remembered that absence of history of recent constipation should under no circumstances exclude a diagnosis of intestinal obstruction. The patient might have moved his bowel in the morning. The symptoms started in the afternoon. For constipation to arrive as a significant sign one has to wait for another 24 hours. This only makes the diagnosis late in case one includes constipation to be one of the four major signs of this condition. Again absolute constipation appears later in the process as it means failure of passage of both faeces and flatus. To add to more confusion intestinal obstruction may be accompanied by diarrhoea. Mesenteric vascular occlusion, Richter's hernia and a pelvic abscess associated with obstruction by adhesion — will produce diarrhoea instead of constipation.

5. *Dehydration.*— The higher is the obstruction more will be dehydration due to tremendous loss of water and electrolytes. To the contrary obstruction of the terminal ileum is associated with relatively small amount of loss of fluid and electrolytes as the secretions of the G.I. tract are reabsorbed. As a matter of fact dehydration appears late in obstruction of the terminal ileum but the distension becomes pronounce whereas in obstruction of the jejunum dehydration appears earlier but distension is much less.

On examination the patient looks anxious and restless. In the early stage pulse, respiration and temperature show no deviation from normal. **Inspection** rarely shows distension in the early stage, but a little fullness cannot be missed by an experienced clinician. *Distension* either central (small gut obstruction) or peripheral (large gut obstruction) or regional (volvulus of sigmoid colon or caecum) is a distinctive feature in acute intestinal obstruction. If the clinician becomes more patient and watchful he can discover *visible peristalsis* which is again diagnostic. Gentle flicking of the abdominal wall may initiate visible peristalsis. *It can't be over emphasised at this stage of inspection to inspect all the hernial sites, particularly inguinal, femoral and umbilical.* While umbilical hernia becomes obvious on inspection, inguinal and more often femoral herniae are missed if these sites are not looked for. **On palpation** muscle guard is conspicuous by its absence. If the hand is laid flat upon the abdomen the underlying coils of intestine may be felt to harden and soften alternately. During palpation one must be careful to discover a lump as may be found in intussusception, neoplasm of the small or large intestine or an intra-abdominal abscess.

Presence of muscle rigidity and rebound tenderness suggest internal strangulation.

Percussion is not much informative in the sense that it only reveals resonant note of gaseous distension of the bowel.

Auscultation is quite an important procedure, yet often missed. Presence of borborygmi which coincide with intestinal colic is very diagnostic. In a case of intestinal obstruction, "silent abdomen" suggests paralytic ileus. Localized absence of intestinal sounds means localized peritonitis or internal strangulation. **Rectal examination** is usually non-informative yet ballooning of the rectum is peculiarly noticed. Very occasionally one may detect pelvic abscess, a lump caused by intussusception or neoplasm of the small or large intestine.

Straight X-ray of the abdomen is very diagnostic. It shows gas-distended loops of the intestine and multiple fluid levels. *Gas-distended bowels* are seen earlier and for fluid levels to appear the fluid must be separated from the gas. Jejunum, ileum and colon may be seen distended with gas and will show characteristic appearances in X-ray. Jejunum is characterized by its valvulae conniventes which are placed at regular intervals giving rise to a concertina effect. Ileum is characterized by straight lines of its walls. Large intestine shows haustral folds, which leave indentations in the walls. While gas shadows can be seen even in the supine position, *fluid levels* are seen only in erect posture. The number of fluid levels is proportionate to the degree of obstruction and to its site. The number of fluid level is more, the nearer the obstruction is to the ileo-caecal valve. In paralytic ileus fluid level becomes more conspicuous and more numerous. In obstruction of the large intestine a gas-filled caecum becomes obvious in X-ray. In this context one should remember two fallacies — (i) in infants under the age of 2 years a few fluid levels in the small intestine are not abnormal. (ii) Two inconstant fluid levels may be seen in the duodenal cap and at the terminal ileum.

Having diagnosed that the case is one of acute intestinal obstruction, the clinician should proceed to detect (a) the site, (b) the nature and (c) the cause of the obstruction.

(a) *THE SITE OF OBSTRUCTION.*— In high intestinal obstruction vomiting is early and profuse. The vomitus consists of gastric fluid in the beginning and bile later on. Faeculent vomiting is never seen. The patient becomes dehydrated very soon. The urine is scanty. Though distension is not a marked feature yet fullness of the epigastrium is often noticed. In this category acute dilatation of the stomach and pyloric stenosis may be included. In low small intestinal obstruction the onset is sudden. Pain is situated over the umbilical region. The vomiting is present but it is neither early and nor profuse. In early stage the vomitus consists of gastric content later on bile and becomes faeculent in the last stage. Distension is marked and is central, visible peristalsis in the form of "ladder pattern", is often noticed. In large gut obstruction the patient is usually elderly the onset is gradual (so it is often said to be chronic). Pain is not very prominent. If present, it is complained of in the hypogastrium. Vomiting is a very late feature and it may not be present altogether. Distension is more marked on the flanks. Careful palpation of the right iliac fossa may reveal the caecum to be distended and may harden under the examining finger. Rectal examination may reveal an annular growth.

(b) *NATURE OF OBSTRUCTION.*— Intestinal obstruction may be simple or strangulated and dynamic or paralytic. In *simple obstruction* there will be intestinal colic. Pulse, respiration, temperature and blood pressure remain unaffected. On palpation, muscle rigidity and rebound tenderness are conspicuous by their absence. *In strangulation* however, there is no complete remission of pain between colics. So

colicky pain of simple obstruction is replaced by a continuous pain. Pulse becomes rapid, temperature may be elevated, there may be tachypnoea and blood pressure falls from the beginning. Presence of muscle rigidity and rebound tenderness immediately make the diagnosis. Two hours gastric suction if fail to relieve pain indicates internal strangulation. Though external strangulation is easier to diagnose by tense, tender and irreducible swelling without any impulse on coughing, yet internal strangulation is not so easy to diagnose and must be looked for.

Paralytic ileus — may occur in the early post-operative period after an abdominal operation or as a complication of diffuse peritonitis. It is differentiated from dynamic intestinal obstruction by the following points : (i) history of abdominal operation or features of peritonitis are present; (ii) gradual distension of the abdomen without visible peristalsis; (iii) absence of colicky pain; (iv) 'silent abdomen' in auscultation.

(c) *CAUSE OF OBSTRUCTION.*— In determining the cause of obstruction, age of the patient should be taken into consideration first. In the new born, cause of obstruction is congenital malformation e.g. congenital atresia of oesophagus, congenital pyloric stenosis, meconium ileus, congenital atresia of the duodenum or ileum, Hirschsprung's disease, etc. In *infancy*, intussusception and obstruction due to warms. In *adolescence*, besides intussusception band or adhesion resulting from Meckel's diverticulum or local peritonitis due to appendicitis, tubercular peritonitis, tabes mesenterica, etc. In *adults*, obstruction by a band, volvulus or growth should be considered whereas in the old, carcinoma of the colon is the usual cause. A fatty woman of 40, with previous history of cholelithiasis, if presents with intestinal obstruction possibility of gallstone ileus should be considered. A strangulated hernia may occur at any age.

Acute intussusception.— Usually the patient is a lusty male baby between six to twelve months of age. The onset is usually sudden. The child screams in abdominal pain and draws his legs up. The attacks usually last for a few minutes and come back within fifteen minutes. In between the attacks the patient looks somewhat drawn. Facial pallor is an important sign which always associates with each attack. Vomiting is more often late to come — usually takes about 24 hours. Slight rise of temperature may be seen even during the first 24 hours. Absence of distension with severe colic in the abdomen and pallor should give the suggestion towards the diagnosis. Absolute constipation is rarely seen. In the early stage normal stools are passed frequently, later on blood and mucus are evacuated which is popularly known as "Red-currant Jelly".

On examination the abdomen is hardly distended. The main diagnostic feature is palpation of a lump which is curved, sausage shaped and in the line of the colon with its concavity towards the umbilicus. Should the lump harden under the examining fingers synchronously with the attacks of screaming, the diagnosis is established. The lump may not be felt when it is lying just under the right or the left costal margin. The examination must be gently conducted as contraction of the abdominal muscles may stand in the way of good palpation of the lump. A feeling of emptiness in the right iliac fossa is known as *signe-de-dance*. Too much stress should not be paid on this sign. When everything has been made ready for operation it is a good practice to search for the lump under general anaesthesia. On *rectal examination* bloodstained mucus will be found on the examining finger. There is absolutely no faecal odour. If intussusception has travelled far enough, its apex may be felt per rectum and will be felt like cervix uteri. In very rare instance intussusception may project through the anus. This indicates that the patient possesses a long mesentery to render the small

intestine unduly mobile. After six hours signs of dehydration will appear. After 24 hours the abdomen will start distending and vomiting becomes profuse. *X-ray is confirmatory.*— Straight X-ray of the abdomen will reveal increased gas-shadows in the small intestine and absence of caecal gas-shadow. Barium enema X-ray, in presence of ileocolic intussusception, shows the typical pincer-like ending of the barium enema. Of course in ileoilial intussusception barium enema X-ray will not be helpful if the ileo-caecal valve is competent.

Volvulus of Sigmoid Colon.— Usually middle aged or elderly males are sufferers. The onset is sudden with acute pain on the left side of the abdomen. Abdominal distension soon follows and in no other condition abdominal distension becomes so severe. Constipation is usually absolute but occasionally large quantities of flatus and faeces may be voided due to untwist of the bowel. A straight X-ray is confirmatory and it shows enormous distension of the sigmoid colon with gas.

Volvulus of the caecum.— While volvulus of the sigmoid colon mainly affects middle aged and elderly, this condition is more common in young individuals between 20 and 30 years of age. This condition only occurs when the right half of the colon is laxed and mobile. Distension mainly prevails right lower abdomen which gradually involves the whole of the abdomen and picture becomes very much similar to low small bowel obstruction. Straight X-ray will show a large gas-filled caecum and later on loops of gas-filled ileum.

Meconium ileus.— 5% to 10% of infants born with fibrocystic disease of the pancreas will have small bowel obstruction due to abnormal inspissated meconium resulting from inadequate secretions of enzymes from the pancreas and intestinal mucosa. A family history is often noticed. The infant is born with intestinal obstruction. The typical radiograph shows distended loops of small intestine. There is scarcity or absence of fluid levels in the upright film. Air comes down the small intestine into the thick meconium causing a 'soap bubble' or 'ground glass' appearance.

Volvulus of the Mid-gut (Volvulus neonatorum).— Arrested rotation of the gut is responsible for this volvulus. Floating caecum together with whole of the small intestine rotates on a narrow stalk of mesentery. The child presents the symptoms of intestinal obstruction immediately after birth. The classical features and radiological findings are similar to any small bowel obstruction. Appearance of dehydration is very fast and treatment should be commenced as quickly as possible.

Gallstone ileus.— Obese women within 40 to 50 years of age are usually the victims. Often the previous history of cholelithiasis can be obtained. The site of impact is about 2 ft. proximal to the ileo-caecal valve. This is the narrowest part of the small intestine. Symptoms are often illusive. Recurrent mild colics accompanied by vomiting is the usual presenting symptom. In majority of cases the obstruction is incomplete so there should be some result from enema. Abdominal distension is a late feature. Straight X-ray may reveal the stone to confirm the diagnosis, but even if it be not present, gas-distended loops of ileum should not be missed.

Mesenteric vascular obstruction.— This condition occurs in those who are known to be suffering from cardiac valvular diseases or atherosclerosis. Pronounced shock, colicky pain (which is quite severe), distension and frequent vomiting are the usual symptoms which may mimic acute appendicitis. Haematemesis and melaena occur in about a third of cases. On examination, localized rigidity and tenderness over the infarcted area can be elicited. The symptoms and signs just described are features of mesenteric

arterial occlusion. Mesenteric venous occlusion shows different types of clinical features. An intra-abdominal obstruction or portal hypertension may predispose this condition.

Intestinal obstruction due to worms.— Usually children below 10 years of age in tropical countries are the victims. Aggregation of Ascaris Lumbricoides obstructs the lumen of the distal small bowel. On examination the child is very much undernourished. He may give history of vomiting a worm or of taking an anthelmintic. A swelling may be palpable in the right iliac fossa which pits on pressure. If this condition is suspected the stool is examined, blood is examined for eosinophilia. Straight X-ray may reveal the worm in a gas-filled loop of intestine. The only complication of significance is *perforation peritonitis* in which the worms penetrate the intestinal wall.

Bolus obstruction.— This occurs when insufficiently masticated food obstructs the lumen of the distal small intestine (narrowest portion of the intestine is about 2 feet proximal to the ileocaecal valve). This only occurs after partial gastrectomy as normally these foods are retained in the stomach till they are partially digested. Dried fruit, coconut, unmasticated orange pulp usually cause this type of intestinal obstruction by forming bolus.

HAEMORRHAGE AND TORSION

Ruptured ectopic gestation.— Sudden onset of acute pain over the hypogastrium with tremendous shock in a woman of child-bearing age, having a history of one or two missed periods is suggestive of this condition. Pain is often severe and mainly located in the hypogastrium with radiation backwards and downwards. Gradually the pain may involve whole of the abdomen and even to the tip of the shoulder due to irritation of the under surface of the diaphragm by sanguineous fluid (when haemorrhage is considerable and the foot of the bed is raised to combat shock). *On examination* there may be slight distension of the abdomen due to meteorism. Blue discolouration of the umbilical region, though very rare, is a distinguished sign of this condition. Palpation will reveal deep tenderness in the hypogastrium. Rigidity is not that pronounced as in inflammatory conditions. Rebound tenderness will be positive at an early stage. Shifting dullness will be positive when there is sufficient fluid blood in the peritoneal cavity. Vaginal examination is important and may be diagnostic. (i) That the cervix feels softer than normal; (ii) that all the fornices are tender (in acute appendicitis only the right fornix and in case of pelvic abscess the posterior fornix will be tender) and (iii) that gentle movement of the cervix will cause tremendous pain — give enough indications of the diagnosis of this condition. Later on, restlessness, air-hunger, increasing pallor and running thready pulse will leave no doubt about diagnosis.

Ruptured lutein (follicular) cyst.— If a young woman presents with lower abdominal pain in the middle of her menstrual period this condition should be suspected. When this problem affects the right side, it may mimic acute appendicitis. So the history of the last menstrual period is very important and must always be asked. *That the pain commences in the right iliac fossa* **and not** that it started in the umbilical or epigastric region and then shifted to the right iliac fossa is very much suggestive of this condition. Last menstrual period is also important to exclude ruptured ectopic gestation. In exceptional cases intraperitoneal haemorrhage is considerable to make the shifting dullness test positive.

Twisted ovarian cyst.— If a woman be seized with colicky abdominal pain with vomiting at frequent intervals this condition should be thought of. If a lump is present, which is

tense, tender and cystic with definite smooth margin moving in the lower abdomen — it is a twisted ovarian cyst. Overlying rigidity may mask the lump. If it be small enough to be situated entirely within the pelvis the lump will not be palpable abdominally. Vaginal examination in this case may be helpful. The history that the lump was present before will clinch the diagnosis.

Ruptured or leaking aortic aneurysm.— When a patient, usually middle aged or elderly male, presents with severe upper abdominal or lower chest pain and marked shock, a few conditions should come in mind as probable diagnosis. These are perforated peptic ulcer, coronary thrombosis, acute pancreatitis and ruptured or leaking aortic aneurysm. The patient with this condition is often a known hypertensive patient, but when leakage starts the blood pressure falls catastrophically. He usually complains of severe upper or central abdominal pain radiating through to the back (cf. acute pancreatitis). On examination the patient is considerably anaemic. The aneurysm may be palpable if leakage has not been much or not ruptured. If leakage has started there will be rigidity of the central abdomen more so a little to the left. A mass (blood clot) may be felt in the left iliac fossa resembling pericolic abscess in diverticulitis of sigmoid colon. Arterial pulses of the lower limbs are feeble or absent.

Aortic dissecting aneurysm.— Dissection usually starts in the aortic arch. Hypertension is often of high degree to cause this condition. Pain is excruciating, starts in the retrosternal region, radiates between the shoulders to the back and also spreads to the upper abdomen as dissection proceeds downwards. Signs of shock are apparent, but the blood pressure may be brought down to normal level in an otherwise highly hypertensive patient. Nothing very specific can be discovered on abdominal examination. There may be inequality of pulses of the superior and inferior extremities as the dissection progresses, ultimately there may be disappearance of pulses of one extremity or the other.

COLIC

The common features of colics are :

(a) Sudden appearance of *griping pain* which stays for a period during which the patient almost tosses on the bed and then passes off as suddenly as it came. (b) Nausea, vomiting, belching, retching etc. (c) Varying degree of collapse. (d) Absence of muscle guard (voluntary contraction of the abdominal wall may be mistaken for muscle guard).

Biliary Colic.— Severe colicky pain over the right hypochondrium radiating to the inferior angle of the right scapula and right shoulder is a biliary colic. It is also called gallbladder (Gallstone) colic as it is caused by spasm of the gallbladder to force the stone down the cystic duct. Tenderness over the gallbladder region, jaundice may or may not be associated with depending on whether the stone is in the common bile duct or in the cystic duct. This pain is called a colic as it is intermittent, but the patient seldom describes it as a griping pain. The common bile duct has very little smooth muscle in its wall and this probably cannot be the source of a severe colicky pain.

Ureteric Colic.— Typically the patient is seized with sudden pain starting in the loin and radiating down to the testis, groin or inner side of the thigh (distribution of the genitofemoral nerve, L1 & 2). The testis of the affected side may be drawn up. It is often accompanied by vomiting and profuse sweating. Tenderness can be elicited over the renal angle. Previous history of similar colic, passage of stone with urine and skiagraphy revealing the stone are confirmatory. Frequency of micturition and strangury may be present when

the stone is impacted at the lower end of the ureter. Haematuria may be associated with. This colic occurs when a stone in the renal pelvis temporarily blocks the pelviureteric junction or enters the ureter to block it.

Intestinal Colic.— This occurs in small intestinal obstruction and also in toxic (catarrhal) enteritis. Catarrhal enteritis occurs due to improper food and must be distinguished from acute intestinal obstruction. History of improper diet, occurrence in other members of the same family having taken the same diet and presence of diarrhoea will exclude organic obstruction. In **lead colic**, occupation of the patient as a painter, blue line on the gum and severe constipation are the distinguishing features.

Appendicular colic.— In obstructive appendicitis colicky pain in the right iliac fossa, vomiting and rise of temperature are the usual features. It is a far more serious condition than unobstructive appendicitis and demands immediate surgical interference due to greater possibility of gangrene and perforation of the appendix with resulting spreading peritonitis.

EXTRA-ABDOMINAL CAUSES.—

Rupture of Rectus abdominis muscle and/or tearing of the inferior epigastric artery.— This may occur during a bout of coughing or in pregnancy or during anticoagulant therapy. An extremely tender lump is felt below the arcuate line and above the pubic bones, where the rectus ruptures. Such tender lump is often diagnosed wrongly as appendicitis when occurs on the right side. But this lump is more medially placed. Bruising of the overlying skin makes the diagnosis of tearing of inferior epigastric artery certain. If the patient is asked to lift both the legs keeping the knees straight the lump becomes more prominent and pain aggravates. Strangulated Spigelian hernia is difficult to differentiate from this condition, but absence of vomiting goes in favour of this condition.

Chapter

34 EXAMINATION OF CHRONIC ABDOMINAL CONDITIONS

HISTORY.— In the diagnosis of chronic abdominal lesions, a careful history-taking is very essential as physical signs may be too meagre.

Age and Sex.— Peptic Ulcer is rare before 15 years of age. Incidence of duodenal ulcer is much more before the age of 35 years, whereas gastric ulcer occurs more frequently after 35 years. The ratio of duodenal to gastric ulcer varies from place to place and according to the age of the patient. In the Western countries this ratio is about 4 : 1 below 35 years of age, while in India this ratio is 30 : 1. Carcinoma of stomach is a disease of old age. The majority of patients suffering from hiatus hernia are over 40 years of age. Hiatus hernia may occur in infants when the diagnosis becomes difficult. Diseases of gallbladder mainly affect women of fourth or fifth decade. Congenital pyloric stenosis is obviously a disease of new born babies who start their symptoms from the 2nd month of their lives. Chronic pancreatitis mainly affects individuals in their forties, fifties and sixties.

Peptic ulcer is mainly a disease of males. Carcinoma stomach is also commoner among males but gallbladder diseases and visceroptosis are met with in females more frequently than in males. Chronic appendicitis is more often seen among young girls. Chronic pancreatitis has no predilection towards sex. Congenital pyloric stenosis mainly affects first-born male babies. Women (female, fat, fertile fifty; cf. chronic cholecystitis) are clearly more often affected than men by hiatus hernia.

Occupation.— Though a few professions have been incriminated as causing peptic ulcer, yet substantial evidences are lacking. These professions are bus conductors, clerks, civil servants, business executives etc., who are habituated in drinking teas and coffees in odd times and indulged in excessive smoking. This of course is the statistics in India and may not tally with those of the Western countries.

Residence.— The gallbladder disease is commoner in Eastern region of India, whereas peptic ulcer is more common in northern and southern parts of India due to the habit of taking excessive spicy foods.

COMPLAINTS.—

1. **Pain.**— This is the main symptom of majority of chronic abdominal conditions. Enquiry must be made mainly about the following points :

(a) *Duration.*— Ask the patient, 'How long is he suffering from pain?' When the duration is long, enquire if there is any *periodicity of attacks*. Note, how many attacks did he have, how long did each attack last and whether he was absolutely free from symptoms in the intervals. In peptic ulcer there is definite periodicity which lasts for several weeks and is followed by interval of freedom from pain for 2-6 months. The attacks are more evident in the spring and autumn. In appendicular dyspepsia and gallbladder disease this type of definite periodicity of attacks is not found, instead a mild pain continues even in the periods of remissions.

(b) *Site.*— In case of gastric ulcer pain is complained of in the mid-epigastrium or slightly to its left. In case of duodenal ulcer, the patient complains of pain on the transpyloric plane about one inch to the right of the mid line (duodenal point). In cholecystitis pain is felt on the outer border of the right rectus muscle just below the costal margin. In case of chronic appendicitis, pain is felt in the right iliac fossa on the McBurney's point.

(c) *Radiation.*— When the pain radiates from the right hypochondrium to the right shoulder or to the inferior angle of the right scapula, it suggests gallbladder disease; from epigastrium penetrating through to the back — peptic ulcer penetrating into pancreas; from the left of the umbilicus to the left iliac fossa or to the back — gastrojejunal anastomotic ulcer; from the umbilicus to the right iliac fossa — appendicitis.

(d) *Relationship with food.*— In gastric ulcer food brings pain (*food-pain-relief*), whereas in duodenal ulcer food relieves pain (*food-relief-pain*). The time of appearance of pain in a peptic ulcer depends largely on the site of ulcer. In high gastric, pyloric and duodenal ulcer pain appears about 1/2 hour, 1½ hours and 2½ hours after the meals respectively. The time of appearance of pain is more or less constant in a particular case. So an enquiry should be made whether the patient gets pain when the stomach is empty, i.e. in the early hours of morning or in the afternoon (about 3-4 hours after having lunch); this is diagnostic of duodenal ulcer. If the pain starts immediately after taking food about ½ hour after meals the patient is probably suffering from gastric ulcer. If the pain is more or less constant aching between meals but is increased after intake of food one should suspect gastric carcinoma or complicated gastric ulcer e.g. penetration into the pancreas or pyloric obstruction. That means a gastric ulcer patient, if loses his periodicity of pain one may suspect superimposition of carcinoma or penetration into the pancreas. In cholecystitis and appendicular dyspepsia pain has no relation with food, but it may so happen that a few cholecystitis patients may complain of pain after having fatty meals.

(e) *Character.*— Is the pain severe, griping or mild or burning in nature? A griping pain is often experienced in biliary colic which may be associated with cholecystitis. Pain may be severe in peptic ulcer. In appendicitis pain may be severe and even griping in nature (appendicular colic) with quite a few months of intervals between the attacks. In majority of cases of chronic appendicitis pain is mild aching in nature which gets worse on jolting and running.

(f) *How relieved?* As has been mentioned earlier, in duodenal ulcer food relieves pain (hunger pain). Vomiting always relieves pain of peptic ulcer. The peptic ulcer pain is also relieved by taking alkalis.

2. **Flatulent dyspepsia.**— This is often seen in diseases of gallbladder. The symptoms include a feeling of fullness after food, belching and heart-burn. Sometimes patients with oesophageal hiatus hernia and chronic pancreatitis, may complain of flatulent dyspepsia. This may even be seen in certain cases of gastric ulcer. Heart-burn denotes hyperacidity.

3. **Nausea and Vomiting.**— Nausea is an early symptom of chronic appendicitis, pancreatitis and even gastric carcinoma. Nausea is also an early complaint of virus and serum hepatitis. If there is a history of vomiting, note :

(a) *Character and amount.*— 'Coffee ground' vomiting is seen in conditions where slow haemorrhage takes place in the stomach e.g. carcinoma, gastric ulcer etc. Bilious vomiting is often a feature of cholecystitis and intestinal obstruction. Too much acidic vomiting is a feature of duodenal ulcer. Projectile copious vomiting is often seen in pyloric stenosis complicating duodenal ulcer and in pancreatitis. In pyloric stenosis the vomitus often contains undigested food particles ingested even a day earlier.

(b) *Frequency.*— Vomiting is constant in pyloric obstruction and gastritis; it is frequent

in gastric ulcer, appendicular dyspepsia, gallbladder disease and pancreatitis. It is usually absent in duodenal ulcer without obstruction.

(c) *Relation to food.*— Vomiting soon after the intake of food (within 2 hours) is usually seen in gastric ulcer. In pyloric stenosis it may occur at any time but usually takes place several hours after meal (more often in the evening). Vomiting from gallbladder diseases and pancreatitis (in which vomiting is a marked feature) has got no relation with food.

(d) *Relief of pain.*— Vomiting sometimes brings relief to pain. This is more often seen in case of gastric ulcer. Once the patient has learnt this fact he often resorts to it at the height of pain (induced vomiting) but vomiting affords little relief in pancreatitis, cholecystitis, carcinoma of the stomach and appendicitis.

4. **Haematemesis and Melaena.**— Haematemesis means vomiting of blood and should be distinguished from haemoptysis which means coughing out of blood. Peptic ulcer haemorrhage is a likely complication of a posteriorly situated ulcer whereas perforation is more common in an ulcer lying anteriorly. Though the commonest cause of haematemesis is a chronic peptic ulcer, yet acute peptic ulcer, multiple erosions, oesophageal varices, carcinoma of the stomach, Mallory-Weiss syndrome, purpura, haemophilia etc. are other causes of haematemesis. In a gastric ulcer the amount of vomited blood varies — it may be small or profuse depending on the size of the blood vessel involved. In profuse haemorrhage the colour of the vomitus is bright red; whereas in slow and small bleeding the blood becomes partly digested and looks like 'coffee ground'.

Melaena means passing of dark or tarry stool per anum. It occurs commonly in peptic ulcer, but may be seen in all cases which may have induced haematemesis. A history of fainting attack just before the melaena may be obtained.

5. **Jaundice.**— In surgical practice three groups of cases may present with jaundice — (a) Jaundice due to neoplasia; (b) Jaundice due to biliary tract calculus and (c) Jaundice from other causes.

(a) *Neoplastic Jaundice* — may be due to carcinoma of the head of the pancreas, carcinoma of the ampulla of Vater, carcinoma of the biliary tract including gallbladder, ca-liver and a further 4% of cases may be due to primary neoplastic disease elsewhere with metastatic involvement of the lymph nodes at the porta hepatis.

(b) *Calculous Jaundice.*— Occurs consequent upon a stone or stones in the biliary duct system. Cholangitis from previous calculus may lead to jaundice and rise of temperature.

(c) Among *other causes of Jaundice*, pancreatitis, pancreatic pseudocyst, cirrhosis of liver and virus hepatitis or serum hepatitis are important.

To ascertain yellow discolouration of sclera, skin, nail bed, under surface of the tongue, soft palate etc. one should examine in day light. Jaundice is very liable to be overlooked in artificial light. Itching often accompanies jaundice, so presence of scratch marks on the chest or abdomen sometimes gives a clue to the diagnosis even if yellow discolouration is not that prominent. Itching is due to accumulation of bile salts in the blood. An enquiry must be made about the mode of onset, duration and its progressiveness (that means whether the jaundice is gradually deepening or intermittent). Is the jaundice associated with pain? Painful, intermittent jaundice is very much characteristic of stone in the common bile duct, whereas painless and progressively deepening jaundice is a feature of carcinoma of the head of the pancreas. In carcinoma of ampulla of Vater jaundice may be intermittent due to sloughing of tumour mass.

6. **Bowel habit.**— Blood and/or mucus (slime) in the stool is suggestive of a colonic disease. Constipation is usually present in obstructive lesion of the stomach, gallbladder diseases, chronic appendicitis etc. In case of carcinoma of colon a change of normal bowel habit is noticed

such as increasing constipation or alternate diarrhoea and constipation depending on the site of the lesion. The patient should be asked about the colour and quantity of the stool whether black tarry (melaena — which indicates haemorrhage in the upper G.I. tract or ingestion of large doses of iron or bismuth); or whitish or clay coloured (indicates biliary obstruction either intra- or extra-hepatic); or large, fatty and offensive (suggests chronic pancreatitis).

7. **Appetite.**— Loss of appetite is an early feature of carcinoma affecting any part of the gastro-intestinal tract. This is more prominent in gastric carcinoma. It must be remembered that appetite is never lost in a case of peptic ulcer. Only in case of gastric ulcer the patient becomes reluctant to take food more often due to immediate resumption of pain rather than anything else. In case of appendicitis the patient often rejects food because it initiates nausea and vomiting. Dislike for fatty foods characterizes gallbladder diseases (*qualitative dyspepsia*).

8. **Fever.**— Evening rise of temperature is characteristic of tabes mesenterica as tuberculosis in any other parts of the body. Appendicitis and acute ulcerative colitis are always associated with varying degrees of temperature. Intermittent fever (Charcot's) occurring with rigor and jaundice is highly suggestive of a calculus in the common bile duct.

9. **Loss of weight.**— In carcinoma particularly affecting G.I. tract there will be marked and progressive loss of weight. In pyloric obstruction and in cases with jaundice loss of weight is noticed. In case of gastric ulcer there may be slight loss of weight but in duodenal ulcer patient never loses weight on the contrary he may gain some weight.

Past history.— This must be noted carefully. Whether the patient suffered from typhoid fever (in gallbladder disease), tuberculosis, syphilis, septic foci in the tonsil, throat or nose, jaundice etc. This gives some clue to the present diagnosis. Drug history must be enquired into. Whether the patient was on any drug or not? This not only gives a clue to the diagnosis of the present condition (such as ingestion of aspirin in peptic ulcer) but also it has got importance from anaesthesia point of view (the students are referred to the chapter on 'Anaesthesia' in the treatise 'A Practical Guide to Operative Surgery' written by the author).

Whether the patient had undergone any operation or not? If so, the details of operation should be noted.

Personal history.— The dietary habit of the patient must be noted. Majority of patients with peptic ulcer observe irregular dietary habit whereas patients with appendicitis or gallbladder diseases may maintain a regular dietary habit. The type of diet should be enquired into. Majority of the patients suffering from duodenal ulcer are accustomed to take spicy foods. Meat forms the major dish of patients with appendicitis as this is a disease of civilization.

Excessive smoking and worry have some bearing on the pathogenesis of peptic ulcer. Excessive alcohol consumption also worsens this condition. Cirrhosis of liver and portal hypertension are often accompaniments of excessive drinking of alcohol.

Family history.— Some diseases often run in families — peptic ulcer, Crohn's disease, ulcerative colitis, diverticulitis, carcinoma affecting various parts of the G.I. tract etc.

PHYSICAL EXAMINATION

A. GENERAL SURVEY

The general appearance of the patient should be noted — his build, emaciation, presence of anaemia, jaundice etc. Examine the teeth, fauces and tonsils. Look for signs of pyorrhoea. Note the pulse, respiration and temperature.

B. ABDOMINAL EXAMINATION

INSPECTION.— The patient should lie flat on his back with his legs extended. The whole of the abdomen from the level of the nipples above to the saphenous openings below should be completely exposed. It cannot be over emphasised how rewarding it is to spend sometime on inspection. Examination should be carried out in good light (preferably day light) looking first from the side then tangentially and finally from either end of the bed.

1. **Skin and Subcutaneous tissue.**— Firstly look carefully for any visible swelling. Then look for any erythema — this is due to hot-water bottle application and indicates the site of pain.

If superficial veins are engorged, note (i) their positions — whether situated around the umbilicus (portal obstruction) or on the sides of the abdomen (obstruction of the inferior vena cava) and (ii) the direction of blood flow — whether away from the umbilicus (portal obstruction) or from below upwards (inferior vena caval obstruction). To determine the direction of blood flow two index fingers are placed close together on the vein. A portion of the vein is now emptied by milking it with one of the index fingers. The finger is now released. The rate at which the vein fills after releasing one finger should be noted. The process of emptying the vein is repeated and this time the other finger is taken off. The vein fills rapidly when the finger obstructing the flow of the blood is released. The scar, if any, should be noted. Whether it is linear scar (healing by first intention) or broad and irregular scar (indicating wound infection).

Any hard subcutaneous nodules near the umbilicus, if present, are significant of an intra-abdominal carcinoma, especially that of the stomach.

2. **Umbilicus.**— Umbilicus is normally placed almost in the middle of the line joining the tip of xiphoid process to the top of the symphysis pubis. The umbilicus is displaced upwards by a swelling arising from the pelvis or downwards by ascites (Tanyol's sign). The umbilicus may be everted (ascites) or tucked in (obesity). Any swelling on one side of the abdomen will push the umbilicus to the opposite side.

3. **Contour of the abdomen.**— Normal abdomen is neither retracted nor distended. Generalized retraction is found in thin individual whilst symmetrical distension may be due to fat, fluid, flatus, faeces or foetus. Distension due to obesity should be differentiated from distension due to intra-abdominal causes. In the former the umbilicus is deeply inverted whereas in the latter the umbilicus shows varying degree of eversion. In case of chronic intestinal obstruction there will be fullness of the right iliac fossa. The patient lies in the examination couch straight in such a way that an imaginary line through both the anterior superior iliac spines will be precisely at right angle to the long axis of the examining couch. Compare the left with the right iliac fossa. The fullness of the right fossa due to distended caecum is better seen than felt. In case of enlargement or distension of viscus of the upper abdomen there will be distension of the upper abdomen. Similarly distension or tumour of the viscus of the lower abdomen will lead to distension of that region. In case of *visceroptosis* undue protuberance of the lower abdomen will be evident as soon as the patient stands.

4. **Movements.**—

(a) *Respiratory.*— Localized limitation of respiratory excursion is indicative of subjacent inflammation.

(b) *Peristaltic.*— Peristalsis will be visible in pyloric stenosis and obstruction of the small and large intestines. In pyloric stenosis a rounded prominence will be seen travelling slowly from the left costal margin towards the right whereas peristalsis of the transverse colon will be

seen in the reverse direction. Peristalsis of the small intestine is 'ladder pattern'. In suspected cases peristalsis can be induced by flicking the abdominal wall or by pouring a few drops of alcohol or ether on the abdomen.

(c) *Pulsatile.*— In thin persons epigastric pulsation may be seen. But a pulsatile swelling in the abdomen means either aortic aneurysm (expansile pulsation, see page 31) or a tumour in front of the abdominal aorta (transmitted pulsation).

5. **Swelling,** if present, should be examined as discussed in the next chapter under 'Examination Of An Abdominal Lump'.

PALPATION.— During palpation patient's confidence must be gained. The patient should lie flat on his back comfortably with one pillow below his head. Ask the patient to lie relaxed and breathe slight deeply with mouth open. Under no circumstances he should be hurt. Otherwise abdominal muscles will go into spasm and important findings may be missed. (i) Routine palpation of the abdomen should be carried out with the flat of the hand using mainly the flexor surfaces of the fingers. The forearm should be in the horizontal plane so that the fingers lie flat on the abdomen. For this it is better for the clinician to seat on a chair or even to kneel upon the floor no matter how indignified this may appear. *The fingers must not be held vertical and poke the abdominal wall as shown in the Fig. 33.4.* The great enemy of efficient palpation is rigidity of the abdominal muscles. To avoid this (ii) the patient is asked to flex the hips and knees to release the abdominal muscles. A pillow may be placed under his knees to obviate the strain of keeping the legs flexed. (iii) The patient is adviced to breathe quitely and deeply with his mouth open. (iv) In winter the hand of the clinician must be kept warm same as the patient's skin either by rubbing one hand against the other or by washing it with hot water. (v) It is a good practice to engage the patient in conversation while palpating so that his attention is taken off from clinician's palpation and the abdominal muscles become obviously relaxed. (vi) In obstinate cases some clinicians exert pressure on the lower end of the sternum with the base of the left palm (Nicholson's manoeuvre). This compels the patient to breathe



Fig.34.1.— Shows the method of deep palpation of the abdomen using both hands one above the other.



Fig.34.2.— It is often convenient to palpate a child's abdomen with its own hand. See the text.

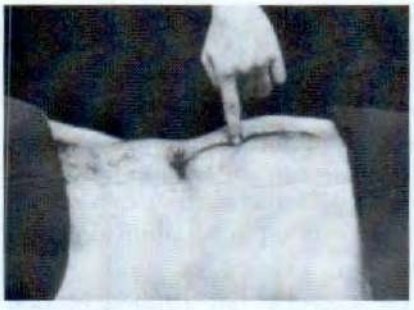

Fig.34.3.— The best method to locate the deep tender spot is with one finger.

abdominally as the movement of the thorax has been restricted. (vii) It is a routine practice to start palpation farthest from the site of the disease. For example, if the pain is located at the right iliac fossa, commence palpating the left hypochondrium and after palpating each quadrant in turn reach the affected area last of all. (viii) When the hand is over a particular region the mind should visualize the particular structures deep to the hand. (ix) While palpating the different regions of the abdomen keep an eye on the patient's face to know his reaction. He may wince at palpation of a region where he did not complain of pain and this may give a valuable clue to the diagnosis. (x) For *deep palpation* the whole of the volar surfaces of the fingers should be used and gradually tilted towards the abdomen. With each expiration more pressure is employed to feel deeper. It is a good practice to use both hands one above the other for deep palpation. While the upper hand puts more pressure, the lower hand remains passive to receive more information about the structures deep to this hand. (xi) *In case of children* who are not cooperative, their hands should be used for deep palpation. Child's one hand is placed on his abdomen and on that the examiner places his hand. Now all the quadrants are palpated like that. When a tender spot comes the child withdraws his own hand.

1. **Tender Spot.**— If the patient has complained of pain at the time of history-taking, ask him to point to its site so that you can begin palpation in a non-tender area and move towards the tender spot. The area of tenderness should be detected by light palpation first. This should be done by gently resting the hand on the abdomen and pressing lightly. Move your hand systematically over all areas of the abdomen. If systematic light palpation over the whole abdomen elicits no pain, repeat the process pressing firmly and deeply to find out if there is deep tenderness. The area of tenderness can be drawn on the history sheet as a hatched area. The degree of tenderness must be assessed — whether it is mildly tender, moderately tender (which initiates slight tightening of the abdominal muscles) or severely tender (when the muscular rigidity becomes obvious).

In case of *gastric ulcer* tender spot is usually situated in the midepigastrium below the xiphoid process. In *duodenal ulcer* it is about 1½ inches to the right of the midline on the transpyloric plane (See Fig. 34.6). To elicit tenderness *in cholecystitis* one may place the right hand just below the right costal margin on the lateral border of the right rectus (the gallbladder point). Moderate pressure is exerted with the fingers to palpate the fundus of the gallbladder. The patient is now asked to take a deep breath in, the gallbladder descends and hurts the examining fingers. The patient will immediately wince with a 'catch' in the breath if the organ is inflamed. This is called **Murphy's sign** (Moynihan's Method). This examination can be performed with the patient sitting. The fingers are hooked under the right costal margin at the lateral border of the rectus and the patient is asked to take deep breaths in. The gallbladder descends further down and comes closure to the palpating fingers. Both sides should be similarly examined to note the difference. In cholecystitis the cartilage of the right 8th rib becomes tender (compare with the other side). This is a positive sign of cholecystitis. In case of *appendicitis* tenderness can be elicited on the McBurney's point, which is situated at the junction of the lateral 1/3 and medial 2/3 of the line joining the right anterior superior iliac spine and the umbilicus (spino-umbilical line).

2. **Fluid Thrill.**— This is obtained when there is a large amount of fluid in the peritoneal cavity either free or encysted. This is obtained by a gentle tap applied to one flank of the abdomen while the thrill is felt with the other hand placed on the other flank of the abdomen. The patient's or an assistant's hand is placed vertically on the midline of the abdomen pressing deeply. This is intended to cut off any transmitted wave through the



Fig.34.4.— Method of eliciting Murphy's sign. In Moynihan's method the patient lies down.

subcutaneous fat which may travel along the abdominal wall to the other flank as also to increase the intra-abdominal fluid tension for better palpation of the fluid thrill. The fluid thrill is also obtained in case of encysted fluid such as a large *ovarian cyst which has touched both the abdominal flanks*. Differentiation between these two conditions can be done by shifting dullness test.

3. **Shifting dullness.**— This is a valuable sign and even becomes positive when the quantity of fluid in the peritoneal cavity is comparatively small. The patient lies flat. Percussion is started from the midline and continued to any of the flanks till the percussion note becomes dull. The finger on the abdomen is kept as such and the patient is asked to turn to the opposite side. In this position wait for a minute or so in order to allow the fluid to gravitate down. That area is again percussed and it will be resonant now.

When there is much fluid in the abdomen palpation of different organs is carried out by 'dipping' the fingers. The quick action will displace the fluid and allows the organ to be felt. In the passing it may be mentioned that in surgical practice the common causes of ascites are portal hypertension, carcinomatosis peritonei and tuberculous peritonitis, but considering all cases including the medical conditions the commonest cause is congestive cardiac failure in which there will be engorgement of the neck veins also.

4. **Palpation of the abdominal organs :**

A. ***STOMACH.***— Normally the stomach cannot be palpated. If there is any history suggesting pyloric stenosis, one should look for visible peristalsis. The sign of *splashing (succussion splash)* should be looked for in these cases. The hand is laid over the stomach. Short, sudden, jerky movements with fingers are made over the stomach area or the patient is shaken. A gurgle may be heard. In case of suspicion the patient may be asked to take fluid before this test is performed.



Fig.34.5.— Method of eliciting fluid thrill.

Occasionally one may find a lump in the pyloric region. Visible lump is more often a feature of congenital pyloric stenosis than adult acquired stenosis. In congenital pyloric stenosis palpation often reveals a thick pylorus. Otherwise a palpable swelling of the stomach means either carcinoma or leaking perforation of a peptic ulcer. *In carcinoma*, the mass is irregular, hard with varying degrees of mobility. A leaking ulcer is firm, less mobile but more tender. But one thing should be borne in mind that *absence of a lump by no means excludes carcinoma of the stomach.*

B. ***LIVER.***— Liver is normally palpable in infancy up to the end of 3rd year. In adults the normal liver is impalpable. Only when the liver is pathologically enlarged it may become



Fig.34.6.— Shows how to find out the transpyloric line (shown in figure by the index finger). On this line 1 inch to the right of the midline is the duodenal point.



Fig.34.7.— Shows a manoeuvre to palpate the spleen. The right hand reaches the costal margin at the tip of the 10th rib and the clinician's left hand is put round the lower left rib cage and is pushed forward with each inspiration. A slightly enlarged spleen may be thus lifted forward enough to make it palpable by the right hand.

palpable under the right costal margin. To palpate for an enlarged liver one should place the hand on the right iliac fossa with the fingers pointing towards the left axilla (that means parallel to the right costal margin). If nothing abnormal is felt, the patient is asked to take deep breath in and out. Every time the patient expires, slide the hand a little towards the right costal margin. This is carried on till the edge of an enlarged liver strikes the lateral margin of the hand when the patient inspires. At this point the hand is kept static keeping a continuous pressure towards the abdomen. As the patient inspires the liver descends and the lateral margin of the index finger will be felt to ride over the free edge of the liver. At this time a few points should be noted as discussed below. If the students want to palpate the liver straight away by placing the fingers below the costal margin, they may miss gross enlargement of the liver. Attention is now directed to palpate the upper margin of the liver. Palpable liver may not be necessarily enlarged, as it may be dropped or pushed down by something from above. To demonstrate the upper limit of the liver it is necessary to percuss along the right mid-axillary line commencing from the 4th interspace. When the

resonance will be replaced by dullness the upper border of the liver is marked. It must be noted in the passing that hydatid cyst or amoebic abscess often causes an upward hepatic enlargement. When the liver becomes palpable note the following points :

(i) *The extent of enlargement* below the costal margin in inches or finger-breadths; (ii) *The character of the edge* — sharp or rounded; (iii) The *surface* — smooth, irregular or nodular with or without umbilication in the nodules; (iv) The *consistency* — soft, firm or stony hard and (v) *Presence or absence of tenderness*. A stony hard and irregular liver is suggestive of metastatic carcinomatous deposits in the liver. A search should be made for the primary focus in the gastro-intestinal tract (i.e. from the stomach down to the upper part of the rectum). The spread mainly occurs through blood via portal vein. Irregular firm liver with small nodules is characteristic of the liver cirrhosis. A soft and very tender liver is often come across in amoebic hepatitis.

C. ***SPLEEN.***— A normal spleen is not palpable. The spleen must be near two times larger than its normal size to be detected by clinical examination. When enlarged it extends from the left costal margin to the right iliac fossa. It moves freely with respiration. Splenic swelling has a sharp anterior border where one or two notches can be felt. This is very much characteristic of a splenic swelling.

The method of palpation of the spleen is very much similar to that of the liver except that this is tried on the left side. There are four methods of palpation : (i) The right hand of the clinician is placed parallel to the left costal margin at the level of the umbilicus and the patient is asked to breathe in and out. During expirations the hand is gradually slided towards the left costal margin till the splenic swelling touches the lateral border of the index finger during inspiration. (ii) Some clinicians put their left hands on the left lower ribs and slide the skin downwards so that the right hand gets an extra bit of skin to insinuate beneath the left costal margin. By this method one can palpate a relatively smaller spleen which has not become big enough to reach below the level of the costal margin. Failure of palpation of an enlarged spleen is mostly due to palpating more medially than its actual position. An enlarged spleen appears just below the tip of the 10th rib. (iii) Another method is that when the right hand reaches the costal margin at the tip of the 10th rib clinician's left hand is put round the lower left rib cage and it is pushed forward with each inspiration (See Fig. 34.7). This manoeuvre occasionally lifts a slightly enlarged spleen forwards enough to make it palpable. (iv) From above spleen may be conveniently palpated with two hands arching below the left costal margin while the patient is asked to take deep breath in and out slowly. The hands are moved further downwards and laterally with each expiration waiting for the enlarged spleen to knock at the fingers during inspiration while the fingers are kept static.

D. ***GALLBLADDER.***— When distended it can be felt as a tense globular swelling projecting downwards and forwards from below the liver just lateral to the outer border of the right rectus muscle (below the tip of the 9th rib). It moves freely with respiration and its upper limit is continuous with the liver. This can be moved slightly from side to side.

Gallbladder becomes palpable (a) in case of mucocele and empyema. Enlarged gallbladder (b) in a jaundiced patient is mainly due to carcinoma of the head of the pancreas or carcinoma of the common bile duct. Calculous jaundice is usually not associated with enlargement of the gallbladder owing to previous inflammatory fibrosis. This is called *Courvoisier's law*. There are a few exceptions to this law, the notable of which are (i) double impaction of stones i.e. one in the cystic duct and the other in the common bile duct; (ii) Oriental cholangiohepatitis; (iii) a pancreatic calculus obstructing the ampulla of Vater; (iv) Mucocele of gallbladder due to a stone in the cystic duct. (c) When the gallbladder swelling seems to be very hard — consider carcinoma of

the gallbladder, a liver metastasis or very rarely a primary liver tumour.

E. ***KIDNEY.***— See Chapter 37 — "Examination of a urinary case".

F. ***PANCREAS.***— This organ cannot be palpated normally unless a growth or cyst has developed in it. The best way to palpate the pancreas is to turn the patient to the right. The hips and knees are flexed. The left subcostal and epigastric regions are deeply palpated. This will evoke tenderness in acute and sometimes in chronic pancreatitis (*Mallet-Guy's sign*).

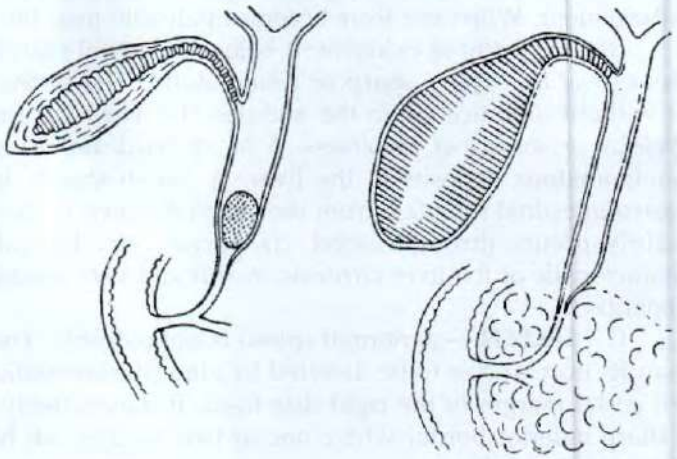

Figs.34.8 & 34.9.— Diagrammatic representation of Courvoisier's law. In jaundice due to a calculus in the common bile duct the gallbladder is usually not distended owing to previous inflammatory fibrosis, whereas in obstruction of the common bile duct due to growth (e.g. carcinoma of the head of the pancreas) the gallbladder becomes distended in an attempt to reduce the pressure in the biliary system.

G. ***COLON.***— Inspection is very important in this case. A fullness of the right iliac fossa due to a distended caecum is better seen than felt. The caecum is distended in majority of cases of obstruction of the large intestine. When the caecum, the beginning of the ascending colon and pelvic colon are thickened they may be palpable. Look for tenderness. A lump in the line of the large intestine may be due to either a faecal mass or a neoplasm. To eliminate the first possibility one can re-examine the patient after a bowel wash, the faecal mass will disappear. Otherwise a faecal mass will yield to digital pressure showing indentation.

PERCUSSION.— The limits of the solid organs can be mapped out by their dull note. The liver extends from the 6th rib to the costal margin on the right midaxillary line. The spleen extends from the 9th to the 11th rib on the left midaxillary line. When there is free fluid in the abdomen *shifting dullness* can be obtained. In case of distended caecum or pelvic colon tympanitic note may be obtained.

Differentiation between ascites and ovarian cyst can be made by percussion. In ascites there is resonance anteriorly and dullness in the flanks whereas in an ovarian cyst there is dullness anteriorly and resonance on the flanks. Further, shifting dullness can be demonstrated in case of ascites but not in case of ovarian cyst.

AUSCULTATION.— It is not very helpful in the diagnosis of chronic abdominal conditions. In case of splenomegaly with portal hypertension, one may hear a venous hum louder on inspiration with a stethoscope placed just below the xiphoid process. This is due to engorgement of the splenic vein and the hum is due to the spleen being compressed during inspiration. This is known as *Kenawy's sign*. Auscultation with scraping may determine the size of the stomach. The bell of the stethoscope is placed below and to the left of the xiphisternum. Along the lines radiating downwards from this point the abdominal wall is scraped with a finger. So long as the finger remains within the limit of the stomach the sound so produced differs from that when the finger goes beyond the limit

of the stomach. The point at which the sound changes is the boundary line of the stomach. When several such points are joined the greater curvature of the stomach can be delineated.

Examination of the left supraclavicular lymph nodes.— This is highly important so far as the carcinoma of the stomach and other abdominal organs are concerned. But it is pity that only a small number of students can remember it. Enlargement of this group of lymph nodes in carcinoma of the stomach is known as *Troisier's sign*.

Rectal and Vaginal Examinations.— Besides the rectal and colonic cases where these examinations are indispensable, in other chronic abdominal conditions the importance of rectal and vaginal examinations cannot be over-emphasised. In appendicitis, Crohn's disease, gastric carcinoma (where Krukenberg's tumour of the ovary may be revealed in vaginal examination) etc. these examinations may help in diagnosis.



Fig.34.10.— Troisier's sign — i.e. enlargement of the left supraclavicular lymph node in a late case of a carcinoma of the stomach.

GENERAL EXAMINATIONS

There are few conditions outside abdomen which may mimic chronic abdominal conditions. So, after examining the abdomen, if the clinician is not satisfied with the clinical findings to account for the pain of the abdomen, he should think of extra-abdominal causes. In these cases he should proceed as follows :

1. Examine the **chest** and **chest wall** for the presence of pleurisy, angina pectoris, coronary thrombosis, pericarditis, fibrosis of intercostal muscles or membranes (pleurodynia), herpes zoster etc.
2. **The spine** for presence of Pott's disease and extradural abscess (Very rare).
3. The **nervous system** for tabes dorsalis. Loss of ankle jerk and sluggish pupillary reaction to light with past history of syphilis and presence of lightning pain in the legs are diagnostic features of this condition.

SPECIAL INVESTIGATIONS

(1) **GASTRIC FUNCTION TESTS.**— These tests are performed as first things in the morning and are comprised of basal secretion and maximum secretion by stimulants such as insulin, histamine and pentagastrin.

The patient should have had nothing to eat or drink from the previous night and should not have taken antacid or anticholinergic drugs for previous 24 hours. The patient should remove his shoes, jacket and tie and opens his collar. His weight and height are measured. The patient now lies comfortably on a couch and his nostril and throat are sprayed with a solution of 3 percent lignocaine in isotonic saline. A nasogastric tube, which was Ryle's tube previously and now it is a plastic, radio-opaque 125 cm long tube with holes close to the tip, is first well lubricated with liquid paraffin and is passed through the nose. The patient is asked to swallow repeatedly while the tube is being pushed steadily and rapidly down through the pharynx and oesophagus into the stomach. A large 20 to 50 ml. syringe is then fixed to the end of the tube and the stomach is emptied of juice and air by repeated aspirations. The patient is now taken to the fluoroscopy room and the position of the tube is adjusted so that its tip lies in the most

dependent part of the stomach which is shown to be along the left border of the spinal column. The tube is now fixed to the face and the end of the tube is connected to a low continuous suction machine which works at a subatmospheric pressure of 3 to 5 cm Hg. Minor adjustment of tube position may be necessary to allow satisfactory aspiration. Normally the quantity of this aspiration is less than 70 ml. If it be more than this, it indicates presence of duodenal ulcer, pyloric obstruction, pylorospasm or hypersecretion. Now the time is recorded and one 60-minutes or four 15-minutes aspirates may be collected and labelled with the times. This is *basal secretion.*

Night fasting secretion (Dragstedt).— This is actually the night secretion of the stomach in its inter-digestive and resting period. Gastric secretion is aspirated through continuous or intermittent low pressure suction for the period of 12 hours from 9 P.M. to 9 A.M. Normally this secretion amounts to about 400 ml. Volumes above this level are suggestive of vagal hyperactivity. In Zollinger-Ellison syndrome this volume may be more than a litre. The juice is tested for HC1 in mEq. In duodenal ulcer this figure is between 40 to 80, in gastric ulcer it is between 5 to 15, in Zollinger-Ellison syndrome it is between 100 to 300 (normal figure being between 10 to 20).

BASAL SECRETION.— 12 hours over-night fasting secretion has little diagnostic advantage over the morning basal secretion. Moreover technically the former is unreliable. The mEq acid per hour of basal secretion in duodenal ulcer is about 5 mEq/hr, in gastric ulcer 1-2 mEq/hr. (normal figure being 1 mEq/hr.). Basal secretion represents secretion of that portion of the patient's parietal cell mass which is being excited even under the resting condition.

MAXIMUM SECRETION.— This can be found out with various stimulants. Whereas Kay's augmented histamine test is gradually losing popularity and Hollander's insulin test has got limited scope of application, pentagastrin is becoming a popular stimulant and is used more often than any other stimulant.

Pentagastrin test.— The optimum dose of pentagastrin is 6 microgram per Kg body weight. It is mostly injected i.m. 15 minutes samples are collected during the next one hour. The term maximum acid output (MAO) is generally used to denote maximum acid output in the whole 60 minutes after injection of pentagastrin and is expressed as m. mol/hr. This test not only has a diagnostic importance but also helps in assessing treatment of the patient e.g. when the acid status is low operation like vagotomy and drainage procedure is enough whereas in case of high acid status individuals operation like vagotomy and antrectomy or partial gastrectomy should be called for. In gastric carcinoma MAO is very low.

Kay's Augmented histamine test.— This test determines the total mass of oxyntic cells in the stomach. At first the fasting stomach contents are collected. Mepyramine malleate is given intramuscularly at the dose of 100 mg. to nullify the side effects of histamine except its stimulation of gastric acid. About 30 minutes later histamine acid phosphate at the dose of 0.04 mg. per Kg. body weight is injected subcutaneously. The gastric acid secretion is collected during the next one hour. The average HC1 response in mEq free acid per hour as follows : a gastric ulcer— 15; duodenal ulcer — 30 to 40; anastomotic ulcer — 30 to 35.

Hollander's insulin test.— This is based on the fact that hypoglycaemia, caused by insulin, induces direct vagal stimulation on the parietal cell mass. Insulin given to a patient who has had a vagotomy performed should result in no increase in acid production. This test is of more value to assess the completeness of vagotomy in the post-operative period. After the fasting stomach contents are aspirated, soluble insulin in the dose of 0.2 unit per Kg. of body weight is injected intravenously. 2 ml. of venous blood is taken just before the introduction of insulin for estimation of sugar. Eight 15-minutes aspirates are collected and labelled. 2 ml. of venous blood is taken

at 30 and 45 minutes after introduction of insulin to estimate the level of blood sugar. It must be remembered that patient's comments and appearance should be noted. Dryness and slight impairment of the level of consciousness should immediately rouse the suspicion of imminent hypoglycaemic coma. Dextrose (50 percent) in the dose of 50 ml should always be kept available during the test and injected immediately intravenously should the said condition arises. A fall in the blood sugar level below 45 mg. per 100 ml. will lead to hypersecretion of acid. Maximum acid output is expected at that time. A rise in concentration of 20 m mol per litre above the basal level in the first hour suggests incomplete vagotomy. It must be remembered that a high acid concentration in basal secretion in the range of more than 20 m mol free acid per hour is indicative of Zollinger-Ellison syndrome.

(2) **EXAMINATION OF BLOOD.**— Haemoglobin level will be low in anaemic patient with melaena and haematemesis. E.S.R. will be high in gastric carcinoma or carcinoma anywhere in the abdomen. During acute attack of appendicitis W.B.C. count will be high. Estimation of circulating gastrin by radioimmunoassay is very much informative.



Fig.34.11.— Gastric ulcer showing the ulcer-crater on the lesser curvature of the stomach and an incisura (indrawing) on the greater curvature just opposite to the crater. Note that the duodenal cap is normal.

(3) **EXAMINATION OF STOOL.**— Melaena i.e. black and tarry stool indicates peptic ulcer with haemorrhage. Small haemorrhage may not be detectable by naked eye examination of the stool. In these cases *occult blood examinations* of the faeces should be undertaken. In chronic pancreatitis there will be presence of neutral fat (steatorrhoea) and striated muscle fibres (creatorrhoea) in the stool. Blood and mucus in the stool is a feature of ulcerative colitis. So routine examination of the stool should be a must in chronic abdominal cases.

(4) **RADIOLOGICAL INVESTIGATION.**— Barium meal X-ray is very much informative so far as the diseases of the stomach, small intestine and appendix are concerned. Lesion of the caecum and proximal part of the colon can be diagnosed by barium follow-through examination. The students should follow the patient to the X-ray department and see how screening is done with barium meal or enema. The patient is given the barium sulphate meal, which is radio-opaque. Palpation of the organ which seems to be diseased under the screen is the most important part of the X-ray examination and is called fluoroscopy. A series of films are also taken 3, 6 and 24 hours after ingestion of the meal. Normally, the fundus of the stomach is seen to be filled with gas (if the film is taken in erect position). The first part of the duodenum appears as a cap, proximal to which a constriction appears caused by normal pyloric sphincter. A constriction also appears about 3 to 4 cm proximal to the pyloric sphincter. This signifies the junction of the body of the stomach and pyloric antrum.

Normally stomach empties within 4 hours. If any residue of barium meal is seen at the



Fig.34.12.— Barium meal X-ray showing the typical filling defect (Shown by an arrow) of carcinoma of the pyloric region of the stomach.

the stomach at the level of the ulcer producing a notch or "incisura" on the greater curvature; (b) a constant deformity suggesting a chronic cicatricial process due to an ulcer; (c) "rugal convergence" i.e. the folds of scar tissue converge on the ulcer side; (d) coarseness and irregularity of the gastric mucosa and, (e) a tender spot on the lesser curvature under fluoroscopic examination.

It is difficult to determine the *development of malignancy in a gastric ulcer.* It may be stated that any ulcer on the lesser curvature more than 1 inch in diameter and all the ulcers on the greater curvature should be taken as malignant unless proved otherwise.

In a duodenal ulcer careful serial radiography may reveal an ulcer crater. But in majority of cases this is not so easily detected. It is important to recognize the shape of the normal duodenal cap in barium meal X-ray. Indirect signs are more common and they are persistent deformity of the dependent part of the stomach after 6 hours it may be due to hypotonia or pylorospasm. If however there is a residue after 24 hours a diagnosis of organic pyloric stenosis is almost certain.

A *gastric ulcer* is recognized by projecting bud of barium meal from normal smooth outline — which is known as *ulcer crater* or *niche.* This is usually seen in the lesser curvature of stomach. This is a direct sign of an ulcer. Since ulcers may lie on the posterior or anterior wall of the lesser curvature, it is obvious that the usual anteroposterior view will not show them. An oblique view may reveal some of them. In these cases, when the stomach has emptied or the barium has gone below the level of the ulcer, there may be left a fleck of barium in the crater with a clear zone around it and corona of mucosal rugae converging towards the crater. These, when seen, are also definite signs of ulcer. In addition to these direct signs one should look for the indirect signs of gastric ulcer. They are : (a) persistent spasm of

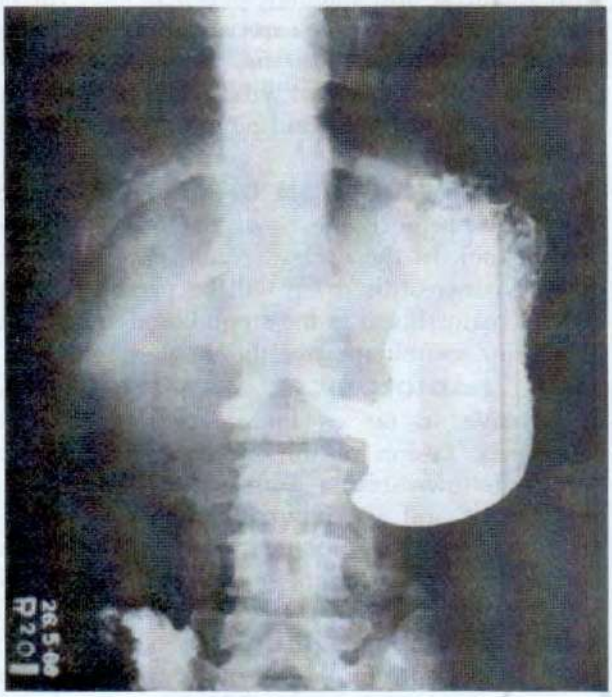

Fig.34.13.— Barium meal X-ray showing irregular filling defect of the pyloric region of the stomach due to carcinoma of the stomach.

duodenal cap, localized tenderness over the duodenum and rapid emptying of the stomach. Deformity of the duodenal cap may sometimes be caused by adhesions in gallbladder diseases.

Carcinoma of the stomach is diagnosed by persistent "filling-defect" which must be constant in all films. The presence of a long and segmental obliteration of mucosal pattern and segmental loss of peristalsis are considered as valuable additional signs of carcinoma.

In carcinoma of the head of pancreas the barium filled duodenum is widened — the "pad" sign. In case of ampulla of Vater carcinoma a filling defect is seen which may give the duodenum an appearance of a reversed 3 (ε).

In *pseudopancreatic cyst* the stomach is anteriorly displaced which is shown in lateral view (Fig.34.15).

In *appendicitis* the part played by X-ray examination is not very significant. The two cardinal signs are tenderness and fixity of the appendix *which has been visualized by barium meal.* A definite opinion cannot be given if the appendix is not properly visualized.

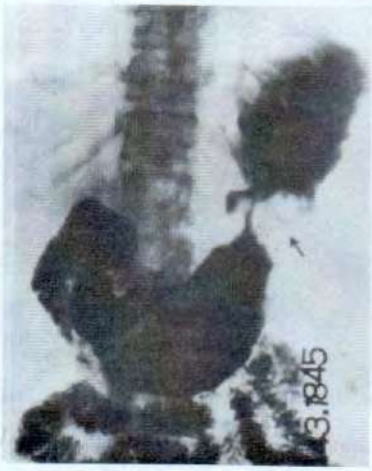

Fig.34.14.— Gastric carcinoma causing 'hour-glass' contracture (shown by an arrow).

Barium meal follow-through examination.— This is performed when a lesion at the distal end of the ileum, appendix, caecum or the proximal part of the ascending colon is suspected. After giving barium meal fluoroscopic examination of stomach and duodenum is performed. Then films are taken after 2, 3 and 4 hours. This is particularly helpful in diagnosis of (i) appendicitis (non-filling of appendix, fixity and tenderness on the appendix when it is filled with barium); (ii) Ileocaecal tuberculosis (the caecum is displaced upwards and the distal part of the ileum becomes slightly narrowed and almost vertical); (iii) Crohn's disease (the terminal ileum becomes narrowed — 'string sign of Kantor'); (iv) Carcinoma of caecum (irregular filling defect in caecum).



Fig.34.15.— Lateral view of barium meal X-ray showing anterior displacement of the stomach due to presence of pseudopancreatic cyst.

Hypotonic duodenography — shows the pathology of the duodenum and the deformity of the duodenum due to the pathology of the pancreas in a much better way. Here the duodenum is made atonic by antrenyl injection, hypotonic barium is pushed through a gastro-duodenal (Scott-Harden) tube and lastly the duodenum is distended with air to give a double-contrast effect. In chronic pancreatitis the earliest change is a definite flattening of the medial margin of the duodenal loop and later on inverted "3" sign is seen. In carcinoma of the pancreas small filling defects (Fig.34.16) or areas of constriction are seen. Besides these, intrinsic lesions of the duodenum like diverticula, papilloma, carcinoma etc. are better delineated than in conventional barium X-ray.

For the radiological investigation of the biliary tract, the patient should be prepared with an aperient, enema and pitressin in order to expel faeces and gas which interfere with biliary shadows. At first straight X-ray is taken. In straight X-ray gallstones can be visualized in only



Fig.34.16.— Hypotonic duodenography showing filling defect due to carcinoma of the pancreas.



Fig.34.17.— Straight X-ray showing a typical radio-opaque gallstone. Note that the centre of the stone is relatively radio-translucent.

10% of cases. If visualized, they look like rings in which the centres remain radiotranslucent whereas the periphery shows calcification. This is typical of mixed stones. Cholesterol stones are not at all radio-opaque. Very rarely a calcified gallbladder or limy bile within the gallbladder may be seen.

Barium enema examination.— Barium enema is introduced per anal canal and X-rays are taken to detect pathology in the rectum, sigmoid colon, descending colon, transverse colon and ascending colon. The deformities which are revealed by this examination in various pathologies of this region are discussed in the section of 'DIFFERENTIAL DIAGNOSIS'. *Double contrast enema,* in which after keeping the enema for sometime the barium enema is evacuated and instead air is pumped through the anal canal. Thus the barium lining in the wall of the colon will be more clearly delineated against the contrast dark background of air filling the colon. This is ideal for small polyp, small ulcer of the mucosa and early malignancy.

Oral cholecystography.— This is essential in the diagnosis of gallbladder diseases. The function of the gallbladder is assessed by this examination. A straight X-ray will be taken in the morning. In the evening the patient is given a light dinner consisting of non-fatty food. After this the patient is given 6 tablets of 'Telepaque' to be ingested with water. The patient is not



Fig.34.18.— In lateral view note that the gallstones (with relatively radiotranslucent centre) are situated quite in front of the vertebral bodies (cf. renal stone).





Figs.34.19 & 34.20.— Straight X-ray of the abdomen showing radio-opaque solitary stone in the gallbladder. In the second figure note that the gallstone lies in front of the lumbar vertebra (cf. renal stone).

given anything to eat or drink till the radiological examination is made on the next morning after 14 hours of ingestion of the dye. The dye is absorbed from the intestine, excreted by the liver and concentrated in the gallbladder. If the dye is not eliminated by vomiting or excessive diarrhoea a normal functioning gallbladder should be visualized in skiagraphy. Non-visualization of the gallbladder means a non-functioning gallbladder. Of course, in a jaundiced patient with impaired liver function the dye may not be excreted and concentrated in the amount to make the gallbladder visible. After 2 or 3 films have been exposed the patient is given a drink containing sufficient amount of fat to cause contraction of the gallbladder. 10 to 20 minutes later films are taken in order to see that the gallbladder contracts



Fig.34.21.— Straight X-ray showing typical multiple mixed stones in the gallbladder.



Fig.34.22.— Oral cholecystography showing a normal functioning gallbladder.





Figs.34.23 & 34.24.— Oral cholecystogram showing negative shadows of gallstones. Obviously these gallstones are not radio-opaque and will not be revealed in straight X-ray.

normally. Biloptin in the evening and solubiloptin in the next morning followed 3 hours later by radiography may show the bile ducts as well as the gallbladder. Stones which were not in the control picture (straight X-ray) may now show as filling defects against uniformly opaque back ground — the 'negative shadows' of gallstones.

Intravenous cholangiography.— Till today it has occupied a mediocre position so far as the disease of the biliary tree is concerned." Biligrafin" is used for this purpose. 20 ml is injected very slowly into a vein. Skiagrams are taken 10 to 40 minutes after the injection. The biliary tract is frequently visualized due to higher concentration of the dye (about 50 to 100 times) within the bile. For the gallbladder this investigation is inferior to oral cholecystography.

By showing a good picture of the biliary tree, stone or other pathology can be easily detected. Though positive finding is of immense importance, yet a negative finding is of no value because the incidence of false negative is unacceptably high. *There are two places where this test surpasses oral cholecystography in diagnosing cholecystitis.* Firstly when the absorption of the dye is impaired as when the patient is vomiting or suffering from diarrhoea and the secondly in case of acute cholecystitis.

Percutaneous transhepatic cholangiography (PTC).— In the recent years by using a 23-guage thin walled needle the percentage of successful study has been increased and the incidence of complication has been decreased thus making this an important investigating method. This investigation shows intra- or extra-hepatic biliary obstruction due to various causes. This should be done in the operation theatre keeping everything ready for operation, if be needed. The prothrombin level should be raised to normal by I.M. injection of vitamin K1. The needle ensheathed by a flexible polypropylene tube is pushed through the liver into dilated intra-hepatic biliary cannalicula. The needle is withdrawn, the polypropylene tube is attached to a syringe and by trial and error aspiration of bile will be seen flowing into the syringe. At this time 20 to 40 ml. of 45 percent Hypaque is injected and X-ray exposures are made. At least three attempts should be made before it is presumed that there is no dilatation of the intra-hepatic bile duct. Haemorrhage, biliary leakage and sepsis are the three major complications of this investigation. It should be a routine practice to send some bile for culture and sensitivity



Fig.34.25.— Percutaneous transhepatic cholangiogram (PTC) showing obstruction of the common bile duct due to metastatic lymph nodes in the Porta-hepatis.



Fig.34.26.— PTC showing obstruction of the common bile duct due to a stone in its lower part shown by the concave margin of dye.

test so that if sepsis ultimately develops one can use the most suitable antibiotic.

(5) **Fibre-optic Endoscopy** — is a great forward step so far as investigation of chronic abdominal conditions are concerned. Modern technique of fibre-optic gastroscopy gives more light and show the actual pathology distinctly. The patient is prepared in the following way: he should fast for 8-10 hours preceding endoscopy. In case of pyloric obstruction repeated aspirations are necessary. Antacids should not be given 10 hours prior to examination. Barium meal X-ray, if required, should be done at least two days before endoscopy. The patient is sedated. The throat should be anaesthetised locally and this remains for about an hour. Indications of gastroscopy are (i) any gastric lesion shown or suspected in X-ray studies; (ii) upper gastro-intestinal bleeding; (iii) persistent vomiting and (iv) symptom complained by a post-gastrectomy patient. It cannot be over emphasised that endoscopy occupies an important role in G.I. bleeding. Further one can detect a peptic ulcer which has not been shown by barium meal X-ray. It also can assess the improvement of the ulcer by medical treatment. A gastric ulcer — whether benign or malignant can also be diagnosed by endoscopy. Gastric camera will show still picture of the pathology in the stomach. Last but not the least is its 90 percent accuracy in finding out a stomach ulcer which is often missed by skiagraphy.

The stomach has long been accessible to the endoscopist and gastritis, ulceration, haemorrhage, stomata and malignancy were diagnosed conveniently. But regular inspection of the duodenum was not possible till the advent of a slim endoscope which can be passed through the pylorus. The forward viewing Olympus GIFD and ACMI or side-viewing Olympus JFB can be used for duodenoscopy as a part of the oesophago-gastro-duodenoscopy. Over all extreme flexibility and control of the instrument make it possible for every part of the stomach and duodenum to be inspected and a lesion may be biopsied. Thus radiology by barium meal which has traditionally been the primary method of gastric examination and is now regarded

as complementary, may soon be less important than endoscopic studies. Besides the uses already described above, duodenoscopy is particularly indicated in the assessment of dyspepsia. There may be definite oedema, narrowing or permanent distortion of the round orifice of the pylorus. There may also be duodenitis in these cases. These are in fact examples of X-ray negative dyspepsia.

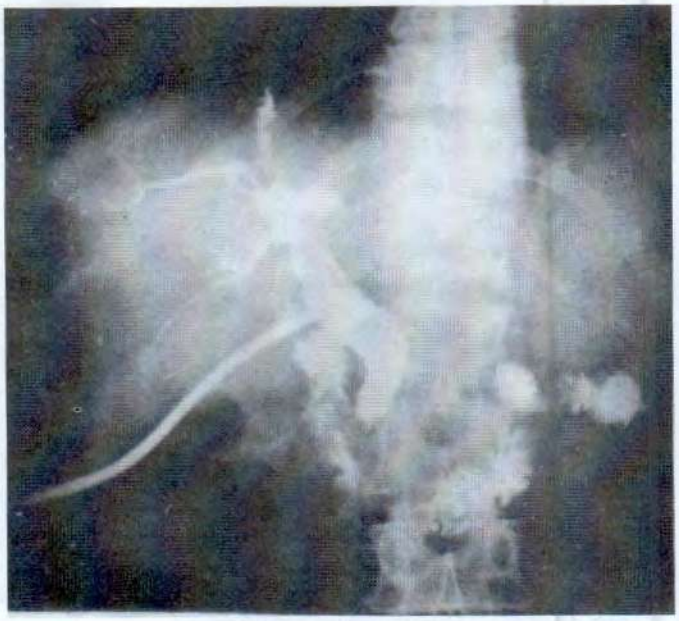

Fig.34.27.— T-tube cholangiography showing stone (negative shadow) at the distal end of the common bile duct. Note that the common bile duct and hepatic ducts are dilated.

Endoscopic Retrograde Cholangio-pancreatography (ERCP).— Now-a-days common bile duct and pancreatic ducts can be cannulated by side viewing fibre-optic duodenoscope through ampulla of Vater. Cannulation of the papilla of Vater is carried out with the instrument so positioned as to give an end-on view of the papilla from some 1 cm distance. A polythene cannula is made clear of air and flushed with 60% Urografin. The cannula is passed through the instrument taking care not to spill contrast medium into the duodenum since this stimulates peristalsis and makes cannulation difficult. Contrast medium is introduced slowly under fluoroscopic control. Both biliary and pancreatic ductal systems fill, but usually one duct fills first. If the pancreatic duct is filled first contrast medium more than 2 to 2.5 ml should not be injected. When the pancreatic ductules at the tail are filled injection must be stopped since overfilling will lead to extravasation and will cause pain. After pancreatography the tip of the cannula is readjusted to fill the biliary duct. Now 40 ml. of contrast can be used and preferably 25% Hypaque is used to prevent obscuring of the small stones. Its main indications are three : (i) Jaundice — Persistent and recurrent undiagnosed jaundice (cause of obstruction will be revealed); (ii) Biliary tract problems.— Undiagnosed upper abdominal pain (suspected to be biliary in origin) and postoperative biliary symptoms. (iii) Pancreatic diseases.— Undiagnosed abdominal or back pain (suspected to be pancreatic in origin), chronic and relapsing pancreatitis (stricture, irregular dilatations, cysts etc. can be seen). The main complications of this procedure are infection (including cholangitis and serum hepatitis) and pancreatitis.

(6) **Ultrasound.**— The development of diagnostic ultrasound has definitely brought about a revolution in the investigations of chronic abdominal disorders. A sonar scan involves minimal patient preparation, takes an average of 15-20 minutes to perform and causes no discomfort to the patient. The barium has a deleterious effect on the scan so if possible ultrasonic examination should be carried out before barium studies. In a supine scan of the upper abdomen it is possible at various levels to outline the liver, spleen, aorta, vena cava and the kidneys. The gallbladder can frequently be identified and there is often a small echo-

free area. Ultrasound is of particular value in the diagnosis of space-occupying lesions. The size, shape and consistency of the organs normally outlined can be assessed and relationships of the mass to these organs can be identified. Cysts present very well defined contour and are transonic. Their surfaces are usually echo-free although they may give rise to linear echoes due to presence of septa. Poor demarcation of the malignant tumour suggests infiltration of the surrounding tissues.



Fig.34.28.— Ultrasonography showing clearly a stone in a dilated gallbladder.

Carcinoma of stomach may even be diagnosed as the mass which remains deep to the left lobe of the liver. The patient is given 2 or 3 glasses of water to identify the gastric lumen. The palpable mass corresponds exactly to the area of fine echoes on the wall of the stomach.



Fig.34.29.— Ultrasonography showing multiple stones inside a dilated gallbladder.

In liver, not only anatomical abnormalities like Riedel's lobe can be diagnosed, but also cysts, abscesses, primary and secondary tumours can be diagnosed by ultrasound. The most frequently recognized appearance of metastatic tumour is either ring-shaped pattern or solid irregular mass with expansion of the adjacent liver outline.

So far as the gallbladder diseases are concerned, in the



Fig.34.30.— Ultrasonography showing a calculus at the neck of the gallbladder, which is hugely dilated — a case of empyema gallbladder. One can also see fluid collection (Coll.) around the highly infected gallbladder.

absence of jaundice ultrasonic B-mode scanning compares well with oral cholecystography, but in the presence of jaundice however ultrasonic scanning is considered to be the investigation of choice, as ultrasound can be used regardless of the state of the gallbladder and liver. Congenital anomalies like duplication of the gallbladder or Phrygian cap can be imaged with ultrasound, even gallbladder size is easily measured with this technique. Ultrasound can detect gallstones larger than a few mm in size. Biliary mud can also be appreciated. It may be confessed that ultrasound may even be preferred to oral cholecystography provided the necessary skills are available. The advantage of ultrasound is that additional information about the biliary tract, liver and pancreas can be obtained. Even a thick, oedematous gallbladder without presence of gallstones as well as gangrenous gallbladder may also be identified by ultrasound. It must be remembered that children may be rarely affected by gallbladder disease and ultrasound is an excellent imaging modality for these cases than oral cholecystography without the hazards of ionising radiation.

Intrahepatic biliary tree and the common hepatic duct can be clearly identified by real-time ultrasound fluoroscopy. A diameter of more than 7 mm in case of common hepatic duct indicates dilatation of the intra-hepatic biliary tree. Stone in the common bile duct can also be identified by this technique. It may even show an enlarged gallbladder with obstruction of the lower end of the common bile duct due to carcinoma of the pancreas when the gallbladder is not palpable clinically. *Here lies the importance of ultrasonic scanning over any method of investigation.* The pancreas is difficult to examine as it is effectively screened by the echo-reflecting bowel. Though a normal pancreas cannot be defined, yet an inflammed oedematous pancreas can however be seen as a poorly defined mass in front of the aorta and the vertebral column. Cysts and pseudocysts can be readily outlined and tumours more than 3 cm in diameter can be identified with the ultrasonic equipment. An enlarged spleen can be recognized from its typical shape — the splenic notch. Cysts of the spleen whether congenital or traumatic are easily seen by ultrasound within the splenic substances. Splenomegaly associated with portal hypertension and cirrhosis of the liver is also not very difficult to detect.

Ultrasonic guidance for biopsy and aspiration is an added advantage of this mode of

investigation. Aspiration of the liver cyst has been performed guided by ultrasound. This technique is more popular in case of renal cyst.

(7) **Radio-isotope scanning.**— Liver scans were found to be of value especially in the differential diagnosis of upper abdominal masses, of jaundice, of hepatomegaly and in the screeing of patient with malignant disease. The method is as follows : The patient is given inorganic iodide orally for two days prior to scanning to block thyroid uptake of isotope. Scanning is performed with the patient in supine position 8 to 10 minutes after the administration of the isotope (this represents the time taken for the hepatic uptake). The isotopic agents normally used are ^{131}I-labelled human serum albumin and ^{99}technetium. In the cases of hepatomegaly of unknown aetiology scanning may help in the differentiation between focal and diffuse diseases. Cirrhosis of liver gives rise to a characteristic pale, patchy scan owing to reduced and irregular hepatic uptake. Scanning may detect malignant



Fig.34.31.— Ultrasonography showing thick walled gallbladder — a case of acalculous acute cholecystitis (*see* Page 879 of 'A Concise Textbook of Surgery' by Dr. S. Das).



Fig.34.32.— Ultrasonography showing a big stone at the distal end of the common bile duct which is dilated.



Fig.34.33.— Ultrasonography of the abdomen showing enlarged metastatic lymph nodes in front of the aorta (involving pre- and para-aortic groups of lymph nodes).

nodes in the porta hepatic as a cause of jaundice. Scanning has at times been used to demonstrate right subphrenic abscess. The greatest application of liver scanning is in detection of intra-hepatic lesion such as abscess, hydatid and other cysts, primary or secondary neoplasms. Reported figures of overall accuracy in detection of hepatic metastasis range from 77% to 93%.

Pancreatic scanning is performed by using ^{75}Se-labelled metheonine in the dose of 3μc per kg admitted intravenously. From a pancreatic scan information can be obtained whether the pancreas is functioning or not, its size, shape, various cysts and tumours within its substance.

(8) **Radioactive isotopes in alimentary bleeding.**— Following intravenous injection of erythrocytes labelled with ^{51}Cr the loss of blood into the lumen of the gut may be measured as ^{51}Cr is not reabsorbed. In clinical management of acute gastrointestinal bleeding, the site of haemorrhage is difficult to find by radiographic or endoscopic examination or even at laparotomy. If following injection of ^{51}Cr-labelled red cells fine polythene tube is passed slowly down the gut as far as the terminal ileum. Frequent samples of gut fluid are obtained and their blood contents are determined. As soon as bleeding is detected the position of the end of the tube is determined radiologically.

(9) **Selective Visceral Angiography.**— Bleeding at the rate of 0.5 to 3cc per minute can be diagnosed by this technique. Emergency angiography is indicated for acute haemorrhage when the site of haemorrhage is unknown. Angiography may not only accurately localize haemorrhage but also can control bleeding to some extent by selective infusion of vasoconstricting drugs. This significantly reduces blood loss and allows better preparation of an emergency patient. Percutaneous catheterisation via the femoral or axillary approach by the Seldinger technique is followed by selective injection of iodinated water soluble contrast material into the coeliac, superior mesenteric or inferior mesenteric artery. Thus the site of haemorrhage is identified. The vessels nearest to the site is selectively catheterised. Pitressin is infused at the rate of 0.2 unit per minute for 15 minutes. Later on this dose is adjusted according to the rate of haemorrhage. Immediate surgery is necessary when bleeding is not controlled by pitressin. Gelfoam mixed clot or a Fogarty catheter can be used to occlude the bleeding vessel.

(10) **Laparoscopy** — in the investigation of patients with jaundice allows visualization of intra-abdominal pathology, target biopsy of intra-abdominal lesions and percutaneous fine-needle cholangiography all carried out at one procedure is of great diagnostic value. Cholangiography is carried out into dilated intra-hepatic ducts, but in cases with minimal dilatation, the gallbladder can be injected with contrast medium. To minimise biliary leakage from the gallbladder which may be under tension, the needle should be directed through the adjacent liver tissue across the gallbladder bed.

(11) **Exploratory laparotomy.**— In places where there is not much scope of carrying out various investigations as stated above, exploratory laparotomy should be called for earlier and becomes the last court of appeal. It must be realized that even after the sophisticated investigations as discussed above have been utilized, a few cases will remain undiagnosed and in these circumstances exploratory laparotomy may be justified to arrive at a definite diagnosis.

DIFFERENTIAL DIAGNOSIS

CHRONIC GASTRIC ULCER.— The majority of the patients are more than 40 years of age and men are more often affected than women. Occupationally the patients are mainly in the rank of executive and perhaps greater stress and strain of the responsibility of the job may predispose the ulcer formation. The patients are often thin due to restricted diet for fear of pain. The main symptom is epigastric discomfort or pain which may vary from vague and mild discomfort, dull aching or burning to very severe pain which compels the patient to lie down. The main feature of the pain is its "clock-like" regularity. The pain appears immediately after taking food, so the patient becomes afraid of it but appetite remains good (cf. duodenal ulcer). Thus the patient may lose a little weight. The pain may radiate to the back when the ulcer penetrates into the pancreas. Relief is obtained spontaneously as soon as the stomach is emptied, or by taking alkali or by vomiting which is often self-induced. Vomiting is sometime a notable symptom, but is not more than 15 percent of cases. Haematemesis and melaena may associate chronic gastric ulcer in about 1/4 of the cases. On examination deep tenderness can be elicited with remarkable constancy in the mid-epigastric region. Investigation can be carried out as discussed above.

CHRONIC DUODENAL ULCER.— Typically the patients are young (below 40 years of age), quite busy and swallows his meals hastily at an irregular intervals between cigarettes and telephone calls. Again men dominate. Pain is the main symptom, but it appears 2½ to 4 hours after meal when the stomach becomes empty, i.e. "hunger pain". The pain usually appears in the early morning or in the late afternoon. The heavier the meal, the longer is the interval but the worse is the pain. The pain is characteristically located 1½ inches to the right of the midline on the transpyloric plane (i.e. about a hand's breadth below the xiphisternal joint). Relief is obtained by taking food. The pain maintains a characteristic periodicity and the attacks come in the spring and autumn. It must be realized that it is precipitated by excessive work, worry and anxiety, cigarettes and alcohol. Eructation of water or acid and heartburn are also very common symptoms of this fail disease. It must be remembered that vomiting is an uncommon symptom of duodenal ulceration. Haematemesis and melaena which are features of haemorrhage within the ulcer are more frequent than in case of gastric ulcer. Appetite is exceptionally good, moreover patients eat at frequent intervals to get rid of the pain, so the majority of the patients are well build. On examination, localized deep tenderness on the duodenal point is quite common. There is 2% chance of perforation and 5% chance of massive haemorrhage. Investigations should be carried out as mentioned earlier.

PYLORIC STENOSIS.— This is due to cicatrisation of a duodenal or a juxta-pyloric ulcer. Peculiarly this occurs more often in the female. The long history of duodenal ulcer, certain loss of its periodicity with enhancement of pain and fullness towards evening are the typical points in the history worth noting. Vomiting, which is large in amount also occurs characteristically in the evening. It is often foul and frothy and contains undigested food material eaten even 2 or 3 days earlier. On examination, visible peristalsis passing from left to right is pathognomonic. Succussion splash is often heard. Barium meal X-ray will clinch the diagnosis.

Gastro-Jejunal ulcer.— It may occur after Polya type of partial gastrectomy or after gastro-jejunal anastomosis. The incidence becomes very high when gastro-jejunostomy is not associated with vagotomy. Recurrent ulcer occurs in about 3% of cases after Polya gastrectomy and 5% of cases after vagotomy and gastro-jejunostomy. Symptoms usually appear within 2 years or so after the operation. Pain is again an important symptom and usually boring in nature and appears within 1/2 hour after taking food. The pain characteristically radiates from above and left of the umbilicus to the left iliac fossa. Haemorrhage is very common and it may be manifested as haematemesis, melaena or occult blood in the stool. Vomiting is also very common and gives relief to the pain. A gastro-jejunal ulcer is more prone to perforation than a peptic ulcer. This ulcer may penetrate into the transverse colon leading to gastro-jejunocolic fistula. With the appearance of this fistula symptoms of anastomotic ulcer disappear, but unfortunately severe diarrhoea and eructation of foul gas take their places. Even the patients may vomit fragments of formed faeces. The main pathology behind this dreadful condition is the fouling of the jejunum by colonic contents. This results in tremendous disturbance of the vital absorbtive mechanism. X-ray examination with barium meal will show narrowing of the gastro-jejunostomy stoma and spastic contraction of the stomach and jejunum. Actual ulcer crater is hardly seen. It must be remembered *that gastro jejunocolic fistula is better diagnosed by a barium enema* since in more than 1/2 the patients the barium meal fails to reveal the fistula.

CARCINOMA OF THE STOMACH.— The clinical picture can be conveniently described under 4 headings: (i) insidious type, (the carcinoma occurring in the body of the stomach), (ii) obstructive type (carcinoma occurring in the pylorus or at the cardiac end), (iii) as a lump and (iv) as a carcinoma superimposed on a gastric ulcer.

This is a disease of the elderly, but if suspected in the young, should not be turned down on the point of age only. This is again commoner in men.

(1) *The insidious type.*— The history is usually short. The early symptoms are indigestion, vague discomfort, a sensation of fullness and heaviness after meals in the upper abdomen; loss of appetite; a feeling of weakness etc. The pain in the true sense is usually conspicuous by its absence in the early stage. Pain may appear in the very late stage of the disease.

The late symptoms are vomiting which give no relief to the pain, loss of weight and constant epigastric pain which is neither caused by nor relieved by food. On examination, wasting and pallor are noticeable features. The patients may be jaundiced. The abdomen becomes scaphoid and the skin becomes wrinkled and inelastic. Paradoxically there may be ascites with abdominal distension. On palpation there may be slight epigastric tenderness.

Deep palpation with relaxed abdomen may reveal an epigastric mass which is hard, irregular, mildly tender and may or may not move with respiration. One should try to palpate the liver which when palpable indicates secondary involvement with hard nodules. Fluid thrill and shifting dullness may be present if there is free fluid in the peritoneal cavity. There may be hard subcutaneous metastatic nodules in the umbilical region. To seek secondary deposit elsewhere one should palpate the lymph node of the neck particularly the left supraclavicular lymph nodes (Virchow's). Rectal examination may reveal transcoelomic

implantation of metastatic cells into the rectovesical pouch. Vaginal examination may reveal Krukenburg's ovarian tumour. Wandering thrombophlebitis (Trousseau's sign) should be looked for in late cases. Special investigations should be carried out as discussed above.

(2) *Obstructive type.*— Gastric carcinoma at the cardiac end and at the pylorus may obstruct the passage of food. Growth at pylorus is much more common than the former variety. The clinical picture resembles pyloric stenosis. The characteristic features of carcinoma are : (a) The history is short — a few months. (b) There may not be any previous history of peptic ulcer. (c) Anorexia, nausea and vomiting are constant; the vomitus is offensive containing altered blood "coffee ground". (d) Loss of weight is marked. (e) Skiagraphy with barium meal will confirm the diagnosis.

(3) *Lump.*— Sometimes the patients may present with epigastric lump and nothing else. The general appearance of the patient will be same as discussed above. The lump will be hard, irregular, mobile or fixed, may or may not move with respiration. One should look for secondary metastasis.

(4) *Peptic ulcer type.*— The possibility of carcinoma supervening on a gastric ulcer is recognized but the percentage of such complication is questionable. Malignancy should be suspected when: (a) there is loss of periodicity of the attacks, remission being shorter or nil; (b) the sharp burning ulcer pain is replaced by a constant dull ache; (c) good appetite of the gastric ulcer is replaced by loss of appetite; (d) nausea is common but vomiting gives no relief as previously (vomiting may be coffee ground); (e) loss of weight is rapid.

HIATUS HERNIA.— It is defined as prolapse of a part of stomach into the thoracic cavity through oesophageal hiatus. It may be of (i) Sliding type — 85%, (ii) Paraoesophageal (Rolling) type — 10% or (iii) Mixed type — 5%. Middle-aged or elderly obese ladies are the usual victims. Patients may complain of heart-burn, which becomes aggravated in stooping or lying down position, belching or reflux of acidic gastric juice into the mouth. They may also present with





Figs. 34.34. & 34.35.— Barium meal X-ray showing sliding type and rolling type of hiatus hernia respectively.

the symptoms due to the presence of hernia in the chest, such as flatulent dyspepsia, fullness, shortness of breath, upper abdominal pain, tachycardia etc. They may also come with the complications of oesophagitis like dysphagia, slight haematemesis or anaemia etc. Special investigations like barium meal X-ray (Figs. 34.34 & 34.35), oesophagoscopy etc. will diagnose the condition.

CHRONIC CHOLECYSTITIS and CHOLELITHIASIS.— Though the typical proverb is that the patients are usually **F**at, **F**ertile, **F**air, **F**emale of **F**orty, yet one should not give very much importance to this five 'F's as definite aid to diagnosis.

In many cases *the feeling of distension* is the first symptom and the patient may feel that she has eaten too much before she has finished the meal. Gradually the patients start complaining of pain over the upper part of the right rectus muscle often radiating to the inferior angle of the right scapula. The patients often notice that the pain becomes worse after taking fatty foods (qualitative dyspepsia). The patient may make attempts to get relief by inducing vomiting, but that is seldom achieved as in peptic ulcer case. Nausea is very common but vomiting is rare. *Postprandial belching*, often described as flatulant dyspepsia, is also a common symptom of this condition. Patient's appetite is maintained. Attacks of pain are irregular lasting for weeks or months or pain free intervals of varying length.

Jaundice is not a sign of cholecystitis although a slight icteric tinge may be present due to associated cholangitis. Inspection reveals a normally looking abdomen. On palpation the most important sign is that of Murphy (see page 488). In majority of cases the gallbladder is not palpable unless a mucocele or empyema develops. The various modes of X-ray are quite confirmatory and have already been discussed under the heading of "Special Investigations". Oral Cholecystography and ultrasound are quite diagnostic.

STONE IN THE COMMON BILE DUCT.— Typically the patients suffer from (a) biliary colic, (b) jaundice following each attack of colic and (c) intermittent fever (Charcot's) — the triad of choledocholithiasis. It should be differentiated from carcinoma of the head of pancreas.

Oriental Cholangiohepatitis.— This is a condition in which there are long standing stones in the common bile duct. This results from obstruction to the common bile duct due to infestation by the Chinese liver flukes (Clonorchis Sinensis). The patient presents with pain, jaundice and intermittent pyrexia (Charcot's triad). Urine contains bile and the stool becomes clay coloured. This condition is common in Japan, China, Hong Kong etc.

Choledochus cyst.— In this condition weakness of a part or whole of the wall of the common bile duct leads to a cystic dilatation which ultimately gives pressure on the remaining bile duct and thus obstructs the flow of the bile to the duodenum. This condition is rare and females are affected more commonly than males. In Japan this condition is commoner than in any other countries. The patient never presents before six months of age and about half of the cases present only in adult life. Upper abdominal pain, obstructive jaundice and pyrexia from infection (Charcot's triad) are again the main presenting symptoms. Palpation may reveal the cyst, which may be confused with pancreatic cyst.

CHRONIC PANCREATITIS.— It is a condition in which there is slow but progressive destruction of the acini with increasing fibrosis — the whole pathology leads to functional failure of the pancreas. Abdominal pain is the main presenting symptom which starts in the epigastrium and tends to pass through to the back. The pain varies from a boring pain to that of biliary colic. The pain is often quite intolerable which becomes slightly relieved when the patient sits up. The pain lasts for about 3 to 4 days. Vomiting is present in more than

50% of cases. Weakness is very common. Jaundice is present in less than 20% of cases but diabetes is more common (about 1/3 of cases). Steatorrhoea is quite common. Best way to palpate the pancreas is to turn the patient to the right and hips and knees are flexed. The left subcostal region is deeply palpated. This will evoke tenderness in acute and chronic pancreatitis (Mallet-Guy's sign).

CARCINOMA OF THE PANCREAS.— It usually affects the head, sometimes the body and rarely the tail of the organ. Men are usually the victims.

Carcinoma of the head of the pancreas.— Although it is often described as a painless condition, yet the patient may present with pain as his first symptom. Jaundice is very common and in majority of cases it precedes pain. Jaundice is classically said to be progressively deepening. Intermission may be seen in cases of carcinoma of the ampulla of Vater due to sloughing of the growth. Anorexia and loss of weight are very common as in other carcinomas. Diarrhoea may be troublesome and foul smelling. The pale stools are quite common and steatorrhoea from enzyme deficiency is also a feature of this condition. Occasionally patients may present with the symptoms very much similar to those of acute pancreatitis. So old patients when present with these symptoms one should investigate thoroughly to exclude carcinoma of the pancreas. The gallbladder is enlarged according to Courvoisier's law (see page 491). The tumour is seldom palpable. The liver may be enlarged. Ascites may be present only in the late cases.





Figs.34.36. & 34.37.— Ultrasonography — In the upper figure one can see a mass in the head of the pancreas near ampulla of Vater with dilated pancreatic duct. In the lower figure in the same case one can see the dilated pancreatic duct (PD) and also a very dilated common bile duct (CD) and the mass near the ampulla of Vater (P).

Carcinoma of the body and tail of the pancreas.— Pain in the epigastrium is the cardinal symptom. The peculiar feature of the pancreatic pain is that it passes through to the back. It is aggravated when the patient lies down and lessened when he sits up so the patient often spends the night sitting up with his arms folded across the chest. Thrombophlebitis migrans may be an indication of the presence of pancreatic carcinoma. Thrombophlebitis which appears spontaneously and resolves only to appear again elsewhere is the type one often comes across. This is known as *Trousseau's sign.*

CHRONIC APPENDICITIS.— Young girls are the main victims of this condition. A vague pain in the abdomen which is more often complained at the right iliac fossa is probably the earliest symptom in majority of cases. Definite localized pain may be absent instead a vague

dyspepsia may be complained of. Vomiting may be present but does not afford any relief to pain. This is commoner in pre- and post-ileal positions of the appendix. Constipation is a common accompaniment of this condition. Scalding pain on micturition or pain which mimics ureteric colic is often complained of. On examination the cardinal finding is a distinct tenderness over the appendix. Rectal examination often gives a clue to the diagnosis.

CROHN'S DISEASE.— The patients often have diarrhoea without obvious bleeding. Perianal lesions such as abscesses, fissure and fistulae are quite common in this condition. The clinical picture is best considered in 4 stages : (1) the inflammatory stage, when a mass is palpable in the right iliac region; (2) the colitis stage, when diarrhoea, fever, anaemia and loss of weight are present; (3) the stenotic stage, when the picture of small gut obstruction supervenes and (4) the fistula stage, either external or internal — communicating with the sigmoid colon, bladder, caecum, etc. Differentiation from an appendicular lump is made by the absence of origin of pain in the umbilical region, insidious onset and presence of occult blood in stool. Skiagraphy with a barium meal will reveal loss of peristalsis in the affected loop and the 'string sign' of Kantor when the lumen is narrowed to a fine cord. (Fig. 35.13).

If the condition has involved the colon, in barium enema a coarse cobblestone pattern may be present but it is often difficult to differentiate this from pseudopolyposis of ulcerative colitis. Segmental lesions strongly favour the diagnosis of Crohn's disease. An abrupt cut-off in the radiological abnormalities speaks in favour of Crohn's disease. The deep fissuring ulcers may give rise to spiky or rose-thorn appearance. Sigmoidoscopy may reveal Crohn's disease if the condition has involved the rectum.

Crohn's disease of the colon.— The main three features of this condition are diarrhoea, loss of weight and abdominal pain. Sometimes abdominal lump may be present due to peri-colonic thickening or infection. Spontaneous fistula may develop either to the exterior or with the viscus. This type of fistula formation is never found in ulcerative colitis though occasionally seen in diverticulitis. In acute colonic Crohn's disease there will be toxic dilatation of the colon as seen in acute ulcerative colitis. Presence of anal abnormality is found in about 80% of colonic cases. Rectal bleeding is less frequent than that in ulcerative colitis and diverticulitis. In contradistinction to ulcerative colitis, rectum is involved in only half the cases, so in sigmoidoscopy normal rectal mucosa does not exclude this condition. The mucosa when affected shows oedematous swelling, granularity and scattered small ulcers with normal mucosa in between (cf. ulcerative colitis, where there is uniform diffuse change without presence of intervening normal mucosa).

Systemic disorders like erythema nodosum, synovitis, iritis and minor septic skin conditions may be seen with this condition.

ABDOMINAL TUBERCULOSIS.— Abdominal tuberculosis can be one of two types — A. Intestinal tuberculosis and B. Tuberculosis of mesenteric lymph nodes.

A. **Intestinal tuberculosis.**— This is also of two varieties — (a) Ulcerative tuberculosis and (b) Hyperplastic ileo-caecal tuberculosis.

(a) ULCERATIVE TUBERCULOSIS.— This usually results from inhalation of tubercle bacilli (human type) in sputum in a case of pulmonary tuberculosis. This condition is characterized by multiple ulcers at the terminal ileum. The long axis of the ulcer lies transversely. The serous coat overlying the ulcer becomes thickened, so perforation is unusual. Healing of the ulcers leads to stricture formation. Loss of weight and diarrhoea with fetid odour stools containing pus and occult blood are complained of. Often the patient is a known case of pulmonary tuberculosis. On examination nothing specific can be discovered except slight tenderness in

the right iliac fossa. Barium meal follow-through may demonstrate non-filling or inadequate filling of terminal ileum, caecum and proximal part of ascending colon due to narrowing and hypermotility of the ulcerated segment.

(b) HYPERPLASTIC TUBERCULOSIS is described in the next chapter in the section of differential diagnosis of swellings in the right iliac region.

B. Tuberculosis of mesenteric lymph nodes.— This is a rare entity and mainly seen in children. Tubercle bacilli (both human type and bovine types) enter the mesenteric lymph nodes through the Peyer's patches present in the terminal ileum. There are various types of presentation of this disease — (a) As a cause *of abdominal pain.*— This central constant abdominal pain is more of a discomfort than severe pain. On examination slight tenderness can be elicited in the umbilical region. Enlarged lymph nodes may be palpable as firm, discrete, round nodules on the right of the umbilicus. (b) As a cause *of general symptoms.*— Patient only presents with loss of weight, loss of appetite, pale and evening rise of temperature. (c) As a cause *of intestinal obstruction.*— A coil of small intestine may become adherent to a caseating node to become obstructed. (d) *Indistinguishable from appendicitis.*— Sometimes this condition may present with abdominal pain, vomiting and slight tenderness in the right iliac fossa mimicing appendicitis. That the pain is persistent in the same place, negative Rovsing's sign, no high pulse rate and no high leucocytosis go against the diagnosis of appendicitis. Straight X-ray may reveal calcified lymph nodes. (e) As *pseudomesenteric cyst.*— After caseation the cold abscess remains confined between the two leaves of the mesentery to form a cyst (mesenteric cyst).

DIVERTICULITIS.— The diverticula are pulsion diverticula and infection occurs secondarily in them. Diverticula appear most commonly in the sigmoid colon. These diverticula are due to excessive intracolonic pressure from thickened circular fibres which interdigitate with each other. This leads to excessive segmentations and an increase in the intracolonic pressure. Inflammation usually starts at the wall of the diverticulum and spreads in the pericolic tissue and mesenteric fat. The only symptom in the *diverticulosis stage* is rectal bleeding. This bleeding may be profuse and occurs due to trauma round the neck of the diverticula when it steps in and out through the defect in the muscle under varying degree of intra-luminal pressure. It must be remembered that profuse rectal bleeding in the elderly is more often due to diverticular disease than carcinoma.

Appearance of symptoms suggests that *diverticulosis has progressed to diverticulitis.* Intermittent abdominal pain especially in the left iliac fossa with flatulence and slight distension are the characteristic features of this condition. The pain may be due to over distension of an isolated section of the colon or due to a small localized abscess. Typically the bowel actions are small and leave a feeling of incompletion. The patient passes small, pebbly motion which may be accompanied by blood and/or mucus.

Peri-colonic abscess may develop with surrounding fibrosis and adhesion. A pelvic mass may result which may be felt both per abdomen and per rectum. This may even lead to intestinal obstruction. Rarely necrosis involves the whole of the diverticulum leading to perforation. The result of perforation may be anything from small localized abscess (commoner) to general peritonitis. This localized abscess may be absorbed on its own by conservative treatment or may become adherent to the bladder or another loop of bowel forming a vesico-colic or entero-colic fistula.

Sigmoidoscopy is important largely for its negative value in excluding carcinoma. It is difficult or may be impossible to pass the sigmoidoscope beyond the recto-sigmoid junction due to excessive spasm of the sigmoid colon.

Contrast radiography should be avoided in the acute stage. Barium meal follow through or barium enema may be helpful in diagnosing this condition. The latter is more useful in excluding carcinoma. In the first stage there may be small saw-tooth projections. Later large saw-tooth or accordion pleated outline will be obvious. In infective stage it shows a straight sigmoid colon without much convolutions and sacculations.

HIRSCHSPRUNG'S DISEASE or **primary megacolon.**— This condition is due to failure of proper development of the myenteric plexus of the bowel to migrate leading to aganglionosis of the distal part of the bowel. The pathology starts in the distal rectum and spreads to a variable distance proximally and even may spread into the small intestine. This leads to inability of the bowel to adequately contract which leads to failure in peristalsis. Constipation or inability to pass meconium is the hallmark of this disease. It is the commonest cause of intestinal obstruction in the new born babies. It shows a familial tendency and mostly occurs in the first year of life commonly within 3 days following birth. Occasionally if the defect is short enough, the condition may not be diagnosed until adult life; however there will be a history of constipation from first few days of life. Inability to pass meconium which can only be helped by insertion of a little finger or a tube into the rectum, is very suggestive. Progressive abdominal distension with visible peristalsis is the pathognomonic feature of this condition. Rectal examination reveals that the rectum is empty and contracted and the anus is normal. After withdrawal of the finger a large gush of flatus and meconium are passed. As the time passes by the abdomen becomes increasingly distended with borborygmi and visible peristalsis.

Acquired or secondary megacolon.— It occurs in older children and even adults. There is no aganglionic segment and hence colonic distension extends upto the anal canal. Rectal examination will reveal scyballous mass in the rectum and there may be anal fissure which indicates the cause of this condition.

ULCERATIVE COLITIS.— This disease affects women more often than men and maximum incidence is between 20-30 years. Patients present with mucous, blood stained or purulent diarrhoea. There may be abdominal discomfort or pain. The disease is characterized by remissions and relapses. It is rare in tropical countries like India. In chronic and recurrent type the patients gradually become wasted and anaemic from diarrhoea. In acute fulminating type patients run high temp. (103 - 104°F) and incessant diarrhoea containing blood and pus make the patients emaciated. The severity of the condition depends mainly on the extent of involvement of the disease, the depth of the mucosal ulceration and the age of the patient. When this condition is confined to the rectum and sigmoid colon it rarely causes severe illness. When the whole or a substantial portion of the colon is involved the attack is likely to be more severe with some systemic upset. Even though much of the colon is involved the illness can be mild if ulceration remains superficial. To the contrary, deep ulceration especially if the deep muscle is exposed over a moderately large area, severe illness will be the result. *Systemic manifestations* of this disease are erythema nodosum, pyoderma, arthritis etc. and these have no relation with the extent of the ulceration but with the extent of the involvement of the disease. Depletion of the protein is always expected resulting in loss of muscle bulk and loss of body weight. Colitis in the elderly tends to be much more dangerous than in younger patients.

Diagnosis is mainly confirmed by two investigations — (i) Barium enema and (ii) Sigmoidoscopy, colonoscopy & biopsy.

Barium enema.— It must be remembered that when the patient is extremely ill, preliminary straight X-ray is required. If they show colonic dilatation (megacolon), barium studies should

be judged to be contraindicated. In the early stage barium enema will fail to show any ulceration in chronic disease. The mucosal surface will appear smooth. But the colon becomes shortened and looses its haustral pattern. Later on, pseudopolyps may be shown as multiple small filling defects. In acute disease mucosal ulceration may be shown. There will be ulceration and pseudopolyposis.

As the rectum is almost invariably involved in ulcerative colitis, the disease can be diagnosed with confidence by *sigmoidoscopy and biopsy*. In mild cases, hyperaemia and granularity of mucosa can be seen. The mucosa becomes friable. In more severe conditions diffuse haemorrhagic inflammation becomes obvious. Ulcer exudate can be seen. Biopsy specimen may be taken either with bronchoscopy forceps or with a suction type of instrument.



Fig.34.38.— Barium enema X-ray showing multiple polyposis coli.

Complications are stricture, pseudopolyposis, carcinoma, haemorrhage, ischiorectal abscess, fistula-in-ano, arthritis, cirrhosis of liver, ankylosing spondylitis.

Ischaemic colitis.— Unlike mesenteric arterial obstruction, which is an acute condition, ischaemic colitis is a chronic condition. The reason is that the vascular occlusion is always incomplete as the collateral supply comes from the marginal artery of Drummond to allow the ischaemic bowel to recover.

The *signs* and *symptoms* are similar to other types of colitis. There is often left-sided abdominal pain and tenderness along the course of the descending colon, which is more often located in the region of the splenic flexure, as that is the watershed junction between the superior and inferior mesenteric arteries supply. Bloodstained diarrhoea is a common complaint. Later on there may be stricture formation at the site of ischaemic colitis leading to intestinal obstruction.

Polyps — of the intestine are best classified as follows :—

	SOLITARY	*MULTIPLE*
A.	Neoplastic —Adenoma, papillary adenoma, villous papilloma.	Polyposis coli.
B.	Hamartoma — Juvenile, Peutz-Zegher's.	Juvenile, Peutz-Zeghers'.
C.	Inflammatory — Benign lymphoid polyp.	Benign lymphoid polyposis, Pseudopolyposis of Ulcerative colitis.

FAMILIAL POLYPOSIS COLI — is a disease transmitted through genes. Multiple polyps are found mostly in rectum and sigmoid colon, but ultimately the whole colon will be involved. Patients present with diarrhoea containing mucus and blood from early age. Rectal examination will reveal one or more polyps. Sigmoidoscopy and barium enema X-ray (Fig. 34.38) will diagnose the case. Adenocarcinoma is a fatal complication of this disease.

CARCINOMA OF THE COLON.— The cauliflower or fungative type occurs in the right half of the colon and the annular or scirrhous type is encountered in the left half. Clinical features depend on whether the growth is in the right or left half of the colon. In the right half of the colon, the intestinal contents being of the fluid nature, obstruction is not an early feature although the growth is of the hypertrophic type. The patient complains of certain vague symptoms, such as loss of appetite, loss of weight, weakness, flatulence, dyspepsia, etc. Anaemia is often present. He may have diarrhoea alone or alternating diarrhoea and constipation. The most important diagnostic finding is the presence of a lump at the site of the caecum or ascending colon.



Fig.34.39.— Umbilical adenoma (Raspberry tumour).

In the left half of the colon, the contents being solid and the growth being of the annular type, the patient complains of increasing constipation requiring increasing dose of purgatives to move the bowel. No tumour is felt; what is felt is the loaded colon above the growth, as demonstrated by 'pitting on pressure' on the faecal matter. In either case, the diagnosis is confirmed by barium enema (or meal, in the case of the caecal growth) which reveals filling defect in the colon.

DISEASES OF THE UMBILICUS

A. **Umbilical Fistulas.**— (1) Faecal, due to patent vitello-intestinal duct. (2) Urinary, due to patent urachus. (3) Septic, due to infection, abscess formation and bursting. Sometimes umbilical calculus is formed inside the septic cavity. Any intra-abdominal abscess may leak through the umbilicus and form a sinus or fistula.

B. **Enteroteratoma** (syn. Umbilical Adenoma, Raspberry Tumour). (Fig. 34.39).— It is due to prolapse of the mucosa of the unobliterated distal end of the vitello-intestinal duct. (Persistence of the proximal part gives rise to Meckel's diverticulum*). It produces a red raspberry-like tumour with a tendency to bleed.

---

* **Meckel's Diverticulum.**— It occurs in about 2% of subjects, is about 2 inches long and is situated about 2 feet proximal to the ileocaecal junction at the antimesenteric border unlike jejunal diverticula which arise from the mesenteric border. It gives rise to following complications: (1) Meckel's diverticulitis resembling acute appendicitis; (2) Intestinal obstruction either by a band of fibrous tissue from the apex of the diverticulum, or by volvulus occurring around the band, or rarely by intussusception, the apex being formed by swollen heterotropic mucosa (the diverticulum itself may not be inverted); (3) Peptic ulcer resulting from the heterotropic gastric mucosa at the base of the diverticulum; this may lead to bleeding per anum or even perforation; (4) Littre's hernia — this term is applied when a Meckel's diverticulum lies within a hernial sac.

C. **Endometrioma.**— Diagnosis of this condition is suggested when a history of bleeding at each menstruation is obtained in women of child bearing age. It is associated with similar growth of the uterus or ovary.

D. **Carcinoma.**— (1) Primary growth may occur when the lymph nodes of both axillae and both groins are likely to be involved. (2) Secondary carcinoma may develop from primary in the stomach, colon, ovary or breast.

E. **Umbilical concretion (calculus).**— This occurs in those who do not maintain hygiene of the umbilicus and mainly affects old individuals. Black concretions develop inside the umbilicus which is formed by desquamated epithelium and dirt. It remains symptomless for years, but inflammation may supervene to cause abscess formation with discharge.

F. **Umbilical abscess** is a simple abscess of the umbilicus due to its poor hygiene. It is not synonymous with omphalitis which is a condition of new born baby where adequate aseptic precaution is not taken while severing the umbilical cord. The stump of the umbilical cord becomes inflamed. Umbilical abscess however may or may not be associated with umbilical calculus and purulent discharge.

G. **Pilonidal sinus.**— This sinus is very rarely seen in umbilicus when tuft of hair can be seen protruding through it. For characteristic features of this sinus see page 551.

Chapter

35 EXAMINATION OF AN ABDOMINAL LUMP

HISTORY.— See chapter 2 on "Examination of a Swelling", chapter 34 on "Examination of Chronic Abdominal Conditions" and chapter 37 on "Examination of a Urinary Case" to know various types of presentation.

PHYSICAL EXAMINATION

The general appearance of the patient has been discussed in the chapter of "Examination of chronic abdominal conditions".

EXAMINATION OF THE ABDOMEN

INSPECTION.— Besides the points which have already been discussed in the previous chapters, the followings should be particularly noted in a case of an abdominal lump :

1. **Condition of the skin over the swelling** — whether it is tense, red, shining or pigmented ? Are there engorged veins?

2. **Position, Size and Shape.**— Of these the position is the most important and should be described in relation to the nine anatomical regions of the abdomen (See Fig.35.1). Not much information can be elicited by inspection regarding size and shape.

3. **Movement with respiration.**— Swellings arising from the liver, gallbladder, stomach and spleen move well with respiration. Swelling in connection with the kidney or suprarenal moves very little with respiration.

4. **Visible Peristalsis.**— One should spend sometime inspecting the abdomen to detect visible peristalsis if present. Carcinoma at the pylorus of the stomach may present with visible peristalsis. Similarly carcinoma of the transverse colon may produce visible peristalsis. In the former case the peristalsis will be from left to right, whereas in the latter it will be from right to left. Rare cases of obstruction in intestine from malignant growth or enlarged lymph nodes may demonstrate similar visible peristalsis.

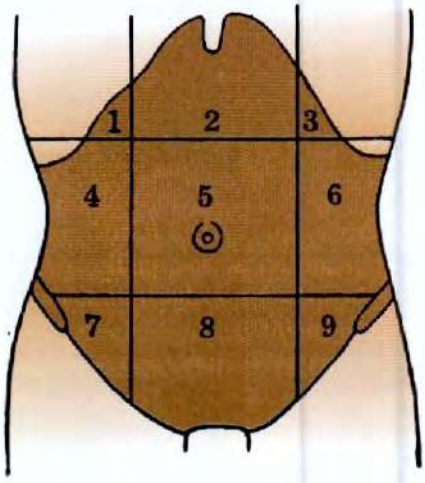

Fig.35.1.— The abdomen is divided into nine regions by two horizontal and two vertical lines. The upper horizontal or transpyloric line midway between the xiphisternum and the umbilicus, the lower horizontal or transtubercular line at the level of the two tubercles on the iliac crest about 2 inches behind the anterior superior iliac spines. The vertical lines are drawn on either side through the midpoint between the anterior superior iliac spine and symphysis pubis. The regions are : (1) Right hypochondrium, (2) Epigastrium, (3) Left hypochondrium, (4) Right lumbar, (5) Umbilical region, (6) Left lumbar, (7) Right iliac, (8) Hypogastrium, (9) Left iliac.

5. **The hernial sites.**— If the swelling is situated over one of the hernial sites, the patient is asked to cough to note the impulse on coughing. When the test is positive the case is one of a hernia. It must be remembered that a swelling over the hernial site may not necessarily be a hernia.

6. **The Scrotum.**— It should be made a routine to inspect the scrotum. Malignancy of the testis may lead to metastasis in the pre-and para-aortic lymph nodes. Swelling of these lymph nodes may be the first presenting symptom in these cases. If scrotum is not examined the entire diagnosis is missed.

7. **Left Supraclavicular lymph node.**— Before completing inspection, one should not forget to see the supraclavicular fossa particularly on the left side to detect if there is any swelling. These nodes are often secondarily involved (Troisier's sign) in breast carcinoma, abdominal carcinoma (especially of the stomach, pancreas or of the colon) and in malignant tumour of the testis. Involvement of these nodes gives a hint towards inoperability of the tumour.

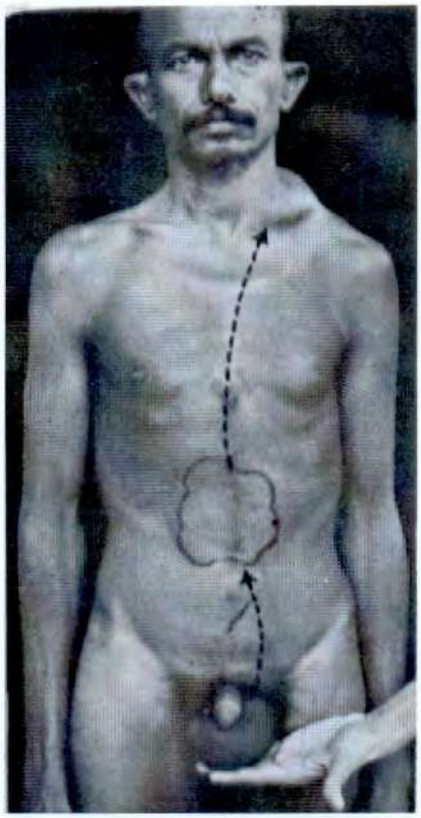

Fig.35.2.— The patient came with lumps in the abdomen and neck. Examination of the scrotum revealed a testicular growth. The lumps are obviously due to secondary deposit in the lymph nodes.

PALPATION.— Deep palpation (See page 362) is required to know details about an abdominal swelling.

1. **Local temperature.**— This is assessed as has been discussed in chapter 3. Local rise of temperature indicates inflammatory swelling.

2. **Tenderness.**— Pain on pressure is also a feature of an inflammatory swelling.

3. **Position, size, shape and surface.**— These are important and give definite clue to the diagnosis. Position indicates the organ that has been involved. Size, shape and surface give indications as to the underlying pathology.

4. **Margin.**— One must try to get all round the swelling. There may be difficulties when some part of the swelling disappears under the costal margin or the pelvis. Well-defined and distinct margin is a feature of neoplasm. Ill-defined margin is a feature of inflammatory or traumatic swelling.

5. **Consistency.**— Is the swelling soft, cystic, firm or hard ? Is it of same consistency throughout the swelling or there is variable consistency at different parts of the swelling. In case of a cystic swelling tests for fluctuation and fluid thrill should be performed. Of course if the cyst becomes tense, fluid thrill test may be negative and fluctuation will be difficult to elicit. Does the swelling pit on pressure? Pitting of the skin is the feature of a parietal abscess. Pitting on pressure can also be demonstrated in a colon loaded with faeces.

6. **Movement.**—

(a) *Does the swelling move with respiration or not*? Swelling associated with the liver, gallbladder, spleen and stomach are movable with respiration. This is an up and down movement and must not be confused with the anteroposterior movement of the abdominal wall during respiration. Place the hand over the lower border of the swelling and the patient is asked to



Fig.35.3.— The 'rising test' in which the patient raises his shoulder from the bed with the arms folded over the chest. This test is performed to know whether the swelling is parietal or intra-abdominal.



Fig.35.4.— The 'leg lifting test' (Carnett's test) to make the abdominal muscles taut to know whether the swelling is parietal or intra-abdominal.

take deep breath in and out. During inspiration the swelling will move downwards alongwith the downward excursion of the diaphragm. During expiration the swelling goes back to its normal position.

(b) *Is the swelling movable in all directions?* The swelling is held and tried to move in vertical and horizontal directions. Any restriction of movement is noted. A mesenteric cyst moves freely at right angle to the line of attachment of the mesentery but not so along the line (the line of attachment of the mesentery is an oblique line starting 1 inch to the left of the midline and 1 inch below the transpyloric plane and extending downwards and to the right for about 6 inches).

(c) *Is the swelling 'ballottable'?* One hand is placed behind the loin and the other hand in front of the abdomen and the swelling is moved anteroposteriorly between the two hands. A renal swelling is 'ballottable'.

7. **Parietal or intra-abdominal.**— The abdominal muscles are made taut by asking the patient either (i) to raise his shoulders from the bed with the arms folded over the chest — the 'rising-test' or (ii) to raise both the extended legs from the bed — the 'leg lifting test' (Carnett's test) or (iii) to try to blow out with his nose and mouth shut. If the swelling is parietal the swelling will be more prominent when the abdominal muscles are made taut and will be freely movable over the taut muscle. If the swelling is parietal but fixed to the abdominal muscle the swelling will not be movable when the muscles are made taut e.g. recurrent fibroid of Paget and haematoma in the rectus muscle. If the swelling disappears or becomes smaller when the abdominal muscles are made taut, the swelling is an intra-abdominal one. Another differentiating point is that if the swelling moves vertically with respiration it is obviously an intra-abdominal swelling.

8. **Is the swelling pulsatile or not?** A swelling in front of the abdominal aorta is pulsatile. This pulsation is 'transmitted' one. An aneurysm of the abdominal aorta is also pulsatile. But this pulsation is 'expansile' one. To differentiate between 'transmitted' and 'expansile' pulsations one may put index finger of each hand over the swelling. With each pulsation the two fingers will be diverted in 'expansile' pulsation whereas fingers will not be diverted in case of

'transmitted' pulsation (see page 32). Another differentiating point is to place the patient in "knee — elbow" position. A swelling in front of the abdominal aorta will be separated from the aorta and will become nonpulsatile, whereas an aneurysm will continue to pulsate.

9. A swelling at any of the **hernial sites** should be tested for expansile impulse on coughing and reducibility. These tests are positive in case of hernia.

10. Lastly **palpate the liver, the spleen** and **kidney** to ascertain the relationship of the tumour to these organs. Try to insinuate fingers between the swelling and the costal margin. This is possible more readily in case of renal swelling but hardly in cases of hepatic and splenic swellings.



Fig.35.5.— Demonstrating that the hand can be insinuated between the swelling and the costal margin in case of a renal swelling but not in case of a splenic swelling.

PERCUSSION.— A swelling arising from a solid organ will be dull on percussion if the swelling is quite superficial. If the coils of intestine overlie the swelling the percussion note will be resonant even if the swelling is a solid one. That is why a swelling arising from a liver or a spleen is dull on percussion whereas a renal swelling is resonant. Only if the kidney is considerably enlarged that the coils of intestine are moved aside and the swelling becomes dull on percussion, but even then a band of colonic resonance may be discovered. Another differentiating point between renal swelling and splenic swelling is to percuss the loin just outside the erector spinae. This area is normally resonant due to the presence of colon. In case of renal swelling this area will be dull as the colon is pushed out by the swelling but in case of a splenic swelling normal resonance is preserved.



Fig.35.6.— Percussing the loin just outside the erector spinae. This area is normally resonant. With a renal tumour the resonance is replaced by dullness but with a splenic enlargement the normal resonance is preserved.

Test for *shifting dullness* when free fluid is suspected in the peritoneal cavity. In ascites, dullness is present over the flanks and it shifts as the patient rolls over. In an ovarian cyst dullness is present over the centre and does not shift with the change of position of the patient.

Hydatid thrill is elicited by placing 3 fingers over the swelling and percussing over the middle one and after thrill will be felt by other 2 fingers. This test is rarely demonstrable.

The area of liver and splenic dullness should be marked out. The upper limit of the liver dullness is raised in subphrenic abscess, liver abscess and hydatid cyst occurring at the superior aspect of the liver.

Rectal and vaginal examination should always be carried out.

SPECIAL INVESTIGATIONS

(a) **Stomach and duodenum.**— See the last chapter.

(b) **Liver and gallbladder.**— Examination of the stool for *Entamoeba histolytica*, liver function test, straight X-ray of abdomen, cholecystography, aspiration of the liver and subphrenic abscess should be carried out. In a hydatid cyst of the liver, a history of an attack of urticaria, the presence of eosinophilia in the blood, a positive complement fixation test and Casoni's intradermal reaction are of great help in arriving at a diagnosis. Should the cyst be situated at the upper surface of the liver, X-ray will confirm the diagnosis. Liver scan and selective angiography will help in the diagnosis of liver swelling particularly if the case is one of carcinoma (primary or secondary). Stone in the gallbladder and bile duct as well as empyema of the gallbladder can be diagnosed by non-invasive technique like ultrasound.

(c) **Spleen.**— Examination of blood and estimation of platelet count, reticulocyte count, bleeding time, etc. are imperative.

(d) **Pancreas.**— X-ray examination with barium meal will reveal, in a lateral view, that the swelling is behind the stomach — pseudopancreatic cyst (Fig. 34.15). Examination of stool for the presence of muscle fibres and for estimation of fat and fatty acids, and examination of the urine for its diastase index and for sugar should be carried out. Carcinoma of the head of the pancreas can be diagnosed by hypotonic duodenography (see under the chapter of "Examination of Chronic abdominal conditions").

Carcinoma near ampulla of Vater can be diagnosed by I.V. cholangiography and percutaneous transhepatic cholangiography. Retrograde fibreoptic endoscopy will also reveal this condition. Retrograde endoscopic pancreaticocholangiography will help in the diagnosis of ca-ampulla of Vater, stone near the ampulla and chronic pancreatitis. Carcinoma of the pancreas can also be diagnosed by selective angiography and pancreatic scan. Pancreatic cyst can be conveniently diagnosed by ultrasound.

(e) **Colon.**— In addition to occult blood test of the stool and sigmoidoscopy, radiological examination should be made with barium meal for the proximal colon and with barium enema for the distal region. The contrast enema, i.e. introduction of air into the colon after the barium enema is partly evacuated, is a valuable method of investigation. A thin film of barium lining the lumen of the colon demarcates its outlines and any filling-defect is readily demonstrated.

(f) **Urinary Organs.**— See chapter 37 on 'Examination of a Urinary Case'.

DIFFERENTIAL DIAGNOSIS OF ABDOMINAL SWELLINGS

First ascertain the position of the swelling in respect to the nine anatomical regions of the abdomen and then whether the swelling is parietal or intra-abdominal. The causes and differential diagnosis of lumps in different regions of the abdomen are discussed below :

CAUSES AND DIFFERENTIAL DIAGNOSIS OF SWELLINGS IN THE RIGHT HYPOCHONDRIUM

A. PARIETAL SWELLINGS.— Besides the swellings involving the skin and subcutaneous tissue e.g. sebaceous cyst, lipoma, fibroma, neurofibroma, angioma, etc., as may occur in other situation, the special parietal swelling is a *cold abscess* arising from caries of the rib (commonly) or spine (rarely). It gives rise to a soft cystic and fluctuating swelling with no signs of inflammation. Irregularity in the affected rib or deformity of the spine, if present, clinches the diagnosis. An X-ray is helpful. A *hepatic, subphrenic* or *perigastric* abscess may burrow through

the anterior abdominal wall to form a parietal abscess.

B. INTRA-ABDOMINAL SWELLINGS.— They may occur in connection with (1) Liver, (2) Gallbladder, (3) Subphrenic space, (4) Pylorus of the stomach and duodenum, (5) Hepatic flexure of the colon, (6) right kidney and (7) right suprarenal gland.

(1) **Liver.**— Enlargement of the liver is determined by palpating its lower border and percussing its upper limit. Hepatic swellings are continuous with the liver dullness and move up and down with respiration. It is difficult to move the swellings sideways. Causes of enlargement of liver are many, but the important surgical conditions are considered here.

(a) *Congenital Riedel's* lobe is a tongue-shaped projection from the lower border of the right lobe of the liver. It is likely to be mistaken for an enlarged gallbladder but it is more wide and flat than the gallbladder and lacks the spherical outline of the distended gallbladder.

(b) *Amoebic hepatitis and abscess.*— The patient, who has suffered from amoebic dysentery months or years ago and now complains of pain in the right hypochondrium often referred to the right shoulder with rise of temperature, is probably suffering from amoebic hepatitis. When a swelling can be felt, an abscess has probably developed. The patient looks pale and slightly icteric. This will attract the attention of a keen observer. The liver is palpable and very tender. Even if the liver is not palpable, inter-costal tenderness may be elicited. Upper limit of liver dullness is raised. When an abscess develops the swelling becomes softer with extreme tenderness. Subcutaneous oedema which pits on pressure is an additional finding and should always be looked for. In X-ray screening the diaphragm is abnormally *raised* and *relatively immobile*. Presence of Entamoeba histolytica in the stool is diagnostic. Aspiration of anchovy sauce (chocolate colour) pus leaves no doubt about the diagnosis.



Fig.35.7.— Ultrasonography showing hydatid cyst in the liver.

(c) *Suppurative pylephlebitis.*— During the course of acute appendicitis or inflamed piles, if the patient suffers from a high rise of temperature with rigor one should suspect of this condition. The liver becomes palpable and tender.

(d) *Suppurative cholangitis.*— Usually a history of cholelithiasis is received. The stone becomes impacted in the common bile duct. There will be high rise of temperature and the liver becomes tender. Jaundice is usually associated with.

(e) *Gumma of the liver.*— This condition is very rare now a days. It resembles carcinoma having no symptom in the early stage. It is a manifestation of third stage of syphilis, WR and



Fig.35.8.— Ultrasonography showing calcified hydatid cyst of the liver which is affecting the right lobe of the liver very near to diaphragm.

(g) *Carcinoma of the Liver.*— Primary carcinoma is rare. It may be a hepatoma or cholangioma. Secondary carcinoma of the liver is much commoner and results from metastasis from carcinoma of the gastro-intestinal tract via portal vein or from organs like breast through lymphatics. In this condition the liver is enlarged, irregular with nodules of varying size and shape and becomes hard. The nodules may show softening in the centre and may become umbilicated. The patient may be jaundiced sooner or later and ascites may be associated with. Primary focus should be searched Kahn test will be positive. Presence of other syphilitic stigmas confirm the diagnosis.

(f) *Hydatid cyst.*— When it occurs near the lower margin of the liver it gives rise to a palpable spherical and smooth swelling, with hydatid thrill and fluctuations. Diagnosis is made by the history of attack of urticaria, eosinophilia, complement fixation test and Casoni's intradermal reaction. X-ray and ultrasound are helpful when the cyst occurs at the upper surface of the liver. If suppuration takes place the signs and symptoms of infection may dominate the picture.



Fig.35.9.— Ultrasonography of the abdomen showing a typical hydatid cyst of the liver affecting upper part of the right lobe of the liver very close to the diaphragm (DIP).

for and its recovery clinches the diagnosis.

(h) *Melanotic carcinoma of the liver.*— It occurs secondary to similar growth on the palm, foot or eye. An enlarged liver with malignant melanoma anywhere in the body should clinch the diagnosis.

(i) *Cirrhosis of the liver.*— It must be remembered that in this condition the liver is not always enlarged; on the contrary it may be shrunk. In pre-cirrhotic stage the liver may be firm, irregular with small nodules which are never umbilicated (cf. carcinoma). Portal hypertension will be present with enlargement of the spleen. Ascites may be associated with but jaundice is never present. These cases often come to the surgical clinic with haematemesis from rupture of oesophageal varices.



Fig.35.10.— Ultrasonography showing multiple liver metastasis.

(2) **Gallbladder.**— It feels as an oval smooth swelling which is tense and cystic. It comes out of the lower border of the liver and moves freely up and down with respiration along with liver. The swelling may be tender depending on the amount of inflammation present. It can be moved sideways a little. It is not ballottable as a kidney swelling. Diagnosis as to the cause of gallbladder swelling has been discussed in the previous chapter.

(3) **Subphrenic abscess.**— There are innumerable causes of accumulation of pus under the diaphragm. Majority follow intraperitoneal conditions e.g. perforated peptic ulcer (commonest), following abdominal trauma, following operations on biliary tract, following operation on the stomach or colon and acute appendicitis. Diagnosis mainly depends on suspicion. The patient looks very much anxious and drawn. They may complain of anorexia and nausea. A rise of temperature is always associated with. But its degree varies — there may be high rise of temperature with rigor, sweating and rapid pulse, or there may be slight rise of temperature but the patient always looks abnormally ill. Rigor only occurs when there is concomitant pylephlebitis or a liver abscess. More important indicator is the pulse rate which always becomes abnormally fast irrespective of the temperature. Tachypnoea is also often present. Pain is not a very prominent feature and should not be much relied on so far as the diagnosis is concerned. If present, it usually becomes localized to the site of lesion. Right hypochondrium or epigastrium is the usual site of pain. Very occasionally it may be complained of in the lower part of thorax, right lumbar region or even referred to the right shoulder. Jaundice is not a sign of this condition but if present indicates obstruction of the common bile duct with a stone or suppurative pylephlebitis.

Tenderness just below the costal margin or xiphoid process or more precisely tenderness over the IIth intercostal space though suggestive of this condition yet may be absurd. X-ray screening will show sluggish movement of the diaphragm. The diaphragm becomes raised and gas may be found beneath it. Aspiration of pus from the subdiaphragmatic space leaves no doubt about the diagnosis.

(4) **Pylorus of the stomach and duodenum.**—

(a) *Carcinoma* — of this region usually gives rise to obstructive symptoms. The details of manifestations of carcinoma of the stomach have been discussed in earlier chapter. Barium meal X-ray will show 'filling-defect' which is very diagnostic.

(b) *Subacute perforation of peptic ulcer* forms a localized tender mass which is a rare condition. The patient gives history suggestive of peptic ulcer and sudden excruciating pain before formation of the mass. It may lead to a subphrenic abscess.

(5) **Hepatic flexure of the colon :**

(a) *Intussusception* (see page 477).

(b) *Hypertrophic tuberculosis.*— This usually starts in the ileo-caecal region and may move up into this region. See the right iliac fossa for more description.

(c) *Carcinoma of this part of the colon* may present with a lump only or with anaemia, anorexia and occult blood in the stool. The lump is irregular and hard with slight or no movement. Barium enema X-ray reveals constant filling defect which is very diagnostic.

(6) **Kidney.**— The features of a kidney swelling are: (i) It is a reniform swelling; (ii) It moves very slightly with respiration as it comes down a little at the height of inspiration; (iii) It is ballottable; (iv) A sickening sensation is often felt during manipulation; (v) A hand can be easily insinuated between the upper pole of swelling and the costal margin; (vi) Percussion will reveal resonant note in front of a kidney swelling as coils of intestine and colon will always be in front of the kidney.



Fig.35.11.— Ultrasonography showing multiple metastases in the liver.

As regards the different causes of kidney swelling and differential diagnosis the reader is referred to the chapter on "Examination of a Urinary Case".

Suprarenal tumours.— Suprarenal gland has got a cortex and a medulla. *In the adrenal cortex* the causative lesion may be bilateral hyperplasia, a benign adenoma or a malignant carcinoma. *In the medulla* phaeochromocytoma, which is usually a benign tumour, a benign ganglio-neuroma or malignant neuroblastoma may appear. Hyperplasia of the medulla, though

described, is exceedingly rare. The clinical syndromes vary with the hormones which are produced. Thus in the lesions of the cortex, excess of aldosterone causes aldosteronism, excess of cortisol causes Cushing's syndrome, excess of androgen causes andrenogenital syndrome and excess of oestrogen causes feminisation in the male. In medullary tumours the clinical features depend on the relative amounts of adrenaline and noradrenaline which are produced.

CAUSES AND DIFFERENTIAL DIAGNOSIS OF THE SWELLINGS IN THE EPIGASTRIUM

A. **PARIETAL SWELLINGS.**— In addition to the swellings discussed under the right hypochondrium i.e. tumours of the skin and subcutaneous tissue, cold abscess, hepatic, subphrenic and perigastric abscesses, the swelling peculiar to this region is the epigastric hernia.

Epigastric hernia.— The usual sufferer is a strong muscular labourer. He presents with a small round swelling exactly in the midline anywhere between the xiphisternum and umbilicus. In the first stage, it is sacless herniation of the extraperitoneal fat through a weak spot in the linea alba. There is no symptom at this stage. In the second stage, a pouch of peritoneum is drawn after it. In the last stage, a small tag of omentum gets into the sac and becomes adherent to it. At this stage the patient complains of dragging pain, discomfort or pain after food, not unlike those in peptic ulcer.

B. **INTRA-ABDOMINAL SWELLINGS.**— They occur in connection with the : (1) liver and subphrenic space, (2) stomach and duodenum, (3) transverse colon, (4) omentum, (5) pancreas, (6) abdominal aorta, (7) lymph nodes and (8) retroperitoneal structure.

1. **Liver** and **subphrenic abscess** have been discussed in the previous section.
2. **Stomach** and **duodenum.**—

(a) *Congenital pyloric stenosis.*— Babies about 2 to 4 weeks old when present with projectile vomiting after meals, the diagnosis becomes obvious. On examination visible peristalsis of the stomach is always seen. Sometime a definite lump may be felt at the pylorus of the stomach.

(b) *Subacute perforation of peptic ulcer.*— See 'Swellings in the right hypochondrium'.

(c) *Carcinoma of the stomach.*— See 'Swellings in the right hypochondrium'.

3. **Transverse colon.**— Intussusception, diverticulitis, hyperplastic tuberculosis and neoplasms are the causes of swellings which may originate from the transverse colon. In intussusception there will be emptiness at the right iliac fossa. The patient complains of colicky pain, a lump in the epigastrium and "red currant jelly" in the stool. In inflammatory conditions a tender and irregular mass may be felt. In carcinoma the swelling is the presenting symptom. The swelling is irregular, hard and may be mobile above downwards and very slightly in the sideways or may be fixed. Anaemia, anorexia and occult blood in the stool are the features which help in the diagnosis. Barium enema X-ray reveals constant 'filling-defect' of the colon.

4. **Omentum.**— In the tubercular peritonitis, the omentum is rolled up to form a transverse ridge in the epigastrium. Enlarged lymph nodes or adherent coils of intestine are also come across in this condition.

5. **Pancreas.**— It hardly gives rise to a palpable swelling. The condition that forms lump in connection with this organ is the *pseudopancreatic cyst. True cyst* of the pancreas is extremely rare. The pseudocyst is a collection of fluid in the lesser sac of the peritoneal cavity resulting from acute pancreatitis or trauma. It forms a smooth rounded swelling with fluctuation test positive. X-ray with barium meal will show the exact position of the swelling which is situated behind the stomach and is best seen in the lateral X-ray.

6. **Abdominal aorta.** — Aneurysm of this part of the aorta is not uncommon. It presents a swelling in the epigastrium with characteristic expansile pulsation. This pulsation should be differentiated from transmitted pulsation caused by a swelling, just in front of the aorta. Knee-elbow position is of great help in this respect. The swelling in front of the aorta will hang loose forward leaving contact with the aorta, hence losing its pulsatile property. Whereas an aneurysm of the aorta will be still pulsatile.



Fig.35.12.— Ultrasonography of the abdomen showing pseudocyst of the pancreas in the lesser sac of the peritoneum which has extended to in front of the left kidney.

7. **Lymph nodes.**— In addition to the usual causes of enlargement of lymph nodes, the followings are more important in this region : (i) tabes mesenterica, (ii) lymphosarcoma and (iii) secondary malignant growth from the neighbouring organs and also from the testis.

8. **Retroperitoneal sarcoma** and **teratoma** are the two conditions commonly seen in the posterior abdominal wall arising from the retroperitoneal tissue.

CAUSES AND DIFFERENTIAL DIAGNOSIS OF SWELLINGS IN THE LEFT HYPOCHONDRIUM

A. **PARIETAL SWELLINGS.**— As on the right side.

B. **INTRA-ABDOMINAL SWELLINGS.**— These swellings occur in connection with the (1) spleen, (2) stomach, (3) left lobe of liver, (4) splenic flexure of the colon, (5) tail of the pancreas, (6) left subphrenic space, (7) left kidney and (8) left suprarenal gland.

(1) **Spleen.**— An enlarged spleen is differentiated from a renal swelling by the following points : (i) The spleen enlarges towards the umbilicus i.e. downwards, forwards and inwards, whereas the kidney enlarges forwards and directly downwards towards the iliac fossa. (ii) A splenic swelling is smooth and uniform, its anterior border is sharp with *one or more notches* — the characteristic feature of this organ. (iii) *On inspection*, a splenic swelling moves more freely with respiration than a renal swelling, (iv) *In palpation*, the spleen is palpated more easily from the anterior aspect and the kidney from the posterior aspect, as the spleen lies just under the anterior abdominal wall and the kidney on the posterior abdominal wall. (v) Further, for the same reason the hand can be insinuated between the swelling and the costal margin in case of the kidney but not in the case of the spleen. (vi) Always look for the notches while palpating

a splenic swelling. (vii) *On percussion on anterior abdominal wall,* the splenic swelling is dull all throughout but in case of a renal swelling a band of colonic resonance is obtained. (viii) The loin just lateral to the erector spinae is resonant in splenic swelling but dull in renal swelling.

Causes of enlargement of the spleen are many. Malaria and kala-azar are common in this country but are of little surgical importance. Only the conditions of surgical importance are described below :

(a) HAEMOLYTIC ANAEMIA.— There are two forms of this disorder : (i) congenital (hereditary spherocytosis) and (ii) acquired.

(i) *HEREDITARY SPHEROCYTOSIS.*— The main pathology is congenital increase in permeability of the red cell membrane to sodium. As sodium leaks into the cell its osmotic pressure rises, the cell swells, becomes spherical and more fragile. In this condition the energy and oxygen requirement of the red cells increase. In the spleen there is deficiency of both glucose and oxygen in the pulp and therefore a large number of red cells are destroyed. Splenectomy reduces red cell destruction. Though it does not cure the congenital red cell membrane defect yet it makes the red cell survival time normal and thus lessens anaemia. This defect is transmitted as a Mendelian autosomal dominant. The circulating excess bilirubin remains unconjugated with glycuronic acid and is attached to albumin. This is not excreted through urine. Hence it is called acholuric jaundice.

The patients present with anaemia and jaundice. A family history may be elicited. Though it is a congenital condition yet it may not be manifested before puberty or even adult life. In adult cases there is often a history of biliary colic. In fact about 70% of untreated cases may show pigment stone in the gallbladder. Sometimes a severe crisis of red cell destruction is come across. The R.B.C. count may fall down to 2 millions during the attack. Such attacks are characterized by abdominal pain, nausea, vomiting and pyrexia besides usual extreme pallor and jaundice. These crises may be precipitated by acute infection and may be as dangerous as to cost lives.

On examination, the spleen is always large. The liver may be palpable and chronic ulcers of the legs are often seen in adult sufferers.

The fragility test will show increased fragility of the R.B.C.s. Normal erythrocytes begin to haemolyse in 0.47 per cent saline solution, whereas in this condition haemolysis occurs in 0.6. per cent or even stronger solution.

The reticulocyte count will give an index as to the severity of this condition. After a crisis the count will be greatly increased. *Faecal urobilinogen* is increased as most of the urobilinogen is excreted by this route.

Measurement of faecal urobilinogen, if made possible, is the best guide to the extent of haemolysis in this condition. Finally use of radioactive chromium (^{51}Cr) by labelling the patient's own red cells and by daily scanning over the spleen will show the degree of red cell sequestration by the spleen. If the sequestration is high, splenectomy can be considered.

(ii) *ACQUIRED HAEMOLYTIC ANAEMIA.*— In this condition auto-antibodies are produced which attach themselves to the circulating erythrocytes and this results in their early dissolution. In this condition Coombs' test is usually, but not always positive. The patients are usually middle-aged or elderly subjects. Family history is usually absent. The spleen is palpable in 50% of cases. The liver may also be palpable and there is sometimes generalized enlargement of the lymph nodes.

(b) IDIOPATHIC THROMBOCYTOPENIC PURPURA.— The disease manifests itself by haemorrhages of all grades of severity. It may occur in acute form which is mostly seen in children. Acute episode consists of cutaneous purpura, bleeding from the oral mucous membrane and epistaxis. This condition is also seen in chronic form which is the disease of the adult. The

attacks tend to come in cyclic order and relapses are of increasing severity. Ecchymoses or purpuric patches in the skin and the mucous membrane are the main manifestations of this disease. These lesions are mainly seen in the dependent areas due to increased intravascular pressure. Sustained bleeding from the wounds which may even be trifle is also a noticeable feature. Bleeding from the mucous membrane either from the gums or in the form of epistaxis or in the form of menorrhagia is not uncommon. Urinary and G.I. tract haemorrhages are rare, similarly rare is haemarthrosis. On examination there is hardly any abnormality detected except that the tourniquet test becomes positive. Enlargement of spleen is hardly noticed if so the spleen becomes just palpable and never hugely enlarged. So a huge spleen makes the diagnosis of thrombocytopenic purpura improbable.

In the *tourniquet test,* the cuff of a sphygmomanometer is applied to the upper arm and inflated to just below the systolic blood pressure for 10 minutes. This causes venous obstruction. Within 5 minutes petechial haemorrhages occur in the skin below the cuff. This test indicates excessive capillary fragility.

SECONDARY PURPURA is sometimes seen in conditions like acute septicaemia; tuberculosis; brucellosis; Boeck's sarcoid; idiosyncrasy to certain drugs like alkylating agents, quinine and arsenical; associated with extensive burns; leukaemia; carcinomatosis of bone; X-ray therapy etc. Senile purpura and Henoch-Schoenlein purpura are also examples of this condition.

(c) PORPHYRIA.— It is an inborn error of catabolism of haemoglobin. The main surgical importance is the association of abdominal crisis with this condition. The crisis is characterized by intestinal colic with constipation. The patient is anaemic with neurological and mental symptoms. Splenic enlargement is a well marked feature and should always be looked for. This will save many unnecessary laparotomies from misdiagnosis. Slight jaundice following an abdominal pain is not unusual.

(d) EGYPTIAN SPLENOMEGALY.— This condition is due to infestation by schistosoma mansoni (in majority of cases) and schistosoma haematobium (in ¼ of cases). Enlargement of the spleen with hypochromic anaemia, eosinophilia, leukopenia and lymphocytosis are the usual features. The liver is moderately enlarged in ¾ of the cases. In late cases there will be enormous enlargement of the spleen and ascites due to liver atrophy.

(e) FELTY'S SYNDROME.— Chronic rheumatoid arthritis, leukopenia and enlargement of the spleen constitute this syndrome. Associated pyogenic infections, infected ulcers around the ankles, anorexia, loss of weight and enlargement of lymph nodes help in the diagnosis.

(f) LEUKAEMIA is characterized by a pronounced hyperplasia of the precursors of the white blood corpuscles throughout the entire reticulo-endothelial system. Two types are known — myeloid and lymphatic. The spleen is grossly enlarged in case of the former and not so in case of the latter. The blood count will reveal large number of white cells in both the types with more percentage of myelocytes in myeloid leukaemia and very high percentage of lymphoblasts in lymphatic leukaemia. Splenectomy is of doubtful value.

(g) TUMOURS AND CYSTS are rare in spleen.

Swellings in connection with other organs are discussed under the right hypochondrium.

CAUSES AND DIFFERENTIAL DIAGNOSIS OF SWELLINGS IN THE LEFT AND RIGHT LUMBAR REGIONS

A. **PARIETAL SWELLINGS.**— A *lumbar abscess* (cold) resulting from Pott's disease gives rise to a swelling which requires to be differentiated from a *lumbar hernia.* Both these conditions

produce impulse on coughing. The hernia is reducible and tympanitic, whereas the abscess is partially reducible and dull on percussion. The features of caries spine — deformity, tenderness, and rigidity will clinch the diagnosis. X-ray will show characteristic bony changes in Pott's disease.

B. **INTRA-ABDOMINAL SWELLINGS.**— These swellings develop in connection with the ascending or descending colon, right or left kidney. In addition, swellings from the neighbourhood may extend to this region e.g. the liver, gallbladder on the right side and the spleen on the left side. These are discussed in appropriate sections.

CAUSES AND DIFFERENTIAL DIAGNOSIS OF SWELLINGS IN THE UMBILICAL REGION

A. **PARIETAL SWELLINGS.**— Those occurring in connection with the umbilicus and rectus sheath are important.

Umbilicus.— *Congenital polyp* or *adenoma* may occur in association with patent umbilical end of the vitelline duct. Sometimes a granulomatous mass resulting from deep seated infection, may look an adenoma.

Umbilical hernia.— Three types are recognized : (a) congenital, (b) infantile and (c) para-umbilical hernia of the adult. The last type is described here. The classical patient is fat multiparous female above the age of 40. The hernia is usually seen just above the umbilicus where the two recti divaricate and this allows the hernia to come out. The two classical signs are always present i.e. expansile impulse on coughing and reducibility. Irreducibility and incarceration (obstruction) are the two frequent complications. The clinician is warned against the diagnosis of incarceration, as the real event may be strangulation and valuable time may be lost by giving enema, waiting for the result and doing this or that. Incidence of strangulation is less in this hernia than in inguinal or femoral hernia.

Postoperative or incisional hernia.—This hernia comes out through an incisional scar. The wall of this hernia consists of fibrous tissue and the contents may be adherent. These are readily diagnosed by the presence of scar with a history of previous operation, expansile impulse on coughing and reducibility.

Rectus sheath.— *Haematoma* in the sheath resulting from trauma or following convulsion of tetanus and strychnine poisoning has been recorded. Tearing of the inferior epigastric artery will cause haematoma in the lower abdomen below the arcuate line. Following a severe bout of coughing or a sudden blow to the abdomen may cause an exquisitely tender lump in relation to the rectus abdominis. There will be bruising of the skin with discolouration suggesting a haematoma underneath.

Abscess within the rectus sheath though rare should be borne in mind.

Desmoid tumour is a type of fibroma which is not encapsulated and is hard. It arises from the deeper part of the rectus abdominis. Majority of the patients are women and have already borne children. This tumour also arises from the scar of the operational wound. Some form of trauma either stretching of the muscle fibres during pregnancy or operational wound will cause haematoma within the muscle fibres which may initiate the tumour formation. This tumour is notorious to recur after excision and is also called 'Recurrent fibroid of Paget'. So it requires wide excision. The recurrent growth is more malignant than the original one.

B. **INTRA-ABDOMINAL SWELLINGS.**— These may develop in connection with the (1) stomach and duodenum, (2) transverse colon, (3) omentum, (4) small intestine and mesentery,

(5) lymph nodes, (6) pancreas, (7) aorta and (8) retroperitoneal connective tissue. Swellings from the neighbourhood when much enlarged may invade this region e.g. splenic, renal, uterine and ovarian swellings.

Small intestine and mesentery.— In this group tuberculosis of the intestine together with tabes mesenterica, tumours of the small intestine, intussusception and cysts of the mesentery are included.

Matted coils of intestine with tuberculous mesenteric lymphadenitis is generally presented with a lump. The patient is usually a child. A pale looking child with loss of appetite, loss of weight and evening pyrexia is probably suffering from this condition. Sometimes the pain becomes the main symptom and on deep palpation infected mesenteric lymph nodes may be palpable. Each node is round or oval without regular outline and is not homogeneous. Radiologically calcified tuberculous lymph nodes may be seen. For calcification to occur in lymph nodes it takes about a year or more. So absence of calcified lymph node radiologically does not exclude this condition.

Tumours of the small intestine are rare compared to the large intestine. Even if they appear they hardly produce a palpable lump till late stage. Adenoma, submucous lipoma and leiomyoma are the benign tumours but they do not produce any palpable swelling. The tumours which may produce palpable lumps are lymphosarcoma and spindle-cell sarcoma. Carcinoma is very rare and only becomes palpable in late stage.

Cysts of the mesentery may be of various types of which chylolymphatic, enterogenous (derived from a diverticulum on the mesenteric border of the intestine) and dermoid (teratoma) cysts deserve mentioning. Besides these, tubercular abscess of the mesentery and hydatid cyst of the mesentery are rarely seen. These present as painless abdominal swellings, which are fluctuant and are situated near the umbilicus. The swellings move freely at right angle to the line of attachment of the mesentery but a little along the line of attachment. These cysts will be dull on percussion but will be surrounded by band of resonance. Recurrent attacks of abdominal pain may also be the presenting symptom. Temporary impaction of a food bolus in a segment of bowel narrowed by the cyst may produce features of intestinal obstruction. Torsion of the mesentery may produce acute abdomen which demands immediate relief. Rupture of the cyst and the haemorrhage of the cyst are the two complications of this condition which may give rise to acute abdominal catastrophe. Barium meal X-ray will show coils of intestine to be displaced around the cyst. A portion of the intestine may be shown to be narrowed.

Retroperitoneal connective tissue.— *Retroperitoneal cyst.*— A cyst developing in the retroperitoneal tissue may attain very large dimensions. Pyelography may be required to differentiate cyst from a hydronephrosis. These cysts may be derived from remnants of the Wolfian ducts when the containing fluid will be clear or the cyst may be a teratoma when it is filled with sebaceous material.

Retroperitoneal lymphoma — mainly affects women and will also require pyelography for differential diagnosis.

Retroperitoneal sarcoma — presents with similar features as the previous one. An indefinite abdominal pain or subacute intestinal obstruction from pressure on the colon may be the presenting symptom. On examination, a fixed smooth swelling may be discovered which will require pyelography to rule out the possibility of a renal swelling.

CAUSES AND DIFFERENTIAL DIAGNOSIS OF SWELLINGS IN THE RIGHT ILIAC REGION

A. **PARIETAL SWELLINGS.**— There is no special parietal swelling in this region. An *iliac abscess* (pyogenic) or an *appendicular abscess* may burrow through the anterior abdominal wall and may become parietal. Inguinal swellings are discussed elsewhere.

B. **INTRA-ABDOMINAL SWELLINGS.**— These swellings may develop in connection with the structures which normally present in this region or may originate from organs lying in other regions and abnormally invade this region.

The structures which normally present in this region are : (1) the appendix, (2) caecum, (3) terminal part of the ileum, (4) lymph nodes, (5) iliac arteries, (6) retroperitoneal connective tissue, (7) iliopsoas sheath and (8) ilium (os ilii).

Swellings arising from organs lying in other regions which may invade right iliac region are : (1) renal swelling (unascended), (2) gallbladder swelling, (3) uterine swelling, (4) urinary vesical swelling, (5) undescended testis and (6) pelvic abscess.

Appendix.— Appendicular lump is the commonest swelling in the right iliac region. The lump may be either an appendicular mass or an appendicular abscess. The appendicular mass gradually develops on third day or earlier after commencement of an attack of acute appendicitis. The mass invariably coincides with the position of the appendix. There will be rigidity of the abdominal musculature, beneath which the tender mass may not be so easy to feel. The mass consists of inflamed appendix, greater omentum, oedematous caecal wall surrounded by coils of small intestine matted together with lymph. This is an attempt by the nature to make a protective wall around the inflamed appendix to prevent general peritonitis even if the appendix perforates. With conservative treatment gradually the mass becomes smaller and disappears. This can be verified by outlining the mass with a skin pencil. The lump is irregular, firm, tender, and fixed. It may be tympanitic on percussion, but it is so tender that the patient may not allow proper percussion to be performed. This appendicular mass should not be confused with appendicular abscess. Variable pyrexia and increase in the number of leucocytes with polymorphonuclear leucocytosis are features of appendicular abscess. Whereas appendicular mass does not contain any pus at all, the appendicular abscess contains pus. Appendicular abscess tends to approach towards the surface when inflammatory signs i.e. redness and oedema of the abdominal wall become evident.

Ileocaecal region.—

(a) *HYPERPLASTIC ILEOCAECAL TUBERCULOSIS.*— In this condition infection starts in the lymphoid follicles and then spreads to the submucous and subserous planes. The intestinal wall becomes thickened with narrowing of its lumen. There will be early involvement of regional lymph nodes which become matted along with the involved terminal part of ileum and caecum to produce the lump.

Recurrent attacks of abdominal pain with diarrhoea and features of blind loop syndrome (i.e. anaemia, loss of weight and steatorrhoea) are the usual complaints. Along with these symptoms a lump in the right iliac fossa with ill health and evening rise of temperature should arouse the suspicion of this condition.

This condition should be differentially diagnosed from Crohn's disease, actinomycosis and carcinoma of the caecum. In Crohn's disease the caecum remains in its position and is not elevated as in this condition. Anal complications such as fissure and multiple fistulae are mainly seen in Crohn's disease. Fistulae may even be seen in the right iliac fossa in Crohn's disease. Carcinoma of the caecum is a disease of the elderly. Occult blood in the stool with anaemia

and rapid loss of weight are features of this condition. The lump, if felt, is hard, irregular and fixed (at a later stage). Moreover features of tuberculosis will always be present in hyperplastic ileocaecal tuberculosis. Barium meal X-ray and follow through can categorically differentiate these conditions. In hyperplastic ileocaecal tuberculosis a long narrow constricted terminal ileum and ascending colon with caecum in high up position can be noticed. In Crohn's disease a narrow and smooth terminal part of ileum (string sign of Kantor) can be seen. This part of ileum will be devoid of peristaltic waves and caecum will be normal in majority of cases (cf. Hyperplastic ileocaecal tuberculosis). In carcinoma of the caecum there will be an irregular filling defect affecting the caecum with soft tissue shadow showing the extent of the tumours but terminal part of ileum is absolutely normal.

(b) *AMOEBIC TYPHLITIS.*— This condition hardly produces a lump. Diarrhoea is the main manifestation of this disease. In tropical countries where amoebiasis is endemic this is a constantly recurring problem. One must be very careful to exclude this condition before one does appendicectomy. Patient complains of pain mainly over two places — over the caecum and the sigmoid colon. On examination, a thickened and tender colon may be palpable. Sigmoidoscope is of great help in diagnosis. Rectal haemorrhage, fibrous stricture, intestinal obstruction, paracolic abscess, ischio-rectal abscess and fistula (from perforation by amoebae of the intestinal wall followed by secondary infection) and even perforation are the complications of amoebic typhlitis.

(c) *CROHN'S DISEASE OR REGIONAL ILEITIS.*— The clinical feature can be best classified into four stages: (i) *Inflammatory stage,* when a tender mass is palpable in the right iliac fossa. The patient will run temperature and there will be moderate anaemia. This condition is very much similar to acute appendicitis barring the fact that the patient will be having diarrhoea instead of constipation. (ii) *The colitis stage,* when diarrhoea, fever, anaemia, loss of weight etc. are present. Occult blood and mucus may be present in the stool. Majority of the patients will suffer from steatorrhoea. High incidence of fissure-in-ano, perianal abscess and fistulae is significant diagnostic point at this stage. (iii) *The stenotic stage,* when the picture of small intestinal obstruction may supervene. (iv) *The fistulae,* either external or internal communicating with the sigmoid colon, the caecum, the urinary bladder etc. are not infrequent in the late stage. Barium meal X-ray will reveal loss of peristalsis in the affected loop and the string sign of Kantor when the lumen is narrowed to a fine cord (Fig. 35.13).



Fig.35.13.— Barium meal X-ray showing Crohn's disease affecting the terminal part of the ileum producing the typical 'string sign of Kantor'.

(d) *CARCINOMA OF THE CAECUM.*— Usually the patient is above 40. The lump may be the first indication of this disease. There may not be any change in the bowel habit. If present, alternate constipation and diarrhoea may be the complaint. Anaemia, anorexia, and loss of

weight are the associated signs and symptoms of this condition. Occult blood in the stool is a diagnostic point in special investigation. Barium meal X-ray will show 'filling defect' in the caecum which is the main diagnostic feature of this condition. Soft tissue shadow of the tumour may be seen in case of a big lump.

(e) *ACTINOMYCOSIS* of the caecum and appendix may give rise to a hard and fixed mass in the right iliac fossa. Multiple sinuses are seen discharging sulphur granules. Discolouration of the affected skin is often noticed. This condition may follow after operation of the appendix.

(f) *IMPACTION OF ROUND WORMS* in the lower part of the ileum often produces a lump. History of passing worms with stool or vomiting is often obtained.

Lymph nodes.— Enlargement of the iliac group of lymph nodes may produce lump in this region. The details of causes of enlargement of lymph nodes have been discussed in chapter 8 of 'Examination of the lymphatic system'. Filariasis, lymphosarcoma, secondary carcinoma and tuberculosis are the main causes of enlargement of lymph nodes in this region. Filarial nodes are suspected when the patient suffers from periodic attacks of fever with simultaneous tenderness and swelling of the nodes. Eosinophilia and demonstration of microfilaria in blood drawn at night will clinch the diagnosis. Lymphosarcoma gives rise to rapid enlargement of the nodes without other complaints in the young subject. Secondary carcinoma will be felt as a hard, nodular and fixed mass. Primary growth should be looked for and if found settles the diagnosis. Tuberculous nodes will be associated with other tuberculous features. These nodes may soon often produce cold abscess which shows a tendency to burrow through the tissues to come more superficially and gives rise to a cold abscess in the parietes.

Iliac arteries.— Aneurysm of iliac artery is rare but easy to recognize by expansile pulsation.

Retroperitoneal sarcoma.— See page 532.

Iliopsoas sheath.— Two conditions — iliac abscess of pyogenic origin and iliopsoas cold abscess from Pott's disease — should be considered here.

ILIAC ABSCESS results from infection of a haematoma in the traumatised iliacus muscle. This condition mimics appendicular abscess and is differentiated by two points — (i) that there will be a history of trauma and the pain is only restricted to this region unlike appendicular abscess where pain started in the region of the umbilicus and then shifted to the right iliac fossa and (ii) that there will be a clear space between the abscess and the ilium in case of appendicular abscess but not in case of an iliac abscess.

ILIOPSOAS COLD ABSCESS gravitates from the affected thoraco-lumbar vertebrae down the psoas sheath deep to the inguinal ligament into the thigh. Therefore cross fluctuation above and below the inguinal ligament can be easily demonstrated. Deformity of the spine (gibbus) and X-ray will confirm the diagnosis. Cold abscess arising from sacro-iliac joint may fill up the right iliac fossa. Examination of this joint and X-ray should always be performed.

Ilium.— The pathological conditions which may give rise to bony swellings from the ilium are same as those arising from any other bone. These have been discussed in chapter 11 under "Examination of a Bony Lesion".

The structures which abnormally present or those which invade this region from the neighbourhood are:

Kidney.— (a) *Unascended kidney.*— The first rudiment of the kidney makes its appearance in the pelvis. With the development of the foetus the kidney gradually ascends to take up its final position. Due to some unknown reason the kidney may fail to ascend and remain permanently either in the pelvis or in the iliac fossa as a lobulated mass. I.V.P. alone can make the diagnosis with certainty.

(b) *Dropped kidney* or moveable kidney may come down to the right iliac fossa and create confusion in the diagnosis. But a kidney to drop to the iliac fossa is extremely rare.

Gallbladder.— Very occasionally a hugely distended gallbladder (hydrops) with enlarged liver may descend as low as the right iliac fossa.

Uterus and its appendages.— (a) *Tubo-ovarian mass,* (b) *pyosalpinx,* (c) *cyst and abscess of the broad ligament,* (d) *fibroid of the uterus* and (e) *ovarian cyst* may invade this region. History of their extension from the pelvis and findings of the vaginal examination should be taken into consideration in diagnosis.

Urinary Bladder.— If it be enlarged with retention of urine the swelling will be in the hypogastrium and not in this region. Only a huge diverticulum of the bladder may invade this region.

Retained or undescended testis.— The testis develops in the lumbar region. As the foetus grows, the testis descends through the inguinal canal into the scrotum. The testis may abnormally fail to descend and become an abdominal organ or may remain within the inguinal canal. It hardly forms a swelling when it is an abdominal organ, though the chance of malignant transformation is higher in this region. When it is within the inguinal canal it forms a swelling which gives rise to the typical 'testicular feel'. It must be remembered that the commonest position of an ectopic testis is the superficial inguinal pouch.

Pelvic abscess, as it enlarges, may overflow towards the iliac fossa. Besides other features, rectal and vaginal examinations are conclusive.

CAUSES AND DIFFERENTIAL DIAGNOSIS OF SWELLINGS IN THE HYPOGASTRIUM

The bladder must be emptied by a catheter before clinical examination is made.

A. **PARIETAL SWELLINGS.**— In addition to those parietal swellings discussed under the umbilical region, a rare swelling — urachal cyst — may be considered here.

URACHAL CYST.— Normally the urachus (the remnant of the allantois extending from the bladder to the umbilicus) becomes obliterated. If it remains patent, it forms a urinary fistula at the umbilicus in a new born baby. Closure of the umbilical and vesical ends and persistence of the middle segment gives rise to the urachal cyst. This is a cystic swelling, which lies just deep to the abdominal musculature and is relatively fixed.

B. **INTRA-ABDOMINAL SWELLINGS.**— These swellings may occur in connection with (1) the urinary bladder, (2) small intestine, (3) sigmoid colon, (4) uterus and its appendages, (5) pelvis and (6) pelvic bone.

Urinary bladder.— Distended urinary bladder forms a globular swelling that can be seen and palpated in the midline just above the pubis. It may reach up to the umbilicus in chronic retention of urine. It is dull on percussion which is a very significant point, as this area is normally resonant due to the presence of the terminal coils of the small intestine. Pressure on distended bladder will induce a desire for micturition. Differential diagnosis of causes of retention of urine is discussed in page 591.

Uterus.— It is again emphasised that the urinary bladder should be catheterised before palpation for the uterus is made. Many a wrongly diagnosed uterine swelling melts away after catheterisation. Two common swellings of the uterus are due to pregnancy and fibroid. Amenorrhoea in a young woman with smooth uterine enlargement would suggest pregnancy to be confirmed by classical signs and symptoms of pregnancy. Menorrhagia of some standing

in women above 30 years of age but before menopause with irregular enlargement of the uterus (except in the submucous type in which the swelling will be smooth) will lead one to think of fibroid.

Fallopian tube and **Ovary.**— Acute salpingitis rarely gives rise to a lump in early stage. The *TUBO-OVARIAN MASS* results from chronic salpingitis and oophoritis. The patient is a young woman and the mass is situated either in the midline or more often on one or the other side of the midline. This is usually preceded by an attack of pelvic peritonitis in the form of pain, rise of temperature, bladder disturbance etc. Vaginal examination is confirmatory.

RUPTURED TUBAL GESTATION.— No lump is normally felt in the early stage. When the leakage is slow, a mass can be felt a few days later, on one side of the uterus or behind it. History of missed period or periods is an important hint to the diagnosis.

OVARIAN TUMOUR AND CYSTS.— They spring up from one side of the pelvis but later on take up a central position. Their attachment to the uterine cornua as determined by the vaginal examination, is an important diagnostic feature. Menstruation will be normal or scanty depending on the amount of ovarian destruction. It should be differentiated from ascites by dullness over the front of the abdomen with resonant areas in the flanks, whereas in ascites there is dullness on the flanks with resonance over the front of the abdomen in supine position.

BROAD LIGAMENT CYST gives rise to a swelling that can be felt abdominally. It is not usually so big as the ovarian cyst. By vaginal examination this condition is more conveniently diagnosed.

Pelvic abscess.— It may follow acute appendicitis, salpingo-oophoritis, perforated peptic ulcer, puerperal sepsis etc. Besides constitutional disturbances it leads to copious discharge of mucus per anum and frequency of micturition. Patient will complain of pain in the lower abdomen and will run temperature. Rectal examination will reveal bulging of the anterior wall of the rectum.

Pelvic Bones.— Swellings in connection with the pelvic bones are rare. Their fixity to any of the pelvic walls, bony hard consistency and X-ray will make the diagnosis certain.

CAUSES AND DIFFERENTIAL DIAGNOSIS OF SWELLINGS IN THE LEFT ILIAC REGION

A. **PARIETAL SWELLINGS.**— In this region iliac abscess (pyogenic) or cold abscess may form swelling. Appendicular abscess cannot be present here. Inguinal swellings have been discussed elsewhere.

B. **INTRA-ABDOMINAL SWELLINGS.**— The same conditions that have been discussed under the right iliac region are applicable here, with the exception of the caecum and appendix, but in their stead the sigmoid (and descending) colon is substituted. Amongst the structures that may invade this region, the spleen should be considered instead of the gallbladder.

Sigmoid colon.— There are two pathologies of the sigmoid colon which may give rise to a mass in the left iliac fossa. These are *diverticulitis* and *carcinoma*. The patient is above 40 years in both these conditions.

DIVERTICULITIS.— Diverticulosis, which is the first stage of this condition often passes asymptomatic. But rectal haemorrhage and flatulent distension of the lower abdomen may be the presenting symptoms at this stage. When inflammation sets in diverticulitis develops. Fever, malaise, pain and tenderness on the left iliac fossa are the main features of this condition. All these sum up to mimic left sided appendicitis. This disease is rare in India. X-ray with barium

enema will show multiple diverticula or 'saw tooth' appearance with narrowing of the colon. Sudden haemorrhage, perforation, local abscess, general peritonitis (very rare), fistulae (both internal and external) and even carcinoma are the complications of this disease.

CARCINOMA.— In this region mainly annular type of carcinoma is seen. Increasing constipation requiring increasing doses of purgatives is the main presenting symptom. The carcinoma itself hardly produces a lump. What is felt is a loaded colon proximal to the stenosis as determined by pitting on pressure. X ray with barium enema will show constant 'filling defect'.

Chapter

36 EXAMINATION OF A RECTAL CASE

HISTORY.— The patient may present with bleeding, discharge of pus or mucus, pain, abnormality in bowel habit or prolapse.

1. **Bleeding.**— Enquire about the *AMOUNT OF BLEEDING;* the *COLOUR OF THE BLOOD* lost — bright red (coming from the rectum or anal canal), dark red (coming from the ascending, transverse, descending or sigmoid colon) or black i.e. melaena (from the small intestine or higher); *Its relation with the faeces* — unchanged blood may appear in four ways — (i) blood mixed with faeces means that the blood has come from bowel higher than sigmoid colon where the softness of the stool remains giving chance to the blood to mix with the faeces. (ii) Blood on the surface of the faeces usually comes from the rectum or anal canal. (iii) Blood separate from the faeces may occur when bleeding occurs at some other time than defaecation e.g. bleeding carcinoma of the rectum when blood accumulates in the rectum and gives rise to desire to defaecate and only blood and mucus come out. Such bleeding may also occur in diverticulosis, diverticulitis, ulcerative colitis, polyp, prolapsed piles etc. (iv) Blood in the toilet paper is only seen in case of minor bleeding from the anal skin either due to fissure-in-ano or external haemorrhoids.

When a child comes with bleeding per anum, a diagnosis of rectal polyp should be made until this is excluded by rectal examination.

2. **Discharge of pus or mucus.**— Soiling of the clothes with purulent discharge coming from a sinus is the constant complaint of the patient with a fistula-in-ano. In ulcerative carcinoma of the rectum the patient often passes a considerable quantity of blood-stained, purulent and offensive discharge at the time of defaecation. Excessive mucus is also discharged in colitis, Crohn's disease and colloid carcinoma of the rectum.

3. **Pain.**— It is interesting to know that all pathological conditions below the Hilton's line are painful but above this line they are painless so long as they remain confined within the rectal wall. Inflammation or infiltration beyond the rectal wall is likely to be painful. Enquire about the *nature of pain* — whether throbbing (ano-rectal abscess) or sharp cutting (anal fissure) or intermittent in nature in case of fistula-in-ano (see below) and its *relation with defaecation.* Pain is the main symptom of chronic fissure-in-ano. It starts with defaecation and persists for sometime after the act. In a fistula-in-ano pain is intermittent. When the fistula becomes closed the pain appears and gradually increases as the discharge accumulates until the fistula is forced open, when the collection is voided and pain disappears. Uncomplicated piles are absolutely painless but when they are complicated by secondary infection or strangulation, they become painful. Carcinoma of the rectum is painless to start with. When pain appears it indicates a spread into the pelvic cellular tissue or sacral plexus (causing bilateral sciatica). An annular lesion high in the rectum may obstruct the lumen of the bowel and cause lower abdominal colic.

4. **Abnormality of the bowel habit.**— In carcinoma of the rectum the bowel habit is altered and the *nature of alteration depends on the position of the growth* — whether occurring at the pelvirectal junction, in the ampulla or in the anal canal *and on the macroscopic feature of the growth* — either annular or ulcerative or proliferative. The growth at the pelvirectal junction or in the sigmoid colon is usually of the annular type. Increasing constipation is the earliest symptom in these cases. A proliferative growth in the ampulla causes a sensation of fullness in the rectum and the patient feels that his bowel has not been completely emptied after defaecation. In ulcerative growth, mucus, pus, blood and faeces accumulate overnight during the night and the patient on rising from the bed gets an urgent call to stool — this is called 'spurious morning diarrhoea'. A growth in the lower part of the rectum and anal canal may alter the shape of the stool which becomes either pipestem or tape-like. *Tenesmus* is the painful straining to empty bowel without any result. Such tenesmus may be caused by a proliferative growth (space-occupying lesion) in the ampulla of rectum.

5. **Prolapse.**— If the patient complains of something coming out of the anal canal during defaecation, he is possibly suffering from prolapse, polypus or long standing internal piles. Enquire whether the prolapse that comes out with defaecation is reduced automatically after the act or has to be replaced by pushing it in. Sometimes the patient comes with a prolapse remaining unreduced for two to three days. Enquire also about the length of the protruded mass. If the protrusion is slight, it is a partial prolapse (i.e. prolapse of the mucous membrane and submucosa only). If it is more than two inches in length, it is a complete prolapse or procidentia (i.e. prolapse of all coats of the rectum).

6. **Other complaints.**— (a) *Pruritus ani* is a symptom often complained of by the patients. A list of the conditions which cause pruritus ani have been given at the end of this chapter. (b) *Loss of weight* and cachexia are often complained of by patients with malignant growth in this region. (c) Various types of indigestion may be complained of in case of carcinoma of rectum, ulcerative colitis, Crohn's disease and fissure-in-ano (particularly in old individuals when the rectum is full of faeces as the patients try to avoid defaecation which is so painful).

Past History.— In a case of fistula-in-ano a previous history of anal abscess is often obtained. This abscess has either burst spontaneously or has been incised. Fistula-in-ano may be even found in cases of tuberculosis, Crohn's disease, ulcerative colitis, colloid carcinoma of the rectum etc. So relevant questions must be asked to find out if the patient is suffering or was suffering from any of these ailments. Habitual constipation is often associated with internal piles and fissures. In the case of prolapse a previous history of dysentery or severe diarrhoea may be obtained. Wasting of the patient leads to weakening of the rectal support — this together with tenesmus as occurs in dysentery is responsible for the development of prolapse. Anal tag and perianal abscess are sometimes seen in Crohn's disease.

Family history.— Polyposis is recognized to be a hereditary disease. A family history may be volunteered by the patients suffering from piles, fissures, prolapse and even carcinoma of the rectum.

RECTAL EXAMINATION

Position of the patient.— 1. *The left lateral position (Sims').*— This is the most popular position for anorectal examination. The patient lies on the left-side. The buttocks should project over the edge of the table. Both the hips and knees are well flexed so that the knees are taken near to the chest of the patient. This position is suitable for inspection of the perianal region and proctoscopy.

2. *Dorsal position.*— The patient lies on his back with the hips flexed. The examiner passes his forearm beneath the right thigh and the index finger is pushed through the anal canal. This position is popular when the patient is too ill to alter the position. It is also convenient to do bimanual examination in this position. The right index finger remains in the rectum while the left hand on the abdomen to know the interior of the pelvis in a better way — the size and characteristics of a pelvic swelling and more information regarding recto-vesical or recto-uterine pouch, but this position is not suitable for inspection around the anus.

3. *The Knee-Elbow position.*— This position is particularly suitable for palpating the prostate and seminal vesicles.



Fig.36.1.— Complete prolapse (procidentia) of the rectum.

4. *Right lateral position* — can be chosen in the case of carcinoma at the pelvirectal junction when it tends to fall downwards and towards the anus for better palpation by the examining finger.

5. *Lithotomy position.*— The advantages of this position are that more informations regarding pelvic viscera can be obtained and bimanual examination can be conveniently performed. Moreover a lesion high in the rectum is more likely to be felt.

The students should remember that about 10 cm from the anus can be explored by digital examination.

It cannot be emphasised too strongly *that the anal region must be inspected firstly, palpated secondly and digital examination lastly.*

INSPECTION.— This part of examination should never be omitted. Anal tags (external piles), sentinel pile (a feature of chronic fissure), fistula-in-ano, pilonidal sinus, condyloma and



Fig.36.2.— Carcinoma of the rectum involving the anal canal.



Fig.36.3.— Anal Carcinoma.

carcinoma can be diagnosed by inspection alone. Swellings and ulcers may be seen in this region as in other regions of the body. *Anal tag* may be present anywhere around the anus but the position of the *sentinel pile* is more or less constant — on the midline posteriorly. The sentinel



Fig.36.4.— Basal cell carcinoma of the anus.



Fig.36.5.— Prolapsed internal piles. Note that the primary piles are situated at 3, 7 and 11 O' clock positions.

pile is associated with **fissure-in-ano**, which is a linear ulcer in the anal canal (mostly situated on the midline posteriorly). The lower end of the fissure can just be seen when the anal margins are separated — a procedure which causes extreme pain. When a **fistula-in-ano** is found note the distance of its orifice from the anus and its position — whether situated anteriorly or posteriorly to an imaginary line passing transversely through the middle of the anus. The position of the external opening of a fistula-in-ano gives an idea of the position of the internal opening. If the external orifice lies either behind the imaginary line referred to above or anterior to it but beyond 1½ inches from the anus, the internal opening will be found on the midline posteriorly between the two sphincters, the fistulous track being curved. When the external opening is situated in front of the line but within 1½ inches of the anus, the internal opening lies on the same radial line as the external opening, the track being straight (*Goodsall's rule*). **Pilonidal Sinus** is seen typically on the midline at the tip of the coccyx. A tuft of hair will be seen extruding through the sinus. **Condylomata** (Fig.36.11) at anal region are of two types — *CONDYLOMATA ACUMINATA* and *CONDYLOMATA LATA*. ***Condylomata acuminata*** are

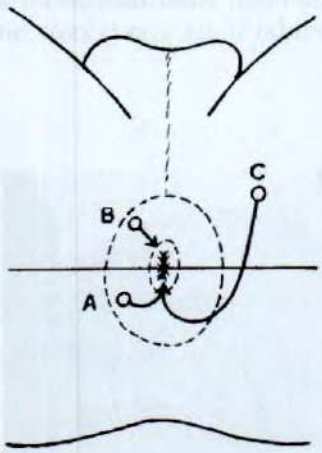

Fig.36.6.— Application of Goodsall's rule. When the external opening of a fistula-in-ano (A) lies behind the transverse line passing across the anus or (C) anterior to this line but beyond 1½ inches from the anus, the internal opening is found in the midline posteriorly between the sphincters, the fistula's track being curved. When the external opening (B) is situated in front of the transverse line, but within 1½ inches from the anus, the internal opening lies in the same radial line as the external orifice, the fistula track being straight.

multiple, pedunculated papilliferous lesions that are easy to recognize. These are caused by a virus which is a variant of the papilloma virus responsible for skin warts. This type of warts may spread over a wider area to involve the perineum, labia majora and even back of the scrotum. ***Condyloma lata*** is a manifestation of secondary syphilis and is rare nowadays. These are flat, raised, white and hypertrophied epithelium at the mucocutaneous junction of the anus. **Anal carcinoma** is mostly seen as an extensive ulcer with everted margin (Fig.36.3).

Furthermore inspection will provide with informations regarding internal piles, prolapse, pruritus ani etc. When there is a history of **prolapse** ask the patient to strain as he would do during defaecation, if required, in the squatting position. Note the protruded mass. In case of prolapse if the protrusion is less than 1 inch it is a partial prolapse, whereas any protrusion more than 2 inches should be considered as complete. *Long-standing* **internal piles** may protrude through the anus, but this protruded mass is divided in segments whereas an incomplete prolapse is a single segment. It should be remembered that an external pile is covered with skin whereas an internal pile is covered with mucous membrane. Very rarely a **polypus** or an *intussusception* may come out of the anal orifice. **Melanoma** of the anus, though rare, may be seen as bluish-black soft mass which may be confused with a thrombotic pile.



Fig.36.7.— A case of complete rectal prolapse.

PALPATION.— Before digital examination palpation of the perianal region should be performed. A *swelling* or an *ulcer* may be present in this region and should be examined as has been described in the chapters 3 and 4. An indurated tender swelling with brawny oedema on one side of the anus is usually due to an *ischiorectal abscess*. One should not wait for fluctuation to develop. External opening of *fistula-in-ano* can be seen in this region. Careful palpation will indicate the track. An apex of long standing *intussusception* may be seen through the anus. This has to be differentiated from *prolapse* of the rectum. In the former a finger can be insinuated between intussusception and the anal margin, but in the latter this is not possible.

DIGITAL EXAMINATION.— Now-a-days disposable gloves are being used. Then patient should be told what is about to be done. He is instructed to open his mouth and breathe in and out deeply. The gloved finger should be lubricated and the lubricant is wiped round the anus. The digital examination should be made gently and should not hurt the patient. The pulp of the index finger should be laid flat on the anal verge. Gentle pressure is exerted till the sphincter yields. More pressure will gradually push the finger into the anal canal with rotatory movement. The tip of the index finger should not be introduced straight into the anus. While the finger is within the anal canal and rectum a definite system should be established to get all the informations of rectal examination.



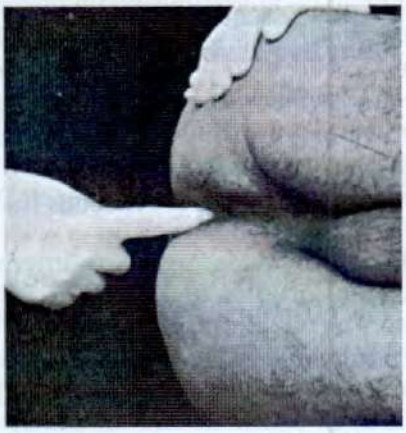

Figs.36.8 & 36.9.— Showing the correct and the wrong methods of introducing the finger into the rectum.

When the finger is in the anal canal note the tone of the sphincter, any pain or tenderness and any thickening of the wall of the anal canal. Patients with fissures may have spasm of the sphincters and will complain of excruciating pain during digital examination. Examination may be deferred in these cases as necessary informations cannot be gathered.

When finger enters the rectum, it should be pushed as high as possible. Informations received in rectal examination can be divided into (a) within the lumen, (b) in the wall and (c) outside the wall.

A. **Within the Lumen.**— Sometimes the rectum is found to be full of hard faeces. At these instances a complete rectal examination is impossible. So it is a good practice to give enema before the rectal examination. The apex of an *intussusception* may occasionally be felt. Its freedom from the rectal wall can be easily assessed if the finger is passed between intussusception and the rectal wall. In *intestinal obstruction* there will be "ballooning" of the rectum. This is evident by the fact that rectal wall can only be felt by bending the examining finger in the rectum. However this sign is not much reliable. False positive results are sometimes seen after administration of enema or in obstruction of the urinary tract (presumably reflex in origin). If a *mass* can be felt ask the patient to strain down. This will bring the mass further down for proper palpation.

B. **In the Wall.**— Just inside the opening of the anus a circular groove can be felt. This lies between the external and internal sphincter muscles. This also marks the dividing line between the external and internal haemorrhoidal plexuses. Further up the ano-rectal ring can be felt. It is approximately 3 cm above the anal verge. This marks the junction between the anal canal and rectum. Posteriorly the ring is felt best, then laterally due to presence of sling-like arrangement of the pubo-rectalis component of the levator ani muscle. These landmarks are important in determining the location of different anorectal abscesses or fistula-in-ano. Above this ring the finger enters the spacious lower part of the rectum. The ascending finger may feel a soft fold of mucous membrane called valve of Houston. *It cannot be impressed too strongly that uncomplicated internal piles cannot be felt with the finger.* They are diagnosed by proctoscope. Only chronically inflamed and thrombosed piles can be felt by digital examination. The internal opening of the *fistula-in-ano* is usually felt as a small dimple in the centre of an indurated area. Most frequently it is situated on the mid-line posteriorly between external and internal sphincters. A diagnosis of *ulcer* is made by absence of normal smoothness of the rectal mucous membrane. The edge of the ulcer should be carefully

palpated for induration and eversion— the pathognomonic features of a malignant ulcer. Besides carcinoma, an ulcer may be due to tuberculosis, dysentery, gonorrhoea, soft sore, syphilis etc. History and isolation of the positive organism will establish the nature of the ulcer. A *polypus* of the rectum is felt as soft round growth about the size of a small grape slipping under the finger. It must be remembered that a soft lesion of the rectal wall is likely to be felt on the downward stroke of the finger than in its upward course. So, as soon as a soft lesion is felt the finger is pushed up clear of the lesion till it reaches its upper limit. The finger is now flexed and withdrawn partially to feel the lesion properly. It may be possible to pull a polypus out of the anus and examine it thoroughly.

When the lumen of the rectum is constricted a diagnosis of *stricture of the rectum* is made. Note the position and extent of such constriction and the character of the mucous membrane at the site of the stricture whether ulcerated or thickened. It must be remembered that narrowing of the rectal lumen may be caused by pressure from outside in which case the mucous lining is perfectly smooth. A stricture may be benign or malignant. A benign stricture feels like a diaphragm with a clean-cut hole in its centre. A malignant stricture feels hard, irregular and is often ulcerated. There are various causes of benign stricture. Besides trauma and post-operative stricture, a few inflammatory conditions may give rise to such strictures. Lymphogranuloma inguinale is the most important in this group. In this case the stricture is rubbery and tubular in character. It is a form of venereal disease caused by ultramicroscopic virus. An enquiry should be made about previous history of genital sores and inguinal bubo. The diagnosis is established by Frei's intradermal test.

Carcinoma of the rectum is a condition in which rectal examination is of paramount importance. 75 percent of carcinomata of the rectum occur in the lower part of the ampulla, where they tend to be papilliferous or ulcerative with everted edge. The remaining 25 percent occur in the upper part of the rectum and are annular in shape. About 90 percent of rectal cancer can be felt by digital examination and it is criminal not to perform rectal examination in patients with any rectal complaint. Determine how much of the circumference of the rectum is involved by the growth. The tumour may bleed readily during examination. Try to decide whether the tumour is fixed or mobile, how much is its local spread — whether the neighbouring structures such as bladder and prostate (or uterus and vagina) anteriorly and the sacrum and the coccyx posteriorly are involved. It is useful to remember that the growth preserves its mobility so long as it remains within the fascia propria of the rectum.

C. **Outside the Wall.**— This is the most important part of rectal examination and probably more often used as a diagnostic procedure than the previous section. The structures around the rectum are explored systematically by palpating anteriorly, right lateral, left lateral and posteriorly.

ANTERIORLY.— The anatomical structures on this aspect are the prostate, seminal vesicles, base of the bladder and recto-vesical pouch of peritoneum in case of male; the uterus, the cervix, the vagina and recto-uterine pouch (pouch of Douglas) in case of female. The examinations of the prostate, the seminal vesicles and base of the bladder are described under "Examination of a urinary case". To make summary of this examination it may be stated that the normal prostate is firm, rubbery, bilobed, its surface is smooth with a shallow central sulcus and the rectal mucosa can be moved freely over it. The seminal vesicles are palpable just above the upper lateral angles of the gland.

Uterus and cervix are easy to feel per rectum. The uterus is felt as a tumour whereas the cervix can be felt projecting through the anterior rectal wall which is popularly known as *pons asinorum*. It is a good practice to feel the cervix first and then follow to the uterus onwards. Bimanual palpation can define the shape and size of the uterus and any ovarian mass in a better way.

Now the attention is directed towards recto-vesical or recto-uterine pouch. The index finger when fully inserted reaches about one inch above the floor of pouch of Douglas in the female and about half that distance in the male. Presence of pus, blood, malignant deposit (e.g. from carcinoma of the stomach) or tumour of the sigmoid colon may be felt through the pouch.

LATERALLY.— The structures which are felt laterally are the ischiorectal fossa, the lateral wall of the pelvis, lower end of the ureters and internal iliac arteries. The pelvic appendix can be felt on right side and the rectal examination is imperative in pelvic appendicitis as tenderness may not be so obvious per abdomen. In case of female fallopion tubes and ovaries may be palpable and rectal examination is of great help in diagnosing salpingitis, ovarian cysts and tumours. A mass may be palpable in a leaking ectopic gestation of some days standing.

Ischio-rectal abscess is often felt per rectum as an extremely tender and tense swelling on the side of the rectum. Rarely, a stone in the lower end of the ureter and an aneurysm of the internal iliac artery may be felt per rectum. Inflammation and growth from the bony wall of pelvis, central dislocation of the hip joint, fracture of the pelvic girdle may be discovered by the finger in the rectum.

POSTERIORLY.— The hollow of the sacrum and coccyx are easily felt through rectum. Any pathological condition affecting this region can be easily palpated through rectum. A suspected case of coccydynia can be detected by an index finger inside the rectum and a thumb over the coccyx to detect abnormal mobility and tenderness in this condition. Sacrococcygeal teratoma and post-anal dermoid can also be felt and diagnosed per rectum.

Bimanual Examination.— The examination of the contents of the pelvis can be conveniently examined during rectal examination by placing another hand on the abdomen. This gives a better idea of the size, shape and nature of any pelvic mass. Its immense importance in staging of bladder carcinoma is discussed in chapter 37.

At the end of the rectal examination always look at the examining finger for presence of faeces, blood, pus or mucus.

Abdominal Examination.— In case of annular carcinoma at the upper part of the rectum an indistinct lump may be felt at the left side of the abdomen. This is nothing but the descending colon loaded with hard faeces. This swelling pits on pressure and thus distinguishes it from any solid swelling at this region. Examine the liver for secondary metastasis. Note also if there is any jaundice, hard subcutaneous nodules and free fluid within the abdomen.

Lymph Nodes.— Carcinoma arising from the hind gut will metastasise to the iliac groups of lymph nodes. On deep palpation one may discover enlargement of these nodes particularly in thin patients. Carcinoma arising from or involving the lower part of the anal canal below the pectinate line commonly spreads to the inguinal group of lymph nodes and these are easily palpable.

SPECIAL INVESTIGATIONS

Proctoscopy.— With the patient in the left lateral or 'knee-elbow' position the warm and lubricated proctoscope is gently inserted into the rectum. The instrument is introduced at first in the direction of the axis of the anal canal, i.e. upwards and forwards towards the patient's umbilicus until the anal canal is passed. The instrument is then directed posteriorly to enter into the rectum properly. Now the obturator is withdrawn and the interior of the rectum and anal canal is seen with the help of a light. The internal piles, fissures, ulcer and growth can be seen if present. The piles will prolapse into the proctoscope as this instrument is being withdrawn. Note the position of the piles. They are generally positioned according to the main branches of the superior

haemorrhoidal vein. The main three branches are situated in the left lateral, right anterior and right posterior positions. When the patient is in the lithotomy position these positions will correspond to the 3, 7 and 11 o'clock positions respectively, if a watch is imagined to be held against the anus. These are called *primary piles*. A few *secondary piles* (4-5) may frequently develop in between the primary ones. *Chronic fissure* is often situated on the midline posteriorly. By proctoscope one can also find inner opening of *fistula*. One can take biopsy from a *growth* or an *ulcer* through a proctoscope.

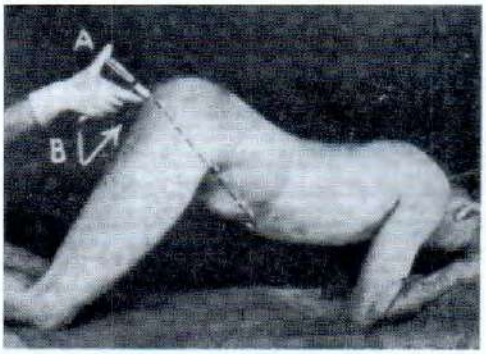

Fig.36.10.— Proctoscopy in the 'Knee-elbow' position. (A) The instrument is first pushed towards the patient's umbilicus as this is the direction of the anal canal. As soon as the anal canal is passed, the instrument is then depressed and pushed towards the sacrum along the rectum (B).

Sigmoidoscopy.— The length of a sigmoidoscope is about 14 inches (35 cm). By this instrument whole of the rectum and a large part of the sigmoid colon can be examined. The conventional position for introduction of this instrument is the 'knee-elbow' position. But a few surgeons prefer left lateral position. The instrument is well lubricated and passed through the anus along the direction of the anal canal i.e. upwards and forwards towards the umbilicus of the patient. As soon as its tip has entered the rectum all further introduction should be carried out under direct vision. The obturator is withdrawn, the glass eye-piece and the light-carrier are fitted and the bellow is attached. Now the instrument is pushed posteriorly (at right angle of the previous direction). While within the rectum, by circumduction movement the interior of the rectum is thoroughly inspected. The instrument is gradually pushed upwards following the sacral curve. Horizontal folds are come across and easily circumvented. As it comes nearer the pelvic-rectal junction the instrument will be directed more anteriorly on one side or the other (usually the left side). Introduction of the instrument into the pelvic colon is the most difficult part of the operation. By gentle inflation of the bowel under direct vision the lumen can be made to open out in advance of the instrument. By continuing in the same manner the sigmoidoscope can be passed up to its full extent so that the greater part of the pelvic colon can be examined.

This instrument is mainly used to detect presence of any growth, ulcer, diverticula etc. in the rectum and lower part of the sigmoid colon. The growth can be biopsied and a smear may be taken from ulcer for bacteriological examination through this instrument. The proliferative type of carcinoma has an irregular nodular surface which is friable and bleeds easily. In case of ulcerative type of carcinoma the margin will be everted and raised. A benign growth is usually pedunculated. An adenoma may be smooth and lobulated. A sessile benign growth is often difficult to distinguish from carcinoma without biopsy.

A sigmoidoscopy should always be supported by contrast enema X-ray. There may be multiple tumours. Just by seeing a polyp through sigmoidoscopy one should not be content in removing it. If there be a carcinoma higher in the colon, this will implant cancer cells in the rectal wound.

Colonoscopy.— Since barium enema was introduced there has been no practical diagnostic method in the colon after X-ray and before the surgeon's knife. With the advent of fibreoptic colonoscope, the whole of the colon upto the caecum can be viewed for practical purposes. This instrument is preferred to sigmoidoscope by majority of the patients.

The key to pleasant and successful colonoscopy lies in achieving a clean bowel before hand. Colonoscopy is never done under general anaesthesia, but it may be done after satisfactory analgesia by injecting intravenously diazepam (Valium) 5-20 mg. and pethidine 25 to 75 mg. It is extremely important for the endoscopist to pay attention to any pain being experienced because of excessive stress on the bowel wall or on the attachments of the colon.

Colonoscopy and the contrast enema are complementary procedures. When the barium enema report is at hand, the *strong indications* of a diagnostic endoscopic examination following the contrast study are listed below : (i) X-ray study negative, but the symptoms persist including occult blood and anaemia; (ii) X-ray study positive yet for confirmation; (iii) X-ray study positive for cancer, but for taking biopsy; (iv) X-ray study positive for cancer yet to exclude synchronous cancer or associated polyps; (v) X-ray study positive for polyp, but to exclude malignant change or for additional polyps; (vi) X-ray study positive for inflammatory disease, but to know the extent of disease and for biopsy.

Perforation is the most frequently reported complication. There are certain clinical conditions in which an attempt at endoscopic examination appears unwise. These are (i) acute toxic dilatation of the colon, (ii) acute severe ulcerative colitis, (iii) acute diverticulitis, (iv) radiation necrosis, (v) recent bowel anastomosis and (vi) in uncooperative patients.

Endoscopic polypectomy has drastically reduced the need for the abdominal approach. Even in most instances malignant polyps can be controlled entirely by polypectomy via the colonoscope.

X-ray.— 1. *Straight X-ray of the abdomen* may indicate evidence of intestinal obstruction due to annular growth at the rectosigmoid junction.

2. *Chest X-ray* is performed in an established case of carcinoma of the rectum to exclude pulmonary metastasis.

Barium enema X-ray.— The importance of this examination in a case of bleeding per anum and in pathologies of the rectum and anal canal cannot be over-emphasised. In any case of internal haemorrhoid barium enema X-ray must be performed to exclude any carcinoma above the rectum to be the cause of this condition. In case of rectal polyp, this polyp may be one of the multiple polyps in the colon which should be excluded by barium enema. Other pathologies like Crohn's disease, ulcerative colitis which often affect this region are mainly diseases of the G.I. tract above this region and better be revealed by barium enema X-ray.

DOUBLE CONTRAST BARIUM ENEMA examination is often used nowadays and it delineates the colonic and rectal walls more precisely to detect pathologies like polyps and carcinomas which may be missed in barium enema X-ray.

CT Scan and **Ultrasonography** are only used in case of rectal carcinomas to detect intrapelvic or intra-abdominal lymph node enlargement and to detect the spread of such growth into neighbouring viscera.

DIFFERENTIAL DIAGNOSIS

Sacrococcygeal teratoma.— It is the most common among the large tumours which are seen in a new born baby. Teratoma may appear anywhere in the body, but frequent choice of this pre-coccygeal region is due to the fact that it is the site of the 'primitive node' which is composed of a group of totipotent cells. Females are more often affected than males. This tumour is firmly fixed to the coccyx and occasionally to the last piece of the sacrum. This tumour may assume a

very huge size, but it may be small enough to pass unnoticed. This small variety may turn malignant.

Postanal dermoid.— A soft cystic swelling may sometimes be come across in the space behind the rectum and anal canal and in front of the lower part of the sacrum and coccyx. This is a postanal dermoid and is a form of teratoma. Though congenital such a cyst often remains symptomless till adult life, until and unless it becomes infected or becomes burst outside forming a sinus. The cyst however if exceptionally of big size may give rise to difficulty in defaecation. The cyst is easily palpable by rectal examination and may be discovered accidentally by this examination.

Haemorrhoids (Piles).— Varicosities of the veins of the anal canal are known as haemorrhoids. It may be internal or external depending on the position of the varicosity. If it is above the Hilton's line it is called 'internal haemorrhoid' and if it is below the Hilton's line it is called 'external haemorrhoid'. So internal haemorrhoid is covered by mucous membrane whereas the external haemorrhoid is covered with skin.

Internal haemorrhoids are the varicosities of the internal haemorrhoidal plexuses. These could be divided into two main types : (a) *Vascular haemorrhoids* in which there is extensive dilatation of the terminal superior haemorrhoidal venous plexus — commonly found in younger individuals particularly men; (b) *Mucosal haemorrhoids* in which there is sliding down of the thickened mucous membrane whcih conceals the underlying veins. Piles may occur at all ages, but are uncommon below the age of 20 years barring piles secondary to vascular malformations which may occur in children. For practical purposes internal haemorrhoids can be divided into three degrees :—

First degree haemorrhoids are those in which hypertrophy of the internal haemorrhoidal plexus remains entirely within the anal canal as the mucosal suspensory ligaments remain intact. Patients in this stage usually present with rectal bleeding and discomfort or irritation. Bleeding is bright red and occurs during defaecation as 'splash in the pan'. It may continue for months or years.

Second degree haemorrhoids occur when with further hypertrophy the mucosal suspensory ligaments become lax and piles will descend so that they prolapse during defaecation but spontaneous reduction takes place afterwards. There may be small skin tag, some mucous discharge, soreness and irritation.

In *third degree* haemorrhoids, they remain prolapsed after defaecation and require replacement. These often descend spontaenously or on exercise. The mucosa overlying such haemorrhoids undergoes squamous metaplasia. Mucous discharge and pruritus ani become troublesome and anaemia becomes obvious. Secondary haemorrhoids occur between the three primary ones, the most common being the mid-posterior position. There may be a large skin tag.

General examination is intended to find out cause of this condition. Whether the patient is constipated or not? Causes of raised intra-abdominal pressure should be excluded. They are urethral stricture, an enlarged prostate, a big pelvic tumour pressing on the superior rectal veins. Pregnancy not only presses on the superior rectal veins but also excess progesterone during this period relaxes the smooth muscles on the walls of the said veins.

Rectal examination is usually not fruitful, as uncomplicated piles cannot be felt with finger unless they are thrombosed or fibrosed. Haemorrhoids are mainly diagnosed by *proctoscopy*. After the proctoscope has been fully introduced the obturator is taken out and with good light interior of the anal canal is seen. The proctoscope is slowly withdrawn. Red brown mucosa with the piles will bulge into the proctoscope. The three common primary piles are at 3, 7 and 11 o'clock positions (when the patient is in the lithotomy position). *Sigmoidoscopy* should always be performed to exclude any serious rectal pathology (such as carcinoma). If there is any doubt

as to the origin of the blood passed per rectum or a history of altered bowel habit, a barium enema X-ray or colonoscopy must be performed.

Fissure-In-ano.— This is a longitudinal ulcer in the anal canal posteriorly situated in majority of cases. Fissures may be of two varieties : (a) Acute and (b) Chronic.

ACUTE FISSURE is a deep tear in the anal canal with surrounding oedema and inflammatory induration. It is always associaetd with spasm of the anal sphincters. Bright streak of blood with the passage of stool and pain after defaecation are the characteristic features. Acute fissures often heal spontaneously.

CHRONIC FISSURE.— When acute fissure fails to heal, it will gradually develop into a deep undermined ulcer with continuing infection and oedema. This ulcer stops above at the pectinate line. Below, there is hypertrophied papilla and skin tag known as 'sentinel pile'. As the fissure is mainly situated in the lower anal canal it is highly painful and associated with spasm of the sphincters. Rectal examination can feel the chronic ulcer. But due to extreme spasm of the Sphincter proctoscopy may be postponed till later stage.

Posterior angulation of the anal canal, relative fixation of the anal canal posteriorly, divergence of the fibres of the external sphincter muscle posteriorly and the elliptical shape of the anal canal are the theories of predominately posterior midline location of fissures.

The students should remember a few secondary causes of anal fissures e. g. ulcerative colitis, Crohn's disease, syphilis, tuberculosis etc.

Ano-rectal abscesses.— There are mainly 3 types of these abscesses — (i) Perianal, (ii) Ischiorectal and (iii) Pelvic-rectal abscesses. Two other types are also seen — (iv) Submucous and (v) Fissure abscess (associated with chronic fissure).

(i) *PERIANAL.*— An acutely tender rounded cystic lump will be seen and felt by the side of the anal verge below Hilton's line. This can be conveniently palpated with an index finger inside the anal canal and a thumb superficial to the swelling. This abscess is less painful than the ischiorectal abscess as the skin can expand easily in this region.

(ii) *ISCHIORECTAL.*— Patient will complain of excruciating throbbing pain by the side of the anal canal. Inspection will reveal brawny oedematous swelling. It is very tender swelling with or without fluctuation. One should not wait for fluctuation to appear. By rectal examination one can feel the tender swelling on one side of the rectum. This abscess may travel to the opposite side posteriorly.

(iii) *PELVI-RECTAL ABSCESS.*— Clinically this abscess mimics the pelvic abscess in many respects. This abscess lies above the levator ani but below the pelvic peritoneum.

Submucous and *fissure abscesses* can be diagnosed by history and rectal examination. In any case of ano-rectal abscess, Crohn's disease must be eliminated.

Fistula-in-ano.— This is a track lined by granulation tissue which opens deeply in the anal canal or rectum and superficially on the skin around the anus. Sometimes the track does not open into the anal canal or rectum, when it should better be called a 'sinus'. Mostly these fistulae develop from ano-rectal abscess which burst spontaneously or was incised inadequately.

An anal fistula may occur with or without symptoms. A history of intermittent swelling with pain, discomfort and discharge in the perianal region can often be obtained. Inspection and palpation usually delineate the course and nature of the fistula. After discovery of an external opening it is possible to palpate the fibrous cord subcutaneously leading toward the anal canal. This is better palpated bidigitally — index finger inside the lumen of the anal canal and the thumb superficially around the anus. All sides should be palpated for presence of multiple fistulae or sinuses. The most important part in rectal examination is to feel the ano-rectal sling and to find out whether the internal opening is above or below that sling. When

the internal opening is above the ano-rectal sling the fistula is said to be a *'high fistula'* and if the inner opening is below the ano-rectal sling the fistula is said to be a *'low fistula'*. While a low fistula can be laid open without fear of incontinence, treatment of a high fistula is very difficult and calls for expert hands in this speciality. Students are referred to page 398 for recapitulation of Goodsall's rule. Proctoscopy may indicate the inner opening. Sigmoidoscopy is mandatory to rule out 'proximal disease', be it inflammatory, neoplastic or otherwise. In every instance, a barium enema should be performed. Scrapings from fistula should be examined bacteriologically. In case of recurrent and multiple fistulae one should always try to eliminate tuberculosis, Crohn's disease, ulcerative colitis, lymphogranuloma inguinale and colloid carcinoma of the rectum. A high index of suspicion is necessary in this respect.

Pilonidal sinus.— The word 'pilonidal' means nest of hairs. It is a sinus which *contains a free tuft of hairs*. These sinuses are commonly found in the skin covering the sacrum and coccyx, between the fingers (in hair dressers) and at the umbilicus. Hairs break off by friction and then find entry either through the open mouth of the sudoriferous gland or through the soften skin either by sweat or some form of dermatitis. This condition is mainly seen between 15 and 40 years. At this age the mouth of sudoriferous gland becomes wider. It is rare before puberty and after 40 years. It is common in men than women. It is typically common in dark-haired, hirsute white men.

The common symptoms are pain and discharge. Pain may be from dull ache to throbbing (particularly when the opening is closed and the discharge becomes purulent and stagnant inside). When the discharge comes out the pain is relieved. Discharge varies from a little serum to a sudden gush of pus. Pilonidal sinuses are always in the mid-line of the natal cleft over the lowest part of the sacrum and coccyx. This differentiates this condition from anal fistula. Palpation of the skin and subcutaneous tissues around the sinus reveals areas of subcutaneous induration. Inguinal lymph nodes do not enlarge because the infection is mostly mild and chronic. The skin around the sinus is usually normal. But when infected it becomes red and tender. There may be puckered scar of old infected sinus. Pilonidal sinus is also seen in interdigital cleft in barber's hand, axilla and umbilicus.

Rectal prolapse.— This condition is seen at the extremes of life — in children between 1 to 3 years and in the elderly after 40 years of age. In children direct downward course of the rectum due to undeveloped sacral curve and reduced anal tone predispose. Women are more commonly affected than men. The main complaint is that something is coming out per rectum during defaecation. It may come out spontaneously even on standing, walking or coughing. The prolapse may reduce spontaneously or require digital reduction. An enquiry should be made into the presence or absence of other symptoms e.g. ano-rectal bleeding, mucous discharge, anal pain, the bowel habit, the control of defaecation etc.

Inspection is probably the single most important part of examination. If the prolapse is not immediately visible, it is often possible to make it appear by asking the patient to perform a Valsalva manoeuvre. This examination is done in the left lateral position or squatting position. Haemorrhoids or polyps can be easily diagnosed. Main difficulty in diagnosis is between mucosal (partial) and complete rectal prolapse. However this should not present a problem if it is remembered that a mucosal prolapse consists of only two layers of mucosa, whilst a complete prolapse consists of full thickness of rectal wall. Furthermore there may be a sulcus between the prolapse and the inside of the anal canal. If the length of the prolapse is less than 3.75 cm it is a partial prolapse and if it is more than this it is a complete prolapse (See Fig.36.10 in Colour Plate XII). A finger in the anal canal can estimate the tone of the anal sphincter and levator ani. Proctoscopy will exclude other pathologies. Double contrast barium enema and colonoscopy will be required if no obvious cause of prolapse can be found out. There may be associated neoplastic lesion further up.

Perianal Crohn's disease.— It must be remembered that 75% of patients with Crohn's disease develop perianal complication. This incidence of course depends on the site of gastrointestinal pathology — the more distal is the disease, higher is the rate of perianal complications. More interesting feature is that perianal complications of Crohn's disease may even appear before the Crohn's disease elsewhere in the G. I. tract even by a few years. The perianal complications can be classified into primary conditions and secondary conditions. *Primary conditions* are fissures, cavitating ulcers like intestinal disease and ulcerated piles. *Secondary conditions* are strictures, skin tags, fistulae and infective abscesses.

Perianal warts (Condylomata acuminata).— These are warts caused by a virus which is a variant of the papilloma virus responsible for skin warts. These are often transmitted by sexual contact, hence these may be present or associated with sexually transmitted disease e.g. gonorrhoea, syphilis, AIDS and herpes genitalis. These are also noticed in patients whose immune response has been depressed with steroids or other forms of chemotherapy.

On inspection perianal warts are multiple, pedunculated, papilliferous lesions seen around the anus. Sometimes the whole perineum is affected, even including the labia majora or the back of the scrotum.

Main symptoms are irritation, discomfort and pain from rubbing against the clothings. These may ulcerate and become infected.

Condyloma lata.— These are broad based, flat topped, raised and white papules. These are actually the manifestation of secondary syphilis. These are highly contagious.

Proctalgia fugax.— Sometimes the patient presents to the doctor with severe rectal pain. The pain appears suddenly and cramp-like in nature, deep inside the anal canal and usually at night. Such pain usually passes off spontaneously after a few minutes or even hours. Nothing can be prescribed to relieve such pain.

Its cause is unknown, as general and rectal examinations are usually normal. It may be suggested that such pain is caused by spasm of the muscles of the pelvic floor.

Carcinoma of the rectum.— Unlike other carcinomas this condition may be seen even in young patients. So age is not criterion for diagnosis. If it occurs in the young it is very virulent. Bleeding is the most constant symptom. It may bleed during defaecation or it may simply stain the underclothing. In case of proliferative growth in ampulla the patient feels the sense of incomplete defaecation even after full opening of the bowel. The patient may endeavour to empty the rectum several times a day often with passage of blood and mucus ('spurious diarrhoea'). The patient often gets up in the morning with an urgent urge for defaecation. In case of annular carcinoma affecting the upper part of the rectum the patient complains of



Fig.36.11.— Shows a case of condyloma acuminatum in the anal region.

increasing constipation needing increasing dose of purgative and as a result diarrhoea ensues. It is also due to the fact that hard faeces irritate the colon leading to diarrhoea. Pain is a late symptom, but pain of colicky character may be experienced by patients with annular growth of the rectosigmoid junction due to some degree of intestinal obstruction. When any growth has invaded beyond the rectal wall pain will be experienced. Weight loss and anaemia are the usual features. Abdominal examination is usually negative. In annular growth of the rectosigmoid junction the colon loaded with faeces may be felt. Pitting on pressure is diagnostic. Liver should always be palpated for metastasis. Peritoneum may be studded with secondary deposits. Ascites may be the result. About 90% of rectal cancers can be felt by finger for rectal examination. Induration of the base of growth is very significant be it an ulcerative or proliferative growth. After the finger has been withdrawn, it will be smeared with blood and mucus if the finger has touched the carcinoma. The mobility of the growth should be tested. At times enlarged iliac group of nodes can be felt through the rectum. One should always perform sigmoidoscopy, double-contrast barium enema X-ray, colonoscopy (if possible) and biopsy of the growth.

BLEEDING PER ANUM

Surgical causes will only be considered here. Causes can be best classified into A. Those which give rise to pain and B. Those which are painless.

A. In this group are — (i) Fissure-in-ano; (ii) Fistula-in-ano; (iii) Carcinoma of the anal canal; (iv) Ruptured perineal haematoma; (v) Ruptured-anorectal abscess; (vi) Endometriosis; (vii) Injury etc.

B. In this group are — (i) Blood alone — Polyp, villous adenoma and diverticular disease; (ii) Blood after defaecation — Haemorrhoids; (iii) Blood with mucus — Ulcerative colitis, Crohn's disease, intussusception, ischaemic colon etc.; (iv) Blood mixed with stool — Carcinoma of the colon; (v) Blood streaked on stool — Carcinoma of the rectum.

Examination and investigation should be in the line discussed above.

ANAL CONDITIONS WITH PAIN

Pain alone.— After defaecation — Anal fissure; Spontaneously at night — Proctalgia fugax.

Pain with bleeding.— Anal fissure, thrombosed and strangulated anal piles, anal carcinoma, rupture of ano-rectal abscess.

Pain with lump.— Perianal haematoma, ano-rectal abscess, carcinoma of the anal canal.

Pain with fistula.— Fistula-in-ano.

Pain with something coming out with bleeding.— Prolapse rectum, prolapsed haemorrhoid, prolapse rectal polyp, intussusception (rarely).

STRICTURE OF THE RECTUM AND ANAL CANAL

Causes :—

1. **Congenital** narrowing of the lumen occurs at the level of the anal membrane.
2. **Traumatic** (i) Injury to the rectum (penetrating injury, impaction of the foetal head during parturition), (ii) Following operations like haemorrhoidectomy due to injudicious removal of the skin or mucous membrane. This may occur after operations for fistula, excision of villous growth or polypus. To prevent stricture formation following these operations frequent digital dilatation is advised during the healing process.

3. **Inflammatory.**— In this group the most important is lymphogranuloma inguinale — a form of venereal disease. This disease is commoner in women and starts as a sore in the posterior vaginal wall. Frei's intradermal test is confirmatory. Stricture may also develop due to cicatricial contraction during healing process of the ulcers of the rectum caused by tuberculosis, syphilis, gonorrhoea, soft sore, bilharziasis, dysentery etc.

4. **Spasmodic.**— Though spasmodic strictures are temporary, yet in untreated and long-standing cases fibrous stenosis may result.

5. **Neoplastic.**— Commonly this is a malignant stricture e.g. annular carcinoma. Rarely benign growths may lead to stenosis e.g. villous adenoma.

6. **General.**— In this group are endometriosis (frequent menstruation with pain in the first two days), senile anal stenosis due to chronic internal sphincter contraction, irradiation stricture etc.

PERINEAL FISTULAE

Causes and diagnosis :

1. **Fistula-in-ano.**— This is the commonest cause of a fistula in the perineal region. Diagnosis is made by the previous history of an anal abscess which has incised or burst giving rise to a fistula. It may be incomplete or complete communicating with the rectum. Sometimes, the fistula track is extensive — the horse-shoe type — connecting the ischiorectal fossa of each side. Tuberculous proctitis, ulcerative colitis, Crohn's disease, colloid carcinoma of the rectum, lymphogranuloma, bilharziasis may be the cause of fistula-in-ano.

2. **Urethral Fistula.**— This is the result of a neglected periurethral abscess which develops proximal to the urethral stricture. When the abscess is incised or bursts urine leaks out through the wound during micturition. A hard fibrous tract is formed and can be traced up to the urethra. It may be single or multiple — when the term 'watering-can' perineum is used (see Fig. 5.3, page 56).

3. **Fistula or sinus in connection with Bone.**— Exceptionally, a sinus in the perineum may be due to osteomyelitis (pyogenic or tuberculous) of the tuber ischii, sacrum or coccyx.

4. **Pilonidal Sinus** — so called because of the presence of a tuft of hair in its interior — is commonly situated in the internatal cleft near the tip of the coccyx.

5. **Infected Postanal Dermoid.**— When a dermoid occurring in front of the coccyx becomes infected and opened, a sinus may develop in the perineum.

All fistulous tracks may be visualized by an X-ray film taken after injecting lipiodol (See Fig.5.7, page 79).

PRURITUS ANI

Causes are best classified into (a) causes in the rectum and anal canal, (b) in the vagina, (c) in the skin, (d) due to parasites and (e) general causes.

(a) ***Pruritus from mucous discharge from the anus.***— Haemorrhoids, fissures, fistula, polyps, carcinoma (particularly the colloid variety), skin tags, condyloma etc.

(b) ***Pruritus from the vaginal discharge.***— Trichomonas vaginitis, Monilial vaginitis, gonorrhoea, cervical erosions etc.

(c) ***Pruritus from skin diseases.***— Tinea cruris, monilial infections, infections from diabetes (Monilial infections are also commoxner in diabetes).

(d) ***Pruritus from the parasites*** — mainly thread worms.

(e) In the ***general group*** are poor hygiene, psychoneuroses and leakage of liquid paraffin from its excessive use.

Chapter

37 EXAMINATION OF A URINARY CASE

HISTORY.— (1) **Age.**— Wilms' tumour (nephroblastoma) is a disease of childhood below 4 years of age. Adenocarcinoma or renal cell carcinoma (hypernephroma) of the kidney is mainly seen in middle-aged individuals above 40 years of age. Bilateral polycystic kidney is also seen in individuals above 40 years of age. Acute pyelonephritis may occur at puberty, just after marriage (honey-moon pyelitis) and during pregnancy. Majority of renal calculi are seen between the ages of 30 and 50 years. Both benign hypertrophy of prostate and carcinoma of prostate are diseases of old age above 50 years of age, mostly above 60 years.

(2) **Sex.**— Acute pyelonephritis and cystitis are more common in females due to their short and straight urethra through which organisms find easy access. Incidence of renal stone is seen equally in males and females. Adenocarcinoma or renal cell carcinoma occurs more commonly in men than women in the ratio of 2 : 1. Prostatic diseases are obviously seen in males only.

(3) **Residence.**— Vesical calculus is more common in Rajasthan and Punjab. Schistosomiasis is more common in greater part of Africa, Israel, Syria, Iran and Iraq.

(4) **Social Status.**— Both renal calculus and vesical calculus are more often seen in poorer class of people may be due to lack of regular adequate diet. Though such predilection cannot be given much importance.

(5) **Occupation.**— Bladder carcinoma is more seen among workers in aniline dye factories, of dyeing industry, rubber and cable industries, of printing industry and in gas workers. People working in leather industry, textile industry and hairdressers also have higher incidence of bladder cancer.

COMPLAINTS.—

1. **Pain.**— Enquire about its *onset, duration, progress* and *nature*. One should also ask whether the pain has any radiation or not, whether it is referred or not and what is its *relation with micturition*. RENAL PAIN is usually felt as a *dull and constant ache* mainly at the angle between the outer border of the erector spinae muscle and the lower border of the 12th rib (renal angle). This pain may even be *severe*. This pain often spreads along the subcostal area towards the umbilicus. The patient typically describes renal pain by putting his hand on the waist with his fingers spreading backwards to cover the renal angle and his thumb forwards pointing towards the umbilicus (Fig.37.1). If there is significant enlargement of the kidney, the peritoneum is stretched and the pain is localized anteriorly at the upper and outer quadrant of the abdomen. Renal pain is mainly caused by distension of the renal capsule and the pelvis. Acute pyelonephritis, tuberculosis, renal stone may cause this typical pain. Sometimes the patient may feel pain in the opposite kidney which hypertrophies in



Fig.37.1.— When a patient experiences renal pain and he is asked to show with his hand the site of pain, this is the usual position of the hand of the patient as shown in the figure.

order to compensate the impaired function of its fellow. It must be remembered that many renal diseases are painless because their progression is so slow that capsular distension does not occur. Such diseases include cancer, chronic pyelonephritis, staghorn calculus, tuberculosis etc. The students are warned *not to use the term "Renal Colic". Colicky pain* only develops when a muscular conducting tube gets obstructed. In case of urinary organs such structure is the ureter and colic only develops from this structure. A severe renal pain which fluctuates in its severity is often called the 'renal colic' by mistake. This so called "colic" neither has the typical griping character nor disappears completely between the attacks.

URETERIC PAIN is mainly caused by acute obstruction either by passage of a stone or a blood clot. There is capsular distension along with severe *colicky pain* due to spasm of the renal pelvis and ureteric muscle. This characteristically starts from the renal angle and radiates downwards *along the course of the ureter,* around the waist obliquely across the abdomen to the groin, base of the penis and to the scrotum in case of males and to the labia majora in case of females and to the inner side of the upper part of the thigh. The point where this ureteric pain begins usually corresponds to the level of the obstruction. This is a *referred pain* due to common innervation of the upper ureter and the testis (T11-12) and the lower ureter and the inner side of the upper part of the thigh (L1, through genitofemoral nerve). The severity and colicky nature of this pain are caused by the hyperperistalsis and spasm of the smooth muscle of the ureter as it attempts to get rid of a foreign body. It is of griping nature and comes in waves with exacerbations and wanes. The pain passes off as suddenly as it came to give a pain-free interval between the attacks. The patient virtually tosses over the bed during the attacks trying in vain to get relief. This pain is often accompanied by nausea and vomiting.

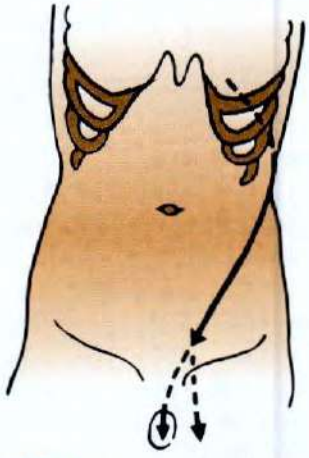

Fig.37.2.— Diagrammatic representation of radiation of pain in case of ureteric colic.

The patient often gives history that his attacks of colic follow episodes of jolting or unusual movements. Such history suggests that he

has a stone in the ureter, which moves by such jolting or unusual physical activity and thus causing the colic.

The clinician may be able to judge the position of the stone by the history of pain. If the stone is lodged in the upper ureter the pain radiates to the testicle (T11-12). When the stone is in the middle of the ureter the pain is referred to the McBurney's point on the right side resembling appendicitis and on the left side simulates diverticulitis (T12-L1). When the stone approaches the bladder, symptoms of vesical irritability appear and the pain may be referred to the penis, labia majora and inner side of the thigh.

VESICAL PAIN varies from mild discomfort to an intense strangury. Pain from bladder is usually dull, midline suprapubic pain which may become worse on micturition. *'Strangury' is a painful desire to micturate which starts in the bladder and radiates into the urethra, but it neither produces any urine nor relieves the pain.* The overdistended bladder in acute retention will cause agonising pain in the suprapubic area. Interstitial cystitis and vesical ulceration caused by tuberculosis or bilharziasis may cause suprapubic discomfort when the bladder becomes full and is usually relieved by urination. In chronic retention of urine the patient experiences little or no suprapubic discomfort even though the bladder reaches the umbilicus. Cystitis, the commonest cause of bladder pain, does not produce any pain over the suprapubic region but is referred to the distal urethra during micturition. Pain is often referred to the tip of the penis with or without haematuria towards the end of micturition and is diagnostic of vesical calculus. In children, vesical calculus is indicated by sudden screaming and pulling at the prepuce during micturition.

PROSTATIC PAIN is not common though occasionally come across when the prostate is inflamed. The patient may feel a vague discomfort or fullness in the perineal or rectal area (S2-4). It is often associated with difficulty in passing urine. Due to the location patient often thinks the pain is coming from the rectum. Throbbing pain in the perineum indicates prostatic abscess. Lumbosacral backache is occasionally experienced as referred pain from the prostate but is not a common symptom of prostatitis.

URETHRAL PAIN occurs during or at the end of micturition. Scalding pain during micturition is characteristic of acute urethritis.

2. **Swelling.**— Enquire about its *mode of onset, duration, progress* and *unilateral or bilateral*. Patient may present with a swelling in the loin. When a middle-aged man comes with such a swelling with short history one must suspect a carcinoma in the kidney. This may or may not be associated with haematuria. It is generally a painless condition. Similar painless swelling may be the presenting feature in case of children under the age of 5 years. This is characteristic of nephroblastoma. Sometimes a swelling with long history may become diminished in size immediately after passing urine. This is a case of intermittent hydronephrosis. Bilateral renal swelling in a man of 40 years of age is typical of polycystic disease of the kidney. One kidney may be affected earlier or may be more swollen than the other kidney to cause confusion to the diagnosis (the case is then considered to be unilateral swelling of the kidney).

3. **Haematuria.**— Bloody urine is a dangerous symptom which cannot be ignored. Enquiry must be made about its *quantity*, its *relation to micturition* — whether blood appears at the beginning of the act (urethral), towards the end of the act (vesical) or is intimately mixed throughout the process (prerenal, renal or vesical). Whether

haematuria is *associated with pain* or not? Some individuals will pass red urine after eating beets or taking laxatives containing phenolphthalein, in which case the urine is translucent and does not contain red cells. Sometimes children may pass red urine after ingestion of cakes, cold drinks, fruit juice containing rhodamine B. Haemoglobinuria following haemolytic syndromes may also cause the urine to be red. Details of the causes of haematuria have been discussed later in this chapter.

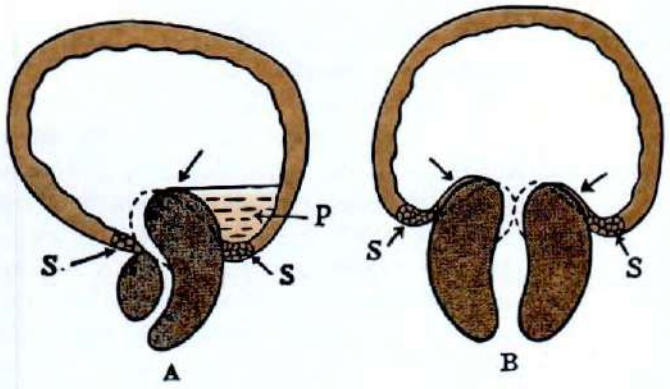

Figs.37.3 & 37.4.— Diagrams showing how straining hinders the act of micturition when the prostate is enlarged. *In the first figure* the median lobe is enlarged and straining increases the intravesical pressure depressing the median lobe forward thus occluding the internal urethral meatus. *In the second figure* the lateral two lobes are enlarged and increased intravesical pressure will lead to approximation of the intravesical parts of the lateral lobes and thus occludes the internal urethral meatus. 'P'— post prostatic pouch holding the residual urine; 'S' — internal sphincter, note that the prostate enlarges through the sphincter and causes urgency.

4. **Frequency of micturition.**— In a few diseases of the urinary system there will be increased frequency of micturition. Inflammation of the bladder and benign hypertrophy of the prostate are the most common conditions which cause increased frequency of micturition. Retention of urine in the bladder following inadequate emptying may be one of the important causes of the frequency of micturition. This is often first noticed at night, so the patient must be asked whether the frequency of micturition is more at night (nocturnal micturition) or not. 24 hours frequency should be recorded as a day/night ratio. The various causes of increased frequency of micturition are discussed later in this chapter.

5. **Difficulty in urination (Dysuria).**— Progressive loss of force and calibre of the urinary stream is noted as a man grows older. In case of prostatic obstruction there is a delay in starting the act of micturition. The stream instead of being projectile tends to fall vertically. The patient should be asked whether straining improves the stream (e.g. urethral stricture) or retards the stream (e.g. enlarged prostate — the median lobe pressing on the internal urethral meatus). Sudden stoppage of the stream during micturition is suggestive of a vesical calculus or pedunculated papilloma of the bladder, the micturition may be started again by changing posture.

6. **Retention of urine.**— When a patient fails to pass urine the condition is called retention of urine. There are two forms of retention — acute and chronic. Acute retention is painful whereas chronic retention is painless. When infection supervenes chronic retention the condition becomes painful. In acute retention the patient cries in agony urgently begging to be relieved. In chronic retention the bladder may be

distended upto the umbilicus, but the patient is absolutely ignorant of the condition and assumes a cheerful look.

7. **Anuria.**— In this condition urine is not excreted by the kidneys therefore the bladder remains empty. In retention urine is formed but it cannot be voided due to obstruction in the urethra, so the bladder becomes full of urine and distended. The causes of anuria are : (a) Prerenal e.g. shock; (b) Renal e.g. pyelonephritis, glomerulonephritis, incompatible blood transfusion, crush syndrome and renal tuberculosis; (c) Postrenal e.g. calculus anuria, accidental ligature of both ureters during the operation of hysterectomy.

8. **Discharge from the urethra.**— In acute gonococcal urethritis the discharge is profuse and purulent. In chronic urethritis or prostatitis a glairy fluid (gleet) is noticed to be discharged particularly in the morning just before micturition.

9. **Incontinence.**— There are many reasons of incontinence. The history often gives a clue to the diagnosis. There are five types of incontinence :— (a) *True incontinence* — when the patient passes urine without warning. It must be remembered that the bladder remains empty in this condition. (b) *False (overflow) incontinence* — when urine overflows from the distended bladder. (c) *Automatic bladder* — when there is periodic contraction of the bladder without patient's knowledge. (d) *Urgency incontinence* — when the patient feels urgency to pass urine and if it is not possible a few drops may come out. This occurs in acute cystitis particularly in women and in benign hypertrophy of prostate in men. (e) *Stress incontinence* — when a few drops of urine come out during physical strain (e.g. coughing, laughing, rising from a chair etc.) due to slight weakness of the sphincteric mechanism.

10. **Renal failure.**— Symptoms of renal failure such as headache, drowsiness, insomnia, thirst, hiccough, vomiting, convulsion etc. may be met with.

11. **Gastrointestinal syndromes.**— Patients with acute pyelonephritis will not only suffer from localized backache, fever, chill, rigor, symptoms of irritability but also from generalized abdominal pain and distension. Patients with ureteric colic often suffer from severe nausea, vomiting and abdominal distension. Afferent stimuli from the renal capsule or musculature of the pelvis may cause pylorospasm (symptoms of peptic ulcer) by reflex action. Inflammations and swellings of the kidney may produce symptoms due to displacement and irritation of the intraperitoneal viscera lying in close relation with the kidney concerned (e.g. hepatic flexure of the colon, the duodenum, the head of the pancreas, the liver and the gallbladder in case of the right kidney; whereas splenic flexure of the colon, tail of the pancreas and stomach in case of left kidney). The symptoms arising from chronic renal diseases (e.g. chronic pyelonephritis, hydronephrosis, staghorn calculus, cancer etc.) may in every way simulate those of other abdominal pathologies such as peptic ulcer, gallbladder, appendicitis etc. So, if a thorough survey of the G. I. tract does not reveal the cause of the symptoms, the clinician should keep every consideration to study the urinary tract.

Past History.— This is very much important and should never be omitted. Whether the patient had suffered from any urinary trouble before? If he had suffered from gonorrhoea, syphilis or tuberculosis? A patient, who had suffered from pulmonary tuberculosis or bone tuberculosis even in his childhood, if presents with vague symptoms this time (after about 20 years), may be suffering from tuberculous affection of the kidney. Enquiry must be made whether the patient was taking any medicine

or not. Phenacetin, cyclophosphamide, saccharine and excessive caffeine intake have been incriminated to cause bladder cancer.

PHYSICAL EXAMINATION

A. **GENERAL SURVEY.**— The tongue should be examined. Whether it is dry or moist (the protruded tongue is touched), clear or covered with white or brown fur. Whether the patient is drowsy or not. Dry and covered tongue with drowsiness and delirium are features of uraemia. Cachexia is sometimes detected in cases of malignancy of kidney, urinary bladder and in renal tuberculosis. Pulse and temperature are always recorded. Cheyne-Stokes respiration may be noticed in uraemia. Blood pressure is always examined, as hypertension is often present with various kidney diseases e.g. renal ischaemia, bilateral polycystic kidney, hydronephrosis, renal carcinoma etc. Skin is rough and dry and there is oedema of face in renal failure.

B. **LOCAL EXAMINATION.**—

1. **EXAMINATION OF THE KIDNEY.**—

INSPECTION.— In *recumbent position* a kidney swelling cannot be seen. However a huge kidney swelling of hydronephrosis or nephroblastoma in case of children may be seen as fullness of the corresponding lumbar region. The swelling moves slightly with respiration. In *sitting posture* from behind fullness of the area just below the last rib and lateral to the sacrospinalis muscle is more evident in case of renal swelling (particularly malignancy) and perinephric infection. Presence and persistence of indentations in the skin from lying on wrinkled sheets suggests oedema of the skin secondary to the perinephric abscess.

PALPATION.— The kidneys lie rather high under the lower ribs. The right kidney is slightly lower than the left. It is very difficult to palpate the kidney by traditional method of palpation of the abdomen. By this one can only feel the lower part of the



Fig.37.5.— Bimanual palpation of the kidney.



Fig.37.6.— The patient is turned laterally on his sound side. The diseased kidney is palpated bimanually as mentioned in the text. This is a useful method of palpating a kidney.

right kidney though with extreme difficulty. The best method of palpation of the kidney is by *bimanual palpation*. The patient lies on his back. A pillow is placed beneath the knees. One hand is placed behind the loin at the renal angle which is used to lift the kidney. The other hand is placed in front of the abdomen just below the costal margin. The patient is now asked to breathe deeply. With each phase of expiration when the abdominal musculature becomes more relaxed the hand in front is gradually pressed posteriorly. The hand behind is used to push the kidney anteriorly. After third or fourth expiration the hand in front is sufficiently pushed deep to feel the kidney, if it is palpable. Once the kidney can be felt, an attempt must be made *to feel the kidney during inspiration*. At this time the kidney moves downwards and the hand in front can trap the kidney and thus palpate the size, shape and consistency of the organ as it slips back into its normal position.

Another method of palpating the kidney is to ask the patient to lie on the sound side. The affected side is palpated by two hands in the similar way as has been discussed above. This is quite a useful method of palpating a kidney. *In case of new born babies* the hand is placed in such a way that the fingers will be on the renal angle and the thumb anteriorly. The two hands are used for two sides. The protagonists of this method have claimed it to be successful in 95% of cases.

In sitting posture one can feel the tenderness of the kidney and swelling quite effectively. The patient sits up and folds his arms in front so that the back is stretched enough for better palpation. The clinician presses his thumb on the renal angle formed by the lower border of the 12th rib and outer border of erector spinae. This sign is of great value in determining tenderness of the kidney. This is known as 'the renal angle test' or 'Murphy's kidney punch'.



Fig.37.7.— Eliciting tenderness in the kidney by pressing at the renal angle (Murphy's kidney punch).

A normal kidney is impalpable unless the patient is unusually thin. The *characteristics of a kidney swelling* are that (i) it lies in the loin or can be moved into the loin, (ii) it is of reniform shape, (iii) it is a ballottable swelling, (iv) it moves slightly with respiration, (v) there is always a band of colonic resonance anteriorly, (vi) it is dull posteriorly, (vii) however large may be in case of the renal swelling fingers can be insinuated between the costal margin and the swelling.

When palpable, note its size, shape, surface, consistency etc. Whether the consistency is solid or cystic. A solid renal swelling suggests compensatory hypertrophy, a neoplasm, advanced tuberculosis etc., whereas a cystic swelling is mainly due to hydronephrosis, pyonephrosis, a solitary cyst or polycystic kidney. Fluctuation can be elicited, though with difficulty, in a hydronephrosis or a large solitary cyst. In case of pyonephrosis this test cannot be positive due to inflammatory thickening of the



Fig.37.8.— A differentiating point between the renal swelling and splenic swelling is to percuss the loin just outside the erector spinae. This area is normally resonant due to the presence of colon. In case of renal swelling this area will be dull as the colon is pushed out by the swelling.

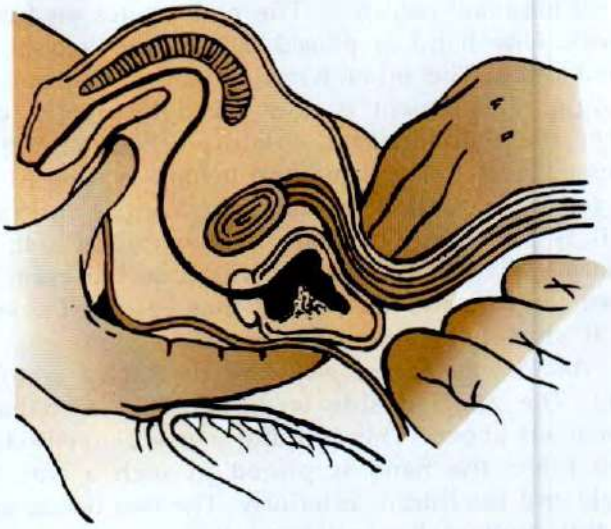

Fig.37.9.— Shows the method of bimanual palpation of the urinary bladder under general anaesthesia. Note the position of the finger in the rectum and the hand on suprapubic region. The vesical neoplasm is indicated by dots. This is the best way clinically to determine the stage of the bladder cancer (see "Carcinoma of Bladder" in 'A Concise Textbook Of Surgery' by Dr. S. Das).

surrounding tissues. Superficial oedema as evidenced by pitting on pressure, is suggestive of perinephric abscess.

Ballottement.— This is in fact a bimanual examination. With the patient supine one hand is insinuated behind the loin so that the pulps of the slightly flexed fingers are kept in contact with the area lateral to the erector spinae muscle and the other hand is laid flat on the abdomen so that the greater part of the flexor surfaces of the fingers overlie the kidney. Short, sharp, forward thrusts are made by the fingers of posteriorly placed hand (displacing). This will cause bouncing impact of the kidney swelling on the anteriorly placed hand (watching). So this is a ballottable swelling.

PERCUSSION.— Anteriorly, there is always a band of resonance due to the presence of colon and small intestine, unless the tumour is large enough to push them aside. If there is difficulty in eliciting colonic resonance one can inflate the colon with air by means of a rubber catheter introduced through the anus (Baldwin's method). Posteriorly, a dull note will always be present lateral to the erector spinae muscle. At times a greatly enlarged kidney cannot be felt on palpation, particularly if it be soft (e.g. a large hydronephrosis). This swelling can be readily outlined by percussion both anteriorly and posteriorly. Percussion has got a special value in outlining an enlarging mass following renal trauma (progressive haemorrhage) where tenderness and muscle spasm prevent proper palpation.

AUSCULTATION.— Its importance particularly lies in cases of stenosis or aneurysm

of the renal artery. A systolic bruit may be heard in these cases. Bruits may be heard over the femoral arteries in Leriche syndrome, which may be a cause of impotence.

2. **EXAMINATION OF THE URETER.**— Ureter cannot be felt. But its terminal part may occasionally be felt, particularly when it is pathological, through the vagina or rectum.

3. **EXAMINATION OF THE BLADDER.**— Bladder is a pelvic organ. It reaches abdomen when it is distended. At this time it can be palpated as an oval swelling just above the symphysis pubis. At least 150 ml of urine must be collected in the bladder to make it palpable above symphysis pubis. The swelling is elastic in feel and dull on percussion. Pressure induces a desire for micturition. In case of a swelling in the lower abdomen, one should always catheterise the bladder before examination is started. Many a swelling will be melted away by such catheterisation. Sometimes in case of children a thickened hypertrophied bladder may be felt above symphysis pubis secondary to obstruction caused by posterior urethral valves. *Bimanual palpation* (abdominorectal or abdominovaginal) is the best way to determine the extent of vesical neoplasm. It must be done under general anaesthesia. The finger in the rectum in case of male is pushed anteriorly above the prostate, whereas the other hand of the clinician is placed on suprapubic region and is gradually pressed posteriorly. Thus the urinary bladder is felt bimanually (see Fig. 37.9).

4. **EXAMINATION OF THE PROSTATE.**— Prostate can only be palpated per rectum. The patient must empty his bladder first. If possible, watch the act of micturition — 'how much is the loss of projectile force?' It is again emphasised that before doing rectal examination palpate the abdomen particularly the suprapubic region to know if the bladder is totally empty or not. Even after micturition if the bladder is not empty, this finding is important and predicts that the rectal examination will not be very reliable in providing necessary informations regarding the prostate. The findings of rectal examination are discussed below in the section of 'Rectal Examination'. Rectal examination for prostate is usually performed in Knee-elbow position or left lateral position. *Bimanual palpation* (abdominorectal or abdominovaginal) in lithotomy position is sometimes required. By this examination intravesical lobe of prostate can be felt. Fixity of this lobe in carcinoma can be ascertained. Residual urine in the post-prostatic pouch can be felt as a soft swelling above the prostate. Seminal vesicles can be well palpated by this technique.

5. **EXAMINATION OF THE URETHRA** — for any discharge, fistula, tenderness, calculus or foreign body should be performed. In some instance, stricture may be felt as firm thickening.

6. **EXAMINATION OF THE EXTERNAL GENITALIA** is described in chapter 40.

7. **EXAMINATION OF THE PERINEUM** for swelling, redness and oedema (periurethral abscess or perineal haematoma). Note if there are urethral fistulas.

8. **RECTAL EXAMINATION.**— This examination is of tremendous importance in case of male patients. The prostate, the seminal vesicles and lower part of the base of the bladder can only be palpated through rectum. Rectal examination should be started by noting the tone of the external sphincter. Laxity of the sphincter suggests similar change in the urinary sphincter. Before proceeding to palpate the seminal vesicles it is customary to rule out pathologies in the lower part of the rectum and anal canal.

While palpating for the **prostate** the following points should be noted : (i) The *size.*— Gradually the students will learn what is the normal size of prostate while palpating through the rectum. This is attained by practice. But it must be remembered that the clinical importance of prostatic hyperplasia is measured by the severity of symptoms and the amount of residual urine, and not by the size of the gland. (ii) *Consistency.*— Normally the consistency of the prostate is like a rubber. It becomes mushy when congested, becomes indurated in chronic infection with or without calculi and becomes stony hard in carcinoma. (iii) *Surface* — whether smooth or irregular. (iv) Whether the *median groove* and the *lateral sulci* can be felt. It must be remembered that enlargement of median lobe may not be detected by rectal examination. But one can palpate this lobe per rectum with introduction of a urethral bougie. (v) *Mobility of the rectal mucosa* over the prostate is an important point to differentiate benign enlargement from malignant diseases of the prostate. (vi) *Prostatic massage* is important particularly in case of asymptomatic prostatitis. Diagnosis of such silent disease is important in preventing cystitis and epididymitis. Prostate should *not* be massaged in acute prostatitis, acute urethritis and obvious cancer of prostate.

Normally **seminal vesicles** are not palpable. They can only be palpated when they are diseased. These are best palpated in knee-elbow position. In case of acute inflammation (commonly gonococcal or E. coli) the vesicles feel cystic and tender. In case of chronic infection, particularly in tuberculous disease, they feel indurated and irregular.

The **base of the bladder** is also not felt normally per rectum. But a vesical calculus may be palpable per rectum. Malignant growth of the bladder can be well felt per rectum and bimanual palpation (abdominorectal in males and abdominovaginal in females) should always be performed under general anaesthesia to detect the actual extent of the disease.

GENERAL EXAMINATION

Heart should be examined in case of suspected renal hypertension. **Lungs** should be examined in tuberculous affection of the kidneys as well as the seminal vesicles. Renal carcinoma mainly spreads by blood, and lungs are the commonest site of metastasis. So lungs should be examined as a routine in case of cancer of the kidney. One should examine for **Parathyroid** enlargement in recurrent renal calculi cases. One should also look for presence of other congenital abnormalities in cases of congenital anomalies of the kidney and ureter e.g. double ureter, horseshoe kidney etc.

Radicular pain is often confused as kidney pain. Every patient who complains of flank pain should be examined for evidence of nerve root irritation. Arthritic changes in the costovertebral or costotransverse joints, hypertrophy of costovertebral ligaments pressing on a nerve, intervertebral disc disease and impingement of a rib spur on a subcostal nerve are the causes of such irritation. Radiculitis usually causes hyperaesthesia of the area of skin supplied by the irritated peripheral nerve. Pressure exerted by the thumb over the costovertebral joints will reveal local tenderness at the point of emergence of the involved peripheral nerve.

SPECIAL INVESTIGATIONS

1. **BLOOD.**— Erythrocytosis has been noted in association with renal carcinoma. The erythropoietin level in the plasma is also increased. Following radical surgery erythropoietin level and increased red cell count return to normal level. It is interesting to note that if metastases develop later erythrocytosis returns. Hypochromic anaemia sometimes occurs in association with pyelonephritis, uraemia and even carcinoma. Immunoassay examination of the blood for certain tumour markers is now possible. CEA (Carcinoembryogenic Antigen) level becomes high in adenocarcinoma of the kidney. Alpha fetoprotein level also goes up in case of carcinoma of urinary bladder.

2. **URINE.**— Proper collection of urine is of utmost importance. In both men and women the urethra harbours bacteria and few pus cells. Mid-stream urine should be collected for examination. In an infected case '2-glass' test affords valuable information. Urine is first voided in a test tube for about 10-15 ml and then the stream is directed to the 2nd test tube for the same amount of sample. Turbidity in the first glass suggests urethritis whereas turbidity in the 2nd glass suggests cystitis. First of all general microscopic examination of the urine should be performed for presence of R.B.C., crystals of oxalates, phosphates or cystine, bacteria, pus cells and malignant cells. *Cytological examination* of urinary sediment is sensitive and specific for poorly differentiated cancer cells anywhere in the urinary tract. Culture in ordinary or special culture media should be performed if bacteria and/or pus cells are detected in the urine. Sensitivity test to various antibiotics (antibiogram) should be performed when the culture becomes positive. Animal (guineapig) inoculation test is important if tuberculosis is suspected. When the urine is acid in reaction, contains pus cells and is sterile in ordinary culture, one should suspect renal tuberculosis. Acid-fast staining should be performed with the centrifuged sediments from 15 ml of urine. It will reveal tubercle bacilli in about 70 to 80% of cases. This may be confirmed by animal inoculation test or better by special culture. In the latter case the result is obtained in three weeks instead of six weeks as in animal inoculation. Urinary pH is important. It ranges normally from 4.5 to 7.5. A figure below 4.5 is typical of diabetic acidosis whereas a figure above 7.5 suggests presence of urea-splitting organisms. *Specific gravity* of the urine is also examined particularly of the morning sample collected after 12 hours of overnight restriction of fluid. The specific gravity of this urine is normally about 1.020. If this specific gravity becomes less than 1.010 it is indicative of renal failure.

Dipsticks impregnated with chemicals which change colour in presence of blood, sugar or protein are convenient way to screen urine for various abnormalities. These (Multistix or Labstix) are often used nowadays.

3. **RENAL FUNCTION TESTS.**— (a) *Protein urea.*— Amount of protein upto 100 mg per 24 hours is normal. Heavy protein urea is seen in nephrosis and at times glomerulo-nephritis. (b) *Specific gravity* of urine is a simple and significant test of renal function. Kidneys can concentrate upto 1.040 at the age below 40 and about 1.030 at the age of 50. Specific gravity of urine voided in the early morning is important and if it is less than 1.010 one may suspect poor function of the kidneys. (c) The *PSP* test.— The patient is instructed to pass urine. Exactly 1 ml of phenol-sulphonaphthalein





Figs.37.10 & 37.11.— Lateral views showing a renal stone *in the first figure* superimposed on the shadow of the vertebral column and gallstone *in the second figure* in front of the vertebral column.

is given intravenously. The patient is allowed to drink no more than 20 ml of water during each of the two subsequent half hour periods. Urine specimens are collected at half-hour intervals. The average amount of dye normally recovered in the first half-hour sample is 50 to 60%, the 2nd sample contains 10 to 15% (thus one hour excretion is about 60 to 75%). The P.S.P. test is a test of renal blood flow and tubular function. (d) *Creatinine clearance.*— The normal values vary between 72 to 140 ml/min. (e) *Blood nitrogen levels.*— In the adult the upper limits of normal are — creatinine 1.4 mg/100 ml and blood urea nitrogen 20 mg/100 ml.

Levels of blood urea and serum creatinine are useful clinical guide to overall renal function. Creatinine clearance will give an approximate value for glomerular filtration rate. Estimation of clearance of chromium -51-labelled ethylenediaminetetra-acetic acid is probably more accurate in this respect. It must be remembered that kidneys have large functional reserve and 70% of function of kidneys must be lost before renal failure becomes evident in various tests.

4. **CATHETERISATION and RESIDUAL URINE.**— Introduction of a catheter may determine the type of obstruction in the urethra. With an enlarged prostate, obstruction is encountered after the catheter has gone beyond the apex of the prostate (i.e. above the perineal membrane) due to the kinking of the prostatic urethra. In case of urethral stricture, obstruction is obtained below the perineal membrane since the bulb of the urethra is the commonest site of stricture formation. The position of the obstruction can be further determined by a finger in the rectum. The *residual urine* i.e. the amount of urine collected by means of a catheter after the patient has voided urine is a good indication of the capacity of the retroprostatic pouch particularly in case of prostatic enlargement.

5. **X-RAY EXAMINATION (STRAIGHT X-RAY).**— *Preparation of the patient.*— No food or fluids should be given to the patient for at least 6 hours before X-ray examination. A purgative is given the night before. Enema is sometimes prescribed but it is probably less effective. Plain film of the abdomen is taken of the kidney, ureter and bladder region (KUB region).

It gives a clue to the diagnosis if properly studied.



Fig.37.12.— Ureteric stone near the ischial spine.

(a) **KIDNEY** — size can be assessed from this film. Congenital absence or unascended kidneys can be diagnosed. Similarly an enlarged kidney from hydronephrosis, polycystic disease or renal cancer can be diagnosed. A normal kidney extends from the top of the 1st to the bottom of the 3rd or middle of the 4th lumbar vertebra. In 90% of cases the right kidney is lower than the left because of displacement by the liver. Localized swelling as may be caused by a carbuncle, a tubercular cyst, a simple cyst or a tumour can be diagnosed.

(b) **STONES.**— Majority of the urinary calculi are radio-opaque except the pure uric acid stone which is not common. It is very difficult to assess the exact position of the radio-opaque stone in straight X-ray of the abdomen. A lateral view or visualization of the urinary tract with radio-opaque dye is necessary. Numerous small calcific bodies in the parenchyma of the kidney may suggest tuberculosis or medullary sponge kidney or nephro-calcinosis caused by hyperparathyroidism. About 7% of malignant renal tumours contain some calcification.



Fig.37.13.— Vesical calculus. Note its rough surface. This is typical of an oxalate stone.

A renal calculus has to be differentiated from (i) a gallstone, (ii) calcified lymph nodes, (iii) calcified costal cartilage, (iv) phlebolith, (v) calcified aneurysm of the abdominal aorta or renal artery and (vi) small calcific bodies in the substance of a kidney as discussed above. A stone in the appendix or a faecolith in the colon may be confused with a stone in the ureter. *It must be remembered that for the diagnosis of a stone either in the kidney, ureter or bladder, a straight film is all that is required, not a urogram.* Even dense round shadows in urogram may not be due to stone. They are often caused by the depths of the dye inside the end-on calyces (i.e. those directed anteriorly or posteriorly).

The *characteristics of a renal stone are*: (i) That a renal calculus moves with respiration which can be verified by taking two exposures, one at full inspiration and the other at full expiration. (ii) Density of a renal stone is uniform whereas gallstones are less dense in the centre. (iii) Renal stones take the shape of the renal pelvis and calyces whereas a solitary gallstone may be round and multiple gallstones are squeezed into the gallbladder and become faceted. (iv) In lateral view the renal stone lies superimposed on the shadow of the vertebral column, whereas gallstones are seen in front of the vertebral bodies.

Ureteric stone is usually oval and lies in the line of the ureter. It is an imaginary line passing along the tips of the transverse processes of the lumbar vertebrae, over the sacro-iliac joint, down to the ischial spine from where this line deviates medially. *Vesical calculi* are seen just above the symphysis pubis. The *prostatic calculi* appear as small dots behind the symphysis pubis.

(c) **PSOAS SHADOWS** are normally seen quite distinctly. Obscure psoas shadows mean perinephric haematoma, abscess or cold abscess.

(d) **BONES** should be carefully noticed to detect any arthritic change or presence of metastases (either osteolytic — commonly seen in a renal carcinoma or osteoblastic — commonly seen in prostatic carcinoma). Arthritic changes may well lead to radicular pain which may mimic a renal pain.

(e) **TOMOGRAPHY** will enhance the renal and psoas outlines thus clarifying renal size and shape. It may also reveal zones of calcification invisible in the plain film. A space-occupying lesion of the renal pelvis revealed in excretory urogram may show a faint opaque body compatible with stone but not tumour in the tomogram studies.

6. **EXCRETORY UROGRAMS.**— This is probably a better nomenclature than intravenous pyelography (IVP), since this does not only reveal the picture of the pelvis of the kidney, but also of the kidney, calyces, ureters and the urinary bladder. It is also called intravenous urography.

Preparation of the patient has been described in section 5. A straight X-ray of the abdomen (particularly the KUB region) is first taken. Then the radio-opaque fluid is injected intravenously. Generally Hypaque (sodium diatrizoate) or Urografin is injected. Adult dose is about 20-25 ml injection is made slowly. Preliminary test of hypersensitivity is always performed. Subcutaneous injection of 0.1 ml of the contrast medium is made. If induration and erythema develop promptly the test is positive. If symptoms and signs of hypersensitivity appear during injection, it should be stopped immediately. Warning signs are respiratory difficulty, itching, urticaria, nausea, vomiting and fainting.

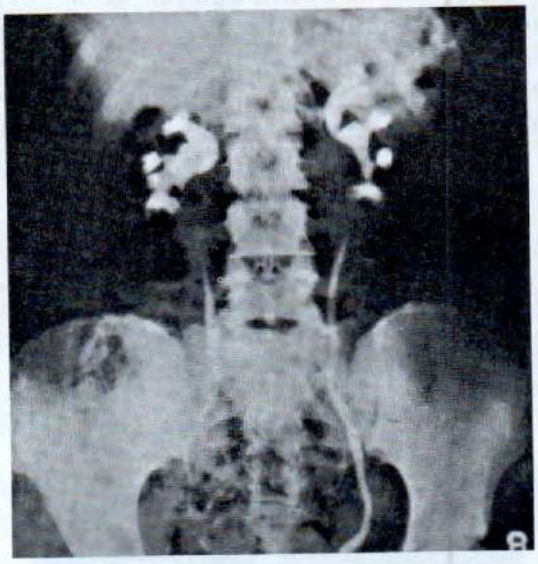

Fig.37.14.— Excretory urogram showing cavities suggesting cavernous tuberculosis.

Treatment consists of oxygen and intravenous dextrose for shock, intravenous injection of antihistaminic drug and intravenous injection of barbiturates for convulsion.

Routine radiograms are taken at 10 seconds for nephrogram effect and at 5, 10 and 15 minutes with the patient in supine position. For hypertensive patients films should be taken 2 and 3 minutes after the beginning of the injection. Delayed concentration of dye in one kidney may suggest decreased renal blood flow and function. At 25 minutes a film is taken in erect posture to note the efficiency with which the renal pelvis and ureters drain, ureterograms and also the mobility of the kidneys. All films should include kidney, ureter and bladder areas, as fine changes in the ureters which imply the presence of vesico-ureteral reflux may be detected. It is advisable to inject additional radio-opaque medium if there is impaired concentration in the initial films.

In infants and children the films should be taken at 3, 5, 8 and 12 minutes as their kidneys excrete the fluid more rapidly than do those of the adults.

X-ray of the bladder region after voiding should be routine in all urologic patients. At the conclusion of the urographic study, the patient is instructed to pass urine and a film of the bladder area is taken immediately. This will demonstrate the presence or absence of residual urine.

Excretory urogram is contraindicated in (i) allergic patients, (ii) multiple myeloma (the dye makes insoluble complex with Bence-Jones protein and precipitate in the renal tubules), (iii) congenital adrenal hyperplasia, (iv) diabetes and (v) primary hyperparathyroidism.

Excretory urogram is a physiological and as well as an anatomical test since it not only determines the function of the kidney but also clearly demonstrates the contour of the renal pelvis and calyces.

INTRAVENOUS INFUSION UROGRAPHY.— This is indicated when there is a huge hydronephrosis or there is certain amount of renal failure (blood urea is in the range of 100 mg). About 2 ml per kg body weight of contrast medium in an equal volume of normal saline is infused in a subcutaneous vein slowly for over a period of 10 minutes. The films are taken at longer intervals.

SUBCUTANEOUS INFUSION UROGRAPHY.— When a proper subcutaneous vein cannot be obtained for intravenous urography, this procedure is adopted. Diluted contrast medium is infused into the subcutaneous tissue alongwith hyaluronidase (hylase).

7. **RETROGRADE UROGRAMS.**— INDICATIONS.— (i) *Inadequate excretory urograms* which have failed to demonstrate the renal pelvis, calyces and the ureters adequately, this investigation will be required. (ii) *Impaired renal function* which has failed to show the pelvis and calyces, this test is needed. (iii) *Sensitivity to intravenous contrast medium* is the definite indication for this test. (iv) If *pyuria is present* catheterization of the ureters may be needed to obtain separate specimens from each kidney for bacteriological study and then retrograde urograms may be performed. (v) Since in intravenous urogram the density of the dye may not be sufficient *for oblique and lateral radiograms*, retrograde urogram will be required.

PROCEDURE.— (a) Preparation of the patient is similar to that of excretory urogram except for the fact that the patient may be allowed to take fluids unless general anaesthesia is to be employed.

(b) Cystoscopy and ureteral catheterization are performed.



Fig.37.15.—Intravenous pylogram showing double kidney. The normal upper kidney shows cupping of the minor calyces and the lower one shows inward direction of the calyces — a congenital abnormality.

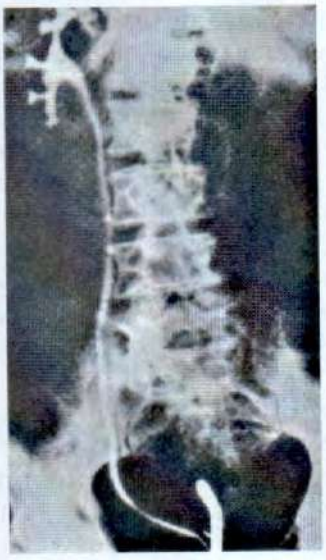

Fig.37.16.— Retrograde urogram showing normal cupping of the minor calyces. Note the end of the catheterising cystoscope lying within the bladder.



Fig.37.17.— Retrograde urogram showing polycystic kidney with 'spider-leg' elongation of the calyces.

(c) Preliminary straight X-ray of the abdomen is taken to know the positions of the catheters besides the points already discussed earlier.

(d) 25% sodium diatrizoate (Hypaque) is used as the contrast medium and 3 to 5 ml is first introduced to delineate normal size pelvis. For hydronephrosis more amount of medium is required.

(e) Supine urogram is taken, developed and viewed. If filling is not complete, more dye is instilled before further X-rays are taken.

(f) Oblique, lateral and upright radiograms are taken as indicated.

(g) Pneumopyelography.— To differentiate between a non-opaque stone and a papillary tumour of the renal pelvis, 4-6 ml of air is instilled into the catheters. A stone may show some opacification, but a tumour will not, but both these will cause a filling defect in the pelvis or calyx in excretory urogram.

8. **ANTEGRADE UROGRAM.**— The clinical indication for this test is inadequate information from intravenous urogram with an unsuccessful or impossible retrograde examination. Under fluoroscopic or ultrasonic control an 18-gauge needle, 15 cm long should be passed into a dilated calyx or pelvis. Radio-opaque dye should then be instilled and appropriate films are taken. It is better to pass the needle into a dilated calyx rather than pelvis as there will be a better seal round the needle track and less danger of puncturing large hilar vessels. Temporary drainage can also be provided with by a small plastic catheter introduced through the needle, which will be subsequently removed. The tube now act as nephrostomy tube.

FINDINGS.— All urograms, be it excretory, retrograde or antegrade are read in the following manner:

A. *Nephrogram.*— From the soft tissue shadow of the kidney, various congenital deformities can be detected. Any tumour or cyst can be suspected. The position and sizecan be assessed.

B. *Calyces.*— A normal calyx looks like a cup due to projection of the apices of the papillae into the calyces. The calyces are directed outwards. Inward directed calyces suggest congenital abnormality such as horese-shoe shaped kidney.

C. *Pelvis.*— The size, shape and position of the pelvis are noted. The lower border of the pelvis forms a uniform curve with the lower calyx. The right pelvi-ureteric junction is situated opposite the transverse process of the second lumbar vertebra whereas the left is slightly higher up. The most important is the shape of the pelvis and the students must learn the normal shape of the pelvis.



Fig.37.18.— Urogram showing the 'spider-leg' deformity due to adenocarcinoma (T) outlined by dots.

D. *The ureter.*— Usually the upper portion of the ureter is visualized. If the whole of the ureter is seen there must be an obstruction further down. Note the shape — whether dilated or not. Dilated ureter indicates obstruction or vesico-ureteral reflux. Also look at the position of the ureter, whether it is kinking or not and whether there is any congenital deformity or not.

9. **CYSTOGRAMS.**— (a) *Excretory cystograms* can be obtained as later films of excretory urograms. If these are not satisfied to delineate clearly the pathological conditions of the bladder, retrograde cystogram may be required.

(b) *Retrograde cystograms* are performed by instilling radio-opaque fluid into the bladder through a catheter. This will outline the bladder-wall including the diverticula. Besides these, this test has a diagnostic value in rupture of the bladder and recurrent infection (vesico-ureteral reflux is the commonest cause of perpetuation of infection).

(c) *Voiding cystourethrograms* are essential as increased intravesical pressure generated at the time of voiding will show ureteral reflux when cystogram has failed to detect it. This will also reveal function of the bladder neck, presence of posterior urethral valves or urethral stricture.

10. **URETHROGRAPHY.**— Water soluble viscous solution like Umbradil viscous V is often used. This investigation is of special value to know the length of the stricture, presence of diverticulum etc. Its importance also lies in revealing the dilated prostatic ducts in chronic or tuberculous prostatitis and bladder neck obstruction. The dye is pushed with some local anaesthetic (lignocaine 20%) by a special Knutsson's apparatus which has a penile clamp.

11. **CYSTOSCOPY.**— This is the most important urological investigation. It not only reveals all the pathological processes inside the bladder e.g. cystitis, tuberculous affection, stone, growth, diverticulum, enlarged prostate etc., but also detect some

involving the kidney and ureter. The ureteric orifices are situated at 4 O'clock and 8 O'clock positions. By rotating the cystoscope the orifices should be noticed carefully. Note the efflux of urine. *Chromocystoscopy* can be employed to find out the ureteric orifices as also the function of the kidney. 5 ml of 0.4 per cent sterile solution of indigocarmine is injected intravenously. Normally a blue jet will be seen to emerge from the ureteric orifices within 3 to 5 minutes. Delay indicates partial obstruction. Feeble efflux or non-appearance means impaired renal function. *In case of haematuria,* cystoscopy should be performed *at the time of bleeding* to detect which kidney is bleeding. But when bleeding is coming from the bladder, cystoscopy should be repeated *when bleeding has ceased.*

12. **URETERIC CATHETERISATION** is another important method of investigation. This is performed through a catheterising cystoscope. Its indications are : (i) to collect specimen of urine from individual kidney for 'split' renal function test; (ii) to perform retrograde urography; (iii) in anuria; (iv) to dislodge ureteric stone; (v) in case of stone in the lower 1/3 of the ureter Dormia basket may be passed through the ureteric orifice to extract the stone.

13. **URETHROSCOPY.**— *Anterior urethroscopy* is conducted under air inflation. It is indicated in stricture, foreign body and chronic urethritis.

Posterior urethroscopy is conducted by irrigating urethroscope. Through this the membraneous part and the prostatic part of the urethra can be inspected. Verumontanum is an eminence on the posterior aspect of the prostatic urethra at the apex of which is the sinus pocularis on each side of which the two ejaculatory ducts open. This will be reddened and dilated in chronic vesiculitis. Numerous prostatic ducts can be seen which will be enlarged and will be seen extruding pus.

14. **NEPHROSCOPY.**— This procedure is now often used in different urologic units to detect various lesions of the kidney. It may be performed either percutaneously i.e. percutaneous nephroscopy (PCN) or by retrograde route i.e. ureterorenoscopy (URS).

15. **ANGIONEPHROTOMOGRAMS** (Intravenous renal angiogram).— In this investigation a bolus of radio-opaque medium (30-50 ml of 90% Hypaque) is injected inside a vein (antecubital vein) rapidly, 4-6 tomograms are taken. This is an efficient method to differentiate a cyst from a tumour. Space occupied by a cyst or abscess fails to opacify, whereas a malignant tumour shows a normal or increased opacification. Renal angiography is, however, more efficient in this differential diagnosis.

16. **RENAL ANGIOGRAPHY.**— Although renal angiogram can be performed by direct lumbar needle puncture of the aorta, yet this technique has been superseded by percutaneous femoral angiography. A catheter is passed to the level of the renal arteries under fluoroscopic control. It is also possible to do the catheterisation through the brachial or axillary artery. 12 to 24 ml of radio-opaque fluid suitable for intravenous urography is injected and 10 exposures are taken in 10 seconds time.

Selective renal angiography is accomplished by passing a femoral catheter into one of the renal arteries under fluoroscopic control. About 8 ml of the contrast medium is injected and 16 exposures are taken within a few seconds. This technique gives detailed demonstration of the arterial pattern in the kidney and thus differentiates efficiently between renal cyst and tumour. If this technique also fails to differentiate in case of small lesion or gets obscured by overlying arteries, epinephrine can first be injected into the catheter followed by instillation of radio-opaque medium. This

technique causes spasm of normal vessels but has no effect on arteries in tumours.

17. **VESICAL ANGIOGRAPHY.**— A Seldinger catheter is passed to the bifurcation of the aorta and 30 ml of 90% contrast medium is injected. Alternatively each hypogastric artery is selectively catheterized and 10 ml of radio-opaque fluid is injected. Films are rapidly exposed in first 8 seconds. The series are repeated in oblique position to give tangential view of the tumour. This technique is occasionally required to judge the size and depth of penetration of the vesical neoplasms. Typical 'stain' of an invasive tumour can be revealed in X-ray.



Fig.37.19.— Renal angiography showing the typical filling defect at the origin of the renal artery due to atheroma.

18. **DIGITAL SUBTRACTION ARTERIOGRAPHY** (DSA).— Satisfactory imaging of the renal vessels can be achieved by this technique after intravenous injection of contrast medium, though intra-arterial injection with a fine catheter inserted through the femoral artery using Seldinger technique offers more precise information. Nowadays flush venogram is more popular than arteriography in diagnosing renal carcinoma, where CT indicates tumour invasion of the renal vein. This is comparatively a newer technique and not available in many institutions in Indian subcontinent.

19. **LYMPHANGIOGRAPHY.**— A lymphatic vessel in the foot is cannulated and oily contrast medium is injected. This leads to opacification of the inguinal, pelvic, aortic groups and supraclavicular lymph nodes. Metastatic infiltration can be demonstrated in regional lymph nodes by filling defect in malignant tumours of the testis, prostate, bladder and penis.

20. **COMPUTED TOMOGRAPHY** (CT Scan).— In this examination the detector system is usually a scintillation phototube or gas-filled ionization chamber and not the X-ray film as in conventional radiography. The X-ray tube and the detector system are on opposite sides of the patient and during a scan they rotate around the patient recording informations about the internal structures of the thin transverse cross-section through which the X-ray beam is passing. Through a complex series of mathematical manipulations the computer 'reconstructs' and displays it as an integrated picture on a television monitor. In this examination, a renal mass is considered to be a simple benign cyst if it has a homogeneous density similar to that of water and has a very thin wall thickness that is virtually immeasurable. A renal cancer has density similar to or slightly higher than that of normal renal parenchyma but has a thick wall which is more significant.

It is customary that if urography demonstrates a solitary renal mass, it has to be evaluated by diagnostic ultrasound. If ultrasound demonstrates all the findings of a simple benign cyst, there is no reason to perform any other diagnostic imaging examination. Only if ultrasound fails to show any convincing result, CT offers an accurate and non-invasive method of evaluating the lesion. The most frequent causes of indeterminate results from ultrasound are (i) a mass in the upper pole of the kidney, (ii) a mass in the region of the renal pelvis, (iii) presence of multiple renal masses and (iv) markedly obese patient. CT is as accurate as angiography in determining the local extent of the cancer, presence of enlarged lymph nodes and presence of tumour thrombus within the renal vein and inferior vena cava.



Fig.37.20.— Secondary deposit (Cannon-ball appearance) at the right lower lung from renal cell carcinoma of the kidney.

Lymph nodes between renal hilum and the diaphragm are not adequately visualized by lymphography, but usually well delineated by CT. With the advance in technology in CT, lymphangiography should be reserved for suspected metastasis in normal-size lymph nodes. CT is accurate for staging of bladder cancer. Value of CT in the staging of prostatic cancer has not been adequately evaluated.

21. **ULTRASOUND.**— With the static B scanner, the transducer is moved at a constant speed in a single sweep along the skin overlying the organ to be imaged. Conventional static B scan and real time instruments also visualize the bladder and prostate with the patient supine. Any change of renal outline and diaplacement or fragmentation of the collecting system of echoes is of pathological significance. With ultrasound, agenesis, hypoplasia, duplex or ectopic kidney can be diagnosed. Cysts can be differentiated from renal carcinomas. In case of haematuria, even if the intravenous urogram is normal, ultrasound can detect a peripheral lesion that does not deform the calyceal system or renal outline. Renal sonography should follow urography in evaluation of a renal mass. Renal sonography should be followed by percutaneous puncture (under sonographic visualization). If aspiration reveals clear fluid and the area is smooth-walled as demonstrated in X-ray following injection of a contrast medium, no further investigation is required. If sonogram fails to show the pattern of solid mass, arteriography is advised. Sonography is about 95% accurate in distinguishing between solid and cystic renal masses.

Large renal calculi can be diagnosed. Even exact position of a small calculus can be determined during operation by the application of a transducer direct to the kidney surface. A small needle can be passed through a slot guide of the probe to the stone.

B Scanning of the bladder has been used to evaluate the intravesical extent of

tumours. The *transrectal approach* is useful in detecting early asymptomatic tumours of the prostate and in accurately staging local disease of the prostate. This is now a routine investigation in carcinoma prostate.

22. **RADIOISOTOPE RENOGRAPHY.**— 100 Ci of I^{131}-labelled hippuran is injected I.V. and radioactivity is measured over each kidney with a pair of scintillation detector. The tracing is in three segments — segment A (vascular phase) with a steep rise lasting 20-30 seconds due to the arrival of radioisotopes in the vascular bed; segment B (secretory phase) lasting for 2-5 mins. due to accumulation by the kidney and its subsequent secretion; segment C (excretory phase) indicates gradual tubular excretion. In renal hypertension the rise is too little (segment A) and prolongation of third phase. In obstruction, the third phase is abnormally prolonged. It is the actual pattern of tracing which is more important. Function of kidney is very well assessed with this technique.

23. **RENAL SCINTISCAN.**— This consists of measuring the rate of accumulation of ^{197}Hg-labelled neohydrin using an external detector upto 1 hour after injection. This test is not so efficient to determine the function of kidney as the previous test, but in injury, it shows the portion of kidney affected and supersedes the previous test to determine the type of operation to be required.

24. **MAGNETIC RESONANCE IMAGING (MRI).**— This is not superior to a good-quality CT. Still it may be used to know the local extent of bladder, prostate or kidney malignancies. Positron emission tomography may be better in staging urological malignancies.

25. **SERUM ACID AND ALKALINE PHOSPHATASE.**— *Acid phosphatase* is present in small amount in normal blood serum (1-4 units). It is elevated in prostatic carcinoma with metastasis (10 units or more), but not so as long as the growth remains confined to the gland. It comes from the cancer cells but does not enter circulation as long as the capsule of the prostate is intact. *Alkaline phosphatase* is secreted by the liver. It enters the circulation from bone. When metastasis in bone occurs in prostatic carcinoma its level is elevated in the serum. It is well recognized fact that osseous metastasis in prostatic carcinoma is *osteosclerotic*, rather than osteolytic in character. *This is due to the elevation of alkaline phosphatase level.*

26. **CHEST X-RAY.**— This is important to exclude blood-borne metastasis in the lungs. This is also used to exclude pulmonary tuberculosis in suspected cases of renal tuberculosis.

27. **BIOPSY.**— In suspected prostatic carcinoma, a specimen of prostatic tissue may be obtained by transurethral resection or by aspiration with a needle through the perineum or through rectum and examined histologically. Very often bone marrow aspiration from the sternum or ilium reveals carcinoma cells even before the radiological evidence of metastasis.

28. **SMEARS** from the urethra or prostate (expressed by massage) should be examined microscopically for evidence of infection, when this is suspected. In carcinoma of the prostate, secretion obtained by prostatic massage may show cancer cells (exfoliate cytology).

29. **LAPAROSCOPY** — may be used to visualize intraperitoneal metastatic spread from a malignant lesion in the urinary system.

DIFFERENTIAL DIAGNOSIS

DISEASES OF THE KIDNEY

HORSE-SHOE KIDNEY.— Primary mesonephric buds which form the kidney on each side fuse when the embryo is only 30 to 40 days old. Usually the lower poles fuse. This kidney cannot ascend to its normal position. The bridge joining the lower poles lies in front of the fourth lumbar vertebra.

As the ureters are angulated as they pass over the fused isthmus, urinary stasis and stone formation are the usual complications. Tuberculosis and tumour formation are also noticed in this kidney. Horse-shoe kidney is as such asymptomatic and only presents when the above complications appear.

Diagnosis is mainly confirmed by urography. Medially directed lowest calyx is confirmatory. Calyces of a normal kidney look outwards. Only occasionally, all the calyces of the horse-shoe kidney may look inwards.

POLYCYSTIC KIDNEY.— This disease is slightly more common in women. Infantile polycystic kidney disease is an hereditary autosomal recessive condition and is often fatal in the neonate.

Adult Polycystic Disease is an autosomal dominant condition and typically presents in mid-adult life (30 to 40 years). When an adult presents with bilateral renal swellings with dragging pain in the loin and haematuria in about 1/4th cases, the case is one of polycystic kidney. In case of unilateral renal swelling diagnosis becomes more difficult. This is seen when one kidney contains larger cysts than the other kidney. Patients with congenital cystic kidney pass abundant urine of low specific gravity (1.010 or less) with a trace of albumin but no casts and cells. Infection of the kidney in the form of pyelonephritis is a common complication. Renal hypertension is seen in more than half number of patients. Symptoms of uraemia e.g. anorexia, headache, drowsiness, vomiting etc. with anaemia may be present.

So polycystic kidney in adult is presented with one or more of the following features —

(i) Abdominal swelling (enlarged kidney); (ii) Pain (due to enlargement of kidney); (iii) Haematuria (present in 25% of cases); (iv) Infection (presents with pyelonephritis); (v) Hypertension; (vi) Chronic renal failure.

Urography is confirmatory. If intravenous urography fails to delineate the pelvicalyceal system properly, retrograde urography should be advised. It must be remembered that one side should be performed and the other side is deferred for a week as oedema may impair the renal function and if performed in both sides in one go there is every possibility of anuria. The calyces are stretched and elongated (spider-leg deformity) by the cysts. Similar deformity may be seen in renal cell carcinoma but in this case the spider legs are smooth and not irregular as seen in this carcinoma. Moreover in this condition the deformity is seen in both sides whereas in renal cell carcinoma the deformity is unilateral. In chromocystography there will be considerable delay in excretion of indigocarmine in the affected side.

Solitary renal cyst.— This condition is rather asymptomatic. Renal swelling with or without dull ache in the loin is the usual presenting symptom. Occasionally haemorrhage inside the cyst may lead to acute renal pain or the cyst may press on the pelviureteric

junction to cause urinary obstruction. Adenocarcinoma may appear in the walls of the cysts, which may be suspected on ultrasound or CT Scanning. These cases should be managed as renal cell carcinomas.

The condition is confirmed by urography. Filling defect of one or more calyces, which are actually stretched over the cyst, is the main abnormality detected. This, of course, is very much similar to what seen in renal neoplasm. Differentiation can be made by ultrasound, cyst puncture under sonographic control, CT and angiography.

Hydatid cyst of the kidney is very occasionally seen. That the patient passes 'grape skin' (ruptured daughter cysts) in the urine is confirmatory.

HYDRONEPHROSIS.— It is the distension of the calyces and pelvis of the kidney caused by an obstruction to the flow of urine.

The *causes* are —

Unilateral Hydronephrosis	Bilateral Hydronephrosis
A. *Pelviureteric obstruction.*—	
(i) Idiopathic pelviureteric junction stenosis (commonest);	(i) Prostatic enlargement — benign or malignant;
(ii) Stone;	(ii) Carcinoma of the bladder;
(iii) Tumour in the renal pelvis;	(iii) Schistosomiasis;
(iv) Pressure from aberrant artery.	(iv) Urethral stricture or valve;
	(v) Phimosis.
B. *Ureteric obstruction.*—	
(i) Stone;	
(ii) Tumour of the ureter;	
(iii) Tumour infiltrating from other organs e.g. bladder, cervix, rectum or colon;	
(iv) Ureterocele;	
(v) Schistosomiasis;	
(vi) Bladder tumour.	

Females are more often affected than men and it occurs practically at all ages. Onset is insidious. Dull ache or a sense of weight may be felt in the loin. Sometimes the patients ignore it as mild backache. If the hydronephrosis develops quickly, the pain may be severe and colicky. It may be exacerbated by drinking excessive amount of water or alcohol or by taking diuretics. Sometimes the pain may be referred to the epigastrium, when it may be mistaken for duodenal ulcer. After a few hours, large quantity of urine may be passed and the swelling considerably reduces in size (Dietl's crisis). In bilateral cases the symptoms are mainly due to the causes.

On examination, a cystic large renal swelling is felt. It is ballottable and better palpable bimanually.

Urography is confirmatory. Conventional earlier films may fail to visualize the pelvis and calyces. Better delineation may be seen after 6 hours of injection. If pelvis and calyces are not seen properly retrograde urography should be called for. The earliest change is seen either in the renal pelvis or minor calyces according as the renal pelvis is extrarenal or intrarenal. In majority of cases the pelvis is extrarenal. Decreasing concavity and later on flattening of the minor calyces are the early changes in case of intrarenal pelvis. Gradually there will be dilatation of the major calyces and convexity (clubbing) of the minor calyces. The pelvis becomes so much distended (in

late stages) that its convex lower margin forms an acute angle with the ureter. Sometimes the cause like stone may be found in X-ray.

Ultrasound scanning is also quite confirmatory, moreover it is the least invasive. It may be used to detect this case due to pelviureteric junction obstruction in utero.

Isotope renography may be used to detect dilatation of the renal collecting system due to obstruction.

Whitaker test is sometimes used in specialised unit to monitor intrapelvic pressure by percutaneous puncture of the kidney.

RENAL CALCULUS.— Majority of the sufferers are between the ages of 30 and 50 years. Both sexes are equally affected, though males slightly dominate. Pain is the main symptom. Majority of the patients suffer from fixed dull ache in the angle between the lower border of the last rib and the lateral border of the sacrospinalis. Pain is also felt anteriorly in the corresponding hypochondriac region. This pain gets worse on movement like running, jolting and climbing up the stairs and gets better with rest. Ureteric colic is sometimes felt particularly when the stone obstructs the pelviureteric junction. Sudden griping pain is felt in the loin and tends to radiate towards the groin. The patient may toss over the bed in agony. Pain may be associated with profuse sweating and vomiting. Pain goes off as suddenly as it came. Haematuria may be complained of either during or after an attack. Pyuria is sometimes noticed but it must be remembered that increase in the number of white cells may be found in urine even in the absence of infection.

On examination, kidney cannot be palpated unless hydronephrosis has developed.



Fig.37.21.— Excretory urogram (IVP) showing normal functioning kidney on right side and *stag horn* calculus with almost nonfunctioning kidney on left side.



Fig.37.22.— Shows a typical stag horn calculus in straight X-ray.

Abdominal rigidity may be felt at the time of colicky pain. Tenderness can be elicited either in the renal angle or during bimanual palpation.

It must be remembered that quite a number of renal stones are asymptomatic. These are mainly phosphate stones. Patients may present with other gastrointestinal symptoms or may present quite late with supervening infection or uraemia or during X-ray examination of the abdomen for some other complaints.

Straight X-ray of the KUB region will reveal 90% of the renal stones except the pure uric acid stones. When a stone is found, exposures are made during full inspiration and full expiration to see whether the stone moves slightly with the kidney during respiration. This is assessed by measuring the distance between the lower border of the kidney and the stone which will remain constant. A lateral film is also essential to exclude other conditions which will show similar type of shadow. A renal stone will be seen to be superimposed on the bodies of the lumbar vertebrae. The other conditions which mimic renal calculus in X-ray are — (i) Gallstone, (ii) calcified lymph nodes, (iii) phleboliths, (iv) drugs or foreign bodies in the alimentary canal, (v) calcified tuberculous lesion of the kidney, (vi) calcified lesion of the suprarenal gland, (vii) fracture of the transverse process of the lumbar vertebra and (viii) calcified adrenal gland.

Excretory urography is essential to know (i) the position of the renal stone, (ii) if it has produced obstructive features or not, (iii) presence of non-opaque stone which can be visualized by filling defect and (iv) the functioning capacity of the affected as well as the sound kidney.

Ultrasound scanning is important to locate stones particularly for extracorporeal shock wave treatment.

ACUTE PYELONEPHRITIS.— Females are more often affected due to their short urethra, which makes easy for the bacteria to enter the bladder. Acute pain is suddenly felt in both the loins. This may be preceded by the prodromal symptoms like headache, lassitude, aches in the joints, rise of temperature, nausea and vomiting. Pain may also be felt anteriorly to be confused with cholecystitis. Temperature rises sharply and may be accompanied by rigor. As cystitis gradually develops patient complains of frequency of micturition and burning pain along the length of the urethra during micturition and even after it. Patient may even complain of 'strangury' i.e. painful and fruitless desire to micturate. Urine may become cloudy and even blood-stained.

On examination, the patient looks ill and anaemic. The tongue is dry and furred. Renal angle will be very tender. There may be rigidity anteriorly due to extreme tenderness.

Bacteriological examination of the urine is highly important. If culture detects the offending organism, sensitivity test must be performed to know which antibiotic will be effective most.

Excretory pyelography in an early case may show poor excretion of the dye and hence poor differentiation can be seen. Radio-isotope renogram will show diminished uptake in certain areas.

PERINEPHRIC ABSCESS.— Diagnosis of this condition depends entirely on clinical examination. In case of pyrexia of unknown origin this condition should be borne in mind. Patient's back is inspected in sitting posture. Slight fullness may be detected just below the last rib and lateral to sacrospinalis muscle on comparing with the opposite side. There may be scoliosis of the lumbar spine with concavity towards the affected

side, which is a relatively early sign. The abscess is often related to the upper pole where no swelling can be detected. But less frequently such abscess may be related to the lower pole of the kidney when a swelling in the renal area can be seen. The patient is now instructed to lie prone on the examining table. While doing 'renal angle test' muscular rigidity is felt on the affected side.

In straight X-ray psoas shadow is obscured, there may be reactionary scoliosis with concavity towards the abscess. The diaphragm is raised and immobile on the affected side. Definite diagnosis is made by CT and ultrasonography.

RENAL TUBERCULOSIS.— Men are more often affected than females and the majority of the victims are between 20 and 40 years of age, though no age is exempted. The earliest and the commonest symptom is frequency of micturition both by day and night. Renal pain is absent (dull ache in the loin may be complained of) in majority of cases but if the bladder is involved patient will complain of suprapubic pain when the bladder is full and if the bladder is secondarily involved pain is felt at the tip of penis after micturition. If a tuberculous ulcer has affected a renal papilla painless haematuria will be the presenting symptom. Generalized symptoms like loss of weight, evening rise of temperature, cough, haemoptysis may or may not be associated with.

On examination, a tuberculous kidney is unlikely to be palpable. The palpable kidney is usually the sound and compensatory hypertrophied kidney (it may be tender). If this condition is suspected it is always worthwhile to examine the prostate, seminal vesicles and the epididymis.

Bacteriological examination is very important pathological test. The sediment of the morning urine should be stained and cultured for acid-fast bacilli. It must be remembered that presence of pus cells in acid urine without any organism in ordinary culture is probably a case of urinary tuberculosis and special culture and animal inoculation test should be called for. *Cystoscopy* will show pallor around the ureteric orifice in early case. Gradually the tubercles appear which coalesce to form a tuberculous ulcer. In late cases due to sclerosing periureteritis the ureter becomes shortened, so the ureteric orifice is pulled up giving rise to a 'golf-hole' ureteric orifice. The capacity of the bladder is gradually diminished and when secondarily infected the whole mucous membrane looks red and oedematous. *Straight X-ray* may reveal calcification in healing foci or calcification around a caseous mass. In *urography* one may find irregular density in nephrogram. Irregular dilatation of the calyces or loss of one calyx due to oedema and spasm of the calyceal neck may be the only finding. Cavity formation is also seen in ulcero-cavernous type. In late cases periureteric fibrosis makes the ureter wider and more straight losing its natural curves. Chest X-ray must be performed to exclude any active lung lesion.

TUMOURS OF THE KIDNEY.— Benign neoplasms are so rare in kidney that it is good to consider all neoplasms of the kidney as malignant. Three types are commonly seen — A. Renal cell carcinoma or Carcinoma of kidney, B. Nephroblastoma and C. Papillary tumours of the renal pelvis.

A. **Renal Cell Carcinoma** (syn. GRAWITZ TUMOUR or HYPERNEPHROMA).— This tumour arises in the cortex from the cells of the uriniferous tubules. It is uncommon to see this tumour below the age of 50 years and it is twice as common in males than females. It can present in many ways but mainly three types of presentations are seen :— (a) *Painless intermittent haematuria;* (b) *A dragging pain* in the loin due to the presence of the kidney with the tumour and (c) *A palpable mass* due to enlarged

kidney discovered by the patient accidentally. These main presentations are always accompanied by general malaise, loss of weight, loss of energy, lassitude, anaemia etc. *Pain* in the kidney may be more disturbing when the tumour breaks through its capsule and invades neighbouring structures. *Pyrexia of unknown origin* without any infection, tuberculosis, lymphoma etc. may be the presenting symptom in odd cases. In about 1/4th of the cases the primary tumour remains silent and *secondary metastasis becomes the presenting features*, e.g. bone pain, fracture, persistent cough, haemoptysis etc. (as blood borne metastasis is early in this tumour). *Polycythaemia* with increased E.S.R. due to increased production of erythropoietin is the presenting feature in a few number of cases. This is evident by redness of the face and hands, heart failure and spontaneous venous and arterial thromboses. Occlusion of the left renal and testicular veins may lead to *varicocele* of recent onset and *oedema of both legs* due to occlusion of the inferior vena cava. *Hypertension* due to increased production of renin is sometimes the presenting feature.

On examination, an enlarged kidney may be palpable. If there is no palpable mass, cystoscopy should be done during haematuria to know from which kidney the blood is coming. Recent weight loss and anaemia from haematuria are important general features. Large tumours are palpable and have all signs of an enlarged kidney described in page 562. A small tumour in the upper pole of the kidney may push the whole kidney downwards and make the lower pole easier to feel. Tenderness is conspiquous by its absence. Renal carcinoma often spreads along renal vein. The commonest site for metastasis is the lung. The tumour cells reach the pulmonary vascular capillaries via the heart. The patient typically develops a number of isolated lesions within the lung field, known as cannon-ball metastases. Renal cell carcinoma is one of the tumours that commonly metasises to bones. Areas of swelling and tenderness in the bones must be looked for carefully. Such metastases are often pulsatile with audible bruit.

Very rarely ectopic hormones may be produced which include parathyroid hormone or a parathyroid hormone-like substance which gives rise to hypercalcaemia. There may be production of adrenocorticotropic hormone or human chorionotropic hormone.

Clinical staging may be used for carcinoma of the kidney as devised by Robin —

Stage I — tumour within the capsule;

Stage II — tumour invades the perinephric fat but within Gerota's fascia;

Stage III — tumour involvement of regional lymph nodes and/or renal vein;

Stage IV — tumour involvement of adjacent organs or distant metastasis.

Urography is extremely important. Renogram is important and may show the soft tissue shadow of the tumour. Otherwise excretory urography may be inconclusive due to lack of concentration of the contrast medium, yet it is important to know the function of the contralateral kidney. *Retrograde urography* may be necessary to know the exact changes of the calyceal system. Filling defect due to invasion of one or more minor and/or major calyces, elongation and stretching of the calyces over the tumour mass may show the 'spider-leg' deformity. The outline of this spider-leg will be irregular in contradistinction to the same type of defect found in polycystic kidney where the outline will be smooth, the legs will be broadened and majority of the calyces will be affected besides the obvious fact that the defect is seen in both the kidneys. Filling defect may also be seen in the renal pelvis with various types of distortion. Ultrasound, CT, arteriography, Renal and bone scan, chest X-ray and tomography are the other investigations to be carried out to know more about the

primary and secondaries of this fast growing tumours.

B. **Nephroblastoma** (Syn. WILMS' TUMOUR).— It is a mixed tumour containing embryonic epithelial and connective tissue elements of the kidney. This is a tumour of children and majority of the victims are between 1–5 years of age. The main presenting feature is painless, rapidly growing tumour without haematuria. The tumour grows within its capsule pushing the rest of the kidney to one side. When the tumour bursts through the capsule into the pelvis haematuria results. So this is an ominous sign and indicates very bad prognosis. 50% of the patients suffer from rise in temperature which adds confusion to the diagnosis. On the right side this condition is confused with liver enlargement and on the left side with the splenic enlargement. Blood-borne metastasis is early and liver is mainly affected. Very rarely bones or brain may be involved.



Fig.37.23.— Nephroblastoma (Wilms' tumour) of the left kidney.

Urography will show the soft tissue shadow of the tumour in nephrogram. Distortion and filling defects of the calyces are the main diagnostic points in urography.

C. **Papillary tumour** of the renal pelvis is discussed under the heading of 'Diseases of the ureter'.

DISEASES OF THE URETER

URETERIC CALCULUS.— A stone in the ureter always originates from the kidney. Ureteric colic is the main symptom of this condition. Haematuria may be complained of. Ureteric colic starts as soon as the stone enters the pelvi-ureteric junction and recurs at longer or shorter intervals so long as the stone remains in the ureter. Ureteric colic ceases when the stone is ejected into the bladder or the stone is impacted in the ureter. When the stone is in the upper 1/3rd of the ureter, pain starts in the loin or near the renal angle and gradually radiates to the groin. Pain is griping in nature and starts suddenly. The patient almost tosses over the bed in agony often associated with profuse sweating and nausea. Pain suddenly goes off almost as suddenly as it appeared. At a lower level, pain commences rather anteriorly just above the iliac crest and is referred along the two branches of the genito femoral nerve to the testis in the male and labium majus in the female and to the antero-medial aspect of the thigh in both sexes. The testis becomes retracted by the spasm of the cremaster. When the stone enters the intramural part of the ureter, pain is referred to the tip of the penis and the patient complains of strangury. When the stone becomes impacted, colic goes off, instead a dull ache arises according to the site of impaction. Such pain varies in intensity, increased by exercise and relieved by rest. On the right side this condition may be confused with appendicitis.

On examination, tenderness and rigidity may be felt along the course of the ureter.

A stone in the lower part of the ureter may be felt in rectal or vaginal examination.

Straight X-ray often reveals stone along the course of the ureter. *Urography* will reveal a non-opaque stone by filling defect. No excretion or delayed excretion is sometimes seen after an attack of ureteric colic. *Cystoscopy* will reveal a stone at the ureteric orifice. It will show delayed or no excretion after intravenous injection of indigocarmine.

PAPILLARY TUMOURS OF THE RENAL PELVIS.— Transitional cell tumours can affect any part of the transitional cell epithelium, which lines the whole of the urinary tract. The frequency with which this tumour develops depends upon the length of time the urine, which contains the carcinogen, remains in contact with the epithelial surface. So this tumour is mostly seen in the bladder (about 90%), then the renal pelvis (about 5%) and lastly in the ureter (about 1%). Painless haematuria is the main presenting symptom. There may be symptoms of ureteric obstruction when it occurs in the ureter. This tumour tends to be malignant. These tumours also spread by seeding into the ureter lower down and even bladder.

Urography is quite diagnostic which shows filling defect according to the position of the papillary tumour whether in the renal pelvis or ureter. Other radiological image and a combination of urinary cytology will confirm the diagnosis.

DISEASES OF THE BLADDER

ECTOPIA VESICAE or **Exstrophy of the bladder.**— This is a congenital anomaly in which there is defect in the formation or agenesis of the anterior wall of the allantois and lower abdominal wall. This is represented by a thin membrane, which after birth is separated with the umbilical cord. Thus the posterior wall of the bladder is exposed.



Fig.37.24.— Ectopia vesicae. Note the absence of umbilicus.



Fig.37.25.— The skiagram of a case of ectopia vesicae. It shows absence of the symphysis pubis resulting in a big gap between the two pubic bones.

There is no umbilicus. Due to pressure of the viscera behind it, the deep red posterior surface extrudes. This surface may bleed. Urine constantly dribbles through the ureteric orifices. Penis is ill-developed and its dorsal surface is split open (epispadias) which

is continuous above with the exstrophy of the bladder. There may be inguinal and umbilical herniae. There is always separation of the pubic bones without any symphysis pubis, instead a strong ligament holds the bones.

RUPTURE OF THE BLADDER.— See page 449.

VESICAL CALCULUS.— Stones may come to the bladder through the ureter and enlarge here. Otherwise stones may form in the bladder secondary to stasis and infection.

No age is exempt from this disease. Males are much more often affected than females. *Increased frequency of micturition* is the commonest symptom. This is not experienced at night. The cause is that in standing posture the stone comes in contact with the trigone and initiates desire to micturate. During night the stone falls off the trigone and frequent desire to micturate goes off. Presence of stone in the bladder will give rise to *pain* in the suprapubic region *particularly after micturition*. This pain is often referred to the tip of the penis or to the labia majora and becomes aggravated by running and jolting. Children may scream and pull the prepuce for pain after micturition. *Haematuria* at the end of micturition is also common symptom. This is caused by abrasion of the vascular trigone and gets worse on exercise. *Sudden interruption of the flow* due to blockage of the urethral meatus with the stone and subsequent continuation by change of posture is also not uncommon. *Symptoms of cystitis* e.g. frequency of micturition, burning sensation, postpubic pain etc. may overshadow those due to presence of stone.

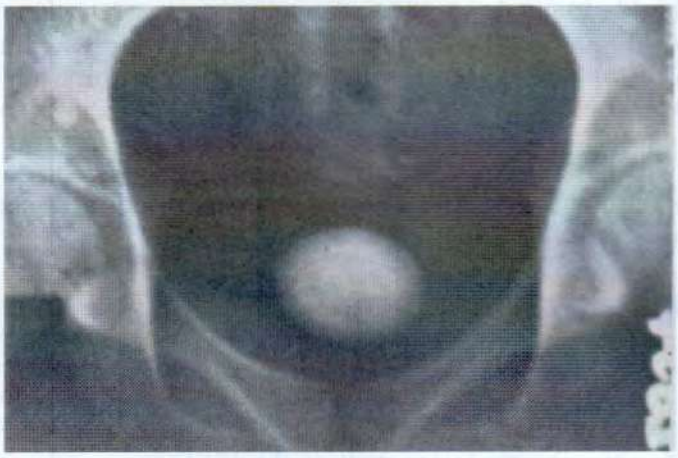

Fig.37.26.— Straight X-ray showing vesical calculus.

Sometimes stone may be situated in the post-prostatic pouch or diverticulum without any typical symptom of stone and is only revealed in X-ray or cystoscopy for other complaints. These are known as 'latent stones'.

On examination, one may elicit suprapubic tenderness. A large stone can be felt per rectum (in male) or per vagina (in female). But bimanual palpation (one on the abdomen and the other in the rectum or vagina) may facilitate palpation.

Urine should be examined microscopically and bacteriologically. Straight X-ray will reveal about 95% of the vesical calculus. The whole KUB region should be exposed to exclude further stones in the ureter or kidney. Urography will show non-opaque stones by filling defect and demonstrate the functioning condition of the kidney. Cystoscopy and bladder sound will detect presence of stone as well.

DIVERTICULUM OF THE BLADDER.— The usual victim is male over 50 years of age. There is no typical symptom of this condition. This condition usually develops from obstruction distal to the urinary bladder e.g. bladder neck obstruction, senile

enlargement of prostate, fibrous prostate, urethral stricture, posterior urethral valves etc. So long it remains uninfected it *remains dormant*. When it becomes infected *symptoms of cystitis* become evident. *Haematuria* may be complained of in a number of cases. *Double micturition* in rapid succession is very suggestive of this condition — first one is clear urine from the bladder and the second is the cloudy urine from the diverticulum.

Urography is confirmatory. Excretory urography will not only reveal this condition, but will also show its impact on the upper urinary tract. If excretory cystography fails to delineate the diverticulum, retrograde cystography will be necessary. Cystoscopy will actually show the diverticulum. For proper inspection the bladder should be fully distended.

CYSTITIS.— Though this condition occurs at all times of life, yet young and middle aged subjects are the usual victims and women are more prone to suffer from this disease. Stasis, presence of foreign body (e.g. stone, catheter, neoplasm etc.), avitaminosis and short urethra of females are the predisposing factors.

The commonest symptom is *increased frequency of micturition* both during day and night. Desire to micturate occurs from every hour to every fifteen minutes. *Urgency* is usually associated with and if the bladder cannot be emptied forthwith incontinence results. *Pain* varies from mild discomfort to agonising. When inflammation affects the dome of the bladder pain is complained of in the suprapubic region. When it affects the trigone pain is felt at the tip of penis or labia majora or even the perineum. Burning or scalding pain along the length of the urethra during micturition is a very typical symptom of this condition. *Haematuria* is quite common and in fact cystitis is the commonest cause of haematuria. It is usually a few drops *at the end of micturition*, less often the whole specimen is blood-stained. *Cloudy urine* is also complained of in late cases.

On examination, one hardly finds a typical sign except suprapubic, per rectum or per vaginum tenderness of the urinary bladder. Urine should be examined for routine examinations and for culture and sensitivity tests. Cystoscopy confirms the diagnosis. This reveals hyperaemia, mucosal haemorrhages, blistering, sloughing and ulceration of the mucosa.

TUBERCULOUS CYSTITIS.— When tuberculosis affects the bladder there is invariably infection in the upper tract. The main complaint of the patient is increased frequency. There is often bladder pain and sometimes haematuria. Gradually the capacity of the bladder is decreased and frequency increases. General malaise, night fever and weight loss are the general features. It must be remembered that even when treated, subsequent scarring leads to a non-compliant bladder. The lower ends of the ureters may be involved to this process of fibrosis leading to obstruction. When the ureter is affected, sclerosing periureteritis may lead to shortening of the ureter, so that the ureteric orifice is pulled up giving rise to a 'golf-hole' ureteric orific.

Cystoscopy reveals tuberculous ulceration. Early treatment may prevent cicatrization and bladder capacity may be maintained normal. So early treatment is of great importance.

INTERSTITIAL CYSTITIS.— This condition is a chronic idiopathic cystitis involving the whole of the bladder. It usually occurs in women between 30 and 40 years of age. Mucosal ulceration with contact bleeding and marked muscular fibrosis are the main pathology which leads to a contracted bladder, the functional capacity of which is thus

reduced. Intense frequency of micturition with haematuria and painful bladder are the presenting features.

TUMOURS OF THE BLADDER.— It can be broadly classified into two varieties clinically — (1) Papilloma and (2) Carcinoma.

Tumours of the bladder are commonly seen in males from middle age onwards. Certain chemicals when excreted in the urine may stimulate malignant change in the bladder. These are alpha- and beta-naphthylamine, benzidine, xylenamine etc. The industries which use these chemicals are the rubber and cable industries, printers and dyers. Bilharziasis and the conditions which cause chronic irritation of the bladder mucosa may initiate tumour formation.

PAPILLOMA.— Painless, profuse and paroxysmal haematuria is the main and only symptom for a long time. Haematuria may last for a few hours and days and then ceases to recur again after an interval of weeks or months. Sometimes clot retention or obstruction of the internal meatus may cause retention. Fragments of growth may be passed with urine which can be detected microscopically. Diagnosis is established by cystoscopy. A papilloma is pedunculated with villi which float in the fluid of the bladder. Malignant transformation is suspected when (i) the growth is sessile, (ii) the surrounding mucous membrane becomes oedematous and more vascular, (iii) the villi are stunted and swollen like cauliflower, (iv) the surface of the growth ulcerates with areas of necrosis, (v) the tumour is accompanied by cystitis or (vi) submucosal lymphatic nodules appear around the growth.

CARCINOMA.— Initial symptom is again profuse and intermittent haematuria. Later on symptoms of cystitis may appear, even strangury may be complained of. Loin pain may be a symptom from obstructed ureter. When the growth has invaded the tissues around the bladder, pain in the suprapubic region, buttock, perineum and even down the thigh may be complained of due to nerve involvement.

Cytology of urine may give a clue to the diagnosis. *Excretory urography* may show soft tissue shadow in case of large malignant growth. Obstruction of ureter may be evidenced in urography. Function of kidneys are generally not jeopardised. Mainly the filling defect of the growth is the diagnostic point in this investigation. *Cystoscopy* is the mainstay of diagnosis. A tumour which is sessile, lobulated, deep red and bleeds to touch is a carcinoma. The surface may become ulcerated in places. A carcinomatous ulcer may be seen. This is seen in the base of the bladder or on the trigone. Ulcer has everted margin and fixed indurated base. This is a fast growing carcinoma. *Bimanual palpation (recto-abdominally in the male and vagino-abdominally in the female) under general anaesthesia* is very important to determine the stage of the cancer.

Unless a bladder tumour is large, it is not usually palpable. The majority of the bladder tumours (80%) are superficial i.e. not involving the muscle of the bladder wall, at the time of first diagnosis. These are not detectable on clinical examination. The remaining 20% have already invaded the muscle of the bladder wall and farther; which can be palpable bimanually under general anaesthesia. The size, position and mobility of the tumour must be assessed. The clinical staging of the disease should be performed in determining subsequent treatment. Staging is best achieved by a combination of bimanual examination under anaesthesia followed by cystoscopic excision biopsy of the tumour.

DISEASES OF THE PROSTATE

BENIGN HYPERTROPHY OF THE PROSTATE.— This is a disease of old age and almost never seen below fifty years of age. Hyperplasia and hypertrophy affect the inner glandular and fibrous tissue which compress the outer portion known as 'surgical capsule'. It is also called adenomatous enlargement of the prostate. The aetiology is not known, but the popular theory is that it is an involutional hypertrophy in response to a changing hormonal environment.

Though prostate starts enlarging at the age of 40 years, but patients usually present between 50 and 70 years.

Increased frequency of micturition particularly at night is the earliest symptom. Patient gets up in the middle of night twice or thrice to pass urine. This is due to inadequate emptying of the bladder and due to presence of sensitive prostatic mucous membrane of the intravesical enlargement of the prostate. Frequency gradually progresses and then presents both by day and night. Another symptom is *urgency* due to the fact that urine escapes through the stretched vesical sphincter into sensitive prostatic mucosa which causes reflex for intense desire to void. Gradually residual urine increases and frequency becomes more and more evident with advent of cystitis and polyuria due to renal insufficiency. *Difficulty in micturition* is quite common. The patient has to *wait* before the stream starts. The stream is weak and dribbles down instead of being projected. Straining hinders flow rather than increasing the flow. *Haematuria* is quite common. It is terminal in prostatic congestion but profuse due to rupture of 'vesical piles'. Some patients present with *retention of urine* — either acute or chronic. Others may present with *over-flow incontinence*. It may so happen that the patient may present with the *symptoms of uraemia* — headache, drowsiness, vomiting and even haematemesis.

On examination, it is noted whether the patient is drowsy or not. The tongue should be noted — whether coated or not. The kidneys should be palpated. Tenderness there indicates pyelonephritis and enlargement may indicate hydronephrosis. Examine the penis, testis and epididymis.

Diagnosis is mainly made by *rectal examination*. The examination should be performed with the patient in the left lateral position or some prefer the knee-elbow position. The urinary bladder must be emptied before the examination. The index finger is usually used and should face the anterior surface of the rectum, so that the lobes of the prostate can be felt through the rectal wall. The prostate gland is enlarged. The finger may not even reach the upper limit of the prostate. The prostate may not be felt enlarged if only the median lobe is enlarged. It is not tender. The gland is firm, rubbery and lobulated. The two lateral lobes of the gland can be felt to bulge into the rectum divided by the central sulcus which is well defined. There may be some asymmetry of the enlargement, though both the lobes retain their smooth texture. Total prostatic volume is assessed by passing the examining finger from base to apex and also from side-to-side. It must be remembered that the size of the gland may not always correlate with the degree of obstruction by the gland or the symptoms of the patient. Consistency is homogeneous. The surface is smooth and bosselated. Persistence of median sulcus is a definite sign of this condition which is often obliterated in carcinoma. The rectal mucosa moves freely over the gland. It is advisable to empty the bladder first in retention for better palpation.

Clinically, the prostate is divided into 3 lobes, 2 lateral and 1 median. Histological process of benign prostatic hyperplasia usually affects all the lobes equally. Sometimes the median lobe may grow more than the lateral lobes. This lobe cannot be felt per rectum and the prostate may appear normal. However cystoscopically enlargement of this lobe can be detected. Enlargement of median lobe gives rise to mainly irritative symptoms e.g. nocturia, frequency and urgency. Enlargement of lateral lobes mainly gives rise to obstructive symptoms e.g. slow stream, terminal dribbling and hesitancy.

Blood is examined routinely for Hb%, T.C., D.C. E.S.R., urea and sugar. *Urine* should be sent for routine examination, culture and sensitivity. Urography will indicate functional status of the kidneys and presence or absence of hydronephrosis. Cystography after voiding will indicate the amount of residual urine. Cystography may show filling defect due to projection of median lobe inside the bladder. *Cystoscopy* is essential to exclude presence of diverticulum, stone and growth. This is more important when the operation of prostatectomy is not performed transvesically.

3 recent advances have made diagnosis of this disease easier. These are estimation of prostate-specific antigen (PSA), transrectal ultrasound scanning and transrectal biopsy with ultrasound control. These are more elaborately discussed in the section of carcinoma of the prostate (see below).

ACUTE PROSTATITIS.— Blood-borne infection seems to be the cause of this condition. High rise of temperature, rigor, pain all over the body particularly in the back are the prodromal symptoms which may mislead the clinician. Specific symptoms are perineal heaviness, pain during micturition and defaecation. Increased frequency of micturition is only complained of when cystitis has supervened.

On examination, no abnormality can be detected except tenderness of the prostate on rectal examination. Initial specimen of urine which contains threads should be sent for culture and sensitivity.

CHRONIC PROSTATITIS.— This generally occurs due to inadequate treatment of acute prostatitis. Aches all over with mild pyrexia and malaise are the usual symptoms. Premature ejaculation and impotence may be associated with. Dull ache in the perineum, low backache radiating downwards to the thigh and *gleety urine* are the only specific symptoms.

Diagnosis is based on rectal examination which may reveal a slightly tender prostate relatively firmer and irregular or softer than normal, examination of the fluid received by prostatic massage (which will contain pus cells and bacteria), microscopical examination, culture and sensitivity of the initial specimen of urine which contains the gleet and urethroscopy which reveals dilated prostatic ducts which may extrude pus.

CARCINOMA OF PROSTATE.— This is the commonest malignant condition in men over 60 years of age. Carcinoma of the prostate begins in the outer part of the gland, so it spreads easily into the floor of the pelvis. It often reaches an advanced stage before it causes symptoms. Symptoms are similar to those of benign hypertrophy of prostate — *frequency, urgency* and *difficulty of micturition* (collectively known as 'prostatism'). But the main difference is that the history is quite short and they get worse rapidly. About half the patients present with some form of *retention of urine* — acute or chronic. General debility, malaise, anaemia and loss of weight are common. Sometimes urinary symptoms are absent or slight. *Pain in the back, sciatica* (from metastasis in the spine) and *pathological fractures* may be the symptoms first to appear.

On examination, the bladder may be felt suprapubically when there is retention. *Rectal examination* will reveal relatively hard nodular prostate, irregular and heterogenous in consistency. The median sulcus will be obliterated (very important sign) and the rectal mucosa is tethered to the gland (rectal mucosa cannot be moved over the prostate). The tissues lateral to the gland may be infiltrated giving rise to 'winging' of the prostate. Occasionally carcinoma may arise from an already adenomatous enlarged gland, so even in case of benign enlargement one should look for discrete induration. For clinical staging of the disease the students are referred to author's 'A CONCISE TEXTBOOK OF SURGERY', page 1323.



Fig.37.27.— Bone scan showing metastatic deposits in the iliac bones and lumbar vertebrae in a case of carcinoma of prostate.

Digital rectal examination is an important screening examination for prostatic malignancy. Used in combination with measurement of serum level of the prostate-specific antigen and transrectal ultrasound and biopsy have led to a dramatic increase in the number of men diagnosed with prostatic carcinoma.

Special investigations are serum acid phosphatase (only raised when there is bony metastasis) and alkaline phosphatase, biopsy of the prostate, radiological examination (which shows osteoblastic lesion), bone scanning, lymphangiography etc. Biopsy can be performed with a needle through the perineum, transurethral resection (which has the advantage of removing obstruction and providing large piece of tissue for examination and is mainly done during retention), but open perineal biopsy is still favoured by a few urologists.

3 recent advances are now used in specialized centres for precise diagnosis of this condition and also used as screening procedures to detect more patients with carcinoma of prostate. These are —

(i) *Estimation of prostate-specific antigen (PSA).*— PSA is a glycoprotein, whose function is to facilitate liquifaction of semen. It is now being used as a marker for prostatic disease. It is measured by immunoassay technique and the normal upper limit is about 4nmol/ml. It is more important in the diagnosis of carcinoma of prostate, in which case the level goes upto 15nmol/ml in localized cancer to 30nmol/ml in case of metastatic cancer. However in benign hyperplasia of prostate the level goes upto 4-10nmol/ml.

(ii) *Transrectal ultrasound scanning.*— This imaging technique offers accurate estimation of prostatic size. It is probably more effective in detection of associated early prostatic cancer. If such suspicion is not there, it is not required to use routinely. It is used when the level of PSA is high or the surface of prostate is hard and irregular. Though

this investigation can be used in early detection of the tumour, however many such tumours are also missed with this technique. In fact only about 50% of cancers can be diagnosed with this technique.

(iii) Presently *transrectal biopsy* using an automated gun with appropriate antibiotic cover is used. Several cores are taken to make definite diagnosis.

URETHRAL STRICTURE.— This is due to formation of fibrous tissue following damage to the urethral mucosa. The commonest cause is gonococcal urethritis transmitted through sexual intercourse and obviously the sufferers are young adults.

Patient often gives a past history of exuding pus per urethra and later on glairy urethral discharge, particularly noticeable in the morning.

The commonest symptom is *difficulty in micturition (dysuria)*. But the difference from benign hypertrophy of prostate is that the *flow increases on straining*. Normally the stream is thin and dribbles at the end. Gradually cystitis develops which increases frequency of micturition and causes urgency. *Acute retention* is quite common.

On examination, nothing abnormality could be detected except that the bladder may be palpable when it is distended. Examine the kidney region for back pressure and infection. Diagnosis is confirmed by passing bougie which will be obstructed at the bulb of the urethra (commonest site of stricture in gonococcal urethritis). Urethrography will demonstrate the site and length of the stricture. The *chief complications* are retention of urine and periurethral abscess which may burst to cause urethral fistula or extravasation of urine, according as it opens to the exterior or subcutaneous tissue respectively.

Other causes of urethral stricture are : (i) Bad instrumentation (catheterisation or bougienage); (ii) Following prostatectomy; (iii) Amputation of penis; (iv) Direct injury (following treatment of rupture of urethra); (v) Meatal ulcer; (vi) Urethral neoplasm.

RETENTION OF URINE

Retention of urine means accumulation of urine in the urinary bladder. Patient is unable to pass urine or passes small quantity of urine. It must be remembered that kidneys excrete urine normally. In anuria also patient does not pass urine but in this condition the kidneys fail to excrete urine and there is no urine in the bladder, hence collapsed. There are two forms of retention of urine — acute retention and chronic retention.

Acute retention is sudden inability to pass urine and it is a painful condition. *Chronic retention* is gradual accumulation of urine in the bladder due to inability of the patient to empty the bladder completely. The result is an enlarged painless bladder. If infection supervenes on chronic retention it becomes painful and it is often described as acute-on-chronic retention. It may be called 'infection-on-chronic retention'.

Acute retention.— It must be remembered that acute retention in a normal bladder is extremely rare and occurs only after anaesthesia, an injury to the urethra or after a surgical operation. In majority of cases there has been a chronic retention before the acute attack. These cases may be called acute-on-chronic retention. The patient is likely to have some symptoms related to chronic retention previous to the acute episode. Sudden inability to pass urine with severe pain and with an exaggerated desire to micturate is the main presenting feature of this condition.

On examination, the urinary bladder is sufficiently enlarged to become palpable, tense and dull arising out of the pelvis. Pressure on this swelling increases the patient's desire to micturate.

Rectal examination will reveal that the prostate or uterus is pushed backwards and downwards by the bladder which can be easily felt as a cystic mass. It must be remembered that one cannot assess the size of the prostate gland when the bladder is full. One must try to feel the other organs of the pelvis as well. Sensory, motor and reflex functions of the nerves of the perineum and lower limbs should be assessed carefully.

Chronic retention.— Elderly individuals are mainly affected by this disease. Chronic retention is a painless condition and the patient is often unaware of his/her destended bladder. The symptoms may be in the form of increased frequency of micturition, difficulty of micturition or even overflow incontinence.

On examination the foreskin and urethral meatus should be examined for phimosis or meatal stenosis. The length of the urethra as far as the bulb should be palpated for a stricture, periurethral abscess or presence of a stone or a foreign body. Urethral discharge, if present, should be noted. The prostate must be examined, as this is the commonest cause of retention of urine in the male. But the bladder should be deflated before proper assessment of the prostate. The bladder is always palpable. It may reach the umbilicus or somewhere in between the pubic symphysis and umbilicus. It is neither tense nor tender. Pressure on the bladder does not initiate the desire to micturate (cf. acute retention). The bladder is obviously dull to percussion and may elicit fluid thrill if the patient is thin. Examination of the nervous system is of immense importance. Bladder sensation/micturition reflex arc may be inhibited by a disease of CNS which is localized at the level of the midsacral neural outflow. Absent ankle jerk and diminished or absent cutaneous sensation in the perineum and perianal regions are usually associated with such lesion.

In infants and children the urinary bladder is more of an abdominal organ and can be palpated without retention of urine. If there is difficulty or inability to pass urine the cause is most likely to be neurological in origin or due to obstruction from the presence of posterior urethral valves.

The **causes** of retention of urine are classified as follows —

Causes :—

A. **Mechanical :**

(a) *Urinary bladder.*— Stone, tumour, blood clot and contracture of the bladder neck.

(b) *Prostate.*— Prostatic abscess, benign and malignant enlargements.

(c) *Urethra.*— Urethral stricture, rupture, congenital valves, foreign body, acute urethritis, stone, growth, pin-hole meatus, meatal ulcer.

(d) *Prepuce.*— Phimosis.

From outside —

Pregnancy (retroverted gravid uterus), fibroid, ovarian cyst, carcinoma of the cervix uteri and rectum and any pelvic growth and paraphimosis.

B. **Neurogenic :**

(a) *Spinal cord diseases* e.g. disseminated sclerosis, tabes dorsalis, transverse myelitis etc.

(b) *Injuries and diseases of the spine* e.g. fracture-dislocation, Pott's disease etc.

(c) *Miscellaneous* e.g. postoperative retention, hysteria, tetanus, drugs such as anticholinergics, smooth muscle relaxants, tranquillizers etc.

HAEMATURIA

Causes.— These can be conveniently described under four headings — A. Lesions of the urinary tract; B. Diseases of the adjacent viscera involving the urinary tract; C. General disorders; D. After ingestion of certain drugs.

A. **Lesion of the urinary tract :—**

I. KIDNEY.—

Congenital — Polycystic kidney.

Traumatic — Ruptured kidney.

Inflammatory — Tuberculosis, acute nephritis (rare).

Neoplastic — Angioma, carcinoma of the kidney, nephroblastoma of the kidney, papilloma or carcinoma of the renal pelvis.

Others — Stone, infarction, essential haematuria.

II. URETER.— Stone, papilloma or carcinoma of urothelium.

III. BLADDER.—

Traumatic — Rupture.

Inflammatory — Cystitis, Tuberculosis, Bilharziasis.

Neoplastic — Papilloma and carcinoma.

Others — Stone.

IV. PROSTATE.— Benign and malignant enlargement. Sometimes prostatitis.

V. URETHRA.—

Traumatic — Rupture.

Inflammatory — Acute urethritis.

Neoplastic — Transitional cell carcinoma.

Others — Stone.

B. **Diseases of the adjacent viscera :—**

Acute appendicitis, salpingitis and *pelvic abscess.* The inflammatory process may spread to the ureter and bladder. *Carcinoma of the rectum* and *cervix uteri* may infiltrate the bladder to cause haematuria.

C. **General disorders :—**

I. BLOOD DISORDERS.— Purpura, sickle cell anaemia, haemophilia, scurvy, malaria.

II. INFARCTION.— Arterial emboli from myocardial infarct and subacute bacterial endocarditis.

III. CONGESTION.— Right heart failure and Renal vein thrombosis.

IV. COLLAGEN DISEASES.

D. **Drugs :**— Anticoagulant drugs, hexamine, sulphonamides and salicylates — when given in large doses.

INCREASED FREQUENCY OF MICTURITION

In a normal person the act of micturition occurs 5 or 6 times during 24 hours. There will be increased frequency if the fluid intake is more than usual (physiological) or if the amount of urine formation is increased as in diabetes and chronic interstitial

nephritis. If the total amount of urine remains normal, **causes** of increased frequency are :

1. *Renal* — any form of pyelitis, stone, tuberculosis and movable kidney.
2. *Ureteric* — stone (the lower the position of the stone the more is the frequency).
3. *Vesical* — any form of cystitis and stone; inflammatory condition of the pelvis, e.g. salpingitis, appendicitis; secondary infiltration from carcinoma of the uterus or rectum; mechanical obstruction to normal distension by a tumour, e.g. ovarian cyst, fibroid or retroverted uterus.
4. *Prostatic* — prostatitis, senile enlargement and malignant prostate.
5. *Urethral* — posterior urethritis (Gonococcal), stone, pin-hole meatus, phimosis and balanitis.

Investigation.— History is taken as discussed above. Enquire whether frequency is more marked during the day or night, or there is no such distinction. Diurnal frequency is peculiar to vesical calculus and is due to irritation of the trigone in the erect position; nocturnal frequency, when complained of by an elderly man, is due to senile enlargement of the prostate; whereas in cystitis, frequency is equally marked by day and night. It must be remembered that frequency *in a young adult with sterile acid urine containing pus should be regarded as being due to renal tuberculosis* until this can be excluded. The other common cause in a young adult is gonococcal posterior urethritis in which the history is often helpful. In the middle-aged person one should think of diabetes in which the triad is polyuria (excessive discharge of urine), polydipsia (extreme thirst) and polyphagia (excessive eating). In the old, senile enlargement of the prostate is the commonest cause.

Physical examination and *special investigations* are carried out as discussed above in order to arrive at a definite diagnosis.

Chapter

38 EXAMINATION OF A CASE OF HERNIA

A ***hernia*** is defined as protrusion of whole or a part of a viscus through the wall that contains it. The term can be applied to protrusion of a muscle through its fascial covering or of brain through fracture of skull or through foramen magnum into the spinal canal. But by far the commonest variety of hernia is protrusion of a viscus or a part of it through the abdominal wall and will be discussed here.

Of the abdominal herniae the common varieties are inguinal, femoral, umbilical, incisional and epigastric, while the rare varieties are obturator, lumbar, gluteal and Spigelian.

Inguinal hernia comes out through the superficial inguinal ring. Indirect or oblique inguinal hernia comes out of the abdominal cavity through the deep inguinal ring, traverses all along the inguinal canal and ultimately becomes superficial through the superficial inguinal ring. Direct inguinal hernia enters the inguinal canal through the medial half of its weak posterior wall (through the Hesselbach's triangle) and becomes superficial through the same superficial inguinal ring. Inguinal hernia is said to be complete when the contents have reached the bottom of the scrotum. Otherwise the hernia is incomplete.

Femoral hernia comes out through the femoral canal and becomes superficial through the saphenous opening.

HISTORY.— (i) ***Age.***— Indirect inguinal hernia is usually met with in young individuals, whereas a direct hernia is mostly seen in older subjects.

(ii) ***Occupation.***— Strenuous work is responsible for development of hernia. Of course, there should be associated underlying weakness of the abdominal muscles or persistence of processus vaginalis.

COMPLAINTS.— 1. **Pain.**— In the beginning when there is a 'tendency to hernia' the patient complains of a dragging and aching type of pain which gets worse as the day passes. Pain may appear long before the lump is noticed. It continues so long as the hernia is progressing but ceases when it is fully formed.

When the hernia becomes very painful and tender, it is probably strangulated. At this time the patient may complain of pain all over the abdomen due to drag on the mesentery or omentum.

2. **Lump.**— Many herniae may cause no pain and the patient presents because he noticed a swelling in the groin. But this is very rare and some sort of discomfort is almost always present. The followings are the set questions to be asked in case of any inguinoscrotal swelling :

(a) *How did it start?* — Whether on straining like coughing or lifting weight. This is usual in case of a hernia. (b) *Where did it first appear?* If it be in the groin and

gradually extended into the scrotum — it is an inguinal hernia. If it had appeared below the groin crease and gradually ascends above it — the swelling is a femoral hernia. (c) *What was the size and extent when it was first seen?* If the hernia reaches the bottom of the scrotum at its first appearance, it is a congenital hernia developed into a preformed sac. It must be remembered that though it is a congenital hernia it may appear at any age. In the acquired type the swelling is small to start with and gradually increases in size. (d) *Does it disappear automatically on lying down?* Direct inguinal hernia disappears automatically as soon as the patient lies down. Indirect hernia has to be reduced.

3. **Systemic symptoms.**— If the hernia is obstructing the lumen of the bowel (incarcerated hernia) cardinal symptoms of intestinal obstruction will appear. They are colicky abdominal pain, vomiting, abdominal distension and absolute constipation. If the patient is vomiting, note the character of the vomitus — whether bilious or faecal smelling. Faecal smelling vomitus heralds ominous sign.

4. **Other complaints.**— The cause of the hernia must be enquired into. Persistent coughing of chronic bronchitis, constipation, frequency of micturition or urgency of benign enlargement of prostate may be the earlier complaints which the patients deliberately do not mention considering them to be irrelevant. Leading questions may be asked to find out these complaints.

PAST HISTORY.— Whether the patient had any operation or not? During appendicectomy division of nerve may lead to weakness of the abdominal muscles at the inguinal region and a subsequent direct inguinal hernia. Many a time the patient



Fig.38.1.— A typical case of left oblique inguinal hernia.



Fig.38.2.— A direct inguinal hernia may develop as a result of weakness of the abdominal wall caused by division of nerves during appendicectomy.

gives a previous history of hernia repair on the same side (recurrent hernia) or on the opposite side (right sided hernia generally precedes that of the left side).

LOCAL EXAMINATION

It must be realised that both the inguinal regions must be exposed from the level of the umbilicus to the mid-thigh level.

Position of the patient.— Patient is first examined in the standing position and then in the supine position. Inguinal, femoral, epigastric, obturator, lumbar, gluteal and Spigelian herniae are best examined in the standing position and should not be omitted. The patient is asked to hold the clothes up during examination in the standing position. He must not bend forward while being examined.

INSPECTION.—

1. **Swelling.**— If a swelling is already present, note (i) *Size & Shape.*— An indirect hernia is pyriform in shape, with a stalk at the external inguinal ring. It usually extends down into the scrotum. A direct hernia is spherical in shape and shows little tendency



Fig.38.3.— Looking for an impulse on coughing while the patient coughs. Note the position of the patient (standing and that of the examiner — sitting).



Fig.38.4.— In case of inguinal hernia, which is even commoner in case of females, the swelling lies medial to the pubic tubercle positioned by the tip of the index finger.

to enter into the scrotum. Femoral hernia, takes up a spherical shape starting from below and lateral to the pubic tubercle. (ii) *Position* and *Extent.*— Inguinal hernia extends from above the inner part of the inguinal ligament down to the scrotum. Note if the swelling goes right down to the bottom of the scrotum (congenital type) or stops just above the testis (funicular and acquired varieties). Femoral hernia extends from below the inguinal ligament and ascends over it. (iii) *Visible peristalsis.*— If the covering is thin as in recurrent hernia peristalsis may be observed. Visible peristalsis is never seen in femoral hernia. In case of inguinal hernia the students should remember that the scrotal skin exhibits movements due to contraction of the dartos.

2. **Skin over the swelling.**— In uncomplicated hernia the overlying skin should be normal. If the hernia is strangulated the skin may be reddened. If the patient is using truss for a long time, discolouration and streaks of brown pigmentation due to deposition of haemosiderin may be seen. The subcutaneous tissue may be atrophied, so the skin may be wrinkled. In case of recurrent hernia scar of previous operation will be evident. A wide, irregular and puckered scar indicates wound infection following previous operation. This is one of the common causes of recurrence.

3. **Impulse on coughing.**— The patient is asked to turn his face away from the clinician and to cough. This is done to avoid the salivary shower from the patient. Look carefully at the superficial inguinal ring. If a swelling already exists, it will expand

during coughing as more abdominal contents will be driven out into the hernial sac due to increased abdominal tension (expansile cough impulse). If a swelling was not present a momentary bulge may be seen synchronously with the act of coughing. Presence of expansile cough impulse is almost diagnostic of a hernia, but absence of this sign does not exclude a diagnosis of hernia. If the neck of the sac is blocked by adhesions additional viscera will not get access into the sac during coughing.

4. **Position of the penis.**— This is only important in case of inguinal hernia. A large hernia in the scrotum will push the penis to the other side.

PALPATION.— If a swelling is present it is palpated systematically from in front, from the side and from behind noting all the points, e.g. temperature, tenderness, size and shape etc., as discussed in chapter 3 'Examination of a Swelling'. Only important points relevant to cases of hernia are discussed below :



Fig.38.5.— The femoral hernia lies lateral to the pubic tubercle (positioned by the tip of the index finger) and below the inguinal ligament. When the hernia enlarges it travels upwards superficial to the inguinal ligament as shown by the arrow.



Fig.38.6.— Shows the method 'to get above the swelling'. In a case of inguinal hernia this is not possible. It is only possible in a pure scrotal swelling.

1. **Position** and **Extent.**— If the swelling descends into the scrotum or labia majora, it is obviously an inguinal hernia. When it remains confined to the groin, it should be differentiated from a femoral hernia. Two anatomical structures are considered in this respect — (a) the pubic tubercle and (b) the inguinal ligament. An inguinal hernia is positioned above the inguinal ligament and medial to the pubic tubercle, whereas a femoral hernia lies below the inguinal ligament and lateral to the pubic tubercle. But it must be remembered that a large femoral hernia ascends superficial to the inguinal ligament though its base will still be below the inguinal ligament. In obese patients it is very difficult to feel the pubic tubercle. One may follow the tendon of adductor longus upwards to reach the pubic tubercle.

2. **To get above the Swelling** (Fig.38.6).— In case of a swelling this is important. This examination differentiates a scrotal swelling from an inguino-scrotal swelling. The root of the scrotum is held between the thumb in front and other fingers behind in an attempt to reach above the swelling. In case of inguinal hernia one cannot get above

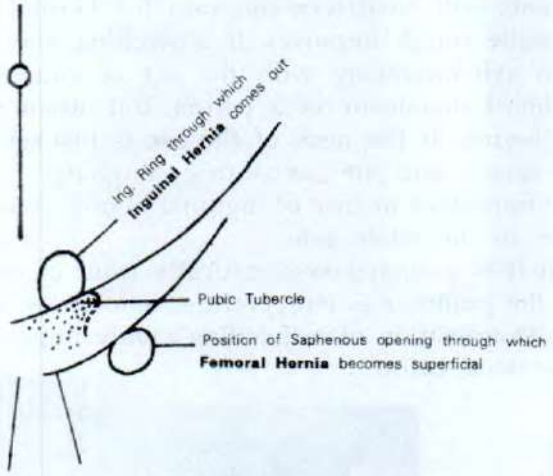

Fig.38.7.— Diagrammatic representation showing the relative positions of inguinal hernia and femoral hernia in respect to pubic tubercle. The superficial inguinal ring is placed above and medial to the pubic tubercle. The saphenous opening is situated 4 cm below and lateral to pubic tubercle.

testis can be felt apart from the hernia.

the swelling, whereas in case of the pure scrotal swelling one can feel nothing between the fingers except the structures within the spermatic cord. In case of femoral hernia this examination is of no use as femoral hernia does not give rise to a scrotal swelling.

3. **Consistency.**— The swelling feels doughy and granular if the hernia contains omentum (omentocele or epiplocele). It is elastic if it contains intestine (enterocele). A strangulated hernia feels tense and tender. This is of great importance in diagnosing this condition.

4. **Relation of the swelling to the testis and spermatic cord.**— Inguinal hernia remains in front and sides of the spermatic cord and testis which remain incorporated in the swelling. If the hernia is acquired or of funicular variety the hernia stops just above the testis. So the

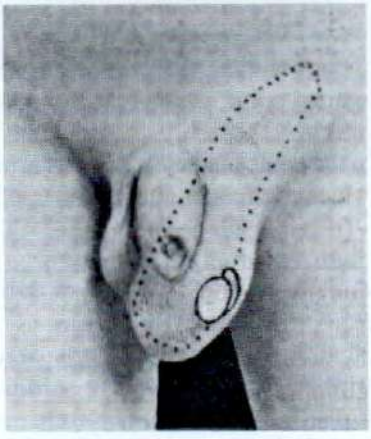

Fig.38.8.— Inguinoscrotal swelling caused by an infantile hydrocele.

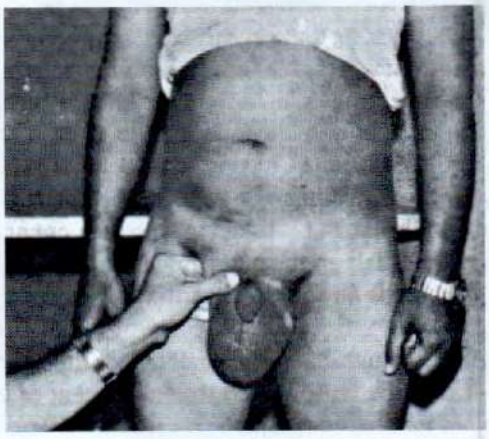

Fig.38.9.— Shows the method of palpation for impulse on coughing.

TWO CLASSICAL SIGNS OF AN UNCOMPLICATED HERNIA ARE (i) IMPULSE ON COUGHING AND (ii) REDUCIBILITY.

5. **Impulse on coughing** (Fig.38.9).— This examination should always be performed in standing position of the patient. When there is no swelling a finger is placed on the superficial inguinal ring and the patient is asked to cough. The root of the scrotum can also be held between the index finger and the thumb and felt for impulse on



Fig.38.10.— An incomplete indirect left inguinal hernia.

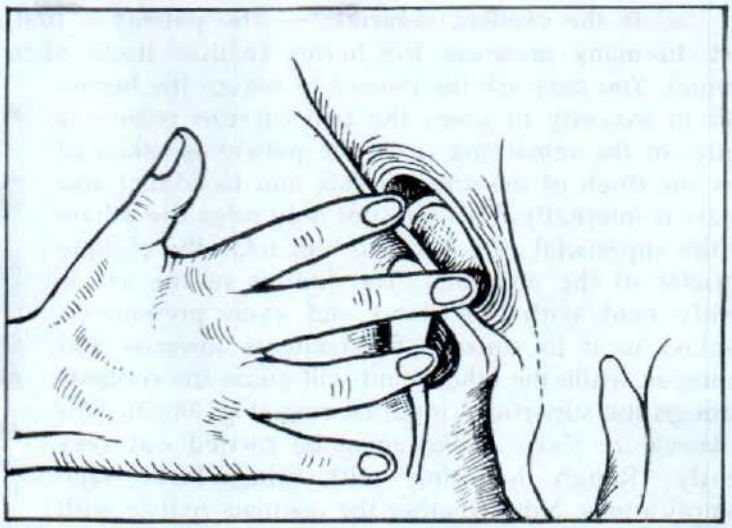

Fig.38.11.— Zieman's technique is shown in which the index finger is placed on the deep inguinal ring (to detect bulge of the indirect inguinal hernia when the patient coughs), the middle finger is placed on the superficial inguinal ring (to detect bulge of the direct inguinal hernia when the patient coughs) and the ring finger is placed on the saphenous opening (to detect bulge of the femoral hernia when the patient coughs). The patient is now asked to cough to diagnose the type of hernia the patient is suffering from.

coughing. Contents of hernia will force out through the superficial inguinal ring and separate the thumb and the index finger. This is an expansile impulse. *Impulse on coughing will be absent in case of strangulated hernia, incarcerated hernia and when the neck of the sac becomes blocked by adhesions which prevent fresh entrance of the contents into the sac.* A distinguished method (Fig.38.11) to find out whether the case is one of direct, indirect (oblique) or femoral hernia is to place the index finger over the deep inguinal ring (½ inch above the mid-inguinal point, which is the midpoint between anterior superior iliac spine and symphysis pubis), the middle finger over the superficial inguinal ring and the ring finger over the saphenous opening (4 cm below and lateral to the pubic tubercle). Remember this technique (*Zieman's technique*) can only be applied when there is no obvious swelling or after the hernia has been completely reduced. The patient is asked to hold the nose and blow (this is better according to Zieman) or to cough. When impulse is felt on the index finger the case is one of indirect hernia, when impulse is felt on the middle finger the case is one of direct hernia and when it is felt on the ring finger the case is one of femoral hernia.

In presence of swelling, coughing will expand (expansile impulse) the swelling and will increase tension within the swelling. It must be remembered that movement of the swelling is not a criterion. A localised swelling of the spermatic cord (encysted hydrocele of the cord) or an undescended testis will sometimes move down the inguinal canal and may come out through the external opening yet it is not a hernia. In case of a large femoral hernia many a time it is not so easy to elicit impulse on coughing. The whole mass is picked up between the thumb and the fingers to get at the root. Now the patient is asked to cough to palpate impulse on coughing.

6. **Is the swelling reducible?**— The patient is first instructed to lie down on the bed. In many instances the hernia reduces itself when the patient lies down (direct hernia). You may ask the patient to reduce the hernia and in majority of cases the patients can reduce it aptly. In the remaining cases the patient is asked to flex the thigh of the affected side and to adduct and rotate it internally. This will not only relax the pillars of the superficial ring but also will relax the oblique muscles of the abdomen. The fundus of the sac is gently held with one hand and even pressure is applied to it to squeeze the contents towards and abdomen while the other hand will guide the contents through the superficial inguinal ring (Fig. 38.12). *This is known as 'Taxis'.* Taxis must be carried out very gently. Rough handling will bring forth fatal complications. Note whether the contents reduce with gurgling. This occurs in an enterocele. In enterocele the first part is often difficult to reduce but the last part slips in easily. In an omentocele the first part goes in easily while the last part resents to be reduced.



Fig.38.12.— Shows the method of reducing an inguinal hernia. Note that the thigh is flexed and internally rotated. With one hand the fundus of the sac is being squeezed while with the other hand the hernia is directed through the superficial inguinal ring.

In case of femoral hernia similar manoeuvre is employed to reduce except for the fact that the contents are reduced through the saphenous opening.

If a hernia cannot be reduced, it is an irreducible hernia or an obstructed hernia or a strangulated hernia.

7. **Invagination test.**— *After reduction of the hernia* this test may be performed to palpate the hernial orifice. It is better to perform this test in recumbent position of the patient. Little finger should be used to minimise hurting the patient. But if it becomes inconvenient, one can use the index finger. Invaginate the skin from the bottom of the scrotum and the little finger is pushed up to palpate the pubic tubercle. Right hand should be used for the right side and left hand for the left side. The finger is then rotated and pushed further up into the superficial inguinal ring. The nail will be against the spermatic cord and the pulp will feel the ring. *Utmost gentleness is required for this examination.* Normal ring is a triangular slit which admits only the tip of a finger. If more than one finger can be easily introduced, the ring is abnormally large. But this will not always be associated with hernia. The patient is asked to cough.

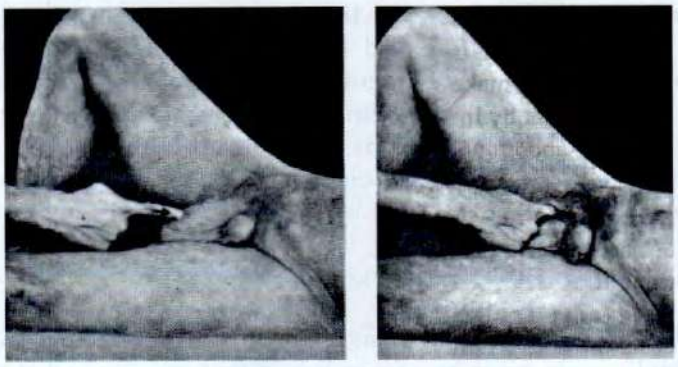

Figs.38.13 & 38.14.— Invagination test. Commence invagination of the skin from the bottom of the scrotum so as to get free play of the finger for the second stage of examination.

Normally the examining finger will be squeezed by the approximation of the two pillars. A palpable impulse will confirm the diagnosis.





Figs.38.15 & 38.16.— Ring occlusion test after reduction of an inguinal hernia. The deep inguinal ring is being occluded with the tip of the thumb. The patient is now asked to cough. In case of indirect hernia no bulging will be seen whereas in case of direct hernia (as shown in the second figure) the hernia comes out.

When the finger enters the ring — *does it go directly backwards* (direct hernia) or upwards, backwards and outwards (indirect hernia)? The finger is again rotated so that the pulp of the finger looks backwards. The patient is again asked to cough. If the *impulse is felt on the pulp of the finger the hernia is a direct one and if the impulse is felt on the tip it is an oblique hernia.*

8. **Ring occlusion test.**— This test is performed in standing position and the hernia must be reduced first. This is a confirmatory test to differentiate an indirect inguinal hernia from a direct inguinal hernia. Since an indirect (oblique) hernia comes out through the deep inguinal ring and a direct hernia medial to the ring, pressure over the deep inguinal ring will occlude the indirect hernia but not the direct hernia. A thumb is pressed on the deep inguinal ring (½ inch above the mid-point between the anterior superior iliac spine and the symphysis pubis). The patient is asked to cough. A direct hernia will show a bulge medial to the occluding finger but an indirect hernia will not find access. See Figs. 38.15 and 38.16.

In case of femoral hernia if pressure is exerted over the femoral canal the hernia will not be able to come out. This is a confirmatory test for femoral hernia.

9. **In case of child** a small inguinal hernia is often invisible due to presence of thick pad of fat over the inguinal region. To make visible such a hernia the child is asked to jolt or jump from the examining table or deliberately make it cry according to its age. Now palpate the spermatic cord as it emerges from the superficial inguinal ring. If there is a hernia the cord will be felt thicker than its fellow on the opposite side due to presence of hernial sac. Even when this test fails *Gornall's test* is performed. The child is held from back by both hands of the clinician on its abdomen. The abdomen is pressed and the child is lifted up. This will make the hernia apparent by increasing intra-abdominal pressure.

PERCUSSION.— A resonant note over a hernia means it contains intestine (enterocele). Whereas if the note is dull it contains omentum or extraperitoneal



Fig.38.17.— An encysted hydrocele of the cord comes down and becomes fixed when the testis is pulled down.

fatty tissue. Percussion can differentiate acute epididymitis and acute filarial funiculitis from strangulated hernia. The note will be resonant in case of the latter whereas in case of former two cases the note will be dull.

AUSCULTATION.— This does not give much diagnostic clue. Peristaltic sounds may be heard in an enterocele.

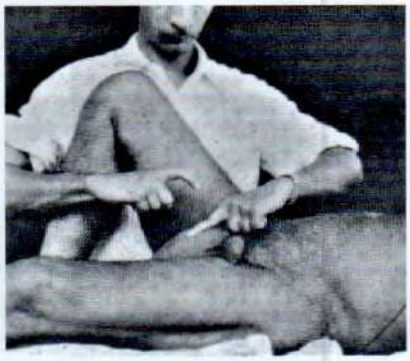

Fig.38.18.— Percussion on an inguinal hernia will give indication about its contents — an enterocele (resonant) or epiplocele (dull).

Examine the testis, epididymis and spermatic cord as discussed in chapter 40. This part of examination is very important. In *traction test* the testis is pulled downwards and with this the encysted hydrocele of the cord descends slightly and becomes fixed.

Examine the tone of the abdominal muscles to select the type of operation suitable for the particular case. The tone can be examined in the following ways : (a) To observe the patient in profile. Undue protrusion of the lower abdomen denotes loss of tone. (b) In recumbent position the patient is asked to raise his shoulders against resistance. When oblique muscles are strong, retraction of the abdominal wall will be observed over the flanks. When the abdominal muscles are weak this test will demonstrate the *'Malgaigne's bulgings'* in the inguinal region or just above it. These are





Figs.38.19 & 38.20.— Methods of estimating the tone of the abdominal muscles (a) by observing the patient in profile and (b) by 'rising test' to demonstrate Malgaigne's bulgings.

oval-shaped longitudinal bilateral bulge produced on straining, above and parallel to the medial half of the inguinal ligament i.e. along the inguinal canal. It indicates poor tone of the oblique muscles. (c) A finger is introduced into the superficial inguinal ring and the patient is asked to cough. The strength of the two pillars and the sphincteric action of the conjoined tendon can be assessed.

GENERAL EXAMINATION

Thorough examination must be performed to exclude chronic bronchitis, enlarged

prostate, stricture urethra, chronic constipation etc., which will induce chronic strain as to cause hernia to develop.

The **chest** must be thoroughly examined to exclude any cause of chronic cough. Rectal examination is obligatory to exclude chronic constipation and enlarged prostate.

Abdomen should always be examined to exclude presence of intestinal obstruction.

DIFFERENTIAL DIAGNOSIS

INGUINAL HERNIA

A. **ANATOMICAL TYPES.**— Three types of classification can be made under this heading. **According to the extent** of the hernia it can be either (a) a *bubonocele* — when the hernia does not come out of the superficial inguinal ring. (b) *an incomplete hernia* — when it comes out through the superficial inguinal ring but fails to reach the bottom of the scrotum, and (c) *a complete hernia* — when it reaches the bottom of the scrotum.

According to its site of exit it can be either (a) *an oblique (indirect) hernia* — when the hernia comes through the deep inguinal ring i.e lateral to the inferior epigastric artery and (b) *a direct hernia* — when it comes out through the Hesselbach's triangle which is bounded medially by the lateral border of the rectus abdominis, laterally by the inferior epigastric artery and below by the inguinal ligament. That means the neck of the sac lies medial to the inferior epigastric artery.

According to the contents of the hernia, a hernia may be either (a) *an enterocele* — when it contains the intestine (enteron); (b) *an epiplocele* or *omentocele* — when it contains omentum (epiploon); or (c) a *cystocele* when it contains the urinary bladder.

OBLIQUE (INDIRECT) HERNIA.— It comprises more than 80% cases of inguinal hernia. Almost all the herniae in children and women are of this type. It occurs earlier than a direct hernia. It is often complete i.e. it reaches the bottom of the scrotum. The hernia descends obliquely downwards and inwards and it reduces obliquely in the opposite direction. This type of hernia does not reduce by itself and if reduced, does not come out at once, but requires a cough to bring it down. For reduction a little manipulation is required. If the internal ring is occluded the hernia cannot come out even if the patient coughs. Two forms of indirect inguinal hernia are found in practice; (i) congenital and (ii) acquired.

Congenital hernia.— Normally the funicular process of peritoneum becomes obliterated after the testis has reached the scrotum. The scrotal part of the process remains patent and acquires the name 'tunica vaginalis'. In case of congenital hernia the whole process remains patent. With increase in the abdominal pressure abdominal contents come out through the patent peritoneal process. Thus a congenital hernia reaches the bottom of the scrotum very quickly. It may so happen that the funicular process remains patent up to the top of the testis. So the hernia stops at the top of the testis and is known as a *congenital funicular hernia*. It must be remembered that congenital hernia, though so named, is usually seen in adults.

Acquired hernia.— As the name suggests it does not protrude into a pre-formed sac. Clinically it can be differentiated from a congenital hernia by the fact that it does not become complete at once. Acquired hernia progresses gradually.



Fig.38.21.—Congenital vaginal hernia.



Fig.38.22.— Congenital funicular hernia.



Fig.38.23.— Acquired hernia.

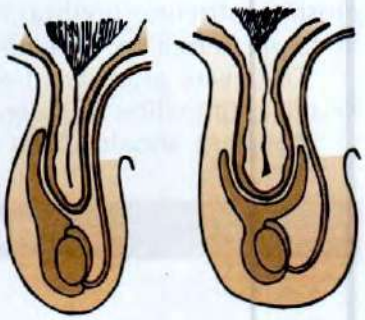

Figs.38.24 & 38.25.— Two types of infantile hernia.

DIRECT HERNIA.— This hernia is more common above the age of 40. It is frequently incomplete, but it may descend into the scrotum if remains untreated for years. The hernia comes out as soon as the patient stands and disappears immediately when he lies down. The swelling is more often spherical in shape. In case of invagination test the finger goes directly backwards instead of upwards, backwards and laterally (in case of indirect hernia). When the patient is asked to cough after occluding the deep inguinal ring the hernia comes out medial to the occluding finger. Direct hernia does not come out through the deep inguinal ring but a little medial to the ring. It becomes rarely strangulated as the neck of the sac is wide.

Enterocele is elastic in consistency, resonant on percussion and slips back into the abdomen with a distinct gurgle. Peristalsis may occasionally be seen if the coverings are thin. Peristaltic sound can be heard on auscultation. Reduction may be difficult in the beginning but easy towards the end.

Epiplocele feels doughy and granular. It is dull on percussion and reduces without gurgle. Reduction may be easy in the beginning but is difficult towards the end.

Cystocele only occurs in a direct hernia or in sliding hernia. It is suspected when the patient gives the history that the hernia gets enlarged just before micturition and smaller after micturition. Pressure on the hernia induces a desire for micturition particularly when it is distended.

B. **CLINICAL TYPES.**— Clinically hernia may be of five types :

1. ***Reducible hernia.***— Normally an uncomplicated hernia is reducible. That means its contents can be returned into the abdominal cavity, but the sac remains in its position.

2. ***Irreducible hernia.***— In this hernia the contents cannot be returned to the abdomen, but it does not suggest any other complication whatsoever. Various causes of irreducibility are :— (i) adhesion of its contents to each other, (ii) adhesion of its contents with the sac, (iii) adhesion of one part of the sac to the other part, (iv) sliding hernia and (v) very large scrotal hernia (scrotal abdomen). Irreducible hernia is often confused with strangulated hernia by the beginners. Clinically a strangulated hernia is also irreducible, but it is extremely tender and tense and the overlying skin may be red. These signs are absent in a pure irreducible hernia.

3. ***Obstructed or incarcerated hernia*** (irreducibility+Intestinal obstruction).— An

obstructed hernia means the hernia is associated with intestinal obstruction due to occlusion of the lumen of the bowel. It must be remembered that there is no interference with the blood supply to the intestine in this hernia. One must be very careful to make this diagnosis, as strangulated hernia also possesses two of its features i.e. irreducibility and intestinal obstruction. Of course the third and most important feature of a strangulated hernia is missing in this hernia i.e. interference with the blood supply of the intestine. So it is a dangerous venture to diagnose obstructed hernia when strangulation may be the real state of affair and thus valuable time will be wasted until it becomes too late to save the patient's life.

4. ***Strangulated hernia*** (irreducibility+obstruction+arrest of blood supply to the contents).— A hernia is said to be strangulated when the contents are so constricted as to be interfered with their blood supply. Intestinal obstruction may not be present particularly in case of omentocele, Richter's hernia and Littre's hernia. Diagnosis of strangulation is made when a hernia is irreducible, without any impulse on coughing, extremely tense and tender. These are followed by features of acute intestinal obstruction.

5. ***Inflamed hernia.***— This is a very rare condition and mimics in many respects a strangulated hernia. This hernia may occur when its content such as an appendix, a salpinx or a Meckel's diverticulum becomes inflamed. Diagnosis is made by the presence of constitutional disturbances associated with local signs of inflammation — overlying skin becomes red and oedematous and the swelling becomes painful, tender and swollen. The only differentiating feature from a strangulated hernia is that this hernia is not tense and is not associated with intestinal obstruction.

Rare varieties of hernia are :— 1. **Hernia-en-glissade or Sliding Hernia.**— In this type of hernia a piece of extraperitoneal bowel, usually the caecum on the right side or the pelvic colon on the left side or the urinary bladder on either side slides down outside the hernial sac forming a part of its wall being covered by the peritoneum on the hernial aspect only. There may be the usual contents in the sac. These herniae usually occur in older men. A large globular hernia when descends well into the scrotum this condition is suspected. It reappears slowly after reduction. This condition may be associated with strangulated small intestine within its sac or a strangulated large intestine outside the sac.



Fig.38.26.— Hernia-en-glissade or sliding hernia. The thick line represents the peritoneum, Note that the colon forms the wall of the sac.

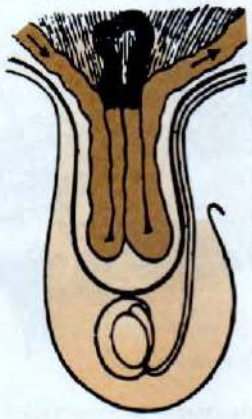

Fig.38.27.— Maydl's hernia. The loop in the abdomen is always found at a more advanced stage of strangulation than the loops in the sac.

2. **Richter's hernia.**— In this condition only a portion of the circumference of the bowel becomes strangulated. This condition often complicates a femoral hernia and rarely an obturator hernia. This condition is particularly dangerous as operation is frequently delayed because the clinical features resemble gastroenteritis.

Intestinal obstruction may not be present until and unless half of the circumference of the bowel is involved. The patient may or may not vomit, intestinal colic is present but the bowels are opened normally. There may be even diarrhoea. Absolute constipation is delayed until paralytic ileus supervenes.

3. **Littre's hernia** is a hernia which contains Meckel's diverticulum.

4. **Maydl's hernia (Hernia-en-W)** *or retrograde strangulation.*— In this condition two loops of bowels remain in the sac and the connecting loop remains within the abdomen and becomes strangulated. The loops of the hernia look like a 'W'. The loop within the abdomen becomes first strangulated and can only be suspected when tenderness is elicited above the inguinal ligament along with presence of intestinal obstruction.

FEMORAL HERNIA

A femoral hernia is a protrusion of extraperitoneal tissue, peritoneum and sometimes abdominal contents through the femoral canal. The femoral canal is bounded superoanteriorly by the inguinal ligament, inferoposteriorly by the pubic ramus and pectineus muscle, medially by the lacunar ligament (Gimbernat's ligament) and laterally by the femoral vein. The hernia actually comes out superficially through the saphenous opening situated 1½ inches below and lateral to the pubic tubercle. When the hernia is within the femoral canal it remains narrow, but once it escapes through the saphenous opening into the loose areolar tissues, it expands considerably. So a femoral hernia assumes the shape of a retort. Its bulbous extremity expands upwards even above the inguinal ligament.

Femoral hernia is very rare before 20 years of age. The incidence gradually rises till the highest incidence is over 50 years. Femoral hernia is commoner in women (2 : 1). But the students must remember that even in women the commonest hernia in the groin is the inguinal hernia. The right side is affected twice as common as the left side and in 20 per cent of cases the condition is bilateral. The symptoms from femoral hernia are less pronounced than those of inguinal hernia. One thing must be borne in mind that the femoral canal being a rigid opening this hernia becomes *strangulated very often.*

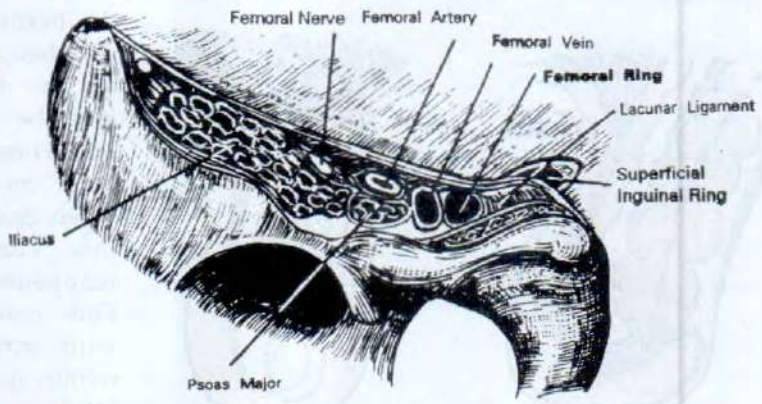

Fig.38.28.— Anatomic representation of the position of the femoral ring.

The femoral hernia is *differentiated from an inguinal hernia* by the following points : (a) The femoral hernia lies lateral to the pubic tubercle and below the inguinal ligament but in late stage it may extend up above the inguinal ligament, whereas an inguinal hernia lies medial to the pubic tubercle and above the inguinal ligament. (b) In case

of femoral hernia impulse on coughing can be seen and felt on the saphenous opening which is about 4 cm below and lateral to the pubic tubercle. (c) In case of femoral hernia the inguinal canal will be empty as determined by the 'invagination test'. (d) By occluding the deep inguinal ring an indirect hernia can be stopped coming out even if the patient coughs, but the direct hernia will bulge medial to the deep inguinal ring. Similarly a femoral hernia can be prevented from coming out by pressure applied over the femoral canal or the saphenous opening.

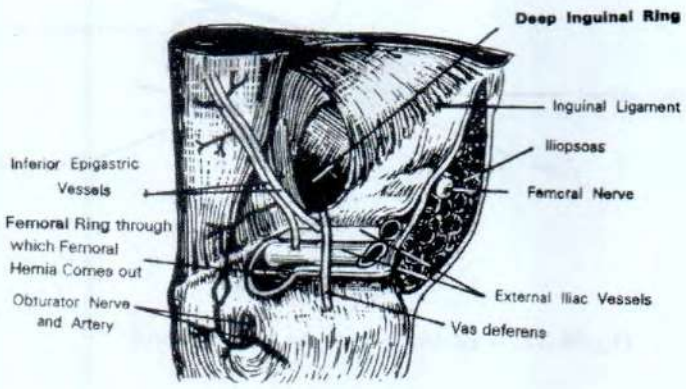

Fig.38.29.— Another anatomical representation of relative positions of deep inguinal ring and femoral ring which are shown from inside the abdomen through which inguinal hernia and femoral hernia come out respectively.

PRE-VASCULAR FEMORAL HERNIA.— This is a special variety of femoral hernia, which descends not through the femoral canal, but bulges down posterior to the inguinal ligament and in front of the femoral artery and vein. Obviously it has a wide neck and a flattened wide sac. This hernia is not difficult to diagnose and can be reduced easily. Such hernia rarely gets strangulated and is very difficult to repair.

A femoral hernia should be differentiated from :

1. **Saphena varix.**— It is a saccular enlargement of the termination of the long saphenous vein. This swelling usually disappears completely when the patient lies down. The so called impulse on coughing is present in this condition as well, but it is actually a fluid thrill and not an expansile impulse to the examining fingers. Varicosity of the long saphenous vein is usually associated with.

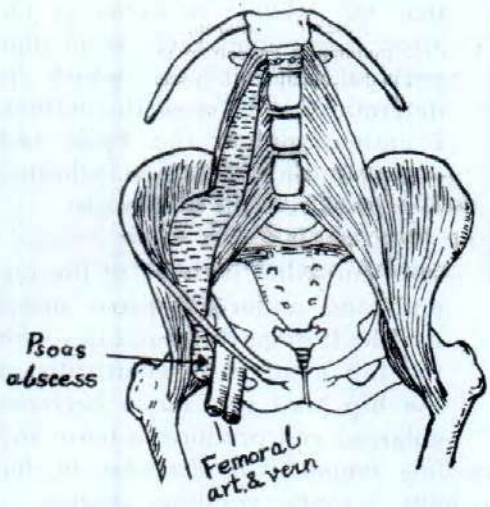

Fig.38.30.— Psoas abscess usually points in the groin lateral to the femoral vessels. The track of the psoas abscess from the caries spine is shown in the figure. It must be remembered that femoral hernia lies on the medial side of the femoral vessels.

Percussion on varicosities of the long saphenous vein will transmit an impulse upwards to the saphena varix felt by the fingers of the other hand — Schwartz's test. Sometimes a venous hum can be heard when the stethoscope is applied over the saphena varix.

2. **Enlarged lymph nodes.**— A search for a possible focus of infection should be made in the drainage area which extends from the

umbilicus down to the toes including the terminal portions of the anal canal, urethra and vagina (i.e. portions developed from the ectoderm). Causes of enlargement of lymph nodes are discussed in chapter 8. The gland of Cloquet lying within the femoral canal may be enlarged and simulates exactly an irreducible femoral hernia. If any focus cannot be found out or any cause of enlargement of lymph nodes cannot be detected, the nature of the lump remains a matter of opinion which is best settled urgently in the operation theatre.

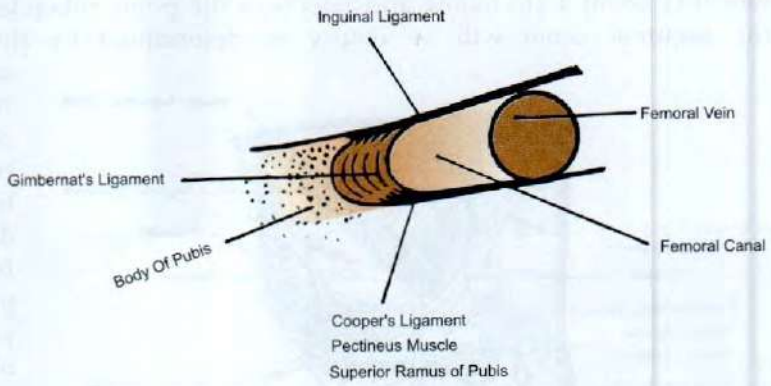

Fig.38.31.— Boundaries of the femoral canal.

3. **Psoas abscess** (Fig.38.30).— This is usually a cold abscess tracking down from Pott's disease. It is a reducible swelling and gives rise to impulse on coughing. It is a painless swelling and if the pulsation of the femoral artery can be palpated it will be appreciated that *the swelling is lateral to the artery*. Sometimes there is an iliac part of the abscess which is determined by cross-fluctuation. Examinations of the back and corresponding iliac fossa including X-rays clarify the diagnosis.



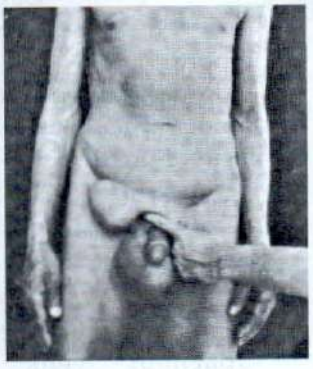

Figs.38.32 & 38.33.— Femoral hernia in male, a rare occurrence. In the first figure, the tip of the finger lies over the pubic tubercle. In the second figure 'invagination test' is being demonstrated. The inguinal canal is empty in a femoral hernia.

4. **An enlarged psoas bursa.**— This bursa lies in front of the hip joint and under the psoas major muscle. It often communicates with the hip joint. In osteoarthritis of the hip joint this bursa becomes enlarged and produces a tense and cystic swelling below the inguinal ligament. *This swelling diminishes in size when the hip joint is flexed*. Presence of osteoarthritis in the hip joint, a cystic swelling, absence of impulse on coughing and that the swelling diminishes in size during flexion of the hip joint are the diagnostic points in favour of this condition.

5. **A femoral aneurysm.**— Expansile pulsation is the pathognomonic feature of this condition.

6. **Lipoma.**— The diagnostic points in favour of this condition are discussed in chapter 3.

7. **Hydrocele of a femoral hernial sac.**— This is an extremely rare condition in which the neck of the sac becomes plugged with omentum or by adhesions. The hydrocele of the sac is thus produced by the secretion of the peritoneum.

UMBILICAL HERNIA

Any hernia which appears to be closely related to the umbilicus can be called as "Umbilical hernia". Four definite varieties are seen :

1. **Exomphalos.**— Abdominal contents are protruded *into the umbilical cord* being covered by a transparent membrane — a diaphanous membrane.

2. **Congenital umbilical hernia.**— This hernia comes out through the centre of a congenital weak umbilical scar. It is common in Negroes. It generally appears in the first few months after birth. Common symptom is the swelling rather than anything else. The neck of the hernia is generally wide and hardly gives rise to intestinal obstruction or strangulation. The main diagnostic features are — (i) Bulge through the centre of the umbilical scar everting the whole umbilicus; (ii) Age of the patient; (iii) The swelling is easily reducible (spontaneously reduced when the child lies down) and there is definite impulse on crying; (iv) The size of the hernia varies — it may be a small defect admitting the tip of the little finger alone to quite a large opening admitting two or three fingers; (v) The content is usually small intestine, so resonant to percussion; (vi) About 90% of these herniae disappear spontaneously during the first 5 years of life as the umbilical scar thickens and contracts.

3. **Acquired umbilical hernia.**— This hernia occurs in adult life and protrudes through the umbilical scar. It is very rare in comparison to the para-umbilical hernia which is described below. Almost invariably it is due to raised intra-abdominal pressure which has forced the hernia through the umbilical scar. One must try to find out the cause of raised intra-abdominal pressure in these cases. Common causes are — pregnancy, ascites, bowel distension, ovarian cyst and fibroid.

4. **Para-umbilical hernia.**— It is the commonest acquired umbilical hernia. It occurs *through a defect adjacent to the umbilicus.* The usual site is just above the umbilicus between the two recti, in fact lower half of the fundus of the sac is covered by the umbilicus. The diagnostic features are as follows : (i) Para-umbilical hernia develops in the middle and old age; (ii) Obese women are more commonly affected; (iii) Usual symptoms are pain and swelling. If the swelling is very small, it may not be noticed by the patient and the pain and discomfort become the main symptoms; (iv) The surface is smooth and the edge is distinct except when the patient is very fat; (v) It contains omentum or bowel. The lump is firm when it contains omentum. The lump is soft and resonant to percussion when the content is bowel; (vi) Many paraumbilical herniae are irreducible when the contents become adherent to the sac or the neck of the sac becomes narrow. If the hernia can be reduced, the firm fibrous edge of the defect in the linea alba can be felt; (vii) As the defect in the linea alba is firm and does not enlarge proportionately these herniae do give rise to intermittent abdominal pain, though strangulation is not common.

EPIGASTRIC HERNIA

An epigastric hernia is a protrusion of extra-peritoneal fat and sometimes a small peritoneal sac through a defect in the linea alba. This defect is usually placed somewhere between the xiphisternum and the umbilicus. The main symptom is epigastric pain and swelling. Pain is usually located over hernia. It often begins after eating probably due to epigastric distension. If the patient could not see the lump, a self-diagnosis of peptic

ulcer is often made. So whenever a patient will complain of epigastric discomfort or pain palpate the abdominal wall first to detect a small lump of epigastric hernia. It must be remembered that usually these herniae do not have impulse on coughing and cannot be reduced. Lipoma very much resembles this condition. That the swelling cannot be moved over the underlying structures favours the diagnosis of epigastric hernia.

INCISIONAL HERNIA is the hernial protrusion through the scar, usually due to previous surgical operation or accidental trauma. Infection of the wound and injury to the motor nerve predispose hernia formation.

DIVARICATION OF THE RECTI.— In this condition the linea alba stretches and allows the two recti muscles to part from each other. These two muscles are inserted to the pubis very close to the midline. By repeated contractions of the flat muscles of the abdomen the two recti show tendency to diverge particularly when the linea alba is weak. This condition is common in elderly multipara.

INTERSTITIAL HERNIA.— This is also called an *Interparietal hernia*. In this condition the hernial sac passes between the layers of the anterior abdominal wall. This sac may be a continuation of an inguinal or femoral hernial sac.

SPIGELIAN HERNIA.— This hernia occurs through the linea semilunaris at the level of the arcuate line i.e. a few centimetres above the inguinal ligament. Usual victims are above 50 years of age.

LUMBAR HERNIA.— This hernia comes out through the Petit's triangle being bounded below by the crest of the ilium, laterally by the external oblique and medially by the latissimus dorsi. There is another superior lumbar triangle being bounded by the 12th rib above, by the sacrospinalis medially and the posterior border of the internal oblique laterally. Through this triangle also the contents may come out of the abdomen. But the incidence is rarer than inferior lumbar hernia through Petit's triangle. Incisional lumbar hernia may follow an operation on kidney, the incisional wound being infected.

OBTURATOR HERNIA.— This hernia comes out through the obturator foramen. As the hernia is covered by the pectineus muscle, it is often overlooked. This hernia causes more pain than any other type of hernia. Pain often radiates along the obturator nerve and may even be referred to the knee via its geniculate branch. The leg is usually kept in the semiflexed position and movement of the limb gives rise to pain. If the limb is flexed, abducted and rotated outwards the hernia becomes prominent. Patients are mostly over 60 years of age and women are more frequently affected than men. Incidence of Richter's hernia in this condition is only second to femoral hernia.

Chapter

39 EXAMINATION OF A SWELLING IN THE INGUINOSCROTAL REGION OR GROIN (EXCEPT INGUINAL AND FEMORAL HERNIAS)

HISTORY.— (1) *Age.*— Funiculitis (inflammation of the spermatic cord) is a disease of young age. Encysted hydrocele of the cord, lymph varix, varicocele etc. may present at any age.

(2) *Occupation.*— Prolonged standing may be the cause of a varicocele.

(3) *Residence.*— Funiculitis and lymph varix are commoner in Orissa and adjoining districts of West Bengal.

COMPLAINTS.— (1) **Pain.**— Funiculitis is always associated with pain and in fact pain is the presenting symptom in this disease. Tuberculous thickening of the cord, as an extension upwards from the epididymis, is also associated with pain. Malignant extension upward from the testis may be also associated with pain. Vague dragging pain is experienced on prolonged standing in case of a varicocele. Sudden agonising pain over inguinoscrotal region and in the lower abdomen is complained of in torsion of the testis. On right side this condition often mimics appendicitis. So always examine the scrotum in case of sudden lower abdominal pain.

(2) **Swelling.**— Swelling is the main presenting feature in case of encysted hydrocele of the cord, diffuse lipoma of the cord, lymph varix etc. Interrogations like "How did it appear?", "Where did it appear first?", "Does it disappear automatically on lying down?" will give a clue to the diagnosis. A varicocele appears spontaneously whereas a funiculitis starts with fever, ushered in with chill and rigor. An inguinal hernia appears from above whereas an infantile hydrocele, testicular growth and varicocele appear from below. An encysted hydrocele of the cord and diffuse lipoma of the cord appear first in the cord and then gradually enlarge. The commonest place of ectopic testis is the superficial inguinal pouch. The patient will say that the swelling was in that position from the beginning. Undescended testis may give rise to the swelling in the inguinal region from the beginning. A varicocele disappears spontaneously when the patient lies down with the scrotum elevated. A lymph varix also reduces spontaneously on lying down although slower than a varicocele.

(3) **Any other complaints.**— The patient with tuberculous thickening of the cord may present other symptoms like evening rise of temperature, excessive coughing, haemoptysis etc. Rapid onset of varicocele on the left side with haematuria indicates carcinoma of the kidney on that side. Sterility may be complained of in case of bilateral undescended testes (cryptorchism).

PAST HISTORY.— Previous history of periodic attacks of fever accompanied by pain and swelling of the spermatic cord of scrotum is highly suggestive of filarial infection.

PERSONAL HISTORY.— History of exposure may be obtained in gonococcal funiculitis.

LOCAL EXAMINATION

Position of the patient.— It is always convenient in these cases to examine the patient in the *standing position* first and later on in the *recumbent position*. The patient is asked to hold

the clothes up to expose the parts completely. He must not be allowed to bend forwards while he is being examined.

INSPECTION.—

1. **Swelling.**— *Position and extent* of the swelling are very important. A localised swelling in the spermatic cord is encysted hydrocele of the cord whereas a diffuse swelling of the cord may be a lipoma. A swelling in the superficial inguinal pouch (just above and slight lateral to the superficial inguinal ring) with absence of testis in the scrotum is probably an ectopic testis. Similarly a swelling in the inguinal region with absence of testis in the scrotum is an undescended testis.

2. **Skin over the swelling.**— In funiculitis or in certain late cases of torsion of testis the skin over the swelling will be red and oedematous. This must be differentiated from strangulated hernia which also shows signs of inflammation.

3. **Impulse on coughing.**— This differentiates a hernia from other conditions in this region. It must be remembered that lymph varix (lymphangiectasis) also gives an impulse (thrill-like) on coughing. Varicocele also gives an impulse on coughing like a fluid thrill. An undescended testis with associated hernia may also give impulse on coughing.



Fig.39.1.— Ectopic testis in the superficial inguinal pouch (the commonest site). Note that the testis is absent from the right side of the scrotum.

PALPATION.— (1) **Position and Extent.**— A cystic swelling in the middle of spermatic cord without any upward extension is an encysted hydrocele of the cord. A diffuse swelling of the cord may be a lipoma when it is non-inflammatory and a funiculitis when it is inflammatory. The commonest position of an ectopic testis is at the superficial inguinal pouch whereas an undescended testis may be felt in the inguinal canal.

(2) **Consistency.**— A localised cystic, fluctuant and translucent swelling is an *encysted hydrocele of the cord. A lymph varix* feels soft, cystic and doughy. A *varicocele* is diagnosed by its peculiar feel like a "bag of worms".

(3) **Reducibility.**— It is a classical sign of a hernia. But a lymph varix and a varicocele become spontaneously reduced when the patient lies down. This reduction occurs slowly and not abruptly as in the case of a hernia. After reduction the external abdominal ring is pressed with a finger and the patient is asked to stand up. A varicocele and a lymph varix will gradually fill from below. But a hernia is prevented from coming down.

(4) **Impulse on coughing.**— This is also a classical sign of a hernia. A *varicocele* and a *lymph varix* also give impulse on coughing, but the impulse is felt like a thrill and is not the typical expansile impulse as felt in the case of a hernia.

PERCUSSION and **AUSCULTATION** are not important in these cases. Percussion is helpful in differentiating a strangulated hernia from acute funiculitis, the former being resonant as it contains the intestine.

It is always advisable to **examine the testis, epididymis** and the **spermatic cord** in these cases.

GENERAL EXAMINATION

The **chest** should be examined particularly in the case of tuberculous epididymitis extending upwards. The **abdomen** should be examined thoroughly in case of malignant infiltration of the spermatic cord from the testis to exclude presence of palpable enlarged pre- and para-aortic groups of lymph nodes. In a case of rapidly growing varicocele in a middle-aged man one should **examine the kidney** as very often tumour of the kidney spreads along the lumen of renal vein (in case of left side) or inferior vena cava (in case of right side) to obstruct the testicular vein resulting in a varicocele.

CAUSES OF INGUINOSCROTAL AND GROIN SWELLINGS

A. **Inguinoscrotal swellings** (except inguinal hernia).— (i) Encysted hydrocele of the cord; (ii) Varicocele; (iii) Lymph varix or lymphangiectasis; (iv) Funiculitis; (v) Diffuse lipoma of the cord; (vi) Inflammatory thickening of the cord extending upwards from the testis and epididymis; (vii) Malignant extension from the testis; (viii) Ectopic testis; (ix) Undescended testis; (x) Torsion of the testis; (xi) Retractile testis; (xii) Enlarged lymph nodes (external iliac and inguinal groups); (xiii) Abscess in the inguinal region; (xiv) Aneurysm of the external iliac artery.

B. **Femoral swellings** (except femoral hernia).— (i) Enlarged lymph nodes (inguinal group); (ii) Saphena varix; (iii) Psoas abscess; (iv) An enlarged psoas bursa; (v) A femoral aneurysm; (vi) Lipoma; (vii) Hydrocele of a femoral hernial sac; (viii) Ectopic testis; (ix) Osteomyelitis and tumours of the upper end of the femur.

DIFFERENTIAL DIAGNOSIS

A. INGUINOSCROTAL SWELLINGS :

1. **Encysted hydrocele of the cord.**— When a portion of the funicular process persists, remains patent and is shut off from the tunica vaginalis below and the peritoneal cavity above, it eventually becomes distended with fluid and presents a cystic swelling either in the inguinal or inguinoscrotal region or in the scrotum. Fluctuation test and translucency test will be positive. One can very well 'get above the swelling'. If the swelling is held at its upper limit and the patient is asked to cough there will be no impulse on coughing. This shows that it has got no connection with hernia nor with the peritoneal cavity. If the testis is pulled down the swelling will also come down and becomes immobile. This is the ***traction test***. The testis can be felt apart from the swelling.

2. **Varicocele.**— It is a condition in which the veins of the pampiniform plexus become dilated and tortuous. Usually the left side is affected, probably because (i) the left spermatic vein is longer than the right, (ii) the left spermatic vein enters the left renal vein at a right angle, (iii) at times the left testicular artery arches over the left renal vein to compress it and (iv) the left colon when loaded may press on the left testicular vein. In the beginning the patient will experience aching or dragging pain particularly after prolonged standing. The swelling appears when the patient stands and disappears when he lies down with the scrotum elevated. The impulse on coughing is more like a thrill. On palpation it feels like a 'bag of worms'. After occluding the superficial inguinal ring with a thumb if the patient is asked to stand up the varicocele fills from below. It must be remembered that a rapid onset of varicocele suggests a carcinoma of the kidney. The renal vein is often involved earlier by permeation in these cases and thus compresses the left spermatic vein which drains into the left renal vein and on the

right side the inferior vena cava is affected into which the right spermatic vein drains.

3. **Lymph Varix or Lymphangiectasis.**— It is a condition in which the lymphatic vessels of the cord become dilated and tortuous caused by obstruction due to filariasis. Past history of periodic attacks of fever with simultaneous development of pain and swelling of the cord are the main symptoms of this condition. The swelling appears on standing and disappears spontaneously on lying down, although slower than in case of varicocele. The impulse on coughing is thrill like and not the typical expansile impulse found in a case of hernia. On palpation it feels soft, cystic and doughy. Presence of eosinophilia and living microfilariae in the blood drawn at night are very much diagnostic.

4. **Funiculitis.**— Besides gonococcal infection funiculitis may be caused by filariasis particularly in this country. Aching in the groin with variable degree of fever are the presenting symptoms in majority of cases. Initial symptoms may be those of acute prostatitis. The inguinal and inguinoscrotal regions will be inflamed and the skin becomes red, oedematous and shiny. It is sometimes very difficult to differentiate it from a small strangulated hernia. While the former condition is mainly treated by conservative means, immediate operative intervention is the only life saving measure for the latter condition. So differentiation is imperative. Palpation just above the deep inguinal ring is of great help in differentiating these two conditions. In a strangulated hernia the abdominal contents can be felt as they enter the deep inguinal ring whereas in funiculitis no such structures can be felt.



Fig.39.2.— Ultrasonography showing intra-abdominal right testis (undescended testis).

5. **Diffuse lipoma of the cord.**— This is a very rare condition. The cord feels soft and lobulated. The swelling is irreducible having no impulse on coughing.

6. **Inflammatory thickening of the cord** (extending upwards from the testis and epididymis).— Tuberculosis often gives rise to this condition. Slight ache in the testis with generalized symptoms of tuberculosis often ushers this condition. Indurated and slightly tender nodular thickening of the cord can be felt. Epididymis is obviously tender, enlarged and nodular. Rectal examination may reveal indurated seminal vesicle of the corresponding side and sometimes of the contralateral side. In late cases cold abscess develops in the lower and posterior aspect of the scrotum which may discharge itself resulting in formation of a sinus. In about two thirds of the cases active tuberculosis of the renal tract may be evident.

7. **Malignant extension of the testis.**— This can be easily diagnosed by presence of malignant

growth in the testis. The cord feels hard and nodular. There may be secondary deposits in the pre- and para-aortic and even in left supraclavicular lymph nodes.

8. **Undescended and ectopic testis.**— An *undescended testis* is one which is arrested at any point along its normal path of descent. An *ectopic testis* is one which has deviated from its usual path of descent. In both these conditions the scrotum of the same side will be empty. If the swelling is within the inguinal canal it is probably an undescended testis. The testis is recognized by its shape, feel and 'testicular sensation'. Ascertain whether the testis is lying superficial or deep to the abdominal muscles by the 'rising test'. The commonest site for an ectopic testis, is just above and lateral to the superficial inguinal ring and superficial to the external oblique aponeurosis. It must be remembered that the undescended testis is always smaller and less developed than its fellow in the scrotum but an ectopic testis is usually well developed. Sometimes an undescended testis may be associated with an inguinal or an interstitial hernia.

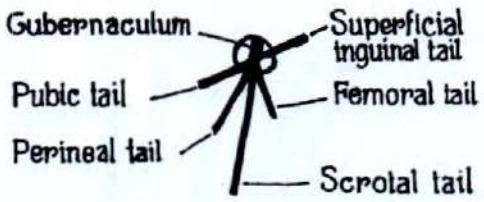

Fig.39.3.— Shows the five tails of gubernaculum testis. See the text.

Though the commonest position of ectopic testis is at the superficial inguinal pouch, yet ectopic testis may be found (i) at the root of the penis (pubic type), (ii) at the perineum (perineal type) and (iii) rarely at the upper and medial part of the femoral triangle (femoral type).

The ectopic testis probably occurs due to rupture of the main scrotal tail of the gubernaculum testis. According to Lockwood the gubernaculum testis has five tails :

1. The scrotal tail — which is the main one.
2. Pubic tail — attached to the pubic tubercle.
3. Perineal tail — attached to the perineum.
4. Inguinal tail — attached to the front of the inguinal canal.
5. Femoral tail — attached to the saphenous opening.

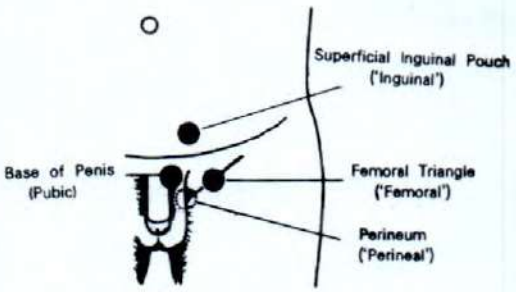

Fig.39.4.— Sites of ectopic testis. These sites are in accordance with the five tails of gubernaculum, of which the normal one is scrotal while the other four are inguinal, pubic, femoral and perineal.

The scrotal tail is the strongest and the other tails normally disappear and that is why the testis normally descends to the scrotum. In case one of the four accessory tails becomes stronger, the testis is drawn towards the attachment of that tail and then the testis is called an *'ectopic testis'*.

9. **Torsion of the testis.**— It is mainly a cause of the swelling of scrotum but an *undescended testis may frequently undergo torsion* which is a subject matter of this chapter. This condition mimics a strangulated hernia. It will give rise to a tense and a tender swelling without an impulse on coughing. Absence of testis in the scrotum should arouse suspicion of this condition. Slight fever, no constipation and dullness on percussion will go in favour of torsion.

10. **Retractile testis.**— This condition is quite common in children and is often diagnosed as ectopic testis due to the fact that in majority of cases the testis lies in the superficial inguinal pouch. Strong contraction of the cremaster muscle may pull the testis up from the scrotum into the superficial inguinal pouch. The testis is usually well developed, the scrotum is also normally developed and the testis can be brought down to the bottom of the scrotum. In difficult cases the child is asked to sit on a chair keeping both feet on its seat and the knees are flexed to the extreme and brought towards its chest. This puts pressure on the inguinal canal downwards and brings the retractile testis into the scrotum. This is known as *'Chair test'*. But probably the first manoeuvre to simply drag the testis into the scrotum is more successful.

B. **FEMORAL SWELLINGS.**— These are discussed in the previous chapter under the heading of 'Femoral Hernia'.



Fig.39.5.— Chair test (Orr). The young patient is asked to sit on a chair hugging his knees to his chest. By this manoeuvre the retractile testis is pushed down to the bottom of the scrotum. By this test retractile testis can be differentiated from ectopic testis.

Chapter

40 EXAMINATION OF MALE EXTERNAL GENITALIA

THE SCROTUM

HISTORY.—

(1) **Age.**— Carcinoma of the skin of the scrotum is a disease of individuals above 50 years of age. But malignant condition of the testis is common in young individuals — teratoma between 20 and 30 years, whereas seminoma between 30 and 40 years. Torsion of the testis is commonly seen in teen-aged boys. Hydrocele is seen even in infants, but the primary hydrocele is most common over the age of 40 years. While the secondary hydrocele is commoner between 20 and 40 years of age. Tuberculous orchitis is the disease of the young. Majority of the epididymal cysts and spermatoceles occur in men above 40 years of age. Cysts of the epididymis, though congenital, appear in the middle-aged men.

(2) **Occupation.**— Except carcinoma of the scrotal skin, other conditions do not have a definite relation with occupation. The former condition is often caused by frequent contact with soot (chimney sweep's cancer), tar or oil (mule spinner's cancer). The skin is exposed to these irritants for many years before a cancer develops. Varicocele often develops in men who are involved in work which requires prolonged standing (Bus conductors etc.).

(3) **History of present illness.**— *Malignant growth of the testis* often grows silently without the knowledge of the patient and in fact he may present a lump in the epigastric or umbilical region due to secondary deposits in the lymph nodes. A history of trauma followed immediately by a swelling is the usual history of a *haematocele*, which maintains this size for a long time. In *torsion of the testis* an exciting cause is almost always present like straining at stool, lifting a heavy weight or coitus. This is due to violent contraction of the spirally attached cremaster muscle, which favours rotation of the testis around a vertical axis. *Acute epididymo-orchitis* begins with an ache in the groin and slight rise of temperature. This is followed by severe pain, a considerable rise of temperature with redness and swelling of the scrotum. In *filariasis* periodic attacks of fever, pain and swelling of the spermatic cord and scrotum are the main features. In *tuberculous epididymitis* a slight ache or a trivial injury call the patient's attention towards the testis. Injury to the bulb of the urethra or bursting of a periurethral abscess — a complication of gonococcal stricture is the usual history of *extravasation of urine*. In *gummatous orchitis* a trivial injury calls the patient's attention towards the already diseased testis.

LOCAL EXAMINATION

INSPECTION.—

1. **Skin and subcutaneous tissue.**— The skin of the scrotum is usually wrinkled and

freely mobile over the testis. It becomes red and oedematous in case of *acute epididymo-orchitis*.

In *hydrocele* the skin will be tense, so the normal rugosity of the skin will be lost and subcutaneous veins will be prominent. Normal rugosity of the skin will also be lost in presence of underlying pathology such as tuberculous epididy-mitis, gummatous orchitis, teratoma and seminoma of the testis, in an otherwise normal size scrotum.



Fig.40.1.— Multiple sebaceous cysts of the scrotum.

Multiple sebaceous cysts are not uncommon in scrotal skin (see Figs. 40.1 & 40.2). Their features will be similar to sebaceous cyst anywhere in the body (See Page 56).

Carcinomatous ulcers may occur anywhere in the scrotum but the industrial cancers are common in the cleft between the scrotum and the thigh. These ulcers are small and circular with everted edge. The floor is covered with yellowish-grey infected necrotic tissue. Ulcers usually discharge offensive, purulent or serosanguineous fluid.

It must be remembered that *gummatous ulcer* of the scrotum resulting from extension of a gumma of the testis lies always on the *anterior aspect of the scrotum*. *Tuberculous ulcer* resulting from tuberculous epididymitis is always seen on the *posterior aspect of the scrotum*. These positions are reversed if the testis is anteverted. In severe infection the testis may protrude through the scrotum and appear as a granulating mass, which is known as *hernia testis*. Rarely the patient may present with *gangrene of the scrotum* for which no cause can be found out. This is known as *Fournier's gangrene (idiopathic gangrene)*. If there are multiple sinuses one should suspect *'Watering can' perineum*.

One must remember that *oedema* of the scrotum and penis may occur in medical conditions like nephritis, heart failure etc. The surgical causes are



Fig.40.2.— Multiple sebaceous cysts of the scrotum.

cellulitis, filariasis, blocking of lymph vessels by cancer cells or following block dissection of inguinal lymph nodes and extravasation of urine. In case of ***extravasation of urine*** look at the perineum for evidence of injury or presence of periurethral abscess which bursts spontaneously to allow the urine to extravasate. A few cases of cellulitis of scrotum is misdiagnosed as suppurated hydrocele.



Fig.40.3.— Extravasation of Urine.

Thickening of the skin and subcutaneous tissues of the scrotum may be so enormous that the scrotum assumes the size of a watermelon (***elephantiasis of the scrotum***), the penis becomes buried in the scrotal swelling. The skin and subcutaneous tissues of the penis may be similarly thickened to produce the typical ***'Ram's Horn' penis*** in filariasis. Another manifestation of filariasis is ***lymph scrotum*** in which the skin of the scrotum shows excessive rugosity with vesicles containing fluid (lymph). Rupture of these vesicles from friction will lead to profuse exudation of lymph (lymphorrhagia).

2. **Swelling.**— Slight swelling of the scrotum is evident by loss of normal rugosity of the scrotum. This is seen in any infection of testis and epididymis. Other conditions like cysts of the epididymis, spermatocele etc. do not produce obvious swelling on inspection. Hydrocele may bring forth various degrees of



Fig.40.4.— Elephantiasis of the scrotum. Note that the penis is buried in the scrotal swelling.

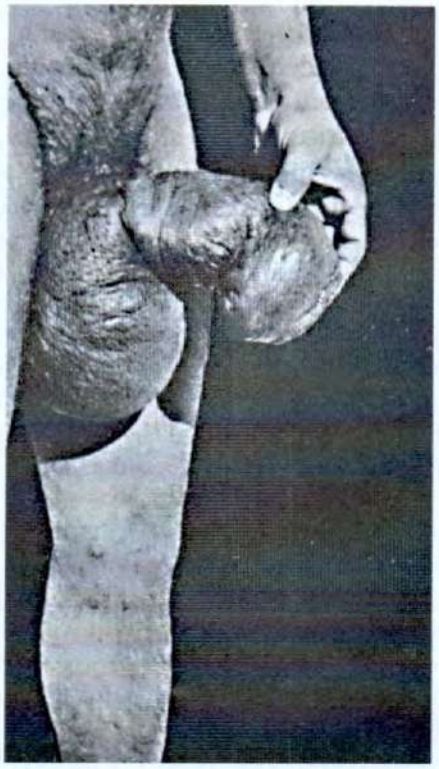

Fig.40.5.— Elephantiasis of the scrotum with 'Ram's Horn' penis.

swelling of the scrotum — small to very big so as to hang up to knee level. A peculiar constriction is often found around the swelling. If the hydrocele is tense it tends to stand out (forward projection).

Note the size, shape and extent of the swelling. Does it extend up along the spermatic cord to the groin?

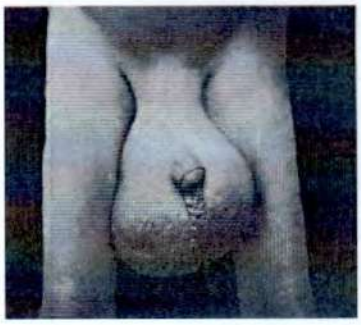

Fig.40.6.— Another case of elephantiasis of scrotum.

3. **Impulse on coughing.**— Many a time hydrocele is associated with hernia — a bubonocele or a complete inguinal hernia. Hernia shows impulse on coughing. So this part of examination cannot be dispensed with.



Fig.40.7.— Lymph scrotum with vesicles.

PALPATION.— *That the swelling is purely scrotal is confirmed by getting above the swelling.*

1. **Skin.**— If there is an ulcer, palpate it thoroughly as described in Chapter 4. ***A carcinomatous ulcer*** of the scrotum is diagnosed by yellowishgrey slough on the floor, hard base and everted margin. In the early stage the ulcer is freely mobile, but if the malignant ulcer becomes tethered to the underlying testis, it becomes fixed and moves with the testis. At this stage it is difficult to decide whether the lesion is a primary skin cancer or a testicular tumour ulcerating through the skin. An anteriorly placed ulcer which is fixed to the testis is probably a ***gummatous ulcer***, whereas a posteriorly placed ulcer which is fixed to the epididymis is a ***tuberculous ulcer***. The testis cannot be separated from the protruded necrotic mass in case of ***hernia testis***, but the testis can be easily separated in ***hernia of a hydrocele***. Oedema of the scrotum will 'pit on pressure'.

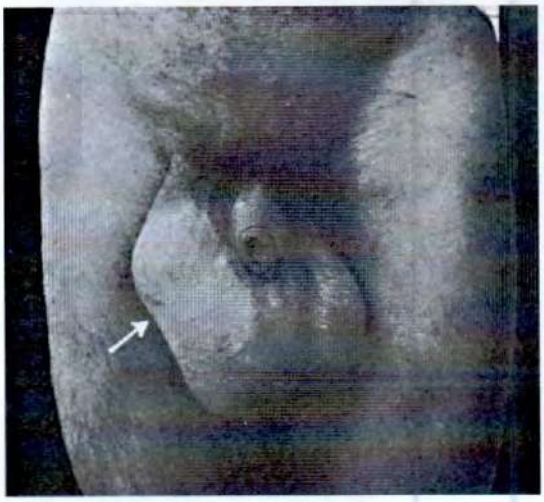

Fig.40.8.— A typical case of hydrocele of the tunica vaginalis. Note a faint constriction at the middle of the swelling shown by an arrow.

2. **Swelling.**— This is first examined in the usual line as discussed in Chapter 3, noting *temperature, tenderness, extent, size, shape, surface, margin* and *consistency*. The commonest cystic swelling is a vaginal hydrocele i.e. a collection of serous fluid in the tunica vaginalis. The two cardinal signs of a hydrocele are : fluctuation and translucency.

FLUCTUATION.— This test cannot be performed in the traditional way, as the whole scrotum is very much mobile. So this test is performed by holding the upper pole of the scrotal swelling between the thumb and the fingers of one hand to make the swelling tense

and steady, while intermittent pressure is applied at the lower pole with the thumb and the fingers of the other hand. This will push the fluid inside the tunica vaginalis upwards, the thumb and the fingers holding the upper pole of the swelling will be pushed apart from each other making this test positive.



Fig.40.9.— Showing the method of eliciting fluctuation in a case of hydrocele. See the text.

TRANSLUCENCY.— This test is best performed in darkness. A pencil torch is placed *laterally* over the swollen scrotum. A red glow will be seen throughout the scrotum indicating presence of clear fluid inside the scrotum. This can be better visualized through a roll of paper placed on the other side of the scrotum even in day light. The common mistake the students often make is to place the torch on the posterior aspect of the scrotum and the roll of paper anteriorly. The testis comes in the way of the light and this test becomes false negative. Uncomplicated hydrocele and the cyst of the epididymis are translucent but spermatocele is not translucent as the fluid it contains is not clear.



Fig.40.10.— Teratoma of the testis. Note the irregular surface of the testis.



Fig.40.11.— Showing the right method of performing the translucency test.



Fig.40.12.— Shows the wrong method of performing the translucency test. The torch is placed behind the testis which will stand in the way of the light and will make the test negative even in presence of hydrocele

REDUCIBILITY.— This is tested by raising the scrotum and compressing the swelling gently. Congenital hydrocele and a varicocele are reducible. In case of the former always examine the abdomen for ascites as congenital hydrocele is often associated with tuberculous peritonitis.

IMPULSE ON COUGHING.— Many a time scrotal swelling may be associated with a hernia, varicocele or lymph varix. The root of the scrotum is held and the patient is asked to cough. An impulse either expansile in nature (hernia or congenital hydrocele) or thrill-like (varicocele or lymph varix) may be obtained. If this test is omitted, these conditions may be missed and treatment will be incomplete.

3. **Testis.**— Examination of a scrotal swelling cannot be complete without palpation of the testis, epididymis and spermatic cord. Note its *position, size, shape, surface, consistency, weight, mobility* and *testicular sensation*. Note the *position* of the testis — whether normal, anteverted (the epididymis lies anteriorly and the body lies posteriorly), completely inverted i.e. upside down (the globus major lies inferiorly) or incompletely inverted i.e. the testis lies horizontally. These latter two positions predispose torsion of the testis. Whether the testis is normal in size, larger, or smaller than normal size? Smaller testis is an underdeveloped testis. Larger testis is often pathological — gummatous or with a tumour. Whether the *surface* is smooth or nodular? Whether the consistency is uniform or heterogenous? Note the *weight* of the organ in respect of its size. This is done by balancing the testis on the palm of the hand. The testis becomes relatively heavy in a case of neoplasm and old haematocele, but is comparatively light in a gumma of the testis. *Testicular sensation* is very important. This is a peculiar sickening sensation felt by the patient when a mild pressure is applied on the testis. In gumma and malignant tumour of the testis, the testicular sensation quickly dwindles away (more so in case of gumma). In case of malignancy one should be very gentle and should not squeeze roughly lest the malignant cells should be dislodged and thrown into the venous and lymphatic channels.



Fig.40.13.— Shows a case of seminoma of the testis.

It must be remembered that testis may be absent from the scrotum (in undescended testis, ectopic testis and retractile testis). *The testis is mainly affected in mumps, syphilis and neoplasm.*

4. **Epididymis.**— This is normally felt as a firm nodular structure attached to the posterior aspect of the testis. Its large upper part is known as head (globus major), the middle part as body and the lower as tail (globus minor). Epididymis is mainly affected in tuberculosis, filariasis and acute (both gonococcal and non-gonococcal) epididymo-orchitis. In ***tuberculosis*** the globus minor is first affected (the infection being mostly retrograde) and becomes enlarged, nodular and slightly tender. Only in blood-borne infection the globus major may be involved first. Gradually the whole epididymis

becomes enlarged, firm, craggy and slightly tender. Softening of the epididymis and formation of cold abscess in the posterior aspect of the scrotum is a great diagnostic point in favour of tuberculosis. In ***filariasis*** the epididymis also enlarges and becomes firm. ***Acute epididymo-orchitis*** is often gonococcal or B. Coli infection (from retrograde passage of urine or 'reflux epididymitis' and post-operative epididymitis following prostatectomy) or from mumps.

Remember syphilis attacks the testis and tuberculosis affects the epididymis. Later on in both these conditions the disease spreads to the other organ. In filariasis, both the testis and epididymis are simultaneously involved.

5. **Spermatic cord.**— This is best palpated at the root of the scrotum between the thumb and the index finger *simultaneously on both sides*. The vas deferens will be felt as hard whipcord slipping between the thumb and the index finger. Besides the vas, the fingers normally feel a number of strings, which are nothing but fibres of cremaster muscle. The spermatic cord is thickened and tender in any inflammatory condition of the epididymis — either acute or chronic. The vas is thickened and beaded in tuberculous epididymitis. The cord is not affected in syphilis but becomes thickened and slightly tender in filariasis. Lymph varix is also a feature of filariasis. A lymph varix feels soft and doughy whereas a varicocele feels like a 'bag of worms'. Both these conditions will yield a thrill-like impulse on coughing, but a varicocele more readily reduces than a lymph varix. In malignancy of the testis the growth may be extended upwards along the cord. In this case the cord will feel hard and nodular.



Fig.40.14.— Shows a lump in the epigastric region of the abdomen from secondary deposits in the lymph nodes from malignant growth of the testis.

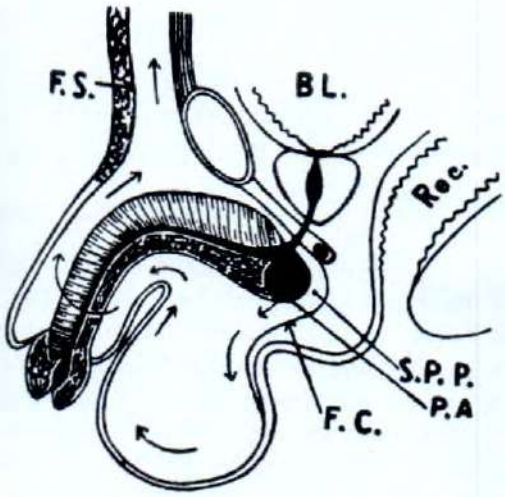

Fig.40.15.— Shows the route of spread of extravasated urine. The urine at the time of micturition escapes through the periurethral abscess (P.A.) into the superficial pouch of the perineum (S.P.P.) under the fascia of Colles (F.C.). It then spreads into the scrotum, penis and anterior abdominal wall under the fascia of Scarpa (F.S.) (for reasons see the text, page 455). A portion of the urinary bladder (BL.) and that of the rectum (Rec.) are also shown.

6. **Lymph nodes.**— It is an extremely important part of examination. The skin of the scrotum drains into the inguinal group of lymph nodes whereas the testis and epididymis drain into the pre- and para-aortic lymph nodes at the level of the origin of the testicular artery from the aorta i.e.

at the transpyloric plane. These groups of lymph nodes must be palpated. The left supraclavicular group of lymph nodes may be involved as in case of malignancies in other abdominal organs by lymphatic spread of malignant cells along the thoracic duct.

GENERAL EXAMINATION

Lungs should be examined particularly in case of tuberculous epididymo-orchitis to exclude tuberculous affection of the lung and malignancy of the testis to exclude secondary deposits in the lung.

One should look for other **syphilitic stigmas** (See page 66) in cases of gummatous orchitis.

Kidneys should be examined in cases of tuberculous epididymitis and varicocele of recent onset. In about 60% of cases there is either active tuberculosis in the renal tract or evidence of previous disease. Varicocele may be a sequel to adenocarcinoma of the kidney of the same side.

Rectal examination should always be performed in epididymo-orchitis either acute or chronic. Acute prostatitis often precedes epididymo-orchitis. The seminal vesicles are often enlarged and tender in cases of tuberculous epididymitis.

SPECIAL INVESTIGATIONS

Blood should be examined for eosinophilia and microfilaria in filariasis. Lymphocytosis and increased E.S.R. may be seen in cases of tuberculous epididymo-orchitis. Positive W.R. and Kahn tests favour the diagnosis of syphilitic orchitis.

Urine should be examined as a routine in cases of acute and chronic epididymo-orchitis. Acute epididymitis often results from retrograde passage of infected urine and presence of E. Coli, streptococcus, staphylococcus or even proteus may be detected in urine. In tuberculous epididymitis many a time one will find tubercle bacilli in the urine.

Chest X-ray is an important investigation in tuberculous epididymo-orchitis to exclude presence of pulmonary tuberculosis. This is also important to exclude secondary deposits in the lungs in cases of testicular tumours particularly the teratomas.

Intravenous pyelography should also be performed in cases of testicular tumours to know the exact positions of the kidneys so that they may be properly shielded during radiotherapy and also to detect retroperitoneal lymphatic metastasis that might have displaced the ureters or brought about deformity of the renal pelvis.

Lymphangiography is an important part of investigation to determine secondary deposits in the para-aortic lymph nodes which have not shown clinical enlargement. Its value in assessing shrinkage of enlarged nodes by radiotherapy is also great.

Aschheim-Zondek test will be positive in cases of Sertoli cell tumour (interstitial cell tumour) and human chorionic gonadotrophin in 12-hour collection of urine will be higher than normal level (100 i.u.) in chorion carcinoma (malignant teratoma trophoblastic) of the testis.

Ultrasonography is extremely helpful not only to know the position of the testis, but also to know whether they are normal or not. This investigation is helpful in hydrocele, haematocele, secondary hydrocele, torsion of testis etc.

Aspiration of a cystic swelling may clinch the diagnosis in a spermatocele or chylocele. The fluid is milky in spermatocele but in case of the cyst of the epididymis the fluid is clear. In hydrocele an amber colour fluid may be obtained whose specific gravity remains in the range of 1.022 to 1.024; it contains water, inorganic salts, cholesterol, fibrinogen and

6% of albumin. In case of secondary hydrocele from testicular tumour the fluid will be blood stained. To facilitate better palpation of testis and epididymis fluid should be aspirated out in case of secondary hydrocele.

Prostatic massage may demonstrate presence of gonococci in cases of acute gonococcal epididymo-orchitis and may demonstrate tubercle bacilli in cases of tuberculous epididymo-orchitis.

DIFFERENTIAL DIAGNOSIS

HYDROCELE.— This can be classified into congenital and acquired varieties. ***Acquired Variety*** can be further classified into *primary* (idiopathic) and *secondary* (from diseases of the testis and epididymis). In ***congenital hydrocele*** the processus vaginalis remains patent and it freely communicates with the peritoneal cavity. But usually the communicating orifice remains too small for hernia to develop. This condition is mainly diagnosed by the fact that the hydrocele gradually disappears when the patient lies down but it returns in the erect posture. The small opening prevents emptying of the hydrocele by digital pressure. In bilateral cases one should exclude ascites from tuberculous peritonitis.

Primary hydrocele is mostly seen in middle-aged men but occasionally it is seen in early childhood. This may be unilateral or bilateral. The main and only complaint is the swelling of the scrotum and that is why the patient often presents with enormous swelling. One can 'get above the swelling' if it is a pure hydrocele, the only exception is the infantile hydrocele. The colour and temperature of the overlying skin are normal. Primary hydrocele is not tender but secondary hydrocele may be tender. It is dull on percussion in contradistinction to the hernia, which is often resonant (due to presence of intestine inside the hernial sac). The fluid of the hydrocele surrounds the body of the testis making the testis impalpable.



Fig.40.16.— Congential hydrocele.



Fig.40.17.— Funicular hydrocele.



Fig.40.18.— Infantile hydrocele.



Fig.40.19.— Encysted hydrocele of the cord.



Fig.40.20.— Bilocular hydrocele 'en bissac'.



Fig.40.21.— Hydrocele of hernial sac.

If one can feel the testis separate from the scrotal swelling then the swelling is not a hydrocele but may be a cyst of the epididymis or spermatocele. In about 5% of cases inguinal hernia is associated with this condition. So one should not omit to look for impulse on coughing. The diagnosis of hydrocele is made by fluctuation and translucency tests.

Secondary hydrocele occurs secondary to acute and chronic epididymo-orchitis, syphilitic affection of the testis and occasionally in malignant tumour of the testis. A secondary hydrocele rarely attains a

big size and in majority of cases it is lax in contradistinction to the primary hydrocele which is often tense. Generally it does not interfere with the palpation of the testis and the epididymis but occasionally aspiration may be needed for better palpation.



Fig.40.22.— Ultrasonography showing a typical case of hydrocele of left scrotum. FL indicates fluid and LT. TES indicates left testis.

Different other types of hydrocele :

(a) ***Infantile hydrocele.***— In this condition the tunica and the processus vaginalis are distended upto the deep inguinal ring but do not communicate with the general peritoneal cavity. It does not necessarily appear in infants though its name suggests so.

(b) ***Funicular hydrocele.***— In this condition the funicular process is closed just above the tunica vaginalis, so it does not produce a proper scrotal swelling but an inguinal swelling will be present. It is often confused with an inguinal hernia and it is a very rare condition.

(c) ***Hydrocele of the hernial sac.***— Sometimes the neck of a hernial sac becomes closed by adhesions or plugged with omentum. This results in retention of the serous fluid secreted by the peritoneum of the hernial sac resulting in a hydrocele.

(d) ***Encysted hydrocele of the cord.***— This has been discussed in the previous chapter.

Complications of a hydrocele are :

(i) *Rupture* — either traumatic or spontaneous; (ii) Haematocele from injury to the hydrocele; (iii) Infection which may lead to suppurative hydrocele and even gradual destruction of the testis; (iv) Hernia of the hydrocele sac may result in long-standing cases when tension of the fluid within the tunica causes herniation through the dartos muscles; (v) Calcification of the sac wall and (vi) Atrophy of the testis in long-standing cases.

Haematocele.— Recent haematocele is usually the result of injury or during tapping of a hydrocele. Patient presents scrotal swelling with pain. On examination the swelling is quite tender, fluctuant but not translucent. *Old haematocele* may result from slow haemorrhage into the tunica vaginalis. This may be a painless condition which gives more confusion to the diagnosis. In majority of cases a history of trauma cannot be elicited. Thus this condition simulates testicular tumour in many respect. No history of gradual enlargement of the swelling, presence of testicular sensation (this is always absent in testicular tumours) and absence of metastasis favours the diagnosis of this condition.

Pyelocele (suppurated hydrocele).— This is a sequel of infection in the hydrocele sac. This condition should be differentiated from cellulitis of the scrotal wall. Pressure on the hydrocele through a comparatively healthy area will elicit tenderness in the cases of suppurated hydrocele but not in the case of cellulitis.

ACUTE EPIDIDYMO-ORCHITIS.— Infection usually starts in the epididymis and may gradually spread to the body of the testis giving the name epididymo-orchitis. It is actually a retrograde infection secondary to the infection of the urethra, prostate and seminal vesicles which spreads via the lumen of the vas deferens. Blood-borne infection, though rare, affects the globus major first. Patient presents with severe pain

and swelling of the testis. The scrotal wall becomes red and oedematous. Later on epididymis may become soften and adherent to the scrotal wall. Causative organism is usually gonococcus (following gonococcal urethritis and diagnosed by finding gonococci in the discharge collected by prostatic massage), E. Coli, streptococcus, staphylococcus or proteus (following retrograde passage of infected urine, following catheterisation, prostatectomy or cystitis).

DIAGRAMMATIC REPRESENTATIONS OF SCROTAL SWELLINGS



Fig.40.23.— Hydrocele or haematocele.



Fig.40.24.— Hernia testis.



Fig.40.25.— Orchitis or gumma of the testis.



Fig.40.26.— Acute epididymo-orchitis.



Fig.40.27.— Filaria epididymo-orchitis.



Fig.40.28.— Tuberculous epididymitis.



Fig.40.29.— Tumour of the testis



Fig.40.30.— Cysts of the epididymis.



Fig.40.31.— Spermatocele



Fig.40.32.— Cyst of hydatid of Morgagni.



Fig.40.33.— Varicocele or lymph varix.



Fig.40.34.— Torsion of the spermatic cord.

TUBERCULOUS EPIDIDYMO-ORCHITIS.— This also results from retrograde spread of infection from seminal vesicle via vas deferens. Blood-borne infection, though rare, will affect the globus major first. Slight aching is the only complaint of the patient and it does not attract attention of the patient till it is involved in a trivial injury. On examination, normal rugosity of the scrotal skin is lost and there is some restriction in the mobility of the testis. Slightly tender, indurated and nodular globus minor and later on the body of the epididymis can be detected. Gradually the whole epididymis becomes thickened and it is felt as firm, craggy and tender nodules. The nodules gradually soften and cold abscess develops in the posterior aspect of the testis. This may adhere to the skin and burst out discharging thin pus, thus develops the tuberculous sinus on the posterior aspect of the scrotum. It must be remembered that in case of anteverted testis these changes will be seen on the anterior aspect. In the spermatic cord, the vas deferens may be thickened and beaded due to submucous tubercles. In untreated cases for long time the contralateral epididymis may be diseased. In 30% of cases secondary hydrocele may be present. On rectal examination, the seminal vesicles may be thickened and tender, the prostate may also be slightly irregular and tender. A thorough investigation of the urinary system is a must as no less than 60% of cases show presence of active lesion in the renal tract or evidence of previous disease. Chest X-ray may show evidence of tuberculosis in about ½ of the cases. Culture of semen may be performed to detect presence of tubercle bacilli.

SYPHILITIC ORCHITIS.— Three types of late manifestations may be seen involving the testis in syphilis. These are :— (i) *Bilateral orchitis* — mostly seen in congenital syphilis. (ii) *Interstitial fibrosis* — is a symptomless and bilateral affection in which there is gradual destruction of the seminiferous tubules. The testes are not enlarged but there will be loss of testicular sensation. (iii) *Gumma* — is the most common of these three varieties. It is always unilateral. The body of the testis slowly enlarges. It is a painless condition. The testis becomes hard with loss of testicular sensation. Secondary hydrocele is almost always present. Later on the testis becomes soften anteriorly involving the scrotal wall and ultimately a gummatous ulcer forms. It is often very difficult in the early stage to differentiate it from a testicular tumour. A search should be made for other syphilitic stigmas, but a history of previous exposure, development of hard chancre and later on generalised involvement of lymph nodes (particularly the epitrochlear and occipital groups) may clinch the diagnosis. Positive serological tests of the serum are confirmatory.

SUBACUTE EPIDIDYMO-ORCHITIS (FILARIAL).— In filariasis epididymo-orchitis is quite common and is of subacute nature. It usually affects the globus major of the epididymis. The epididymis feels swollen, firmer and slightly tender. The digital fossa between the testis and the epididymis on the lateral aspect is obliterated with inflammatory adhesions. Gradually the testis is involved. It becomes enlarged, firm, slightly tender and loses to certain extent testicular sensation. Secondary hydrocele is not uncommon. Differentiation from tuberculous epididymitis is made by presence of a history of periodic fever, absence of 'craggy' epididymis leading to softening, formation of cold abscess and sinus; absence of involvement of the seminal vesicles on rectal examination, presence of eosinophilia and demonstration of microfilariae in the peripheral blood.

LYMPH VARIX.— This is nothing but dilatation of the lymph vessels of the spermatic cord. This is a characteristic feature of filariasis. So it is often associated with filarial fever which has a periodicity. The onset is sudden and is ushered in with chill and rigor. The temperature may rise to 103°-104°. The features with which this condition may be differentiated from malarial fever is by simultaneous attack of tenderness and swelling of the spermatic cord. The spermatic cord gives rise to multilocular elongated cystic swelling, which can be designated as 'diffuse hydrocele of the cord'.

LYMPH SCROTUM.— This term is applied to the condition of dilatation and tortuosity of the cutaneous lymphatics of the scrotum. Excessive rugosity and presence of vesicles are noticed in the skin of the scrotum. The vesicles may be of different sizes containing clear or slightly turbid fluid. Rupture of vesicles from friction may lead to exudation of lymph (lymphorrhagia). Secondary infection is the most important and frequent complication. In absence of infection the skin of the scrotum remains thickened but soft. Later on gradual fibrosis will give rise to elephantiasis.

CHYLOCELE.— Presence of chylous fluid in the tunica vaginalis causes this condition. This condition may be suspected when a case of hydrocele presents with a periodic history of fever and a negative translucency test. The fluid may contain microfilaria.

ELEPHANTIASIS OF THE SCROTUM.— It is a very common manifestation of filariasis. Lymphatic obstruction and later on fibrosis in the lymph-logged tissue will cause this condition. The disease comes through stages viz. filarial fever, lymphangitis, lymph stagnation and finally elephantiasis. So in the early stage the part becomes swollen and oedematous, pitting on pressure, but later on when there is excessive growth of fibrous tissue it becomes non-yielding and firm. The lymph provides suitable nourishment for happy growth of the fibroblasts. The thickening commences at the most dependent part of the scrotum and gradually extends upwards. So the thickening is maximum at the bottom and minimum at the root. On section, the hypertrophied skin forms the outermost layer, under which is the dense fibrotic layer, deep to it is a layer of gelatinous lymph-logged blubbery tissue and deep to it is the hydrocele with the testis. This testis may be atrophied due to lack of nutrition and pressure.

EXTRAVASATION OF URINE.— It may occur (i) from ruptured urethra if the patient tries to pass

urine after such injury or (ii) from bursting of periurethral abscess resulting from stricture of the urethra. This condition means urine has come out from its normal path. The knowledge of spread of extravasation of urine is essential in understanding the clinical picture of this condition.The bulbous urethra is the commonest site of ruptured urethra, similarly it is the commonest site of periurethral abscess following stricture of urethra. So extravasation of urine commonly occurs from this part of the urethra. The urine first collects in the superficial pouch of the perineum. This pouch is closed above by inferior fascia of the urogenital diaphragm (perineal membrane), closed below by fascia of Colles, laterally by ischiopubic rami and posteriorly by continuation of the perineal membrane with the fascia of Colles. So this pouch is open only anteriorly through which urine may come out and travel forwards in the subcutaneous tissue of the scrotum, penis and lower part of the anterior abdominal wall, lying deep to the fascia of Scarpa as it starts deep to the fascia of Colles. But students must remember that it cannot gravitate down the thigh as the fascia of Scarpa is attached to the fascia lata of the thigh a little distal to and parallel to the inguinal ligament.

The swelling due to this condition is of the nature of oedema and the water-logged condition can be easily assessed by pinching the skin of the scrotum and penis. Rise of temperature with or without rigor is expected. In neglected cases sloughing may take place with formation of urinary fistulae. But the patient may not survive upto this stage. Diagnosis is made by previous history of urethral stricture with recent development of swelling and pain indicating periurethral abscess or an injury to the bulbous part of the urethra followed by swelling of the perineum, scrotum, penis and lower part of the anterior abdominal wall.

TORSION OF THE TESTIS.— Some congenital abnormalities usually predispose to torsion of the testis and it must be remembered that the abnormality is usually bilateral so that the other side is always liable to undergo torsion. The ***abnormalities are*** (i) Inversion of testis, (ii) Full coverage of the testis with tunica vaginalis so that the testis is suspended in the tunica and (iii) Presence of a long mesorchium which separates the testis from the epididymis. Torsion does occur in an undescended testis.

Commonest incidence is between 10 to 15 years of age and it is extremely rare after 25 years of age. Sudden and agonising pain in the groin and lower abdomen is the main symptom.

This condition is notoriously difficult to diagnose with confidence, but one must keep this condition in mind whenever a patient presents with acute testicular symptoms. Sudden and agonising pain, which is quite severe occurring between the ages of 10 and 25 years, more commonly between 12 and 18 years is suspicious of a case of torsion. This condition is extremely rare after 25 years of age. The agonising pain is often referred to the groin and lower abdomen instead of being restricted to the scrotum only. Nausea and vomiting are very common associated symptoms. Past history of similar attacks which subsided spontaneously may be obtained. Straining at stool, lifting heavy weight, coitus and blow on the scrotum as the boy jumps on his bicycle are the ***exciting causes***.

On examination, the affected testis hangs higher in the scrotum. Generally a fully developed testis does not undergo torsion as its anchorage prevents torsion. The scrotal skin remains normal in early hours, but after a lapse of 6 hours or so the skin becomes red, hot and oedematous. The testis is exquisitely tender and the patient does not allow to touch. The testis is swollen and it is very difficult to differentiate the contour of the epididymis from the body of the testis.

Torsion of an undescended testis should be differentiated from a strangulated hernia. That the scrotum of that side is empty goes in favour of torsion. Greater problem is to *differentiate torsion of a testis inside the scrotum from an acute epididymo-orchitis*. One may feel the twisted spermatic cord to clinch the issue. In cases of acute epididymo-orchitis, the epididymis is initially the site of maximum swelling and tenderness and the testis remains normal; while in case of torsion, the testis occupies an elevated position and is itself tender on palpation. Moreover in case of the former the onset is less acute and may be associated with other urinary tract symptoms e.g. frequency and dysuria. If the scrotum is elevated, pain is relieved to certain extent in case of acute epididymo-orchitis, but pain will be aggravated in case of torsion. Lastly if mumps can be excluded in

case of a boy and urethritis can be excluded in case of a man, the diagnosis of the prevailing condition is torsion of the testis and not acute epididymo-orchitis.

Another condition that *mimics torsion of the testis is torsion of the testicular appendage or Morgagni's hydatid* which is a mullerian duct remnant. The symptoms are very much similar, but less severe. The diagnosis is possible if the torted appendage can be felt. Often transillumination test may help.

If the diagnosis is still in doubt it is better to explore quickly, as torsion, if not relieved immediately, will lead to death of the testis, on the other hand exploration will not do any extra damage in case of acute epididymo-orchitis.

TUMOURS OF THE TESTIS.— Though these tumours only constitute 1% of all malignant tumours in man, yet these are one of the commonest forms of malignant tumours in the young. Almost all (99%) testicular tumours are malignant. The two main varieties of testicular tumours are — (a) Seminoma (40%) — carcinoma of the seminiferous tubules and (b) Teratoma (35%) — malignancy in the rete testis from toti-potent cells. 15% of the tumours are the mixed type containing both of the above two types. Of the remaining 10%,— 6% are lymphoma, 2% are interstitial cell tumours (arising from Leydig cells and cells of Sertoli) and the 2% other tumours. Clinically it may not be possible to differentiate between seminoma from teratoma and final differentiation rests on histology.

Teratoma occurs between the ages of 20 and 30 years, whereas ***seminoma*** occurs between the ages of 30 and 50 years. The commonest presentation is a painless swelling of the testis. Duration is about a few months. Trivial injury may draw the attention of the patient towards the swelling and he often incriminates trauma to be the cause of the swelling. Dull aching or dragging pain may be experienced in the scrotum if the swelling has grown very large. Acute pain and tenderness is very rare form of presentation which is indistinguishable from acute epididymo-orchitis. General malaise, wasting and loss of appetite are also complained of but in less number of cases. Rarely this condition may present itself as abdominal pain and swelling of the legs due to secondary metastasis in the pre- and para-aortic groups of lymph nodes. It must be remembered that seminomas first metastasise by lymphatic spread and bloodborne metastasis is late; whereas in teratomas blood-borne metastasis is early.

Secondary hydrocele and infertility are very rare forms of presentation but should not be forgotten. Also remember that undescended testis is more vulnerable (about 50 times) to malignant transformation which is not reduced by late orchidopexy. Leydig cell tumours secrete male hormones and may lead to sexual precocity; whereas Sertoli cell tumours secrete female hormones and may lead to feminisation and formation of gynaecomastia.

On examination, the swelling is purely scrotal. The testis is enlarged, firm, smooth and heavy. This is more noticed in case of seminoma, but slight nodularity can be felt. In teratoma the surface is irregular or nodular. Consistency may be varying with soft bosses in between. Testicular sensation is always lost early, but one must be very gentle in finding out this sign. The spermatic cord remains normal for quite a long time. But eventually it may be thickened due to cremasteric hypertrophy and enlargement of testicular vessels, but the vas is never thickened. Rectal examination will reveal no abnormality of the prostate and seminal vesicles.

Now attention is directed towards examination for secondaries. Lymphatic metastasis will cause enlargement of the pre- and para-aortic groups of lymph nodes which are situated just above the level of the umbilicus. Liver should be palpated. Lungs should be examined including chest X-ray to exclude blood-borne metastasis there.

Investigations are done as discussed under the heading of 'Special Investigations'.

CYSTS.— Barring the cyst of an appendage of the testis, these mainly arise in connection with the epididymis.

(i) ***Cysts of the epididymis.***— These are cystic transformation of the aberrant structures like paradidymis, hydatid of Morgagni (appendix of the epididymis), the vas aberrans of Haller etc. Though congenital, yet the sufferers are usually middle-aged men. There are actually multiple cysts or multilocular cyst above and behind the body of the testis. In contradistinction to hydrocele these can be felt apart from the testis. The fluid it contains is crystal clear. These are tense, fluctuant and brilliantly translucent. But due to presence of multiple septa brilliant translucency is finely tesselated giving the appearance of a Chinese lantern. This condition may

be bilateral. If the cyst grows bigger and encroaches downwards into the scrotum, it may mimic a hydrocele, but this cyst lies behind the testis, whereas hydrocele lies in front of the testis.

(ii) ***Spermatocele***.— This is unilocular cyst situated in the head of the epididymis. The fluid inside contains spermatozoa and resembles barley water. This is a lax swelling in comparison to the previous condition. This is less translucent than the previous condition.

(iii) ***Cyst of an appendage of the testis***.— This is a very rare condition and forms a globular swelling at the superior pole of the testis. It is usually unilateral and may undergo torsion if pedunculated.



Fig.40.35.— A typical case of Fournier's gangrene of Scrotum.

FOURNIER'S GANGRENE (Idiopathic gangrene of the scrotum).— It is a rare condition in which (i) there is sudden appearance of scrotal inflammation in an apparently healthy individual; (ii) There is rapid onset of gangrene and (iii) in majority of cases no cause can be found out. This condition is considered to be an infective gangrene in which fulminating inflammation causes obliterative arteritis of the subcutaneous tissue and hence the gangrene. Minor injuries in the perineum often start the disease e.g. bruise and scratch in the perineum, injection of anal fissure or opening of a periurethral abscess. The causative organisms are haemolytic streptococci, staphylococci, E. Coli, Cl. Welchii etc. Clinical features are sudden pain in the scrotum with pyrexia, prostration and pallor. If not treated properly the whole scrotum is sloughed off leaving the testes hanging exposed. Gradually gangrene spreads to the neighbouring tissues as superficial extravasation of urine.

SEBACEOUS CYSTS OF THE SCROTUM (Fig.40.1 & Fig.40.2).— Sebaceous cysts are commonly seen in the scrotum after puberty till middle-age. Multiple cysts are quite common of different sizes. Hardly any of these cysts attain very large size.

CARCINOMA OF SCROTUM.— This disease has a distinct relation with occupation. Previously this condition used to occur among chimney sweepers where soot was the carcinogen. Later on this condition occurred from soakage of the trousers of mule spinners with lubricating oil used in cotton industry. Now this lubricating oil has been made free from impurities and is no more causing this disease. Till today a few among tar and shale oil workers are affected, though majority are of unknown aetiology. The growth starts as a painless nodule or ulcer. On examination hard feel of the nodule or base of the ulcer is of significance. Inguinal lymph nodes are almost always enlarged, discrete and hard.

THE PENIS

HISTORY.—

Age.— Congenital lesions e.g. phimosis, hypospadias, epispadias are commonly seen in children. Hunterian chancre, soft chancre, lymphogranuloma inguinale, granuloma inguinale are seen in adults. Carcinoma of penis is a disease of old age.

Race.— Muslims and Jews are almost immune to carcinoma of penis due to their religious custom of early circumcision.

COMPLAINTS.— Mother may complain that her son is not passing water satisfactorily. Either it is coming out in thin stream or falls by drops. It may be due to a pin-hole meatus or more often phimosis. If the complaint is that the fore-skin is ballooning during micturition, it is purely due to phimosis. ***Phimosis*** is a condition in which the prepucial opening is narrow and cannot be retracted over the glans penis. It must be remembered that the adults may present with such complaints. Long-standing chronic balanoposthitis may lead to cicarticial contraction and hence develops phimosis. Similarly sub-prepucial carcinoma may lead to phimosis. Meatal ulcer may lead to acquired *pin-hole meatus.* Patient may complain with excruciating pain and swelling of the glans penis, with the fore-skin fastened tight round the corona glandis. This is ***paraphimosis***. Sometimes the patients present with **ulcers** in the penis. Enquire about any history of exposure. If the ulcer has developed after four days of exposure it is a soft sore (Chancroid). If it has developed after four weeks of exposure it is a hard chancre (Hunterian chancre). There may be a fleeting, painless papule or ulcer often unnoticed by the patient in case of lymphogranuloma inguinale. In case of granuloma inguinale a painless vesicle or indurated papule develops in penis after 1 to 4 weeks of exposure. This erodes to form a slowly extending ulcer with red granulomatous floor. If there is no history of exposure one should keep in mind the possibility of



Fig.40.36.— Carcinoma of the penis with secondary involvement of the inguninal lymph nodes (fungating).



Fig.40.37.—Epispadias.



Fig.40.38.—Coronal hypospadias.



Fig.40.39.— A case of coronal hypospadias.

cancer. If the patient complains of **discharge**, enquire particularly where is the discharge coming from — the urethra or the prepucial sac. In balanoposthitis, carcinoma etc. discharge may come from the prepucial sac. Even if the discharge is coming from the urethra, note particularly that it is not coming from the infected Morgagni's follicles which open by a pair of mouths just behind the lips of the external urethral meatus.



A case of coronal hypospadias.

If the patient complains of **pain** in the penis, note its relation with micturition. *Pain during micturition* is complained of in acute urethritis, acute prostatitis, prostatic abscess and passage of a calculus. *Pain following micturition* is complained of in vesical calculus, cystitis and diverticulum of the bladder. *Pain independent of micturition* is come across in balanoposthitis, herpes, advanced carcinoma of penis etc.

LOCAL EXAMINATION

Examine systematically (a) the prepuce, (b) the external urethral meatus, (c) the glans penis and (d) the body of the penis.

Retract the prepuce over the glans upto the corona. Failure to do so is due to ***phimosis***. When the prepuce becomes tight round the corona with swelling of the glans, the condition is known as ***paraphimosis***.

Look for presence of *pin-hole meatus*. This is mainly a congenital deformity but acquired type may be seen following a meatal ulcer. **An ulcer** may be due to either Hunterian chancre or chancroid or granulomatous inguinale or an epithelioma. A *Hunterian chancre* is painless with the welldefined edge and an indurated base. This feels like a button. *Chancroid* (soft sores) are multiple, painful ulcers with ill-defined and oedematous margins discharging pus. *Epithelioma* may be anywhere on the skin of the prepuce or the glans penis. Two types are usually seen — a papilliferous tumour (cauliflower-like growth) and an ulcer with raised and everted edge and necrotic floor. A few **premalignant conditions** may be seen — (i) *Leukoplakia* (features are same as those more popularly known in the tongue). (ii) *Paget's disease* — as chronic red eczema on the



Fig.40.40.— Hypospadias—there is a distal penile opening.

glans or inside the prepuce. (iii) *Erythroplasia of Querat* — as dark red flat indurated patch on the glans or inner surface of the prepuce. This is also seen on vulva and in the mouth.

The **swellings** on the glans may be an epithelioma, erythroplasia of Querat and condylomata acuminata (venereal warts). Venereal warts are multiple papillomatous growths which are moist and discharge bad smelling serous fluid. They are mostly placed in the region of coronal sulcus. These are the most common benign neoplasm of the penis.

Balanitis is an infection of the glans penis and *posthitis* is infection of the inner surface of the prepuce. The patient complains of a bad smelling creamy discharge from beneath the prepuce.

Epispadias is a condition in which the urethral opening is on the dorsal surface of the penis. But more common *hypospadias* is a condition in which the urethra opens on the ventral surface of the penis. According to the position of the opening it is classified into a glandular type (opening is on the glans), a penile type (opening is on the body of the penis) or the perineal type (the opening is on the perineum with bifid scrotum).

Watch the patient passing urine.— In case of phimosis the prepuce will balloon out or a very fine stream of urine can be seen. Both indicate phimosis which needs circumcision.

Body of the penis is palpated with index finger and thumb of both hands systematically. The deep part of the body is palpated through the scrotum and perineum.



Fig.40.41.— Hypospadias — there is a proximal penile opening (Penile type).

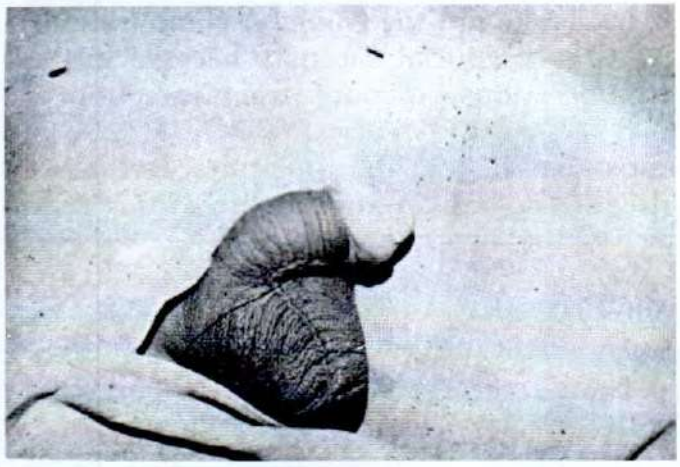

Fig.40.42.— Paraphimosis.

If urethritis is suspected the penis can be milked with the thumb and the index finger to express some purulent discharge.

Examination of the draining lymph nodes.— Carcinoma of the penis mainly drains into the inguinal group of lymph nodes. But it must be remembered that enlargement of these lymph nodes do not always signify the presence of metastasis. In fact, in about 50% of cases swelling of these lymph nodes is due to inflammation rather than lymphatic metastasis. Involvement of the urethra by inflammation or neoplasm will lead to enlargement of lymph nodes of the iliac group.

DIFFERENTIAL DIAGNOSIS

Hypospadias.— This is the most common congenital malformation of the urethra. The external urinary meatus is not situated at the tip of the penis, but at some point on the under-surface of the penis or in the perineum. According to its location, hypospadias can be of the following types — (a) *Glandular* type in which the meatus is situated on the under-surface of the glans generally at a point where the frenum (which is absent) is normally attached. A blind depression marks the normal site of the meatus. This is the most common variety. (b) *Coronal* type, in which the meatus is at the corona. (c) *Penile* type, in which the meatus is situated at some point on the under-surface of the body of the penis between the glans and the penoscrotal junction. (d) *Penoscrotal* type, in which the meatus is at the penoscrotal junction. (e) *Perineal* type, in which the meatus is at the perineum about 3 cm in front of the anus. This is the least common. The scrotum is cleft. The testes are either undescended or if descended are very small. In all varieties the penis is curved downwards (chordee) (except the glandular type) due to presence of fibrous tissue from the meatus to the tip of the penis.

Epispadias.— This is quite rare and the external urinary meatus in this condition opens on the dorsal surface of the penis. Three varieties are usually seen — (a) *Glandular* type, where the meatus is situated on the dorsal aspect of the glans. (b) *Penile* type, in which the meatus is situated on the dorsal aspect of the body of the penis. The penis curves upward. (c) *Total* type, which is associated with ectopia vesicae and incontinence of urine.

Phimosis.— It is a condition in which the end of the prepuce is so narrow that it cannot be retracted over the glans upto the corona. It is a congenital abnormality. So the children are the main sufferers. It may or may not be associated with pin-hole meatus. It leads to difficulty in micturition and ballooning of the prepuce. Recurrent balanoposthitis causing pain and purulent discharge are the common complications. The smegma in the prepucial sac may become inspissated to form concretions. Urinary tract infection is not common.



Fig.40.43.— A typical case of para-phimosis.

Phimosis may develop in adults (*acquired type*) from long standing balanoposthitis or carcinoma occurring on the undersurface of the prepuce. So in case of phimosis in the adult it is better to make a dorsal slit for proper examination inside.

Paraphimosis.— When a narrow prepuce is forcibly retracted behind the corona it may stick tight in this position. It impedes venous blood flow and causes oedema and congestion of the glans which in turn makes reduction of the prepuce more difficult. The patient presents with swelling and pain of the glans penis. It needs immediate surgical intervention.

Balanoposthitis.— This is infection of the glans penis and the prepucial sac. The patient complains of obnoxious smell and creamy discharge from beneath the prepuce. When the foreskin is retracted one will find red and oedematous inner surface of the prepuce. If the retraction is not possible a dorsal slit or circumcision must be performed. Patient usually complains of itching, pain or discharge from the subprepucial space. If the prepuce can be retracted, the glans and inside of the prepuce should be examined properly. The inguinal lymph nodes should be palpated. A thorough search for the cause of balanoposthitis should be made. The *main causes are* — (i) Candida albicans is common in sexually active persons and diabetes. Glans penis is itching with red patches. Prepuce becomes whitish with longitudinal fissuring particularly at the tip. (ii) Herpes genitalis — often involves glans, foreskin and even the shaft of penis. The initial itchy vesicles are soon replaced by shallow, painful erosions. There may be painful inguinal lymphadenopathy. (iii) Fixed drug

eruptions are painless discolouration of the glans which develop from certain drug hypersensitivity. (iv) Poor hygiene is a very common cause of this condition. (v) Diabetes which makes the patient more susceptible to infection, may cause this condition. (vi) Syphilitic chancre and carcinoma often associated with this condition and clinician must be careful about this. This condition should not be ignored as a sub-prepucial carcinoma may be the cause of this condition.



Fig.40.44.— A typical Hunterian chancre at the coronal sinus.

Infection of Morgagni's follicles.— These are a pair of follicles that open laterally just behind the lips of the external urethral meatus. Openings are not usually seen except when the follicles become infected often as a complication of urethritis, when pus will be seen extruding through the prominent openings.

Infection of Tyson's glands.— These are a pair of sebaceous glands which secrete smegma. These glands are situated on either side of frenum and the ducts open in the prepucial sac and not in the urethra. These glands become infected as complication of gonococcal urethritis and give rise to firm, tender swellings on the undersurface of the glans just lateral to the frenum.

Meatal ulcer.— This occurs from abrasion to delicate unprotected mucosa by napkins following recent circumcision. It is characterised by alternating open ulceration which may slightly bleed to stain the undercloth and scabbing of the meatus leading to narrowing of the external meatus. In fact anteroposterior diameter of the external meatus is shortened. If untreated it may lead to pin-hole meatus which causes retention of urine to varying extent.

Syphilitic chancre (Hunterian chancre).— It is a sore or an ulcer on the prepuce or on the glans. It occurs in the primary stage of syphilis and the incubation period is 3-4 weeks from the exposure. It is a painless ulcer with well-defined margin raised above the surface with indurated base. It feels like a button. It must be remembered that chancre on genitalia is painless but on other sites such as fingers and lips they tend to be painful. Spirochaeta pallida can be demonstrated in the serous discharge on dark-ground illumination. The inguinal nodes are invariably enlarged. They feel rubbery, discrete, freely mobile and are not tender. The second stage of syphilis will begin 4-6 weeks after the appearance of the chancre.

Chancroid (Soft sores).— These are multiple painful sores affecting the glans and prepuce. They have ill-defined, inflammatory and oedematous margins. Soft sores are caused by Ducrey's bacilli and the incubation period is about 3-5 days. The inguinal lymph nodes are invariably enlarged and they show tendency towards suppuration.

Premalignant conditions.— (i) Leukoplakia, (ii) Paget's disease and (iii) Erythroplasia of Querat have been discussed under the heading of 'Local Examination'.

Lymphogranuloma inguinale.— It is a venereal disease and transmitted by sexual intercourse, but accidental infection has occurred (e.g. handling the primary or the secondary lesion inadvertently). The infection is caused by a virus of the psittacosis lymphogranuloma inguinale group. The ***primary lesion*** is often ignored. These are sores in the anterior urethra (penis in case of male). The sores look like vesicles which are painless. These gradually disappear and the secondary lesion starts. The patients mainly present with the ***secondary lesions***, the incubation period of which varies from three to six weeks after exposure. The lymph nodes in one or both the groins are enlarged. Pariadenitis occurs leading to matting of the lymph nodes. The overlying skin gradually becomes red. The matted lymph nodes tend to suppurate and gradually become superficial. Ulti-

mately thick yellowish-white pus is discharged. The resulting sinus or sinuses persist for months or years. In case of females an additional complication arises if the primary lesion affects the posterior vaginal wall or cervix. In these cases para-rectal lymph nodes enlarge and suppurate. Due to intense para-rectal inflammation fibrosis of the rectal wall follows with the formation of a stricture of rectum. Due to lymphatic obstruction there



Fig.40.45.— Palpating the inguinal lymph nodes in a case of carcinoma of the penis.



Fig.40.46.— Palpating the external iliac lymph nodes. The thigh is flexed to relax the abdominal muscles.

may be occasional elephantiasis of the scrotum and penis as well as the vulva. Ischiorectal abscess, rectovaginal fistulae and perianal abscess may develop in females consequent upon intense para-rectal inflammation. Complement fixation test and biopsy of the affected lymph nodes confirm the diagnosis. The Frei test is also confirmatory. 0.1 ml of sterile pus obtained from an unruptured bubo of a patient suffering from this disease is injected intradermally. If a red papule of at least 6 mm. diameter appears in 48 hours the test is positive and the patient is suffering from this condition.

Granuloma inguinale.— In contradistinction to the previous condition granuloma inguinale mainly manifests itself in the primary lesion. This is a vesicle surrounded by an area of erythema and induration. Gradually the overlying epithelium disintegrates and ulcer develops. These ulcers may be seen in the genital, inguinal and perianal regions. Pain is conspicuous by its absence. *The lymph nodes are not involved.* This condition is caused by Donovan body, which is seen as a Gram-negative rod in the cytoplasm of mononuclear tissue cells.

Elephantiasis of the penis.— Penis may be involved separately or alongwith the scrotum in filariasis. The subcutaneous tissue of the penis may be affected similar to the scrotum. Sometimes penis may be enormously thickened and distorted owing to unequal contraction of hypertrophied fibrous tissue and fascia around the penis. Such a distorted and swollen organ is called the 'Ram's horn penis'. At other times the penis may be completely buried under the enormously distended scrotum. Its orifice is then indicated by hypertrophied prepuce, from where a long channel goes upwards to meet the glans penis.

Peyronie's disease.— This is due to indurated plaque formed at the dorsal aspect of one corpus cavernosum. The penis on erection becomes curved and painful. Probably trauma of unknown nature is the cause of this condition. Majority of the patients are over forty years of age.

Papillomas (Venereal warts).— This is the commonest benign growth of the penis. It may occur in the uncircumcised as well as in the circumcised. These are actually condylomata acuminata. These appear on the glans, coronal sulcus, frenulum and also inside the urethral meatus. So these occur mainly in areas subject to trauma during intercourse. These are caused by human papilloma virus which are almost invariably sexually transmitted. These are moist, multiple papillomas without induration and discharges thin serous fluid. These

warts may progress to intraepithelial neoplasia and later to invasive carcinoma.

Carcinoma of the penis.— A few pathological facts are to be remembered in this respect. *Firstly* circumcision, if correctly performed soon after birth, confers almost total immunity against this disease. But circumcision done in early infancy does not provide the same degree of immunity. *Secondly*, a few conditions ***predispose*** to the development of cancer. These are chronic balanoposthitis, leukoplakia, papillomas, Paget's disease and Erythroplasia of Querat. *Thirdly*, majority of the carcinomas are of squamous variety, only rarely columnar variety may develop arising from Tyson's glands (situated on either side of the frenum). *Fourthly*, the



Fig.40.47.— A case of carcinoma of penis which is gradually affecting the body of the penis and has almost eroded the prepuce.



Fig.40.48.— A case of carcinoma of penis affecting glans penis. The inguinal lymph nodes are being palpated.

earliest spread is to the lymph nodes (first to inguinal group and then to iliac group) and direct spread to the body of the penis is prevented by a fascial sheath for many months. *Lastly* this is a slow growing tumour. Though majority of the patients are above 40 years of age yet 30% of the patients are under 40 years of age. The lesion may be anywhere on the skin of the prepuce or glans penis. It is a painless condition so in an uncircumcised individual mild irritation and purulent discharge from under the prepuce are often the first symptoms. Gradually blood stained foul discharge may be noticed. At this stage the condition may be misdiagnosed as balanoposthitis. One must be clever enough to suspect this to be a case of carcinoma and a dorsal slit must be performed for proper inspection. Majority of the patients present with a lump or an ulcer. The lump is a sessile cauliflower growth with an indurated base whereas an ulcer has the same indurated base with rolled out and everted margin, the floor is formed by necrosed tissues.

The inguinal lymph nodes are often enlarged, but about half of these cases the enlargement is due to sepsis and the other half due to secondary deposits. One must palpate the iliac group of lymph nodes to exclude secondaries in these nodes. Death may occur due to bleeding from external iliac or femoral vessels from erosion by the metastatic lymph nodes.

Priapism.— This means persistent and painful erection of the penis. Most common cause is idiopathic thrombosis in the corpora cavernosa. But other causes are — sickle cell anaemia, leukaemia, secondary malignant deposit in corpora cavernosa, spinal cord injury and organic diseases of central nervous system .

INDEX

A

Abdominal tuberculosis, 512
Abdominal aorta, 528
Abdominal facies, 454
Abducent nerve, 273
Abduction injury of ankle, 211
Abductor pollicis brevis, 128
Aberration of Normal Development & Involution (ANDI), 428
Abnormal movements, 168
Abscess, 46
  cold, 46
  pyaemic, 46
  pyogenic, 46
Accessory nerve, 136, 274
Achalasia, 326
Achilles tendinitis, 143
Achondroplasia, 158
Acid, 575
Acoustic neurofibroma, 280
Acrocyanosis, 95
Acromioclavicular dislocation, 181
Actinomycosis, 330, 340, 535
Actinomycosis of the lung, 404
Acute appendicitis, 468
Acute arterial occlusion, 95
Acute cholecystitis, 470
Acute diverticulitis, 471
Acute intestinal obstruction, 474
Acute intussusception, 477
Acute lymphadenitis, 118
Acute mastitis, 426
Acute mesenteric lymphadenitis, 471
Acute non-specific lymphadenitis, 472
Acute osteomyelitis, 157
Acute osteomyelitis of spine, 306
Acute pancreatitis, 470
Acute parotitis, 359
Acute prostatitis, 588
Acute pyelonephritis, 579
Acute regional ileitis, 472
Acute retention of urine, 591
Acute salpingitis, 472
Acute suppurative arthritis, 217
Acute supraspinatus tendinitis, 227
Acute thyroiditis, 392
Acute ulcerative colitis, 472
Adamantinoma, 337
Adduction injury of ankle, 211
Adductor pollicis, 130
Adenoid cystic carcinoma, 362
Adhesion in fracture, 176
Adiadochokinesia, 275
Adolescent coxa vara, 238, 244, 246
Adson's test, 88
Ainhum, 94
Albright's disease, 161
Alkaline phosphatase, 575
Allen's test, 84
Alveolar abscess, 338
Amazia, 426
Amelanotic melanoma, 55, 326
Ameloblastoma, 337
Amoebic hepatitis, 523
Amoebic liver abscess, 473, 523
Amoebic typhlitis, 534
ANDI, 428
Aneurysm, 97
  acquired, 97
  causes of, 97
  complications of, 98
  congenital, 97
  degenerative, 97
  differential diagnosis of, 98
  dissecting, 97
  effects of, 98
  examinations of, 98
  false, 97
  fusiform, 97
  infective, 97
  saccular, 97
  symptoms of, 97
  traumatic, 97
  true, 97
Aneurysmal bone cyst, 163
Angiography, 39
  selective visceral, 506
Angionephrotomogram, 572
Ankle clonus, 275
Ankle jerk, 275
Ankylosing spondylitis, 303
Ankylosis, 222
  true, 222
  false, 222
Ano-rectal abscess, 550
Antegrade urogram, 570
Anterior compartment syndrome, 95
Anuria, 559
Aortic aneurysm, ruptured, 480
Aortic arch occlusive disease, 95
Aortic dissecting aneurysm, 480
Aortic embolism, 95, 96
Ape-thumb, 124
Apical group of axillary lymph nodes, 422
Apical space infection, 312
Apley's grinding test, 206
  distraction test, 206
Appendicitis, acute, 468
  chronic, 511
  in elderly, 469
  in infancy, 469
  pelvic, 469
  in pregnancy, 470
  retrocaecal, 469
Appendicular colic, 481
Appendix, 533
Areola, 415
Argyll-Robertson pupil, 216, 463
Arterial embolus, 95
Arterial thrombosis, 96
Arterial trauma, 96
Arterial ulcer, 69, 73
Arteriography, 89
  of bone pathology, 155
  direct arterial, 90
  retrograde percutaneous, 89
  selective, 89
Arteriovenous aneurysm, 98
Arthritis, 217
  gonococcal, 218
  pneumococcal, 218
  rheumatoid, 219
  suppurative, 217
  tuberculous, 218
Arthritis of shoulder, 226
  of elbow, 230
Arthroscopy, 172
Aschheim-Zondek test, 625
Aspiration, 422
Aspiration pneumonia, 408
Atelectasis of lung, 408
  lobar, 409
  lobular, 409
  massive, 409
  segmental, 409
Atresia of oesophagus, 437
Attitude, 5
Auditory nerve, 274
Auriculotemporal syndrome, 359
Auscultation of abdomen, 462
Autoimmune thyroiditis, 392
Avascular necrosis, 175
Axillary group of lymph nodes, 419
Axillary nerve, 126
Axonotmesis, 134

B

Backache, 307
Balanitis, 536
Balanoposthitis, 635
Baldwing's test, 459
Ballance's sign, 446
Ballottable, 520
Ballottement, 562
Barium enema X-ray, 465, 498
  of rectal pathologies, 548
Barium meal X-ray, 495
Barlow's test, 241
Basal cell carcinoma, 54
Basal cell papilloma, 60
Basal secretion, 494
Battle's sign, 261
Bazin's ulcer, 74
Bed-shaking test, 457
Benign hypertrophy of prostate, 587
Benign stricture of oesophagus, 439
Bennett's fracture-dislocation, 195
Biceps brachii, rupture of, 144
Biceps jerk, 276
Bicipitoradial bursitis, 231
Bidigital palpation of parotid duct, 356
Bifid nose, 329
Biliary colic, 480

Bilateral hydronephrosis, 577
Bimanual examination of pelvis, 546
Biopsy, 39
Biopsy of bone pathology, 156
Biopsy of breast, 425
Biopsy of lymph nodes, 115
Bladder diverticulum, 584
Bladder tumours, 586
Bleeding from nose, ear or mouth, 260
Bleeding per anum, 539, 553
Blood vessel injury in fracture, 173
Blue-domed cyst of Blood good, 429
Boas's sign, 457
Boil, 46
Bolus obstruction, 479
Bone cyst, 157, 161
Bone scan, 155, 171, 425
Bony irregularity, 168
Bony swelling, classification of, 156
Bony tenderness, 168
Bowel habit, 454, 484, 540
Bowen's disease, 60
Brachial neuralgia, 228
Brachial plexus, 135
Brachioradialis, 126
Brain Scan, 264, 279
Brachial group of lymph nodes, 420
Branchial cyst, 364, 371
Branchial fistula, 371
Branchiogenic carcinoma, 371
Branham's sign, 84
Breast carcinoma, 430
Breast sarcoma, 433
Brittle bone, 159
Broad ligament cyst, 537
Brodie-Trendelenburg test, 102
Brodie's abscess, 158
Bronchiectasis, 408
Bronchoscopy, 406
Bryant's test, 180
Bryant's triangle, 199
Buerger's angle, 82
Buerger's disease, 92
Buerger's test, 82
Build, 5
Burkitt's tumour, 338
Bursitis, subdeltoid, 228
Butcher's wart, 316

C

Cafe au lait patch, 49
Calcanean spur, 326
Calcaneum fracture, 211
Calculus of submandibular salivary gland, 362
Callosity, 59
Callus formation, 171
Cancer en cuirasse, 415, 430
Cancrum oris, 94, 330, 344, 350
Capillary filling time, 82
Capillary refilling, 83
Carbuncle, 46
Carcinoma of bladder, 586
Carcinoma of breast, 430
Carcinoma of caecum, 534
Carcinoma of colon, 515
Carcinoma of kidney, 580
Carcinoma of lip, 350
Carcinoma of liver, 524
Carcinoma of lung, 408
Carcinoma of oesophagus, 440
Carcinoma of pancreas, 511
Carcinoma of penis, 638
Carcinoma of prostate, 588
Carcinoma of rectum, 552
Carcinoma of scrotum, 631
Carcinoma of sigmoid colon, 537
Carcinoma of stomach, 508
Carcinoma of thyroid, 391
anaplastic, 391
follicular, 391
papillary, 391
Carcinoma of tongue, 352
Cardiac tamponade, 400
Cardiospasm, 439
Carotid angiography, 264, 278
Carotid body tumour, 365, 372
Carotid occlusive disease, 95
Carpal tunnel syndrome, 144, 233
Carpopedal spasm, 395
Carrying angle, 183, 228
Cat-scratch disease, 19
Catheterisation, 572
Causalgia, 122
Cavernous haemangioma, 44
Cellulitis, 45
Central group of lymph nodes, 422
Cephal haematoma, 330
Cerebral compression, 269
Cerebral Concussion, 267
Cerebral contusion, 267
Cerebral irritation, 267
Cerebral laceration, 267
Cerebral puncture, 278
Cervical lymph nodes, 368
swellings of, 370
Cervical rib, 93, 365
Chair test, 617
Chancre, hard, 71
soft, 71
Chancroid, 636
Charcot's joint, 220
Charcot's triad, 485
Chauffeur's fracture, 193
Cheyne Stokes' respiration, 261
Chiene's test, 199
Cholangiography, intravenous, 500
Cholangiography, Percutaneous Transhepatic (PTC), 500
Cholecystitis, acute, 470
Cholecystography, oral, 498
Choledochus cyst, 510
Cholelithiasis, 510
Chondroma, 164
Chondromalacia patellae, 254
Chondromyxoid fibroma, 164
Chondrosarcoma, 165
Chronic appendicitis, 511
Chronic cholecystitis, 510
Chronic duodenal ulcer, 507
Chronic empyema, 407
Chronic gastric ulcer, 507
Chronic interstitial mastitis, 427
Chronic lymphadenitis, 118
Chronic osteomyelitis, 158
Chronic pancreatitis, 510
Chronic prostatitis, 588
Chronic retention of urine, 590
Chronic superficial glossitis, 351
Chronic supraspinatus tendinitis, 227
Chvostek-Weiss sign, 395
Chylocele, 628
Cirrhosis of liver, 525
Clasping test, 128
Claw foot, 322
Claw hand, 123
Clavicle fracture, 181
Cleft lip, 328, 342
Cleft palate, 328
Cleido-cranial dysostosis, 159
Club foot, 321
Clutton's joint, 222
Cock's peculiar tumour, 57
Codman's method, 224
Cold & warm water test, 84
Cold abscess of chest, 404, 407
Colic, 12, 480
appendicular, 481
biliary, 480
intestinal, 481
ureteric, 480
Colles' fracture, 194
Colloid goitre, 389
Colon, 492, 522
Colonoscopy, 547
Common bile duct, stone, 510
Common peroneal nerve, 130
Complication of head injury, 270
Complications of fracture, 173
Compound palmar ganglion, 233, 319
Compressibility, 31
Compression test, 398
Computed Tomography (CT Scan), 37
3D CT Scan, 38
of brain tumour, 279
for urinary case, 573
Condyloma, 58, 71, 543
Congenital abnormalities of breast, 426
Congenital arteriovenous fistula, 44
Congenital dislocation of hip, 238, 243, 246
Congenital fissure of tongue, 352
Congenital fistulae of lower lip, 329
Consistency, 28
Contour of chest, 403
Contusion of lung, 400
Cope's psoas test, 458
Corn, 59
Costoclavicular compression test, 84
compressive manoeuvre, 84
Cough, 402
Cranial tumours, 279
Crepitus, 18, 398
of bone & joint, 18, 169
subcutaneous, 19
Crile's method, 379
Crohn's disease, 512, 534
Crossed leg test, 84
Cruciate ligament injury, 208
Cullen's sign, 471
Curly toes, 323

Cushing's syndrome, 272, 280
Cyanosis, 5
Cylindroma, 331, 362
Cyst, dermoid, 42
of breast, 429
sebaceous, 56
Cystic hygroma, 51, 365, 371
Cystitis, 585
Cystocele, 604
Cyst of testis, 631
Cystogram, 571
Cystosarcoma phylloides, 429
Cystoscopy, 571
Cysts about the knee, 254
Cysts of the epididymis, 630
Cysts of mesentery, 532

D

Dactylitis, 316
Deep vein thrombosis, 106
Dercum's disease, 49
De Quervain's disease, 144, 233
De Quervain's thyroiditis, 392
Decubitus, 5
Delayed union, 174
Deltoid, 126
Dental cyst, 336
Dentigerous cyst, 336
Depth of unconsciousness, 260
Dermoid cyst, 42,
of face, 328
sublingual, 345
Desmoid tumour, 47, 531
Diabetic gangrene, 94
Diaphragmatic hernia, 401
Diaphyseal aclasis, 159
Difficulty in urination, 558
Diffuse lipoma of cord, 515
Diffuse oesophageal spasm, 439
Digital examination, 543
Digital subtraction arteriography (DSA), 573
Dinner-fork deformity, 191
Discharge from nipple, 419
Discharge from urethra, 559
Discography, 300
Disc prolapse, 306
lumbar, 306
Diseases of joint, 213
Dislocation, 173
Dislocation of elbow, 190
Dislocation of hip, 201
pathological, 248
Dislocation of shoulder, 182
recurrent, 182
of acromioclavicular joint, 181
Dislocation of spine, 286
Divarication of recti, 610
Diverticula of oesophagus, 439
Diverticulitis, 537
acute, 471
chronic, 513
Diverticulum of bladder, 584
Doppler effect, 90
Doppler ultrasonogram, 108
Dorsal position, 541
Dragstedt test, 494
Drawer sign, 207
Ducrey's chancre (sore), 71
Duct carcinoma of breast, 431
Duct papilloma, 430
Dugas' test, 180
Duodenal injury, 447
Duodenal ulcer, chronic, 507
Duodenography, hypotonic, 497
Duplex imaging, 108
Dupuytren's contracture, 145, 317
Dysphagia lusoria, 441
Dyspnoea, 402
Dysuria, 558

E

Echo-encephalography, 264, 278
scintillation, 279
Ectopia vesicae, 583
Ectopic gestation, ruptured, 479
Ectopic testis, 615
Ectrodactylism, 316
E.E.G., 264, 278
Egyptian splenomegaly, 530
Elbow dislocation, 190
Elbow tunnel syndrome, 231
Electrical responses of nerve injury, 133
Electromagnetic flowmeter, 90
Elephantiasis graecorum, 50
Elephantiasis neurofibromatosis, 50
Elephantiasis of scrotum, 619, 628, 637
Embolic gangrene, 93
Embolism, 96
Empyema, 407
acute, 407
chronic, 407
Empyema necessitatis, 404, 407
Encephalocele, 327
Encephalography, 278
Encephaloid carcinoma of breast, 431
Encysted hydrocele of cord, 613
Endometrioma, 516
Endoscopy for acute abdomen, 466
for chronic abdomen, 501
for dysphagia, 435
Enema, 466
Enterocele, 604
Enteroteratoma, 516
Ependymoma, 280
Epidermoid carcinoma, 54
Epididymis, 622
Epididymitis, 618
tuberculous, 618
Epididymo-orchitis, 618, 623
acute, 623
Epidurography, 300
Epigastric hernia, 527, 609
Epileptic fits, 259, 271
Epiplocele, 604
Epispadias, 635
Epithelioma, 54, 72
Epulis, 334, 336
Erb-Duchenne paralysis, 135
ERCP, 502
Erysipelas, 45
Erythrocyanoid ulcer, 74
Erythroplasia of Querat, 634, 638
Ewing's tumour, 166
Examination of ankle & foot, 256
Examination of elbow joint, 228
of hip joint, 234
of supratrochlear lymph node, 229
of wrist joint, 231
Examination of kidney, 560
of bladder, 563
of perineum, 563
of prostate, 564
of ureter, 563
Examination of lymph nodes for breast pathologies, 419
Examination of shoulder joint, 223
Excretory urogram, 568
Exfoliative cytology, 37
Exomphalos, 608
Exophthalmic goitre, 390
Exophthalmos, 383
Exostosis, 163
cancellous, 163
compact, 163
ivory, 163
subungual, 326
Exploratory laparotomy, 507
Exstrophy of bladder, 583
Extensor digitorum, 127
Extensor muscles of wrist joint, 126
Extensor pollicis longus, attrition of, 318
Extradural haemorrhage, 268
Extraperitoneal rupture of bladder, 449
Extravasation of urine, 619, 628

F

Facial cleft, 329, 342
Facial nerve, 274
Facies, 5, 332
abdominal, 454
adenoid, 332
carcinoid, 332
of cretinism, 332
of cushing's syndrome, 332
of dehydration, 454
of hepatic cirrhosis, 332
hippocratica, 454
Faeces, 19
Familial polyposis coli, 515
Fegan's test, 104
Felon, 312
Felty's syndrome, 530
Femoral aneurysm, 608
Femoral hernia, 606
Femoral nerve stretch test, 296
Femoral swellings, 613
Fibre-optic endoscopy, 501
Fibroadenoma, 429
Fibroadenosis, 429
Fibrocystic disease of bone, 160
Fibroma, 47
Fibrosarcoma of bone, 165
Fibrous dysplasia of bone, 160
Filarial epididymo-orchitis, 628
Filarial lymphadenitis, 119
Fissure-in-ano, 542, 550
Fissuring of the tongue, 352
congenital, 352
syphilitic, 352

Fistula, 76
classification of, 79
Fistula-in-ano, 542, 554
Fixed abduction deformity, 236
adduction deformity, 236
flexion deformity, 236, 239
lateral or medial rotation, 236
Flail chest, 396, 399
Flat foot, 322
Flatulent dyspepsia, 483
Flexor carpi ulnaris, 129
Flexor digitorum superficialis & profundus, 128
Flexor pollicis longus, 127
Fluctuation, 29
Fluid thrill, 30, 461, 488
FNAB or FNAC, 37
Follicular carcinoma, 391
Follicular odontome, 336
Foot drop, 123
Fournier's gangrene, 618, 631
Fracture, 173
complications of, 173
Fracture of the rib, 399
Fracture of spine, 285
of anterior cranial fossa, 266
of calcaneum, 211
of capitulum, 190
of clavicle, 181
of greater trochanter, 182
of head of radius, 190
lateral condyle of humerus, 189
of lesser trochanter, 202
of mandible, 334
medial condyle of humerus, 189
of metacarpals & phalanges, 195
of metatarsal bone, 212
of middle cranial fossa, 266
Monteggia, 191
of neck of femur, 201
of neck of humerus, 182
of neck of radius, 190
of olecranon, 190
of patella, 207
of posterior cranial fossa, 267
of scapula, 182
of supracondyle of humerus, 188
T- and Y-shaped, 189
of tibial spine, 209
Freckles, 52
Hutchinson's, 53
Free Thyroxin Index (FTI), 387
Freiberg's disease, 326
Frequency of micturition, 558
increased, 592
Frey's syndrome, 359
Frozen shoulder, 227
Fuchsig's test, 84
Funiculitis, 614
Funnel chest, 403
Furuncle, 46

G

Gait, 5
Galeazzi fracture, 194
Gallbladder, 491, 522, 525
Gallstone ileus, 478
Ganglion, 145, 233, 319
Gangrene, 91
causes of, 91
clinical types of, 91
diabetic, 94
embolic, 93
examination of, 83, 84
infective, 94
neuropathic, 94
senile, 92
signs of, 91
syphilitic, 94
Gas gangrene, 94
Gastric function tests, 493
basal secretion, 494
histamine test, 494
insulin test, 494
maximum secretion, 494
pentagastrin test, 494
Gasrtic ulcer, chronic, 507
Gastrointestinal syndromes, 559
Gastro-jejunal ulcer, 508
Gastro-oesophageal reflux, 441
General survey, 4
Genslen's test, 297
Get above the swelling, 597
Giant-cell tumour of bone, 164
Giant-cell granuloma, 337
Gillie's test, 297
Girdle pain, 282
Glands of Montgomery, 415
Glandular fever, 119
Gliomas, 279
Glioblastoma multiforme, 280
Glomangioma, 44, 319
Glomus tumour, 44, 319
Glossopharyngeal nerve, 274
Goitre, 392
colloid, 389
hyperplastic, 389
multinodular, 389
nodular, 390
primary toxic, 390
retrosternal, 391
secondary toxic, 390
Golfer's elbow, 143, 230
Gonococcal arthritis, 218
Goodsall's rule, 542
Gordon's biological test, 115
Gornall's test, 601
Gout, 220
pseudo, 220
Granuloma inguinale, 637
Granuloma pyogenicum, 59
Granulomatous thyroiditis, 392
Grawitz tumour, 580
Graves' disease, 390
Grey Turner's sign, 471
Gumma of liver, 523
Gummatous orchitis, 624
Gummatous ulcer, 71
Gummatous ulcer of testis, 618
Gynaecomastia, 422, 433
Gynaecomazia, 422, 433

H

Haemangioma, 43
capillary, 43
cavernous, 44
of the face, 330
plexiform, 44
Haemangioma of bone, 164
Haematemesis, 484
Haematocele, 626
Haematoma of the scalp, 329
Haematomyelia, 282
Haematorrachis, 282
Haematuria, 557, 592
Haemolytic anaemia, 529
Haemopericardium, 400
Haemophilic joint, 222
Haemoptysis, 402
Haemorrhoids, 549
internal, 549
Haemothorax, 400
Hallux rigidus, 323
Hallux valgus, 322
Hamilton's ruler test, 180
Hammer toe, 323
Hard chancre, 71
Hare lip, 328
Harvey's sign, 83
Hashimoto's disease, 392
Head injury, 258
complications of, 270
Heberden's nodes, 319
Hepatic flexure of colon, 526
Hereditary spherocytosis, 529
Hernia of hydrocele, 620
Hernia testis, 620
Hernia-en-glissade, 605
Hernia-en-W, 606
Hiatus hernia, 509
Hiccup, 15
Hip dislocation, 201
Hippocratic facies, 332
Hirschsprung's disease, 514
acquired, 514
primary, 514
secondary, 514
Histamine test, 494
Histiocytic lymphoma, 119
Hodgkin's disease, 120
Hollander's insulin test, 494
Homan's sign, 106
Horner's syndrome, 381
Horse-shoe kidney, 576
Humerus neck fracture, 182
Hunterian chancre, 636
of finger, 316
of lip, 350
Hunter's disease, 159
Hurler's disease, 159
Hutchinson's freckle, 53
Hutchinson's pupil, 262
Hydatid cyst of liver, 524
Hydatid thrill, 35, 521
Hydrocele, 625
complications of, 626
encysted of the cord, 626
funicular, 626
of hernial sac, 626
infantile, 626
primary, 625
secondary, 625
Hydrocele of the neck, 52
Hydrocephalus, 327
Hydronephrosis, 577
bilateral, 577
unilateral, 577
Hyperabduction manoeuvre, 84
Hyperaesthesia, 457
Hypernephroma, 580
Hyperparathyroidism, 162, 394
Hyperplastic ileocaecal tuberculosis, 533
Hypertrophic scar, 58
Hypoglossal nerve, 136, 275
Hypospadias, 635

Hypothyroidism, 376
Hypotonic duodenography, 497
Hysterical gout, 220

I

Idiopathic thrombocytopenic purpura, 529
Ileocaecal region, 533
  tuberculosis of, 533
Iliac & inferior venacavography, 301
Iliac abscess, 535
Iliopsoas cold abscess, 535
Implantation dermoid, 43, 319
Impulse on coughing, 26, 31, 612
  in hernia, 597, 598
Incarcerated hernia, 604
Incisional hernia, 610
Incontinence, 559
Increased frequency of micturition, 592
Infection of hand & fingers, 312
Infection of middle & proximal volar spaces, 313
Infection of middle palmar space, 316
Infection of Parona's space, 316
Infection of radial bursa, 315
Infection of thenar space, 315
Infection of ulnar bursa, 314
Infections of fascial spaces, 315
Infections of foot, 324
Infectious mononucleosis, 119
Infective gangrene, 94
Infective ulcer, 74
Inflamed hernia, 605
Inflammatory thickening of cord, 614
Infrapatellar fat injury, 209
Infratentorial haemorrhage, 269
Ingrowing toe-nail, 325
Inguinal hernia, 603
  acquired, 603
  congenital, 603
  direct, 604
  indirect, 603
  oblique, 603
  irreducible, 604
  obstructed, 604
  reducible, 604
  strangulated, 605
Injuries around ankle & foot, 209
  of base of skull, 265, 266
  to the brain, 265, 267
  of collateral ligament, 207
  of cranial nerves, 266
  of cruciate ligaments, 208
  to duodenum, 447
  of duramater, 265
  around elbow, 188
  around hip, 197
  of infrapatellar pad of fat, 209
  to kidney, 448
  around knee joint, 202
  to large intestine, 447
  to liver, 445
  around pelvis, 196
  of the scalp, 264
  of semilunar cartilage, 208
  around shoulder, 177
  to small intestine, 447
  to spleen, 446
  to urinary bladder, 449
  of the vault of the skull, 265, 266
  around wrist & hand, 191
Injury of peripheral nerves, 133
Injury to diaphragm, 401
Injury to heart, 400
Injury to the spinal cord, 285
  complete contusion, 287
  cord concussion, 286
  root transection, 287
  traumatic intra-spinal haemorrhage, 287
Inspection holes, 264
Insulin test, 494
Intermittent claudication, 80
Interossei, 129
Interstitial cystitis, 585
Interstitial hernia, 610
Intestinal colic, 481
Intestinal injury, 447
Intestinal obstruction, acute, 474
  due to worms, 479
Intestinal tuberculosis, 512
Intracranial abscess, 281
Intracranial tumours, 280
Intraperitoneal rupture of bladder, 449
Intrathecal whitlow, 314
Intravenous cholangiography, 500
Intussusception, acute, 477
Invagination test, 600
Investigation for vasospasm, 90
Investigation of motor function, 275
Investigation of sensory function, 275
Irreducible hernia, 604
Irritable hip, 247
Ischaemic ulcer, 69
Ischiorectal abscess, 550
Isotope technique, 90
Itching, 15

J

Jacksonian epilepsy, 259
Jaundice, 6, 484
Jerks, 276
  ankle, 275
  biceps, 276
  knee, 276
  triceps, 276
Joffroy's sign, 383
Joint complications of fracture, 175

K

Kangri cancer, 2
Kaposi's sarcoma, 324
Kay's augmented histamine test, 494
Keloid, 58
Kehr's sign, 446
Kenawy's sign, 492
Keratoacanthoma, 59
Kidney, 526, 535, 560
Kidney injury, 448
Kienbock's disease, 195
Klumpke's paralysis, 136
Knee jerk, 276
Kocher's test, 380
Kohler's disease, 326
Kyphosis, 291, 303

L

Laceration of lung, 400
Lactation carcinoma, 431
Lahey's method, 379
Laparoscopy, 507
Laparotomy, 116
Large intestine injury, 447
Laryngocele, 372
Lassegue's sign, 296
Lateral popliteal nerve, 130
Lentigo, 53
Lesser trochanter fracture, 202
Leukaemia, 530
Leukoplakia, 351
Leukoplakia of penis, 633, 636
Lhermitte's sign, 296
Lid lag, 383
Lid retraction, 383
Lightening pain, 216
Line of demarcation, 83
Lingual thyroid, 343
Lipoma, 47
  diffuse, 49
  encapsulated, 47
  multiple, 49
Lipoma of the cord, 614
Lithotomy position, 541
Littre's hernia, 606
Liver, 489, 522
Liver dullness, obliteration of, 461
Liver injury, 445
Liver scan, 425
Locking, 213
London's sign, 443
Long thoracic nerve, 137
Loose bodies of joint, 222
Loose bodies of knee joint, 209
Loozer's zones, 161
Lordosis, 291, 303
Low back pain, 307
Ludloff's sign, 202
Lumbago, 309
Lumbar disc prolapse, 306
Lumbar hernia, 610
Lumbar punture, 264, 277
Lumbar spondylosis, 307
Lumbosacral strain, 309
Lump, 21
Lunate dislocation, 195
Lung abscess, 407
Lupus vulgaris, 70, 330
Lutein cyst, 479
Lymphadenography, 116
Lymphangiectasis, 614
Lymphangiography, 116, 624
  for urinary case, 573
Lymphangioma, 51
  capillary, 51
  cavernous, 51
  cystic hygroma, 51
Lymphangioma circumscriptum, 51
Lymphangitis of hand, 312

Lymphatic drainage of the skin, 113
of tongue, 347
Lymphatic leukaemia, 121
Lymphatics, 113
Lymph nodes of neck, 368
swellings of, 369
Lymphocytic lymphoma, 120
Lymphoedema, 114
Lymphogranuloma inguinale, 119, 636
Lymphography, 301
Lymphoma, histiocytic, 119
lymphocytic, 120
mixed, 120
Lymph scrotum, 619, 628
Lymph varix, 624, 628

M

Macrocheilia, 329, 342
Macrodactylism, 316
Macroglossia, 342, 351
Macrostoma, 329
Macules, 6
Main en griffe, 123
Madelung's deformity, 195, 316
Madura foot, 324
Magnetic Resonance Imaging (MRI), 38, 279
of brain, 264
of spinal abnormalities, 301
for urinary case, 575
Magnuson's test, 309
Mal-union, 175
Malgaigne's bulging, 602
Malignant lymphoma of thyroid, 392
Malignant melanoma, 54, 121
of foot, 324
subungual, 325
Malingerer's low back pain, 309
Mallet finger, 196, 318
Mallet-Guy's sign, 492
Mammary duct ectasia, 427
Mammary fistula, 415, 427
Mammography, 422
Mandibular cleft, 329
Mandibular prognathism, 340
Manometric examination, 437
March fracture, 326
Marfan's syndrome, 162
Marjolin's ulcer, 72
Martorell's ulcer, 74
Mastitis, 426
acute, 426
chronic, 427
Maximum secretion, 494
Maydl's hernia, 606
McBurney's point, 457
McMurray's test, 205
Measurement, 169
circumference, 169
longitudinal, 169
Meatal ulcer, 636
Meckel's diverticulum, 517
Meconium ileus, 478
Median mental sinus, 339
Median nerve, 138
Median rhomboid glossitis, 351
Mediastinal emphysema, 19, 398
Mediastinal flutter, 396
Mediastinal scanning, 116
Mediastinoscopy, 406
Medullary carcinoma of thyroid, 392
Medulloblastoma, 280
Melaena, 484
Melanoma, benign, 52
Melanoma, malignant, 54
Meleney's ulcer, 71, 74
Meningioma, 280
Meningocele, 302, 327
Meningo-encephalocele, 327
Meniscus injury, 208
Mental state, 272
Mesenteric lymphadenitis, acute, 472
Mesenteric vascular obstruction, 478
Mesentery injury, 447
Metastatic tumours of brain, 280
Metatarsal fracture, 212
Meteorism, 443
Micrognathism, 340
Micturition, 454
Middle palmar space, 315, 316
Mikulicz's disease, 363
Mill's manoeuvre, 230
Miner's elbow, 231
Mixed tumour of salivary gland, 360
Moebius' sign, 384
Moles, 52
blue, 53
compound, 53
hairy, 53
junctional, 53
juvenile, 54
non-hairy or smooth, 53
Molluscum sebaceum, 59
Monteggia fracture, 191
reversed, 191
Monteggia fracture dislocation, 191
Morrant Baker's cyst, 249
Morris' bitrochanteric test, 199
Morrissey's cough test, 104
Morton's metatarsalgia, 326
Moses' sign, 106
Movements of shoulder joint, 224
of foot, 320
of hip joint, 239
of knee joint, 250
of spine, 294
of wrist, 311
Movements of the abdomen, 484
Moynihan's sign, 488
Mucoepidermoid, 362
Mucopolysaccharide disorders, 159
Mucous cyst, 348, 363
Multiple chondromas, 159
Multiple exostoses, 159
Multiple myeloma, 166
Murphy's kidney punch, 561
Murphy's sign, 488
Muscle guard & rigidity, 443
Muscle guard, 459
Muscle power, 125
Muscular rigidity, 459
Myelocele, 302
Myelography, 300
Myositis ossificans traumatica, 175
Myxoedema, 376
symptoms of, 376

N

Naevolipoma, 48
Naevus, 52
blue, 53
compound, 53
junctional, 53
juvenile, 54
Naffziger's sign, 296
Nails, 17
Nausea, 483
Neck of femur fracture, 201
Neck rigidity, 263
Nelaton's line, 199
Neoplasm, 21
Nephroblastoma, 582
Nephroscopy, 572
Nerve conduction study, 133
Nerve injury in fracture, 173
Nerve of Bell, 137
Neurilemmoma, 50
Neurofibroma, 49
elephantiasis, 50
generalized, 49
local, 49
plexiform, 50
Neurolipoma, 48
Neuropathic gangrene, 94
Neuropraxia, 134
Neurotmesis, 134
Night cry, 213
Night fasting test, 494
Nipple, 414, 419
Nodular goitre, 389
multinodular, 389
solitary nodular, 390
Non-Hodgkin's lymphoma, 119
Non-specific mesenteric lymphadenitis, acute, 472
Non-union, 174
Nuclear Magnetic Resonance (NMR), 38

O

Obliteration of liver dullness, 444, 461
Obstructed hernia, 604
Obturator hernia, 610
Obturator test, 459
Occult blood in stool, 495
Ochsner's clasping test, 128
Oculomotor nerve, 273
Odontomes, 336
Oesophagoscopy, 435
Oesophagus carcinoma, 434
Oesophagus rupture of, 400
Olecranon process fracture, 190
Olfactory nerve, 273
Oligodendroglioma, 280
Ollier's disease, 159
Omentum, 527
Onychogryphosis, 325
Onychomycosis, 325
Ophthalmoplegia, 384
Opponens pollicis, 128
Optic nerve, 273
Optimum position of joint, 214
Oral cholecystography, 498
Oriental cholangiohepatitis, 510
Ortolani's test, 241
Oscillometry, 91
Osteitis deformans, 162

Osteoarthritis, 219
of hip, 248
of knee, 254
Osteochondritis, 220
crushing, 220
dissecans, 221
of elbow, 230
juvenilis, 246
of knee, 254
splitting, 221
traction, 221
Osteoclastoma, 164
Osteogenesis imperfecta, 159
Osteoid osteoma, 164
Osteoma, 163
of head, 331
Osteomalacia, 161
Osteomyelitis, 157
acute, 157
chronic, 158
syphilitic, 158
tuberculous, 158
typhoid, 158
Osteomyelitis of bone, 157
of jaw, 339
Osteomyelitis of spine, 306
Osteoporosis, 162
Osteosarcoma, 164
Ovarian cyst, twisted, 479
Ovarian tumour & cyst, 537
Oxyphil adenoma, 361

P

Pachydermatocele, 50
Paget's disease of bone, 162
Paget's disease of breast, 425
Paget's disease of skull, 331
Paget's recurrent fibroid, 47
Pain, 9, 22
of acute abdomen, 450
burning, 12
of chest, 402
of chronic abdomen, 482
constricting, 12
deep, 11
distension, 12
of pathological joints, 213
prostatic, 557
psychogenic, 11
radiation of, 13
rectal, 540
referred, 13
renal, 47
segmental, 11
shifting or migration, 13
shooting, 12
of spinal abnormalities, 219
stabbing, 12
superficial, 11
throbbing, 12
twisting, 13
ureteric, 557
urethral, 557
vesical, 557
Pain in foot, 326
Painful arc syndrome, 227
Pallor, 5
Palpation of the blood vessels, 85
of anterior tibial, 86
of brachial, 87
of common carotid, 87
of dorsalis pedis, 86
of femoral, 87
of popliteal, 86
of posterior tibial, 86
of subclavian, 87
of superficial temporal, 87
Pancoast tumour, 402
Pancreas, 492, 522, 527
Pancreas, carcinoma of, 511
Pancreatitis, acute, 470
Papillary cystadenoma lymphomatosum, 361
Papillary tumours of renal pelvis, 583
Papilloma, 47
Papilloma of bladder, 586
Papilloma of breast, 430
Papilloma of penis, 637
Papules, 6
Paradoxical respiration, 396
Paralytic ileus, 477
Paraoesophageal hiatus hernia, 441
Paraphimosis, 632, 635
Parathyroid tetany, 394
Para-umbilical hernia, 609
Parenchymatous goitre, 389
Parona's space, 314, 316
Paronychia, 312
chronic, 312
Parotid duct, 356
Parotid gland, 355
carcinoma of, 361
tumours of, 362
Parotid tumours, 360
Parotitis, acute, 359
chronic, 360,
subacute, 360
Passive straight-leg raising test, 298
Patella fracture, 207
Patellar tap, 250
Paterson-Kelly syndrome, 438
Pathological dislocation of hip, 248
Pawel's angle, 200
Peau d'orange, 413
Pectoral group of lymph nodes, 419
Pectus carinatum, 403
Pectus excavatum, 403
Pellegrini-Stieda's disease, 254
Pelvic abscess, 537
Pelvi-rectal abscess, 550
Penis, 631
Pentagastrin test, 494
Pen test, 128
Peptic perforation, 473
Peptic ulcer, 509
Percutaneous Transhepatic Cholangiography (PTC), 500
Perforation of diverticular disease of colon, 474
Perforation of typhoid ulcer, 474
Perforation of ulcerative colitis, 474
Perilunate dislocation, 195
Perineal fistula, 554
Perinephric abscess, 579
Peripheral nerve, 122
causes of lesion, 135
examination of , 123
injury of, 133
Peripheral nerve lesion, 135
causes of, 135
Peritoneal lavage, 445
Peritoneocentesis, 445
Perkin's line, 243
Perthes' disease, 244, 246
Perthes' test, 103
modified, 103
Pes cavus, 322
Pes planus, 322
Peyronie's disease, 637
Phalanges fracture, 195
Phalen's sign, 234
Pharyngeal pouch, 371, 438
Phimosis, 632, 635
Phlebography, 107
Phlegmasia alba dolens, 101, 106
Phlegmasia cerulea dolens, 101, 106
Pigeon chest, 403
Pigmented naevus, 52
Piles, internal, 543
Pilonidal sinus, 517, 542, 551
barber's, 319
Pin-hole meatus, 632, 633
Pitting on pressure, 18
Pituitary adenoma, 280
Pizzillo's method, 377
Plantar fasciitis, 143
Plasma cell mastitis, 427
Plasmacytoma, 166
Pleomorphic adenoma, 360
Plethysmography, 91
Plexiform neurofibromatosis, 50
Plummer-Vinson syndrome, 438
Plunging ranula, 353
Pneumococcal arthritis, 218
Pointing index, 124
Pointing sign, 443
Policeman receiving tip, 124
Policeman's heel, 326
Polycystic kidney, 576
Polymazia, 426
Polyps of intestine, 515
familial polyposis coli, 515
Popliteal abscess, 256
Popliteal aneurysm, 256
Popliteal nerve, 130
lateral, 130, 141
medial, 130, 141
Popliteal swelling, 256
Porphyria, 530
Position of rest, 214
Position sense, 132
Post anal dermoid, 549
Posterior interosseous nerve, 137
Post-Traumatic Amnesia (PTA), 258
Pott's disease, 305
Pott's puffy tumour, 265, 330
Pratt's test, 103
Preauricular sinus, 329
Premalignant condition of penis, 636
Priapism, 638
Proctoscopy, 546
Prolapse of rectum, 540, 551
Prostate, benign, hypertrophy of, 587
carcinoma of, 588
Prostatic massage, 625
Prostatic pain, 557
Prostatitis, 588
acute, 588
chronic, 588
Provisional diagnosis, 9
Pruritus ani, 554
Pseudocoxalgia, 246
Pseudo-gout, 220
Pseudolipoma, 49
Pseudopancreatic cyst, 527
true cyst, 527
Psoas abscess, 608

Psoas bursa, 608
Puberty goitre, 389
Pulled elbow, 191
Pulmonary embolism, 409
Pulp-space infection, 312
Pulsatile swelling, 32, 520
Pulsatility, 31
  expansile, 31
  transmitted, 31
Pulse, 6
Pump-handle test, 298
Purpura, 530
  secondary, 530
Pustules, 6
Pyelocele, 626
Pyelonephritis, 579
  acute, 579
Pyloric stenosis, 508
Pylorus of stomach, 526
Pyogenic granuloma, 59
Pyorrhoea alveolaris, 344

Q

Qualitative dyspepsia, 485

R

Rachitic chest, 403
Radial bursa, 315
Radial nerve, 137
Radioactive fibrinogen test, 107
Radioactive scanning of bone, 155
Radiography with barium meal, 436
Radioisotope renography, 575
Radioisotope scanning, 505
  in alimentary bleeding, 506
Ram's horn penis, 619
Ranula, 345, 353
Raspberry tumour, 516
Raynaud's disease, 92
Rebound tenderness, 458
Rectal examination, 539, 543
Rectal prolapse, 551
Rectus sheath, 531
  haematoma of, 531
Recurrent dislocation of shoulder, 182
  of patella, 253
Recurrent fibroid of Paget, 531
Red-currant jelly, 462
Reducibility, 612, 622
Referred pain, 451
Reflexes, 275
  abdominal, 276
  cremasteric, 276
  knee, 276
  plantar, 275
Regional ileitis, 534
Reiter's disease, 218
Renal angiography, 572
Renal calculus, 578
Renal cell carcinoma of kidney, 580
Renal cyst, 579
Renal failure, 559
Renal function test, 565
Renal injury, 448
Renal pain, 555
Renal scintiscan, 575
Renal stone, 579
Renal tuberculosis, 580
Renal tumours, 580
Respiration, 6
Respiratory movements, 403
Rest pain, 81
Retention cyst, 363
Retention of urine, 558, 590
  acute, 590
  chronic, 591
Retractile testis, 616
Retraction of nipple, 411
Retrograde urogram, 569
Retrograde-Traumatic Amnesia (RTA), 258
Retroperitoneal cyst, 532
  lymphoma, 532
  sarcoma, 532
Retrosternal goitre, 377, 391
Reversed Monteggia fracture, 191
Rheumatoid arthritis, 219
  of hand, 318
Rib tumours, 406
Richter's hernia, 605
Rickets, 161
  infantile, 161
  renal, 161
  renal tubule, 161
Rickety rosary, 403
Riedel's thyroiditis, 393
Rigidity of neck, 263
Rigidity of spine, 289, 294
Ring occlusion test, 601
Rodent ulcer, 54
Romberg's sign, 275
Root transection, 287
Rotator cuff, 223
Rovsing's sign, 458
Rupture oesophagus, 400
Rupture of achilles tendon, 144
  of biceps tendon, 228
  of extensor pollicis longus, 318
  of long head of biceps, 144
  of supraspinatus tendon, 144, 227
  of rectus abdominis muscle, 481
  of supraspinatus tendon, 144
Rupture of thoracic aorta, 400
Rupture of thoracic duct, 401
Rupture of urinary bladder, 449
  extraperitoneal, 449
  intraperitoneal, 449
  of duodenum, 447
  of kidney, 448
  of large intestine, 447
  of liver, 445
  of mesentery, 447
  of small intestine, 447
  of spleen, 446
Ruptured aortic aneurysm, 480
Ruptured ectopic gestation, 479
Ruptured lutein (follicular) cyst, 479
Ruptured tubal gestation, 537

S

Sacro-iliac arthritis, 309
Sacro-iliac joint, 297
Sacro-iliac strain, 309
Sacro-iliac tuberculosis, 309
Sacrococcygeal teratoma, 548
Salpingitis, acute, 472
Saphena varix, 607
Sarcoidosis, 119
Sarcoma, 56
Sarcoma of breast, 433
Scalene node biopsy, 406
Scalenus anticus syndrome, 93
Scaphoid fracture, 195
Schatzki's ring, 440
Schoemaker's line, 199
Schwannoma, 50
Schwartz test, 103
Sciatic nerve, 130, 141
Scirrhous carcinoma, 430
Scleroderma, 439
Scoliosis, 290, 302
  compensatory, 302
  congenital, 302
  idiopathic, 302
  mobile, 302
  paralytic, 302
  postural, 302
  structural, 302
Screening of diaphragm, 406
Scrotum, 617
Seat-belt injury, 445
Sebaceous cyst, 56
Sebaceous cyst of scrotum, 631
Sebaceous horn, 58
Seborrhoeic keratosis, 60
Seborrhoeic wart, 60
Secondary carcinoma of lymph nodes, 121
Secondary carcinoma of bone, 166
Secondary carcinoma of skull, 331
Secondary carcinoma of spine, 307
Secondary thyrotoxicosis, 375, 390
Selective angiography, 89
Selective visceral angiography, 506
Semilunar cartilage injury, 208
Seminoma of testis, 630
Senile gangrene, 92
Senile keratosis, 60
Senile wart, 60
Sensation, 131
  position, 132
  temperature, 132
  vibration, 132
Serratus anterior, 126
Serum Acid & Alkaline Phosphatase, 575
Serum PBI, 386
Serum T^3, 386
Serum thyroxin (T^4), 386
Sherren's triangle, 457
Shifting dullness, 460, 489, 521
Shifting of pain, 451
Shoulder joint dislocation, 182
  recurrent dislocation, 182
Shoveller's fracture, 286
Sialectasis, 359
Sialography, 357
Sigmoidoscopy, 547
Sign-de-dance, 460
Signs of ischaemia, 82
Sim's position, 540
Sinus, 76
  classification of, 79
Sjogren's syndrome, 363
Skin eruption, 6
Skin test, 37
Sliding hernia, 605
Slipped epiphysis, 244, 246
Small intestine & mesentery, 532
  cysts of mesentery, 532

tuberculous lymphadenitis, 532
tumours, 532
Smith's fracture, 194
Soft chancre, 71
Solar keratosis, 60
Solitary bone cyst of jaw, 337
Solitary renal cyst, 576
Spermatic cord, 623
Spermatocele, 631
Spigelian hernia, 610
Spina bifida, 301
Spina bifida occulta, 301
Spleen, 491, 522, 528
Spleen injury, 446
Spondylolisthesis, 291, 304
Sprain, 173
Springing of fibula, 205, 210
of radius, 184
Squamous cell carcinoma, 54
Stability of knee joint, 206
Stellwag's sign, 383
Stenosing tenovaginitis, 144, 233
Stensen's duct, 356
Sternoclavicular dislocation, 181
Sternomastoid tumour, 372
Stomach, 489
Stomatitis, 348
angular, 350
aphthous, 349
gangrenous, 350
monilial, 349
vincent's (ulcerative), 349
Stove-in-chest, 399
Straight-leg raising test, 295, 298
Strain of spring ligament, 326
Strangulated hernia, 605
Strangury, 454
Stricture of rectum & anal canal, 553
Struma thyroiditis, 393
Student's elbow, 228, 231
Subacromial bursitis, 228
Subacute epididymo-orchitis, 628
Subacute parotitis, 360
Subacute thyroiditis, 392
Subclavian steal syndrome, 95
Subcortical haemorrhage, 268
Subdeltoid bursitis, 228
Subdural haemorrhage, 268
Sublingual dermoid, 353
Sublingual salivary gland, 363
tumours of, 363
Subluxation, 173
Subluxation of head of radius, 191
Submandibular salivary gland, 357
calculus of, 362
tumours of, 363
Subphrenic abscess, 473, 521, 525
Subungual exostosis, 325
Sudeck's osteodystrophy, 176
Superficial phlebitis, 81
Superficial vein thrombosis, 107
Suppurative arthritis, 217
Suppurative cholangitis, 523
Suppurative pylephlebitis, 523
Suppurative urethritis, 217
Supraclavicular lymph node, left, 519
Supracondylar fracture of humerus, 188
Suprarenal tumour, 526
Supraspinatus tendinitis, 143
Supratentorial haemorrhage, 268
Surgical emphysema, 397, 399
Swelling, 21
congenital, 40
consistency of, 28
diagnosis of, 40
edge of, 27
fluctuation of, 29
of foot, 323
inflammatory, 41
neoplastic, 41
size, shape & extent of, 27
tenderness of, 27
translucency of, 31
traumatic, 40
Swellings of the jaw, 336
Syndactylism, 316
Synovial sarcoma, 56, 166
Synovioma, 56
Syphilis in tongue, 351
Syphilitic chancre, 636
Syphilitic gangrene, 94
Syphilitic lymphadenitis, 119
Syphilitic orchitis, 628
Syphilitic osteomyelitis, 158
Syphilitic ulcer, 71
Syringo-myelocele, 302

T

T3 resin uptake, 386
T3 suppression test, 388
Tactile sensitivity, 131
Tailor's bursa, 257
Takayasu's arteritis, 95
Talipes, 321
calcaneovalgus, 322
equinovarus, 321
Taxis, 600
Tear of bronchus, 400
Tearing of inferior epigastric artery, 481
Telescopic test, 241
Temperature, 7
Temporomandibular joint, 335
Tender spot, 488
Tenderness of abdomen, 457
Tennis elbow, 143, 230
Tension pneumothorax, 400
Teratoma of testis, 630
Testicular cyst, 631
Testicular sensation, 622
Testis, 622
Test of stability of knee joint, 206
Tetany, 395
Thenar space, 315
Thermography, 424
Thomas' test, 236
Thoracic duct, rupture of, 401
Thoracic outlet syndrome, 93
Thromboangiitis obliterans, 92
Thrombophlebitis, 107
Thyroglossal cyst, 377, 393
Thyroglossal fistula, 378, 394
Thyroid bruit, 385
Thyroid carcinoma, 391
Thyroid function test, 385
Thyroid scan, 388
Thyroid swellings, 389
Thyroid tumours, 391
anaplastic carcinoma, 391
carcinoma, 391
follicular carcinoma, 391
papillary carcinoma, 391
Thyroid uptake test, 387
Thyrotoxicosis, 375
primary, 375, 390
primary manifestations of, 383
secondary, 375, 390
secondary manifestations of, 385
symptoms of primary, 375
symptoms of secondary, 375
Thyroxin, serum, 386
Tibial nerve, 130
Tibial spine fracture, 209
TNM classification, of breast cancer, 430
Tongue, 16
Tongue carcinoma, 352
Torsion of testis, 615, 629
Torticollis, 372
Tourniquet test, 102
Toxic goitre, primary, 390
secondary, 390
Translucency, 31
Transmitted movement, 169
Transverse colon, 527
Trapezius, 126
Traumatic asphyxia, 400
Traumatic fat necrosis, 426
Traumatic haemothorax, 400
Traumatic pneumothorax, 398
Traumatic ulcer, 69
Tremor, 384
Trendelenburg test, 102, 235
Trethowan's sign, 245
Tri-iodothyronine, serum, 386
Triceps jerk, 276
Trigeminal nerve, 273
Trigger finger, 144, 318
Trismus, 335
Trochlear nerve, 273
Troisier's sign, 493, 519
Trophic ulcer, 70
Tropical ulcer, 70, 75
Trousseau's sign, 395, 511
TSH, 387
Tubal gestation, 537
Tuberculoma, 280
Tuberculosis, intestinal, 512
Tuberculosis of hip, 245, 247
of foot, 324
of knee, 253
Tuberculosis of mesenteric lymph nodes, 513
Tuberculosis of sacro-iliac joint, 309
Tuberculosis of spine, 305
Tuberculous arthritis, 218
of ankle joint, 257
of hip joint, 237
Tuberculous cystitis, 585
Tuberculous epididymo-orchitis, 627
Tuberculous lymphadenitis, 118
Tuberculous osteomyelitis, 158
Tuberculous ulcer, 70
Tuberculous ulcer of scrotum, 620
Tubo-ovarian mass, 537
Tumours of bladder, 586
Tumours of kidney, 580
Tumours of prostate, 588
Tumours of testis, 630
Tumours of the lower jaw, 338
Tumours of the upper jaw, 337

Turban tumour, 331
Twisted ovarian cyst, 479
Typhoid arthritis, 218
Typhoid osteomyelitis, 158

U

Ulcer, 61
arterial, 69
base of, 65
Bazin's, 74
callous or chronic, 68
diabetic, 70
discharge of, 64
edge of, 63
edge & margin, 65
examination of, 61
floor of, 64
of foot, 324
gummatous, 71
healing, 68
ischaemic, 69
of leg, 73
malignant, 69
Marjolin's, 72
Martorell's, 74
Meleney's, 74
neurogenic, 70
non-specific, 68
position of, 62
size & shape, 62
specific, 69
spreading, 68
syphilitic, 71
of tongue, 352
traumatic, 69
trophic, 70
tropical, 70
tuberculous, 70
venous, 69, 73
Ulcerative colitis, acute, 472
chronic, 515
Ulnar bursa, 314
Ulnar nerve, 140
Ultrasonography, 37
Ultrasound of breast, 424
of chronic abdomen, 502
of urinary case, 574
Ultrasound doppler effect, 90
Umbilical abscess, 516
Umbilical adenoma, 516
Umbilical calculus (concretion), 516
Umbilical carcinoma, 516
Umbilical fistula, 516
Umbilical hernia, 531, 609
acquired, 609
congenital, 609
para-umbilical, 609
Umbilicus, 531
diseases of, 516
Unconscious depth of, 260
Undescended testis, 536, 615
Unilateral hydronephrosis, 577
Uptake test, 387
Urachal cyst, 536
Ureteric calculus, 582
Ureteric catheterisation, 572
Ureteric colic, 480
Urethral pain, 557
Urethral stricture, 590
Urethrography, 571
Urethroscopy, 572
Urinary bladder injury, 449
Urinary calculus, 578
Urogram, excretory, 568
antegrade, 570
retrograde, 569
Uterus, 536

V

Vagus nerve, 274
Varicocele, 613
Varicose vein, 100
causes of, 105
complications of, 104
examinations of, 101
Vascular angle, 82
Vascular sign of Narath, 239
Venereal warts, 637
Venous refilling, 83
Venous thrombosis, 105
deep, 106
superficial, 107
Venous ulcer, 69, 73
Ventriculography, 264, 278
Vertebral angiography, 278
Vesical angiography, 573
Vesical calculus, 584
Vesical pain, 557
Vesical tumours, 584
Vesicles, 6
Vibration sensation, 132
Victor Horsley's sign, 262
Vincent's stomatitis, 344
Violence 167
direct, 167
indirect, 167
muscular 167
Virchow's lymph nodes, 113
Visible peristalsis, 518
Visible veins, 16
Vocal fremitus, 398, 404
Volkmann's ischaemic contracture, 175, 187, 317
Volvulus of caecum, 478
Volvulus of midgut, 478
Volvulus of sigmoid colon, 478
Vomiting, 14, 453, 483
Von Recklinghausen's disease, 49
of bone, 162
Von Graefe's sign, 383

W

Warthin's tumour, 361
Warts, 58
Wasserman reaction, 277
Watering Can perineum, 77
Webs & rings of oesophagus, 440
Web space infection, 313
Werner test, 388
Wharton's duct, 358
Wheal, 6
Wilms' tumour, 582
Winging of scapula, 123
Wrist drop, 123

X

X-ray examination of bone, 151
X-ray of bone & joint injuries, 170, 180, 187, 193, 200
of acute abdomen, 464
of brain tumour, 277
of diseases of chest, 405
of knee joint, 248
of KUB, 567
of pathological joint, 216
of spinal abnormalities, 299
of spinal injuries, 285
Xeroradiography, 423

Y

Yaws, 75

Z

Zieman's technique, 599